# A nurse-inserted Peripherally Inserted Central Catheter program in General Pediatrics: A single-center experience

**Zhuowen Yu**
Children's Hospital of Fudan University
**Xiaojing Hu**
Children's Hospital of Fudan University
**Xiaofeng Xu**
Children's Hospital of Fudan University
**Lili Lin**
Children's Hospital of Fudan University
**Ying Gu**
Children's Hospital of Fudan University
**Jianguo Zhou** ( zhoujianguo220@126.com )
Children's Hospital of Fudan University

**Research Article**

**Keywords:** Peripherally inserted central catheter, pediatrics, malposition, complication, arm movements

**Posted Date:** May 12th, 2022

**DOI:** https://doi.org/10.21203/rs.3.rs-1628862/v1



**Additional Declarations:** No competing interests reported.

**Version of Record:** A version of this preprint was published at BMC Pediatrics on January 14th, 2023. See the published version at https://doi.org/10.1186/s12887-022-03809-x.

# Abstract

**Background** A peripherally inserted central catheter (PICC) with its tip preferably in the vena cava is essential in caring patients with chronic conditions in general pediatrics. However, the information regarding the experience is limited.

**Objectives** To share the experience of a nurse-inserted peripherally inserted central catheters (PICC) program initiated in a general pediatric department.

**Methods** A retrospective descriptive cohort study based on prospectively collected data was conducted. All PICCs inserted in the departments of gastroenterology and pulmonology in a tertiary pediatric center from Dec. 2015 to Dec. 2019 were included in the study. Complications and risk factors were analyzed by comparing cases with and without complications. We also reported arm movements in malpositioned PICC corrections.

**Results** There were 169 cases with a median(IQR) age of 42(6, 108) months who received PICC insertion during a 4-year period. Inflammatory bowel disease was the leading diagnosis accounting for 25.4% (43/169) of all cases. The overall complication rate was 16.4 per 1000 catheter days with malposition and obstruction as the two most common complications. Multivariate models performed by logistic regression demonstrated that young age [p=0.004, OR(95%CI) = 0.987(0.978, 0.996)] and small PICC diameter (1.9Fr, p=0.003, OR(95%CI) = 3.936(1.578, 9.818)] were risk factors for PICC complications. Correction of malpositioned catheters was attempted and all succeeded in 9 eligible cases by using arm movements.

**Conclusion** The nurse-inserted PICC program in general pediatrics is feasible without causing high complication rate. PICC tip malposition and obstruction were two major PICC-related complications, when low age and small catheter lumina were major risk factors. Furtherly, arm manipulation potentially is an easy and effective approach for correcting malpositioned newly-inserted PICC catheters.


# Key messages

The nurse-inserted PICC program in general pediatrics out of intensive care unit is feasible, without causing high rate of complications.

PICC tip malposition and obstruction were two major PICC-related complications in the nurse-inserted PICC, when low age and small catheter lumina were major risk factors.

Arm manipulation potentially is an easy and effective approach for correcting malpositioned newly-inserted PICC catheters.

# Background

Obtaining peripheral venous access in pediatric patients with chronic disease for the purpose of infusing parenteral nutrition or stimulant drugs is often challenging for nursing professionals. A peripherally inserted central catheter (PICC) with its tip preferably in the vena cava allows for middle to long-term intravenous therapy, blood sampling, and reductions in repeated intravenous catheterizations[1,2]. Though PICC insertion is a relatively convenient and effective technique, it can cause life-threatening complications such as catheter-related bloodstream infection[3,4] and pericardial tamponade[5–8].

PICCs, inserted by nurses at the bedside, have been routinely used in the neonatal and pediatric intensive care units for decades in our hospital, a leading pediatric academic center in China. With increasing numbers of pediatric patients with chronic conditions referred from other hospitals, PICC insertion in pediatric sub-specialties other than intensive care units, such as the department of gastroenterology and pulmonology, was promoted. However, interventional pediatric radiologists inserting PICC under fluoroscopic guidance, which is common in developed countries, is not available yet in China. Therefore, a nurse-led PICC insertion program outside of the intensive care unit was established in Dec. 2015. Since then, there have been 169 patients received PICC insertion in the department of gastroenterology and pulmonology. The objective of this study was to share the experience of a nurse-inserted pediatric PICC program outside intensive care units, mainly focusing on PICC-related complications and risk factors.

## Patients And Methods

# Study design, setting, and participants

This is a retrospective cohort study. All inpatients with PICC insertion in the department of gastroenterology and pulmonology at the Children's Hospital of Fudan University from Dec. 2015 through Dec. 2019 were included in the study. The department is a leading pediatric referral center in China for the treatment of chronic pediatric gastrointestinal and lung diseases, such as infant onset inflammatory bowel disease, intractable diarrhea, infant chronic lung disease, and pneumonia with complications. The study was approved by the Institutional Review Board of the Children's Hospital of Fudan University.

The indications for PICC insertion in the department included: patients requiring intermediate- to long-term intravenous access for medications, fluid therapy, or parenteral nutrition; expected difficult peripheral IV catheter insertion during hospitalization. Contraindications included infection at the insertion site; damaged or thrombosed vessels caused by previous catheter insertions or repeated attempts; severe coagulopathy or thrombocytopenia.

# PICC practice

Informed consent was obtained from the parent or guardian. PICC insertion occurred in a therapeutic suite using sterile technique and topical anesthetic was applied. The insertion procedure and post-insertion maintenance were guided by institutional protocol. The placement of the PICC tips was confirmed by x-ray after insertion. Of note, if PICC tip malposition was discovered in upper limb insertion, a serial arm movements procedure as reported by Nadroo et al. was attempted to correct the malposition

in eligible patients[9]. For PICCs inserted via basilic veins, the arm was abducted at the shoulder and extended the elbow as far as possible, then adducted at the shoulder and flexed at the elbow; for PICCs inserted via cephalic veins, the arm was adducted at the shoulder and extended at the elbow as fa as possible, then the shoulder was abducted and the elbow was flexed. After the movements, a repeat x-ray was performed within 24 hours to confirm the placement of the PICC tip.

# Data collection and definition

All data including patient gender, age, clinical diagnosis, indications for PICC, insertion procedure, post-insertion x-ray, PICC dwell time, and complications were extracted from a prospectively registered database. Procedure time was recorded from entry into the procedure room to exit from the room after completion of the procedure. PICC tip placement was determined by radiography as either central or non-central. Reasons for PICC removal were categorized as planned if the therapy ended, otherwise categorized as unplanned removal. Complications of PICC were defined as following[10]: malposition, the inappropriate position of PICC tip after insertion; catheter blockage, obstruction of the catheter; dislodgment, accidental removal of PICC; fracture and fragmentation, catheter breakage; mechanical phlebitis, clinical signs of tenderness, erythema, and edema at insertion site; infection, systemic or insertion site bacteremia or fungi infection.

# Statistical analysis

Analyses were performed using SPSS 25 (SPSS, Inc., Chicago, IL). Patient characteristics were demonstrated as counts with proportions for categorical variables and median with interquartile range (IQR) for continuous variables. The comparison between patients with and without complications was conducted using Pearson chi-square or Fisher's exact test for categorical variables and Mann-Whitney U test for continuous variables. The variables with p-value less than 0.1 were collected and used to study the risk factors for PICC-related complications by logistic regression analyses using multivariate models. PICC diameter choice was significantly dependent on age, therefore, PICC diameter and age were collinear variables and put in the model separately. A p-value $< 0.05$ was considered statistically significant.

## Results

# PICC and Patient characteristics

There were 169 cases of patients with a median(IQR) age of 42(6, 108) months who received PICC insertion during the 4-year period. Inflammatory bowel disease(43/169, 25.4%) was the leading diagnosis in all cases followed by chronic diarrhea(18/169, 10.7%), upper gastrointestinal bleeding(18/169, 10.7%), pneumonia(15/169, 8.9%) etc. Requiring parenteral nutrition was the major indication for PICC insertion in 65.1%(110/169) cases followed by expected intravenous infusion requirement > 6days(49/169, 29.0%) and difficult peripheral intravenous catheter insertion(10/169, 5.9%). For all PICC insertions, one puncture success rate was 52.7%(89/169); the total device days was 2859, with a median catheter retention

duration of 12(8, 20) days; 32.5%(55/169) received 1.9 Fr catheter; 43.2%(73/169) was inserted through a basilic vein.

# Complications of PICC and risk factors

Forty-seven onsets of complications occurred in 43 cases including 16 catheter malposition, 14 catheter obstruction, 9 mechanical phlebitis, 6 external breakages, 1 catheter-related bloodstream infection, 1 bleeding, and 1 limb edema. The total complication rate was 16.4 per 1000 catheter days. 56.3%(9/16) of malposition and 100%(14/14) of obstruction occurred in 1.9Fr cases. The complications of PICC were demonstrated in Table 1.

Table 1
Complications of PICC and clinical outcomes

| Complications | Cases (rate per 1000 catheter days) * | Catheter diameter/Fr | | | Treated in place | unplanned removed/exchanged |
|---|---|---|---|---|---|---|
| | | 1.9 | 3.0 | 4.0 | | |
| Malposition | 16(5.6) | 9 | 2 | 5 | 16 | 0 |
| Obstruction | 14(4.9) | 14 | 0 | 0 | 11 | 3 |
| Mechanical phlebitis | 9(3.1) | 2 | 1 | 6 | 9 | 0 |
| External breakage | 5(1.7) | 3 | 2 | 0 | 2 | 3 |
| Catheter-related bloodstream infection | 1(0.3) | 0 | 1 | 0 | 0 | 1 |
| Bleeding | 1(0.3) | 0 | 0 | 1 | 0 | 1 |
| Impaired venous return | 1(0.3) | 0 | 1 | 0 | 0 | 1 |
| Total | 47(16.4) | 28 | 7 | 12 | 38 | 9 |
| * Total catheter days = 2859 | | | | | | |

The comparison between patients with and without PICC complications demonstrated that age, procedure time, catheter diameter, puncture number were potential risk factors for complications with p-value less than 0.1(Table 2). As age and catheter diameter were collinear variables, two multivariate models were performed by logistic regression, with the results demonstrating that young age and small PICC diameter were risk factors for PICC complications (Table 3).

Table 2
Comparison of patients with and without PICC-related complications

| Variables | Total<br>N = 169 | With complications<br>N = 43 | without complications<br>N = 126 | P-value |
|---|---|---|---|---|
| Sex-male — n (%) | 97(57.4) | 28(65.1) | 70(55.6) | 0.273 |
| Age in months—Median(IQR) | 42(6,108) | 9(2, 50) | 66(12, 120) | <0.001 |
| Age categories — n (%) | | | | 0.001 |
| 1month-1year | 59(34.9) | 25(58.1) | 34(27.0) | |
| ~5year | 37(21.9) | 9(20.9) | 28(22.2) | |
| ~10year | 40(23.7) | 6(14.0) | 34(27.0) | |
| ~16year | 33(19.5) | 3(7.0) | 30(24.8) | |
| Total device days—Median(IQR) | 12(8, 20) | 13(10, 24) | 12(8, 20) | 0.433 |
| Procedure time—Median(IQR) mins | 40(30,80) | 60(30, 120) | 40(30, 60) | 0.031 |
| Puncture number — n (%) | | | | |
| One | 89(52.7) | 16(37.2) | 73(57.9) | 0.061 |
| Two | 25(14.8) | 8(18.6) | 17(13.5) | |
| Three or more | 55(32.5) | 19(44.2) | 36(28.6) | |
| Catheter diameter — n (%) | | | | < 0.001 |
| PICC 1.9Fr | 55(32.5) | 24(55.8) | 31(24.6) | |
| PICC 3.0Fr | 22(13.0) | 6(14.0) | 16(12.7) | |
| PICC 4.0Fr | 92(54.4) | 13(30.2) | 79(62.7) | |
| Sites of insertion — n (%) | | | | 0.309 |
| Right arm | 117(69.2) | 25(58.1) | 92(73.0) | |
| Left arm | 31(18.3) | 10(23.3) | 21(16.7) | |
| Leg | 11(6.5) | 4(9.3) | 7(5.6) | |
| Jugular vein | 10(5.9) | 4(9.3) | 6(4.8) | |

*Fisher's exact test. IQR, interquartile range; PICC, peripherally inserted central catheter.

Table 3
Risk factors for PICC-complications in pediatric cases identified by logistic regression

| Risk factors | B | Wald | P-value | Odds Ratio [95%] |
|---|---|---|---|---|
| Model 1* | | | | |
| Age (month, continuous) | -0.013 | 8.114 | 0.004 | 0.987[0.978, 0.996] |
| Procedure time (minute, continuous) | 0.002 | 0.199 | 0.655 | 1.002[0.993, 1.012] |
| Puncture number | | | | |
| One | -0.284 | 0.345 | 0.557 | 0.753[0.293, 1.939] |
| Two | 0.3 | 0.271 | 0.603 | 1.350[0.436, 4.183] |
| Three or more | Reference | . | . | . |
| Model 2** | | | | |
| Catheter diameter | | | | |
| 1.9 Fr | 1.37 | 8.632 | 0.003 | 3.936[1.578, 9.818] |
| 3.0 Fr | 0.867 | 2.236 | 0.135 | 2.380[0.764, 7.417] |
| 4.0 Fr | Reference | . | . | . |
| Procedure time (minute, continuous) | 0.002 | 0.221 | 0.638 | 1.002[0.993, 1.012] |
| Puncture number | | | | |
| One | -0.267 | 0.297 | 0.586 | 0.765[0.293, 2.001] |
| Two | 0.413 | 0.496 | 0.481 | 1.511[0.479, 4.766] |
| Three or more | Reference | . | . | . |
| *Model 1 variables included age, procedure time, and puncture number; | | | | |
| **Model 2 variables included catheter diameter, procedure time, and puncture number. | | | | |

# PICC malposition correction

Of 16 incidents of PICC malposition, 9 cases eligible for arm movement were successfully corrected by arm movements. The typical x-ray images before and after the maneuver were demonstrated in Fig. 1(6 cases were demonstrated, while the other 3 cases reported previously[11]).

# Discussion

This study reported the experience of a nurse-inserted PICC program in a pediatric sub-specialty outside intensive care unit in a tertiary children's hospital from China. Of all cases, 83.4%(141/169) were from the department of gastroenterology with inflammatory bowel disease as the most common diagnosis while 16.6%(28/169) were from pulmonology with pneumonia as the most common diagnosis. The age range of cases was from 1 month to 16 years old. PICCs inserted during the study had catheter diameters ranging from 1.9Fr to 4.0Fr. Regarding the age range of patients, PICC insertion in such a pediatric sub-specialty seems more challenging than that in neonatal intensive care units, where age and weight were more uniform. PICC in pediatric sub-specialties apart from intensive care units has been reported in other studies. Piper et al. reported that, for infants with intestinal failure, PICCs offer an advantage over central venous catheters; PICCs can often be inserted without general anesthesia and have a low rate of catheter-related bloodstream infection and venous thrombosis. The study recommended PICCs for infants with intestinal failure requiring parenteral nutrition[12]. Gibson et al. from Canada reported PICC use at a tertiary care pediatric center. The number of PICCs used outside intensive care units, including general pediatrics, oncology, cardiology, general surgery, gastrointestinal medicine, and neurosurgery, increased from 2001 to 2012[13]. In China, PICC use in pediatric sub-specialties other than oncology and intensive care units is underdeveloped. Since interventional pediatric radiologists inserting PICCs under fluoroscopic guidance, which is common in developed countries, is not available yet in China. The nurse-inserted PICC program reported in this study is a feasible alternative model meriting introduction to other pediatric subspecialties.

The complication rate in our study was 16.4 per 1000 catheter days. The result is consistent with other reports. In a review, Westergaard et al reported the overall rates of complications in pediatric populations ranging from 1.11 to 19.3 per 1000 catheter days[14]. Of all complications in our cases, only 19.1%(9/47) required removal or replacement of the PICC, the rate was much lower than one-third as reported in previous publications[15]. Therefore, only a small proportion of complications in cases included in this study could be classified as severe. Malposition was the leading complication in our cases, however, 93.8%(15/16) of cases were primary malposition occurred just after insertion; only one incident of secondary malposition occurred as a result of patient behavior (severe cough). 60%(9/15) of primary malposition occurred in 1.9Fr cases, ultrasound not being used for guiding PICC procedure in such low age group potentially delayed the detection of malposition. PICC obstruction, with a rate of 4.9 per 1000 catheter days was the second most common complication, all of which occurred in cases where a 1.9Fr lumen PICC was inserted. Obstruction was significantly greater in PICCs with smaller lumina. The result is consistent with Thiagarajan et al.'s study[16]. There was one catheter-related bloodstream infection that occurred in our study, the rate was 0.3 per 1000 catheter days which was relatively low compared with the rates reported in previous studies in pediatrics ranging from 1.4 to 2.0 per 1000 catheter days[16,17]. We ascertained that the risk factors for PICC complications were low age and small PICC lumina. The result was consistent with Flores Moreno M's report[18]. Of all 28 1.9Fr complications, 50%(14/28) was obstruction. In a review, Westergaard recommended daily flushing of the catheter with saline or a heparin solution(50-100U/ml) to reduce the risk of catheter obstruction[14]. The approach potentially could be introduced to 1.9Fr cases.

Of 16 malposition, 9 were corrected by arm movement. Correct PICC tip position by arm manipulation has been reported previously. Nadroo et al. reported that arm movements significantly affect the position of the tip of the PICCs in neonatal cases. For catheters that were placed in the basilic vein, simultaneous shoulder adduction and elbow flexion caused the greatest movement toward the heart(15.11 ± 1.22mm)[9]. Another adult study reported that there was a large amplitude of PICC tip position change with the depth of inspiration and arm position[19]. Since arm movement significantly alters PICC tip position, there were studies using arm movement for correcting malposition. Nadroo et al. described the maneuver for correcting PICC malposition and approved the effectiveness[9]. The maneuver was used in this study. Besides arm movement, a high-flow flush technique was another approach to malposition correction studied in previously published studies with a success rate of approximately 70%[20]. Of note, arm movement and high-flow flush are only alternative approaches for PICC malposition correction while radiologic intervention is the first or only choice in certain complicated cases[21].

Our study comprehensively reported the experience of PICC practice in infants and children outside intensive care units from a single tertiary pediatric center. All clinical data were collected prospectively, therefore, the data accuracy was high. Risk factor analyses for complications and malposition correction techniques provided a valuable reference for counterparts. Our study has limitations as well. Firstly, in analyzing risk factors for complications, some risk factors reported in previous studies[22,23], such as dual lumen catheters, non-central position of the catheter tip, were not identified due to small sample size (only 2 non-central cases) and only single lumina catheters used in our practice. Secondly, Rastogi et al. reported that a malapportioned PICC potentially could be corrected spontaneously[24]. Arm movement was approved effective in malposition correction in our descriptive study, however, without non-intervention control, the necessity of proactive correction by arm movement warrants further comparison studies.

Even though the complication rate in overall cases was not remarkably high, there is still large room for improvement. The following approaches could be carefully reviewed in future cases: ultrasound for guiding PICC insertion, routine daily heparin flushing in 1.9Fr cases, novel approaches for guiding PICC insertion, such as intracavitary electrocardiogram etc.[25].

# Conclusions

the nurse-inserted PICC program in general pediatrics is feasible with low complication rate. PICC tip malposition and obstruction were two major PICC-related complications with low age and small catheter lumina as risk factors. Arm movement potentially is an easy approach for correcting malpositioned PICC catheters.

# Abbreviations

PICC  peripherally inserted central catheter

# Declarations

### Availability of data and materials

The data that support the findings of this study are available from the corresponding author, Jianguo Zhou and Ying Gu

### Ethics approval and consent to participate

The research proposal was approved by Ethics Committee of Clinical Research, Children's Hospital of Fudan University, Shanghai. Informed consent was assured from guardians of children for participation in this research. All study methods were implemented in line with involved guidelines of Helsinki Declaration.

### Consent for publication

Informed consent for publication of data was taken from children’s guardians and all the data can be published.

### Availability of data and materials

The data that support the findings of this study are available from the corresponding author, Jianguo Zhou and Ying Gu

### Competing interests

The authors declare that there is no conflict of interest.

### Funding

No funding.

### Authors' contributions

ZY and JZ conceived the original idea and designed the study. XX and LL collected the data. ZY and XH interpreted the results. ZY and JZ drafted the paper. YG revised it critically. All authors approved the final

# References

1. Practical guide for safe central venous catheterization and management 2017. J Anesth. 2019.
2. Cotogni P, Pittiruti M. Focus on peripherally inserted central catheters in critically ill patients. World J Crit Care Med. 2014;3(4):80–94.
3. Vachharajani AJ, Vachharajani NA, Morris H, et al. Reducing peripherally inserted central catheters in the neonatal intensive care unit. Journal of perinatology: official journal of the California Perinatal

Association. 2017;37(4):409–413.

4. Mori N, Nishihara Y, Tayama H, Higuchi A, Aoki Y. Peripherally inserted central catheter-related bloodstream infection caused by Kocuria marina in an elderly man. Infection. 2017;45(5):683–686.
5. Minghui Z, Hujun C, Li M, Weidan C, Yanqin C, Xinxin C. Iatrogenic acute cardiac tamponade during percutaneous removal of a fractured peripherally inserted central catheter in a premature neonate. Heart & lung: the journal of critical care. 2015;44(6):517–520.
6. Garcia-Galiana E, Sanchis-Gil V, Martinez-Navarrete MA. [Cardiac tamponade after withdrawal of a peripheral access central catheter]. Rev Esp Anestesiol Reanim. 2015;62(3):157–160.
7. Barreiros LL, Andrade FM, Torres RA, Magalhaes LVB, Farnetano BDS, Fiorelli RKA. Cardiac tamponade by peripherally inserted central catheter in preterm infants: role of bedside ultrasonography and therapeutic approach. Rev Col Bras Cir. 2018;45(3):e1818.
8. Atmawidjaja RW, Azri M, Ismail IH. Cardiac tamponade: a rare but preventable complication of central venous catheter in neonates. The Medical journal of Malaysia. 2016;71(3):147–148.
9. Nadroo AM, Glass RB, Lin J, Green RS, Holzman IR. Changes in upper extremity position cause migration of peripherally inserted central catheters in neonates. Pediatrics. 2002;110(1 Pt 1):131–136.
10. Pettit J. Assessment of infants with peripherally inserted central catheters: Part 1. Detecting the most frequently occurring complications. Advances in neonatal care: official journal of the National Association of Neonatal Nurses. 2002;2(6):304–315.
11. Yu Z, Gu Y, Zhang Y, Huang Y, Shen G, Hu X. The feasibility of peripherally inserted central catheters use for intermediate to long term infusion at a tertiary pediatric hospital: sixty cases report. Chin J Evid Based Padiatr. 2017;12(2):100–105.
12. Piper HG, de Silva NT, Amaral JG, Avitzur Y, Wales PW. Peripherally inserted central catheters for long-term parenteral nutrition in infants with intestinal failure. Journal of pediatric gastroenterology and nutrition. 2013;56(5):578–581.
13. Gibson C, Connolly BL, Moineddin R, Mahant S, Filipescu D, Amaral JG. Peripherally inserted central catheters: use at a tertiary care pediatric center. Journal of vascular and interventional radiology: JVIR. 2013;24(9):1323–1331.
14. Westergaard B, Classen V, Walther-Larsen S. Peripherally inserted central catheters in infants and children - indications, techniques, complications and clinical recommendations. Acta Anaesthesiol Scand. 2013;57(3):278–287.
15. Barrier A, Williams DJ, Connelly M, Creech CB. Frequency of peripherally inserted central catheter complications in children. The Pediatric infectious disease journal. 2012;31(5):519–521.
16. Thiagarajan RR, Ramamoorthy C, Gettmann T, Bratton SL. Survey of the use of peripherally inserted central venous catheters in children. Pediatrics. 1997;99(2):E4.
17. Levy I, Bendet M, Samra Z, Shalit I, Katz J. Infectious complications of peripherally inserted central venous catheters in children. The Pediatric infectious disease journal. 2010;29(5):426–429.

18. Flores Moreno M, Pueblas Bedoy KS, Ojeda Sanchez A, Zurita-Cruz J. [Risk factors associated with complications that required the removal of peripherally inserted central venous catheters in a tertiary pediatric hospital]. Boletin medico del Hospital Infantil de Mexico. 2017;74(4):289–294.
19. De Carvalho BR, Eagar GM. Immediate post-insertion tip migration of peripherally inserted central catheters dependent on arm position and depth of inspiration. Journal of medical imaging and radiation oncology. 2018;62(3):324–329.
20. Spencer TR. Repositioning of central venous access devices using a high-flow flush technique - a clinical practice and cost review. The journal of vascular access. 2017;18(5):419–425.
21. Gebauer B, Teichgraber UK, Podrabsky P, Werk M, Hanninen EL, Felix R. Radiological interventions for correction of central venous port catheter migrations. Cardiovascular and interventional radiology. 2007;30(4):668–674.
22. Isemann B, Sorrels R, Akinbi H. Effect of heparin and other factors associated with complications of peripherally inserted central venous catheters in neonates. Journal of perinatology: official journal of the California Perinatal Association. 2012;32(11):856–860.
23. Costa P, Kimura AF, Brandon DH, Paiva ED, de Camargo PP. The development of a risk score for unplanned removal of peripherally inserted central catheter in newborns. Revista latino-americana de enfermagem. 2015;23(3):475–482.
24. Rastogi S, Bhutada A, Sahni R, Berdon WE, Wung JT. Spontaneous correction of the malpositioned percutaneous central venous line in infants. Pediatric radiology. 1998;28(9):694–696.
25. Ling Q, Chen H, Tang M, Qu Y, Tang B. Accuracy and Safety Study of Intracavitary Electrocardiographic Guidance for Peripherally Inserted Central Catheter Placement in Neonates. The Journal of perinatal & neonatal nursing. 2019;33(1):89–95.

# Figures

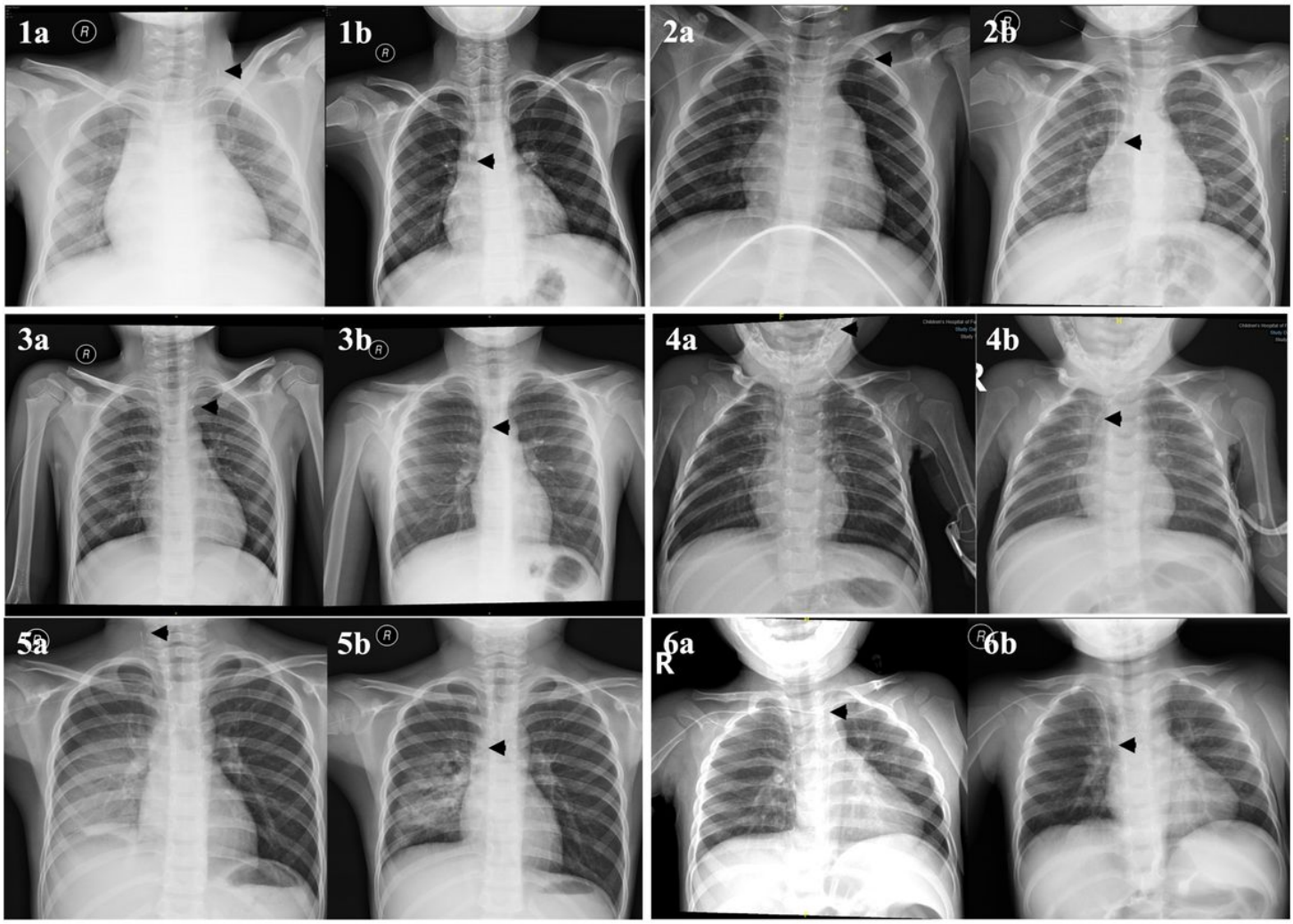


**Figure 1**

X-ray images of PICC before(a) and after arm movements(b). 1a/1b, 13-year boy, right basilic vein insertion, 4.0 Fr catheter, the tip was in the right jugular vein before arm movements. 2a/2b, 6-year girl, right basilic vein insertion, 4.0 Fr catheter, the tip was in the left subclavian vein before arm movements. 3a/3b, 5-year boy, right cephalic vein insertion, 4.0 Fr catheter, the tip was in the left subclavian vein before arm movements. 4a/4b, 5-month boy, left axillary vein insertion, 1.9Fr catheter, the tip was in the left jugular vein before arm movements. 5a/5b, 7-year boy, right cephalic vein insertion, 3.0 Fr catheter, the tip was in the right jugular vein before arm movements. 6a/6b, 20-month boy, right basilic vein insertion, 3.0 Fr catheter, the tip was in the left brachiocephalic vein before arm movements. Tips of all PICCs were in superior vena cava after arm movements.