Quantitative study of vertebral body changes in ovariectomized rats by spectral CT combined with DXA

Xingman Guo
The Second Affiliated Hospital of Shandong First Medical University
Yan Shao
The Second Affiliated Hospital of Shandong First Medical University
Xiyue Yu
Xinjiang Medical University, Xinjiang Uygur Autonomous Region
Qianqian Yao
The Second Affiliated Hospital of Shandong First Medical University
Huafang Chen
The Second Affiliated Hospital of Shandong First Medical University
Jian Qin (sdqinjian@126.com)
The Second Affiliated Hospital of Shandong First Medical University

Research Article

Keywords: Spectral CT, DXA, ovariectomized rats, postmenopausal osteoporosis

Posted Date: May 10th, 2022

DOI: https://doi.org/10.21203/rs.3.rs-1630636/v1

Abstract

Background: With the application of material decomposition and monoenergetic imaging reconstruction technology of spectral CT in the musculoskeletal system, the purpose of this study was to explore the quantitative changes of L5 vertebral body in ovariectomized rats by spectral CT Gemstone Spectral Imaging (GSI) and dual energy X-ray absorption (DXA).

Methods: Spectral CT GSI and DXA scans of the forty rats were conducted at 0 (baseline), 4, 8 and 12 weeks after operation. Hydroxyapatite (HAP)/fat value, 74KeV monoenergetic CT value and bone mineral density (BMD) of L5 vertebral body were measured. After excessive anesthesia, L5 vertebral body was taken for histological observation.

Results: There was significant difference in HAP(fat) value between groups at 4, 8 and 12 weeks after operation ($P<0.05$), and the significant difference in 74KeV monoenergetic CT value and BMD at 8 and 12 weeks after operation ($P<0.05$). There was also a positive correlation between 74KeV monoenergetic CT value and BMD of L5 vertebral body in OVX group. From 4 weeks after operation, the L5 of the OVX group showed sparse loss of the trabecular interconnectivity, thinning of the trabeculae and widened intertrabecular spaces.

Conclusion: Spectral CT material decomposition technology can be used to detect the bone state of vertebral body in the early stage of estrogen deficiency and has the better sensitivity than the BMD.

Introduction

Osteoporosis is a chronic metabolic skeletal disorder, which is characterised by decline of bone mineral density (BMD) and destruction of bone microstructure [1]. Osteoporosis more frequently occurs in females than males. Moreover, Post-menopausal women more commonly suffer from this systemic skeletal disease compared to premenopausal women, and the incidence of this disease has increased considerably in the past few years [2]. The mainly reason is that lacking of estrogen level in postmenopausal women leads to postmenopausal osteoporosis (PMOP) which is characterized by progressive bone loss, increased bone fragility and risk of fracture. In addition, this change has been proved occur in trabecular bone firstly [3]. At present, DXA is the "gold standard" for the diagnosis of osteoporosis in clinical and the BMD is an important index to measure bone mass because the decrease of it is directly related to osteoporosis [4, 5]. In recent years, many applications of spectral CT are used to improve the diagnosis and treatment of some diseases, and also play an increasingly important role in the musculoskeletal system [6]. As far as we know, few scholars have reported the early bone state of postmenopausal osteoporosis by spectral CT.

Therefore, this study was to use spectral CT and DXA to conduct a comprehensive analysis of the short-term effects of estrogen deficiency on the BMD and the substance content in the lumbar vertebra of ovariectomized (OVX) rats model. Our aim is to study the diagnostic value of spectral CT in PMOP and provide new ideas for the early detection and diagnosis of PMOP.

Materials And Methods

1.1 Animal Model

Forty female Sprague dawley rats (12-week-old, specific-pathogen-free grade) were purchased from the weitonglihua Experimental Animal Technology Co., Ltd. (Beijing, China). Then they were assigned randomly to group for either bilaterally ovariectomy (n=20) and group which was only performed abdominal incision without ovariectomy (Sham group, n=20). The animals were maintained under standard conditions (relative humidity = 50–60%; ambient temperature = 20 ± 2 °C; 12h light/dark cycle) with free access to water and food, and allowed to acclimate for 1 week. At 0 (baseline), 4, 8 and 12 weeks after operation, 5 rats in each group were randomly selected for spectral CT Gemstone Spectral Imaging (GSI) and dual energy X-ray absorption (DXA) scanning under anesthesia (3ml of Urethane intraperitoneal injection, Shanghai Shanpu Chemical Co.,Ltd). Excessive anesthesia after examination, the fifth lumbar vertebra (L5) was separated and taken for pathological observation. All animal experiments were approved by the Committee of animal management and use institutions of Shandong First Medical University and carried out in accordance with the guidelines for the use of experimental animals of the National Institutes of Health. This study is reported in accordance with ARRIVE guidelines.

1.2 GSI Protocol and Analysis

At baseline, 4, 8 and 12 weeks after ovariectomy, all rats were taken from prone position for lumbar vertebra GSI scanning (GE Revolution CT, America) after anesthesia. Specific parameters: tube voltage 80-140KV, tube current 400mA, layer thickness 0.625mm, Stnd reconstruction mode and ASIR 30%. When scanning was finished, transfer the original data to AW4.6 workstation and select the Volume Viewer. Then measure the Hydroxyapatite (HAP)/fat value (mg/cm^3) and 74KeV monoenergetic CT value (HU) of cancellous bone in the sagittal middle layer of L5 vertebral body in sagittal position (place the cursor on the central line of L5 vertebral body in coronal position as far as possible, meanwhile the sagittal position automatically corresponds to the middle plane). Due to the small vertebral body of rats, in order to avoid overlapping with bone cortex and ensure the accuracy of region of interest (ROI), as shown in Fig. 1, ROI is divided into two parts with a total size of about 5.0mm^2. Two experienced radiologists measured it respectively for three times and took the average value to get the final results.

1.3 Measurement of BMD

The BMD (unit, g/cm^2) of the L5 vertebral body was measured at baseline, 4, 8 and 12 weeks post-OVX surgery by DXA (Primus, osteosys Co.,Ltd.) under anesthesia. The rats were placed in the prone position on the DXA scanning table according to the instructions. As shown in Fig. 2, the ROI was analyzed with its own software.

1.4 Histological analysis

The L5 vertebral body was decalcified, dehydrated and embedded in paraffin prior to processing. Then the 5μm tissue sections were stained with hematoxylin and eosin (H&E) staining. As shown in Fig. 3, images of the L5 vertebral body sections were captured using the microscope (20X) equipped with a camera to observe the morphological structure of trabecular bone.

1.5 Statistical analysis

All results were presented as means ± standard deviation (SD) and N represents the number of animals in each group. Pearson correlation analysis was performed on HAP(fat) value, 74KeV monoenergetic CT value and BMD of L5 vertebral body in OVX group by the statistical software SPSS V22.0 (IBM, Armonk, NY, USA). The comparison between groups and intra groups were carried out by one-way ANOVA with subsequent LSD post-hoc test. $P<0.05$ were considered statistically signifificant.

Results

2.1 HAP(fat) Value

Table. 1 showed that HAP(fat) value results of L5 vertebral body in different periods of two groups of rats. The HAP(fat) value of rats in sham group showed a time-course increasing trend, whereas the OVX group demonstrated an decreasing trend ($P<0.05$).

At 4, 8 and 12 weeks post-OVX surgery, the HAP(fat) value of the OVX group was lower than that of the sham group ($P<0.05$).

2.2 74KeV Monoenergetic CT Value

Table. 2 showed that the 74KeV monoenergetic CT value results of L5 vertebral body in different periods of two groups of rats. With the passage of time, the 74KeV monoenergetic CT value of the OVX group decreased, and the intra group difference was statistically significant ($P<0.05$). At 4, 8 and 12 weeks post-OVX surgery, the 74KeV monoenergetic CT value of the OVX group was lower than the sham group, however there was significant differences only at 8 and 12 weeks after operation ($P<0.05$).

2.3 BMD

Table. 3 showed that the BMD results of L5 vertebral body in different periods of two groups of rats. Over time, the BMD of OVX group decreased significantly ($P<0.05$). However, there was no significant change in BMD of L5 vertebral body in the sham group ($P>0.05$). At 4, 8 and 12 weeks post-OVX surgery, the BMD of the OVX group was lower than that of the sham group, but the significant difference between the groups only at 8 and 12 weeks after operation ($P<0.05$).

2.4 Pearson correlation analysis

In OVX group, only 74KeV monoenergetic CT value was positively correlated with BMD that the correlation coefficient was 0.456. The results are shown in Table 4.

2.5 Histopathological findings

All H&E-stained sections from different groups at different times were comparatively evaluated histologically (Fig.3). Normal compactness of the vertebral body and competent trabeculae were found in the sham group. From 4 weeks after operation, The L5 micrographs of the OVX group showed sparse loss of the trabecular interconnectivity and thinning of the trabeculae, resulting in widened intertrabecular spaces.

Discussion

Osteoporosis is a clinical and public health problem related to the bone health of the elderly closely. Due to the sudden decline of estrogen level in postmenopausal women, the rate of bone loss also increases [7]. It is now believed that ovariectomy female rats are widely used animal model for the study of estrogen defificient-induced osteoporosis [8]. At present, DXA is a commonly used tool for screening osteoporosis in clinic. In fact, osteoporosis is not only characterized by the reduction of bone mineral content, but also the destruction of bone microstructure. Therefore, it is one-sided to diagnose osteoporosis only by bone mass. DXA is a two-dimensional imaging, which can not distinguish between cortical bone and cancellous bone. When there are spinal fractures, calcification of blood vessels or ligaments and hyperosteogeny, it is easy to cause false negative results [9, 10]. In contrast, spectral CT uses the principle that tissues and materials have different attenuation characteristics at different energy levels to obtain CT attenuation data at different energy levels, and the results are more accurate [11, 12]. In this study, 12-week-old female rats were selected for ovariectomy. No changes such as vertebral hyperosteogeny were observed at 12 weeks after operation under 20 times microscope. Therefore, BMD in this experiment still has high accuracy. In addition, there was no significant difference in BMD in the sham group, indicating that the bones of normal female rats aged 12–24 weeks were mature and stable, and there was no significant change in bone mass.

Spectral CT is equivalent to a base material pair composed of two base materials according to the absorption and attenuation of X-ray by the material. When the base material pair happens to be the two main components contained in the tissue, measuring the base material can reflect the relative content of the material in the tissue [12]. The main components of vertebral body include bone mineral (HAP / calcium), water, red bone marrow, yellow bone marrow and collagen. According to Li X [13], HAP(water) based material pairs can accurately measure bone mineral density, and the deviation is less than QCT. Yue D [14] reported that the spectral CT Cal (water) value of adult female lumbar spine was significantly positively correlated with BMD. When osteoporosis occurs, the fat content in the vertebral body increases significantly and the HAP content decreases [5]. Therefore, the HAP(fat) value is selected to represent the vertebral bone mineral density in this experiment. In our study, HAP(fat) value changed first than the other two indexes. At 4 weeks after operation, the differences between the two groups was statistically significant, which was more consistent with the observation under pathological microscope.

The virtual monoenergetic image generated by spectral CT using linear mixing technology can simulate the attenuation of monoenergetic X-Ray to the tissue and reconstruct the monoenergetic image in the range of 40-140KeV. For instance, Ishiwata[15] used 70KeV monoenergetic level to indirectly represent the conventional CT value (HU) when studying the diagnostic accuracy of spectral CT for bone metastasis. In addition, spectral CT shows the best arthrography at 72KeV monoenergetic level [12]. Generally, 74KeV monoenergetic image is similar to 120Kvp conventional CT imaging and can be used as an alternative to the latter. Our study results showed that the differences of 74KeV monoenergetic CT value and BMD between groups were statistically significant at 8 and 12 weeks after operation. Besides, it is worth noting that the HAP(fat) value, 74KeV monoenergetic CT value and BMD of the OVX group were higher than those of the sham group at baseline, although the difference between the groups was not statistically significant. However, it is still necessary to further explore the changes of various tissue components of the vertebral body within 4 weeks after ovariectomy.

Some limitations of this study need to be mentioned. First, compared with human spine, the volume of rat vertebral body is small and in order to avoid the influence of bone cortex and surrounding structures, the size of ROI when measuring HAP(fat) value and 74KeV monoenergetic CT value is limited. In addition, in the early stage of osteoporosis, the proportion of various material components in the vertebral body will change. Only measuring the HAP(fat) value may not be enough to reflect the overall BMD. The correlation analysis should also be carried out in combination with HAP(water), Cal(fat) and other base material pairs.

Conclusion

Taken together, in the early stage of ovariectomy in female rats, spectral CT HAP(fat) based material pairs has the better sensitivity than the BMD, which can accurately reflect the changes of vertebral bone mass, and provide a new basis for the application of spectral CT in clinical osteoporosis as soon as possible.

Abbreviations

BMD Bone mineral density

PMOP Postmenopausal osteoporosis

OVX Ovariectomy

GSI Gemstone spectral imaging

HAP Hydroxyapatite

DXA Dual energy X-ray absorption

ROI Region of interest

H&E Hematoxylin and eosin

Declarations

Funding:

The present study was supported by grants from the Academic promotion programme of Shandong First Medical University (No. 2019QL017), Taian science and technology development plan project (No.2020NS246), Taian science and technology development plan project (No.2021NS254).

Conflicts of interest/Competing interests:

Not applicable.

Availability of data and material:

The datasets generated during the current study are not publicly available due our research is still ongoing but they are available from the corresponding author on reasonable request.

Ethics approval:

The study was approved by the Committee of animal management and use institutions of Shandong First Medical University and carried out in accordance with the guidelines for the use of experimental animals of the National Institutes of health. This study is reported in accordance with ARRIVE guidelines.

Code availability:

Not applicable.

Authors' contributions:

Xingman Guo: Writing-Original draft preparation, Methodology

Yan Shao: Software, Data curation

Xiyue Yu:Visualization, Software

Qianqian Yao: Formal analysis, Visualization

Huafang Chen: Data curation, Formal analysis

Jian Qin: Supervision, Resources, Writing- Reviewing and Editing

All authors reviewed the manuscript.

Acknowledgements:

The present study was supported by grants from the Academic promotion programme of Shandong First Medical University (No. 2019QL017), Taian science and technology development plan project(No.2020NS246), Taian science and technology development plan project (No.2021NS254).

References

1. Shevroja E, Cafarelli FP, Guglielmi G, *et al*. DXA parameters, Trabecular Bone Score (TBS) and Bone Mineral Density (BMD), in fracture risk prediction in endocrine-mediated secondary osteoporosis[J]. Endocrine, 2021, 74(1): 20-28.
2. Daly RM, Dalla Via J, Duckham RL, et al. Exercise for the prevention of osteoporosis in postmenopausal women: an evidence-based guide to the optimal prescription[J]. Braz J Phys Ther. 2019;23(2):170-180.
3. Mosekilde L, Danielsen CC, Knudsen UB. The effect of aging and ovariectomy on the vertebral bone mass and biomechanical properties of mature rats[J]. Bone. 1993;14(1):1-6.
4. Zhou S, Zhu L, You T, et al. In vivo quantification of bone mineral density of lumbar vertebrae using fast kVp switching dual-energy CT: correlation with quantitative computed tomography[J]. Quant Imaging Med Surg. 2021;11(1):341-350.
5. Hoffman CM, Han J, Calvi LM. Impact of aging on bone, marrow and their interactions[J]. Bone. 2019;119:1-7.
6. CAROTTI M, SALAFFI F, BECI G, et al. The application of dual-energy computed tomography in the diagnosis of musculoskeletal disorders: A review of current concepts and applications[J]. La Radiologia Medica, 2019, 124(11): 1175-1183.
7. Shang Q, Zhao W, Shen G, et al. Jingui Shenqi Pills Regulate Bone-Fat Balance in Murine Ovariectomy-Induced Osteoporosis with Kidney Yang Deficiency[J]. Evid Based Complement Alternat Med. 2020;2020:1517596.
8. Xu H, Liu T, Hu L, et al. Effect of caffeine on ovariectomy-induced osteoporosis in rats[J]. Biomed Pharmacother. 2019;112:108650.
9. Amstrup AK, Jakobsen NF, Moser E, Sikjaer T, Mosekilde L, Rejnmark L. Association between bone indices assessed by DXA, HR-pQCT and QCT scans in post-menopausal women[J]. J Bone Miner Metab. 2016;34(6):638-645.
10. Woisetschläger M, Spångeus A. Model for improved correlation of BMD values between abdominal routine Dual energy CT data and DXA scans[J]. Eur J Radiol. 2018;99:76-81.
11. Chellini D, Kinman K. Dual-Energy CT Principles and Applications[J]. Radiol Technol. 2020;91(6):561CT-576CT.
12. Rajiah P, Sundaram M, Subhas N. Dual-Energy CT in Musculoskeletal Imaging: What Is the Role Beyond Gout?[J]. AJR Am J Roentgenol. 2019;213(3):493-505.
13. Li X, Li X, Li J, et al. The accuracy of bone mineral density measurement using dual-energy spectral CT and quantitative CT: a comparative phantom study. Clin Radiol. 2020;75(4):320.e9-320.e15.

14. Yue D, Li Fei S, Jing C, et al. The relationship between calcium (water) density and age distribution in adult women with spectral CT: initial result compared to bone mineral density by dual-energy X-ray absorptiometry. Acta Radiol. 2019;60(6):762-768.
15. Ishiwata Y, Hieda Y, Kaki S, et al. Improved Diagnostic Accuracy of Bone Metastasis Detection by Water-HAP Associated to Non-contrast CT[J]. Diagnostics (Basel). 2020;10(10):853.

Tables

Table. 1

Results and comparison of HAP(fat) value (mg/cm^3) of L5 vertebral body in two groups

Week age	OVX Group（n=5）	SHAM Group（n=5）	*P*
baseline	613.70±43.20	573.50±33.38	0.144
4 weeks	533.70±51.01	608.72±49.44	0.009
8 weeks	563.90±51.02	662.38±41.22	0.001
12 weeks	540.28±23.73	648.98±39.19	<0.001
P	0.042	0.014	

Data are presented as mean±SD.

Table. 2

Results and comparison of 74KeV monoenergetic CT value (HU) of L5 vertebral body in two groups

Week age	OVX Group（n=5）	SHAM Group（n=5）	*P*
baseline	742.14±95.52	706.14±41.31	0.511
4 weeks	670.48±55.50	771.48±94.92	0.071
8 weeks	572.78±78.33	748.58±93.52	0.003
12 weeks	650.04±62.95	777.96±129.57	0.024
P	0.020	0.635	

Data are presented as mean±SD.

Table. 3

Results and comparison of BMD (g/cm^2) of L5 vertebral body in two groups

Week age	OVX Group（n=5）	SHAM Group（n=5）	*P*
baseline	0.23±0.02	0.21±0.02	0.252
4 weeks	0.24±0.03	0.26±0.02	0.134
8 weeks	0.18±0.01	0.23±0.02	0.004
12 weeks	0.17±0.01	0.22±0.02	0.001
P	<0.001	0.077	

Data are presented as mean±SD.

Table.4

Results of the correlation among indexes in OVX group

	HAP(fat)	74KeV monoenergetic CT	BMD
HAP(fat)	1	0.343	0.328
74KeV monoenergetic CT	0.343	1	0.456*

*indicates *P*<0.05.

Figures

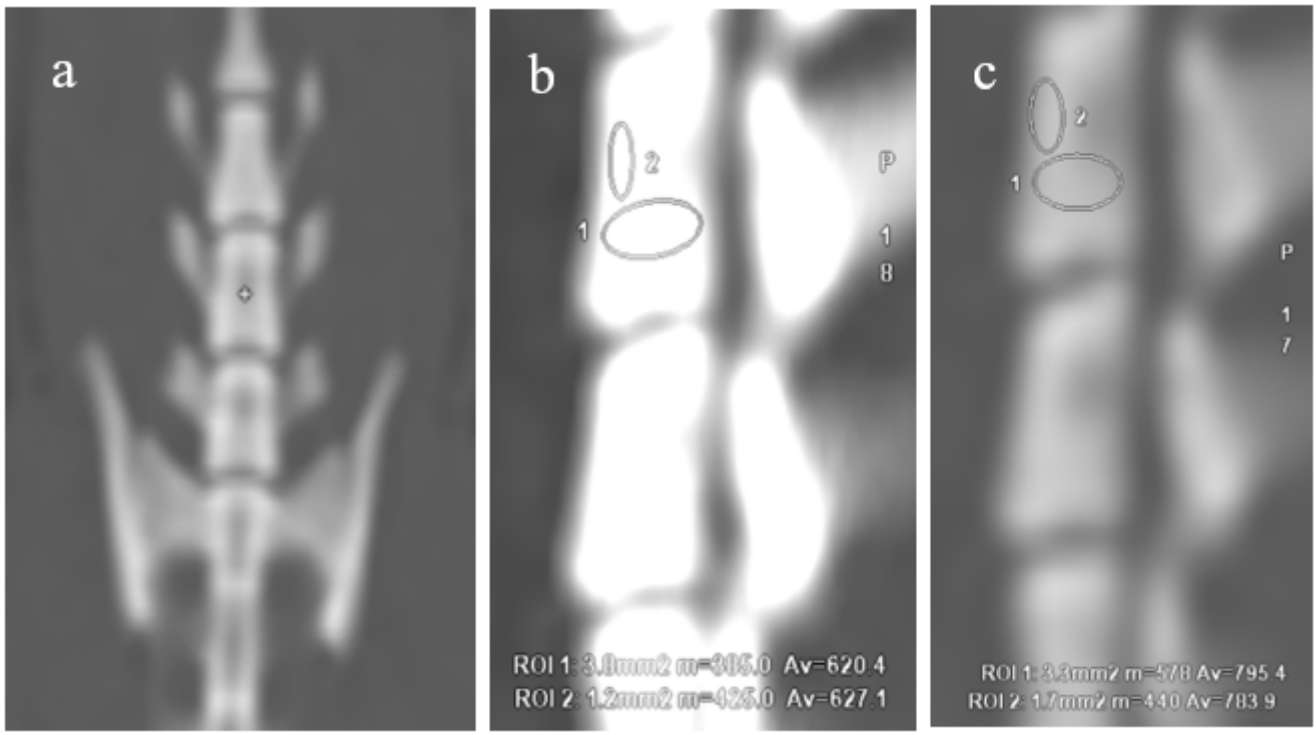

Figure 1

Spectral CT GSI coronal image of L5 vertebral body in rats at 12 weeks after OVX (a), the sagittal images of L5 HAP(fat) (b) and the 74KeV monoenergetic (c). The total ROI is about 5.0mm^2.

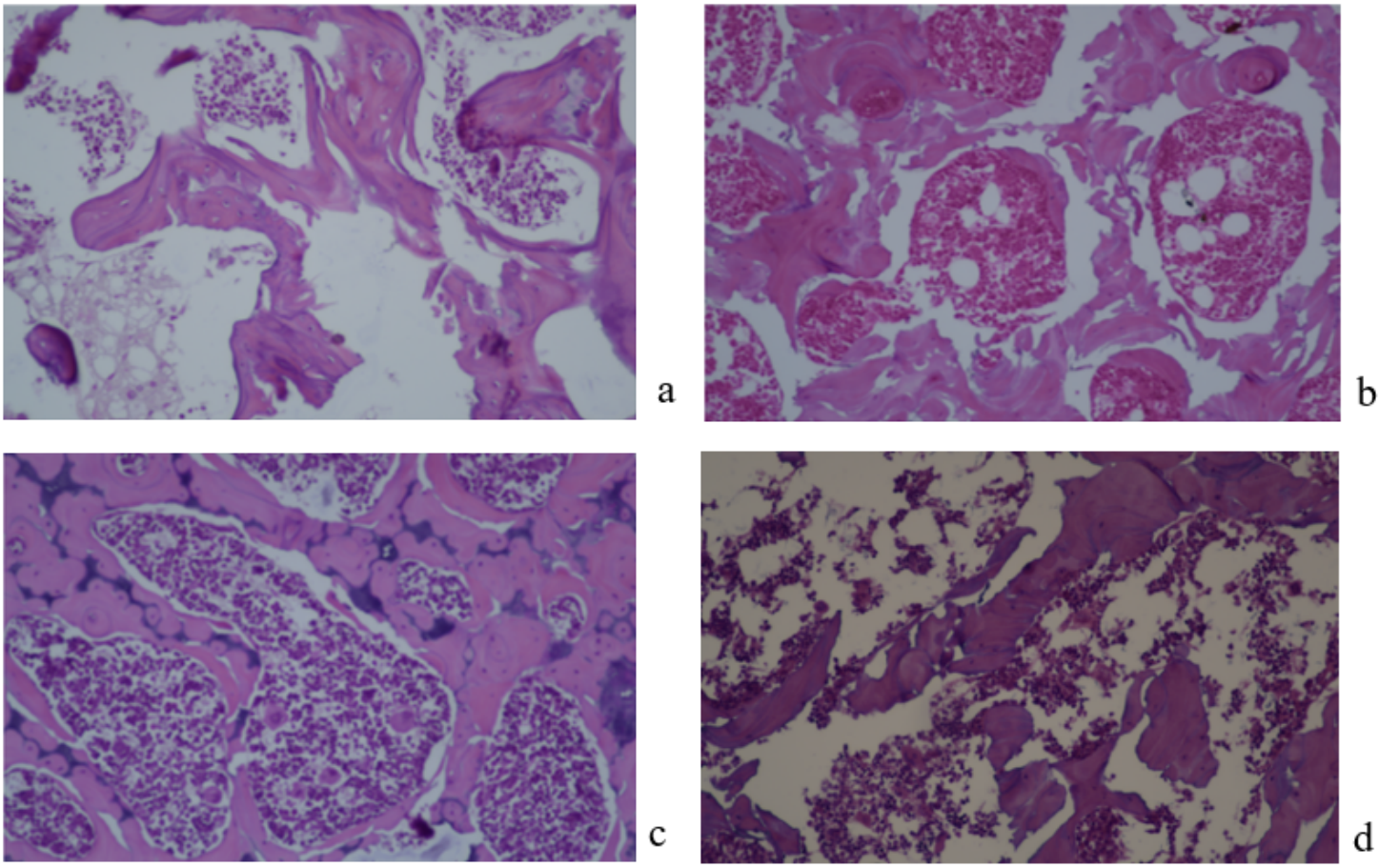

Figure 2

Measured the L5 vertebral body BMD in sham group and OVX group, with the unit of g/cm^2. The ROI is the entire L5 vertebral body.

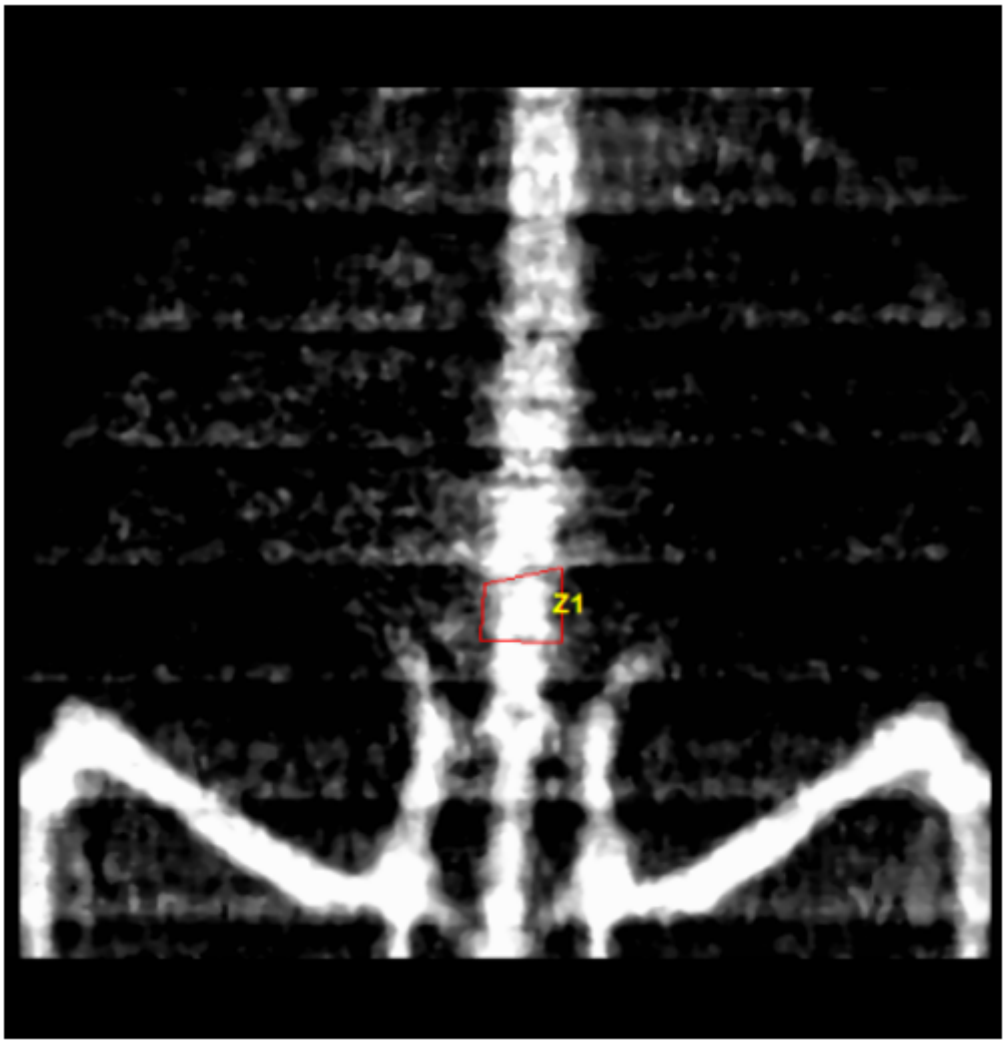

Figure 3

Effects of estrogen deficiency on bone microarchitecture in rats. The microarchitectures of the L5 trabecular bones were detected by H&E staining. Representative images are displayed, baseline(a), 4 weeks(b), 8 weeks(c), 12 weeks(d), and the magnification was ×20. Trabecular bones have been changed since 4 weeks after operation.