Facial nerve monitoring in parotid gland surgery: Design and feasibility assessment of a potential standardized technique

Carlos S Duque (casiduque@hotmail.com)
Hospital Pablo Tobon Uribe

Andres F Londoño
Hospital Pablo Tobon Uribe

Ana M Duque
Clinica Orlant

John J Zuleta
Hospital Pablo Tobon Uribe

Marcela Marulanda
University of Antioquia

Lina M Otalvaro
Clinica Orlant

Miguel Agudelo
Newark Beth Israel Medical Center

Juan P Dueñas
Clinica El Rosario El Tesoro

Maria F Palacio
Clinica Las Americas- Auna

Gianlorenzo Dionigi
Istituto Auxologico Italiano

Research Article

Keywords: Parotid Gland, Facial Nerve, nerve monitoring, intraoperative neural monitoring, loss of signal, latency, amplitude

Posted Date: May 18th, 2022

DOI: https://doi.org/10.21203/rs.3.rs-1631358/v1

Abstract

Introduction

Even though the use of nerve monitoring during parotid gland surgery is not the gold standard to prevent damage to the nerve, it surely offers some advantages over the traditional approach. Different from thyroid surgery, where a series of steps in intraoperative nerve monitoring have been described in order to confirm not only the integrity but – most importantly – the function of the recurrent laryngeal nerve, in parotid gland surgery, a formal guideline to follow while dissecting the facial nerve has yet to be described.

Methods

A five-year retrospective study was done reviewing the intraoperative records of patients who underwent parotid gland surgery under neural monitoring. The operative findings regarding the neuromonitoring process, particularly in regard to the amplitude of two main branches, were revised. A literature search was done in order to search for guidelines to follow when a facial nerve loss of signal is encountered.

Results

Fifty-six patients were operated on using the Nim 3 Nerve Monitoring System (Medtronic, Jacksonville, FL USA); thirty-three were female patients, 46 patients had benign lesions. Minimum changes were observed in the amplitude records after a comparison was made between the first and the last stimulation. There were only three articles discussing the term loss of signal during parotid gland surgery.

Conclusion

Today, no sufficient attention has been given to facial nerve monitoring process during parotidectomy. This study proposes and discusses a formal guideline to follow during this procedure in order to develop a uniform technique of facial nerve stimulation.

Introduction

Parotid gland surgery entails not only the removal of the tumor but, especially, the preservation of the facial nerve (FN) function, to avoid its most-feared complication, facial paralysis. A surgeon performing parotidectomies must follow a series of classical steps and anatomical landmarks to identify and preserve the main trunk of the nerve and its branches. Intraoperative nerve monitoring (IONM) is not a requirement to perform parotid gland surgery; however, this technology provides the surgeon with a tool that not only allows for faster localization of the nerve, but also provides information about its function. [1–9]

Since 2011, several publications have delineated a series of guidelines and recommendations that must be observed by all thyroid surgeons using nerve monitoring to identify and preserve the integrity and

function of the recurrent laryngeal nerve. There is no doubt that thyroidectomies are performed more than parotidectomies; nevertheless, the devastating effects of a facial nerve injury certainly deserves more dedication and research. Up to the present time, various articles have been published describing – and even denying – the benefits of the use of intraoperative nerve monitoring during a formal parotidectomy, in order to preserve the function of the facial nerve. However, although some interesting descriptions have been made, only one recent publication by Kartush JM et al. (2021) makes an approximation daring to describe a formal guideline to facial nerve stimulation-nomenclature. [10–23]

A retrospective revision and analysis of a series of parotidectomies performed under IONM was done in order to describe our experience with the technology, proposing an eventual guide to be followed by surgeons involved in parotid gland surgery under nerve monitoring.

Methods

A retrospective research proposal was submitted to and approved by the Internal Research Committee of the *Hospital Pablo Tobón Uribe* and *Clínica ORLANT* in Medellín, Colombia. The intraoperative records of patients in whom a parotidectomy under neuromonitoring was performed between February 2013 through November 2017 were reviewed. Patients less than 18 years old, those who had prior parotid gland surgery or a parotid tumor causing facial paralysis were excluded. One of the purposes of the study was focused on the findings of the intraoperative nerve responses during the intervention. Pre- and post-dissection electromyographic Amplitude (energy in microvolts, μV) responses upon stimulation recorded throughout the entire procedure were reviewed; the latency numbers for these branches were not considered, as they were incomplete. The Medtronic Nim 3 Nerve Stimulator System (Jacksonville, FL USA) was used in all cases. At the time of surgery, all patients consented to having their parotidectomy done under IONM. Another delineated objective of the investigation was to do a 15-year (2006–2021) literature search and review of Pubmed, Google Scholar, Scopus databases to collect articles containing information regarding the action that a parotid gland surgeon must take if a loss of signal is observed during the facial nerve dissection while performing a parotidectomy. Combinations of terms, such as *facial nerve monitoring* or *neuromonitoring*, *stimulation and/or loss of signal (LOS)*, *parotidectomy and/or parotid gland surgery*, LOS, were used.

Results

During the five-year period of this study, fifty-six patients were operated; 33 (55%) were females and the age range was 25 to 82 years with an average of 50 years. Forty-six (76%) patients were operated due to benign tumors; 30 (65%) pleomorphic adenomas; followed by 12 (21.4%) patients with Warthin's tumors and four (7.14%) had inflammatory conditions; 10 (17.85%) patients were diagnosed with malignant lesions, low- and intermediate-mucoepidermoid carcinomas. All patients were discharged the following day and a post-operative appointment was schedule a week later to review the patient's status and pathology report. Table 1 describes the Amplitude findings of all parotidectomies done under nerve monitoring; we chose to present the data using the median with its 25th and 75th percentiles for the

branches described later on. Along with a low-amplitude response in the final stimulation process, compared to the initial response of the inferior branches that was reflected clinically in five (8.9%) of the patients who presented a temporary marginal – mandibular – paresis that recovered completely within three to four weeks, transitory, two-week Frontalis-branch paresis was seen in one patient (1.7%). There were only three authors (Guntinas-Lichius O et al. Ozturk K et all and Kartush JM,et al) found that briefly mentioned the term *loss of signal* for the facial nerve but without entering into in a deeper and enlightened discussion.

Table 1 Pre- and post-resection amplitude measurements

BRANCH	Pre-Frontalis	Post-Frontalis	Pre-Mentalis	Post-Mentalis
	Median (Percentile 25 – Percentile 75)			
AMPLITUDE Microvolts-µV	660.5 (297 – 1216)	887 (326 – 1982.5)	748 (439.5–972.5)	887 (326.5–1932.5)

Discussion

The classical approach to parotid gland surgery was described more than one hundred years ago; it entails the identification and preservation of the facial nerve, and this technique should not change, regardless of whether the surgeon is using nerve monitoring or not. [1, 2]

Table 2 depicts a series of similarities and disparities between the recurrent laryngeal and facial nerve monitoring process. The recurrent laryngeal nerve (RLN) is a branch of the Vagus nerve, though the nerve might also divide itself into at least two or more sensitive ramifications. The facial nerve is a terminal nerve; as the nerve exits through the stylomastoid foramen, it gives origin to motor and sensory branches (posterior belly of digastric, stylohyoid, superior auricular, etc.) continued by the main trunk (MT) dividing shortly into a Temporozigomatic or superior branch (SB) and a Cervicofacial branch or inferior branch (IB), which – at the same time – divides into several tiny motor ramifications as they travel in an external to a medial fashion to innervate the facial musculature. [22–29]

Table 2 Similarities and disparities between Recurrent Laryngeal Nerve (Thyroid) and Facial Nerve (Parotid) surgery done under Intraoperative nerve monitoring

Fact	Thyroidectomy Recurrent Laryngeal Nerve (RLN)	Parotidectomy Facial nerve
Is IONM the standard of care?	No, visual identification[24]	No, visual identification, [1, 17]
Muscle relaxant	Only at the beginning of the procedure	Only at the beginning of the procedure
Endotracheal tube (ET) with electrodes	Two electrodes incorporated into the tube or attached to a conventional tube by a sticker containing the electrodes	No need for a special tube. Four electrodes are used: Frontal, Orbicularis Oculi, Orbicularis Oris and Mentalis
Continuous monitoring	Yes, or Intermittent [12,13]	Although described, not the usual; intermittent [21]
Principal motor branches	The most anterior, near the trachea [25]	All of the branches
Anastomosis between other neural systems or branches	Yes, to the Superior Laryngeal nerve [26–28]	Yes, to the Glossopharyngeal nerve or within different ramifications itself [29–31]
Number of ramifications	From one to four extra-laryngeal ramifications [25–28]	Two main trunks that divide into various branches and subsequently subdivide distally into tiny terminal ramifications [29–31]
Blind nerve search – mapping- allows from prompt identification of the nerve	Yes	Yes
Bilateral nerve dissection during a total thyroidectomy	Right and left nerves	Not usual for a patient to have a bilateral parotidectomy at the same surgical setting
Injury to one nerve warns or precludes dissecting the contralateral side; surgery might be ended.	Yes. Each case needs to be studied, but this is certainly a possibility [10, 11,13–14]	No. A different scenario: if a nerve branch is affected or even if the main trunk is damaged, the surgery must be completed.

The neuro- monitoring technology must be seen as an aid to try to ensure that no nerve damage will be caused and to allow for an early identification of a potential nerve injury at any time during the surgical process. Regarding the mechanism of injury to the facial nerve, similar to what has been described for the Vagus or RLN, lesions can be classified as general or diffuse; for example, accidentally traumatizing the main trunk by heat, section, pressing, etc., causing a complete face paralysis and loss of signal, or just punctually referring to a specific anatomical site where a particular nerve branch was affected. Even though there is no doubt that the technology certainly helps to expedite and look out for the nerve in high-volume lesions – tumors – it surely speeds up the process of finding the facial nerve main trunk. [8–12]

Loss of Signal

It has been widely described that when there is trauma to the recurrent laryngeal nerve during a thyroidectomy done under IONM, changes – such as an increase in latency (time) and reduced amplitude (energy) that may worsen if the trauma continues – are noted on the monitor, constituting what has been named *loss of signal*. Even though the nerve might seem intact, in reality – and thanks to the information provided by the monitoring process – it is not functional. A consensus was agreed upon by many authors, that if – at some point during a total or hemithyroidectomy – a recurrent laryngeal nerve signal drops more than fifty percent of its original maximum stimulation data in its amplitude along with a prolongation of the latency time, the term “Loss of signal (LOS)” is applied. At this point there is still a chance that the nerve might recover, depending on the severity of the trauma. The surgeon should decide if – in the presence of such event – a proven loss of signal that does not improve in a prudent period of time (usually 20 to 25 minutes) and in the face of a scheduled total thyroidectomy, said procedure should be stopped and a completion thyroidectomy done at a later date, waiting for the nerve to recover within the coming weeks, while avoiding at that moment the potential risk of a tracheostomy if the contralateral lobe is indeed approached and the nerve is injured. Without a doubt, this is certainly one of the benefits that intraoperative nerve monitoring offers to both the surgeon and the patient nowadays. A quite surprising finding of the study was to realize that after exploring the research engines, three articles briefly refer to the process of facial nerve injury and amplitude and latency changes respectively; however, there is no clear instruction in any of the articles on what to do if a surgeon performing a classical superficial parotidectomy under nerve monitoring is faced with an intraoperative facial nerve loss of signal. [6, 20, 23]

Even though that there are significant differences in each process of stimulation of the recurrent laryngeal and the facial nerve, a precise directive to advise what action to take if the parotid gland surgeon is faced with a loss of signal has not yet been described. In our case and based on the analysis of the experience and the data described here, what we do nowadays – in the event that a particular branch has lost its signal, meaning that a considerable difference is encountered in the obtained numbers/nerve stimuli feedback comparing the initial response once the superior or inferior branches are dissected due to trauma – the surgeon must continue and finish the surgery dissecting the remaining branches. Not only does it seem like the logical thing to do, but also – even if the main trunk is injured at the beginning of the procedure and a dramatic drop in the facial nerve amplitude is observed along with a disturbing prolongation of the latency, which in our patients was not the case (Table 1) – the surgeon will complete the surgery removing the entire gland, avoiding, if possible, any further or severe manipulation of the nerve or its branches. Also, if severe monitoring changes are observed in the nerve pattern for a particular branch, the surgeon might “leave this ramification to rest for a while” and dissect the other branch, giving that ramification the potential chance to recover as has been described for the recurrent laryngeal nerve. Besides, different nerve branches might have a system of interconnecting anastomosis that may “overpass” that trauma area and continue to transmit the stimuli, preserving the harmony to the face. This retrospective study did not have the tools, nor the complete data, to answer the important

number to suggest at what point of the Amplitude reduction or the prolongation of the Latency, a surgeon should consider a true loss of signal during a facial nerve dissection. Undoubtedly, this will require a larger prospective study (Fig. 1). [30–32]

The Frontalis and Mentalis branches were chosen as the ones with more reliable information, representing the superior and inferior principal branches respectively, especially regarding the Amplitude as detailed in Table 1. In the complete information available, the data collected mostly showed an increase in the numbers obtained for the superior branches; for the marginal mandibular nerve post operative paresis, a slight decrease in the amplitude was noticed in five patients that had no permanent problem with their lower lip movement.

Our results prompted us to recognize, analyze and revise our strategy for every parotidectomy done under IONM in our department, proposing an initial guideline to follow, as shown in Table 3. It is worth stimulating the main trunk at the beginning of the procedure, observing, and saving the result of the four targeted muscle zones with their amplitude and latency responses in the monitor and comparing them to the following ones. If a surgeon wants to be more precise on the final integrity and functionality of the nerve, the feedback from the Superior and Inferior Branches or any particular branch might also be obtained if they were individually stimulated and saved early in the case. (Figs. 2 and 3)

Indeed, even though more prospective studies are needed, this is a lengthy process of building a guideline for facial nerve monitoring during parotid gland surgery that is not only accepted by most surgeons, but also offers practical and reliable information, thus ensuring the same protocol be used for each patient, just as it has been described and followed by thyroid surgeons with recurrent laryngeal nerve neuromonitoring. [10–14, 32]

Table 3 Proposed guideline to stimulate the facial nerve during a parotidectomy*

1. Preoperative: Inform the patient of the diagnosis and indication for surgery under intraoperative nerve monitoring. Do not present the technology as a warranty that the nerve will not be injured.
2. Anesthesia: Intubation with a short acting muscle relaxant; no other relaxation agents should be used throughout the procedure.
3. Four face electrodes (Frontalis, Orbicularis Oculi, Orbicularis Oris and Mentalis) are sub-dermally inserted in the face-targeted muscles, cleaning the area with alcohol swabs. Grounding and receiving electrodes are placed in the shoulder area. All six electrode ends are connected, matching the color to the provided receiving console that integrates all systems and transmits the electromyographic (EMG) response to the monitor.
4. Landmarks: After a classic approach is done, follow the known anatomical landmarks to find the facial main trunk. Once the tragal pointer is in view, use the nerve stimulator probe set at 1 to 1.5 milliamps (mA) to do “mapping” or a blind search for the main trunk; at this point, a general response of the nerve should be obtained, indicating the proximity of the nerve.
5. Main trunk: Once the trunk is identified, reduce the energy to 0.5 to 0.8 mA; dissect and follow the nerve up to the Pes Anserinus. Save a couple of responses of the main trunk stimulation process for a

subsequent end-of-procedure comparison. (Fig. 2)
6. Dissect and expose the Superior (SB – Temporozigomatic)) and Inferior (IB – Cervicofacial) branches. Stimulate and save branch responses at 0.5–0.8 mA. (Fig. 2)
7. From this point on, the nerve branches should be stimulated at 0.5 mA or with even less energy. Each branch response should be saved.

a. At any given time during the dissection, the surgeon can stimulate a branch if faced with a suspected trauma or dramatic change in the response. If, indeed, a reduced signal – or even a loss of signal is observed – he should try to identify and correct the cause; leave said branch to rest a while, dissecting the next ramification and coming back at a later time to see if it has recovered. Even though the nerve did not recover, the procedure should finish dissecting the affected branch as gently as possible.
8. Once the gland is removed, each dissected branch and main trunk is stimulated, saved, and compared with its initial response. The system will provide the surgeon with a PDF form to save. (Figs. 2 and 3)
*Using the Nim 3 Medtronic Nerve Stimulation System (Jacksonville, FL USA)

Conclusion

Without a doubt, the early analysis of the data allowed us to correct many aspects of the facial nerve stimulation process during our parotidectomies.

Even though there are no definitive guidelines to follow yet in parotid gland surgery and facial nerve preservation, as there are in thyroid surgery, this review will hopefully be followed by a prospective study that includes all four muscles systems in order to continue giving support to the use of the neuromonitoring experience in this procedure.

Declarations

Conflict of interest

Drs. CS Duque and JP Dueñas teach courses in Neuromonitoring techniques in head and neck surgery to surgeons in Latin America with the sponsorship of Medtronic and had been receiving honoraria from that activity

Dr. G Dioningi receives honorarium from Medtronic and Innomed.

The rest of the authors has no relation to any of the above, mentioned companies at all.

FUNDING

This publication was not funded by any private or public company or entity. None of the authors received any type of payment or compensation of any type, by authoring the article.

AUTHOR CONTRIBUTION

All authors participated in the study design development and final description; however, the following distribution of tasks were assigned to different authors in order to obtain the most of their knowledge and expertise . At the end of the document, all authors approved the article, once they have revised the draft, tables, imagens and had given their input on it, and correct or suggest changes along the document.

Initial distribution of document development was distributed as follows:

Carlos S Duque, Andrés F. Londoño : Leading surgeons, data providers involved as well in the entire document build up and analysis.

Marcela Marulanda, Lina Otalvaro, María F Palacio, Miguel Agudelo : Data revision. Table construction, literature search and comparisons.

Ana M Duque , Jhon J Zuleta : Data recollection, analysis and presentation

Juan P Dueñas , Gianlorenzo Dionigi: Neuromonitoring expertise advice , regarding thyroid surgery under nerve monitoring , analysis, and presentation of data.

Acknowledgment

The authors thank Mrs. Jane Losada, official Certificate English reviewer for her thorough correction of the English grama and style of the document.

References

1. Cawardine T. Excision of the parotid gland with preservation of the facial nerve. Lancet 1907;ii:892
2. Janes RM. The treatment of tumours of the salivary glands by radical excision. Can Med Assoc J 1940;43:554–559
3. Ruoholabo J, Mäkitie AA, Aro K,Haapaniemi A, Keski-SänttiH, Takala A, Bäck LJ. Complications after surgery for benign parotid gland neoplasm: A prospective cohort study. Head Neck. 2017;39(1):170–76
4. Cannizzaro MA, LoBianco S, Picardo MC, Provenzano D, Buffone A. How to avoid and manage post-operative complications in thyroid surgery. Updates Surg 2017;69(2):211–15
5. Eisele DW, Wang SJ, Olrloff LA. Electrophysiologic facial nerve monitoring during parotidectomy. head Neck. 2010;32(3):399–405
6. Guntinas-Lichius O, Eisele DW. Facial Nerve monitoring. Adv Otorhinolaryngol. 2016;78;46–52
7. Savvas E, Hillman S, Weiss D, Koopman M, Rudack C, Alberty J. Association between facial nerve monitoring with post-operative facial paralysis in parotidectomy. JAMA Otololaryngol head neck Surg 2016,1;142(9):828–33
8. Petrides GA, Subramaniam N, Pham M, Clark JR. Reducing the morbidity of parotidectomy for benign pathology. ANZ J Surg. 2020 Nov;90(11):2315–2321. doi: 10.1111/ans.16008. Epub 2020 Jun 2.

PMID: 32483863.

9. Chiesa-Estomba CM, Saga-Gutiérrez C, González-García JÁ, et al. Intraoperative monitoring of the facial nerve during parotid gland surgery in Otolaryngology services - Head and Neck Surgery. Acta Otorrinolaringol Esp (Engl Ed). 2021 May-Jun;72(3):158–163. English, Spanish. doi: 10.1016/j.otorri.2020.03.004. Epub 2020 Nov 23. PMID: 33243418.
10. Randolph GW, Dralle H; International Intraoperative Monitoring Study Group, et al Electrophysiologic recurrent laryngeal nerve monitoring during thyroid and parathyroid surgery: international standards guideline statement. Laryngoscope. 2011;121 Suppl 1: S1-16
11. Schneider R, Randolph GW, Dionigi G, et al International neural monitoring study group guideline 2018 part I: Staging bilateral thyroid surgery with monitoring loss of signal. Laryngoscope. 2018 Oct;128 Suppl 3: S1-S17. doi: 10.1002/lary.27359. Epub 2018 Oct 5. PMID: 30289983.
12. Wu CW, Dionigi G, Barczynski M, et al. International neuromonitoring study group guidelines 2018: Part II: Optimal recurrent laryngeal nerve management for invasive thyroid cancer-incorporation of surgical, laryngeal, and neural electrophysiologic data. Laryngoscope. 2018 Oct;128 Suppl 3: S18-S27. doi: 10.1002/lary.27360. Epub 2018 Oct 6. PMID: 30291765.
13. Schneider R, Machens A, Lorenz K, Dralle H. Intraoperative nerve monitoring in thyroid surgery-shifting current paradigms. Gland Surg. 2020 Feb;9(Suppl 2): S120-S128. doi: 10.21037/gs.2019.11.04. PMID: 32175252; PMCID: PMC7044089.
14. Dionigi G, Chiang FY, Dralle H, et al. Safety of neural monitoring in thyroid surgery. Int J Surg. 2013;11 Suppl 1: S120-6. doi: 10.1016/S1743-9191(13)60031-X. PMID: 24380543.
15. .Al-Qurayshi Z, Robins R, Hauch A, Randolpgh GW, Kandil E. Association of surgeon volume with outcomes and cost savings following thyroidectomy: A national forecast. JAMA Otolaryngol Head Neck Surg. 2016;142(1):32–9
16. Sun GH, DeMonner S, Davis MM. Epidemiological and economic trend in inpatient and outpatient thyroidectomy in the United States 1996–2006. Thyroid 2013.23(6):727–33
17. Sethi RKV, Deschler DG. National trends in inpatient parotidectomy: A fourteen-year retrospective analysis. Am J Otolaryngol. 2018 Sep-Oct;39(5):553–557. doi: 10.1016/j.amjoto.2018.06.010. Epub 2018 Jun 7. PMID: 29907428.
18. Sood Aj. Houlton JJ, Nguyen SA, Gillespie MB. Facial nerve monitoring during parotidectomy: a systematic review and metanalysis. Otolaryngol Head Neck Surg 2015; 152(4):631–7
19. Grosheva M, Klussmann JP, Groimminger C, Wittwkind t C, Beutner D, Pantel M, Volk GF, Guntinas - Lichius O. Electromyographic facial nerve monitoring during parotidectomy for benign lesion does not improve the outcome of postoperative facial nerve function: a prospective two-center trial. Laryngoscope 2009;119(12)2299 – 305
20. Ozturk K, Akyildiz S, Gode S, Turhal G, Gursan G, Kirazli T. The effect of partial superficial parotidectomy on amplitude, latency, and threshold of facial nerve stimulation. Eur Arch Otorhinolaryngol. 2016 Jun;273(6):1527–31. doi: 10.1007/s00405-015-3622-9

21. Graciano AJ, Fischer CA, Coelho GV, Steck JH, Paschoal JR, Chone CT. Facial nerve dysfunction after superficial parotidectomy with or without continuous intraoperative electromyographic neuromonitoring: a prospective randomized pilot study. Eur Arch Otorhinolaryngol. 2018;275(11): 2861–68
22. Haring CT, Ellsperman SE, Edwards BM, et al. Assessment of Intraoperative Nerve Monitoring Parameters Associated with Facial Nerve Outcome in Parotidectomy for Benign Disease. JAMA Otolaryngol Head Neck Surg. 2019 May 2;145(12):1137–43. doi: 10.1001/jamaoto.2019
23. Kartush JM, Rice KS, Minahan RE, Balzer GK, Yingling CD, Seubert CN. Best Practices in Facial Nerve Monitoring. Laryngoscope. 2021 Apr;131 Suppl 4:S1-S42. doi: 10.1002/lary.29459
24. Lahey FH, Hoover WB. Injuries to the Recurrent Laryngeal Nerve in Thyroid operations: Their management and avoidance. Ann Surg. 1938;108(4):545–562. doi:10.1097/00000658-193810000-00006
25. Serpell JW, Yeung MJ, Grodski S. The motor fibers of the recurrent laryngeal nerve are located in the anterior extralarynegal branch. Ann Surg 2009, 249(4):648–52
26. Henry BM, Vikse J, Graves MJ, et al. Extralaryngeal branching of the recurrent laryngeal nerve: a meta-analysis of 28,387 nerves. Langenbecks Arch Surg. 2016;401(7):913–923.
27. Thomas AM, Fahim DK, Gemechu JM. Anatomical Variations of the Recurrent Laryngeal Nerve and Implications for Injury Prevention during Surgical Procedures of the Neck. Diagnostics (Basel). 2020 Sep 4;10(9):670. doi: 10.3390/diagnostics10090670
28. Cernea CR, Hojaij FC, De Carlucci D Jr, Gotoda R, Plopper C, Vanderlei F, Brandão LG. Recurrent laryngeal nerve: a plexus rather than a nerve? Arch Otolaryngol Head Neck Surg. 2009 Nov;135(11):1098–102. doi: 10.1001/archoto.2009.151.
29. Kwak HH, Park HD, Youn KH, Hu KS, Koh KS, Han SH, Kim HJ. Branching patterns of the facial nerve and its communication with the auriculotemporal nerve. Surg Radiol Anat. 2004, 26(6):494–500
30. Stankevicius D, Suchomlinov A. Variations in facial nerve branches and anatomical landnmarks for its trunk identification: A pilot cadaveric study in the Lithuanian population. Cureus.2019,11(11):6100
31. Diamond M, Wartmann CT, Tubbs RS, Shoja MM, Cohen-Gadol AA Loukas M. Peripheral facial nerve communications and their clinical implications. Clin Anat. 2011 Jan;24(1):10–8. doi: 10.1002/ca.21072
32. Sitges-Serra A, Fontané J, Dueñas JP, Duque CS, Lorente L, Trillo L, Sancho JJ. Prospective study on loss of signal on the first side during neuromonitoring of the recurrent laryngeal nerve in total thyroidectomy. Br J Surg. 2013 Apr;100(5):662–6. doi: 10.1002/bjs.9044

Figures

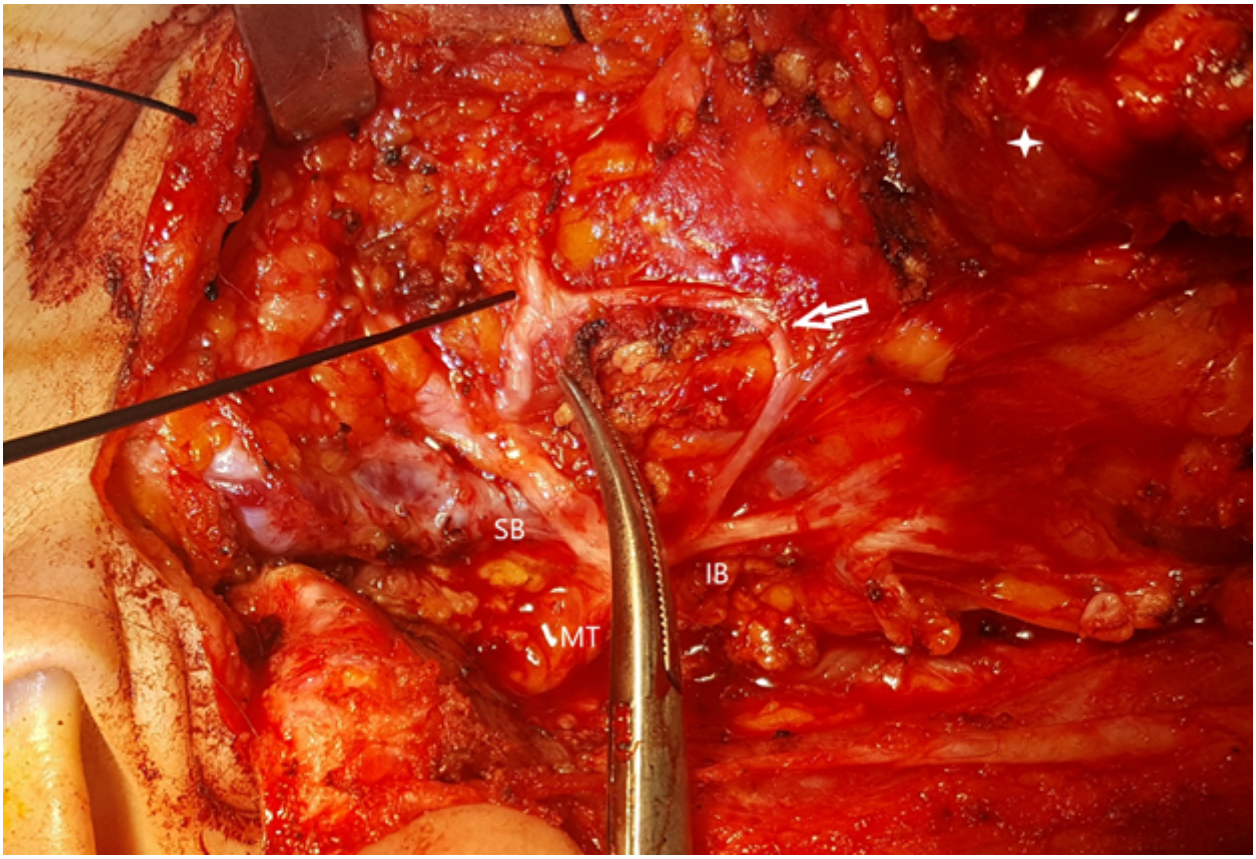

Figure 1

Right parotidectomy; the gland with the tumor – star – is about to be removed. Hemostat clamp and the nerve stimulator probe point to a superior branch that communicates with the inferior system depicted by the arrow. MT: Main trunk; SB: Superior Branch; and IB: Inferior Branch

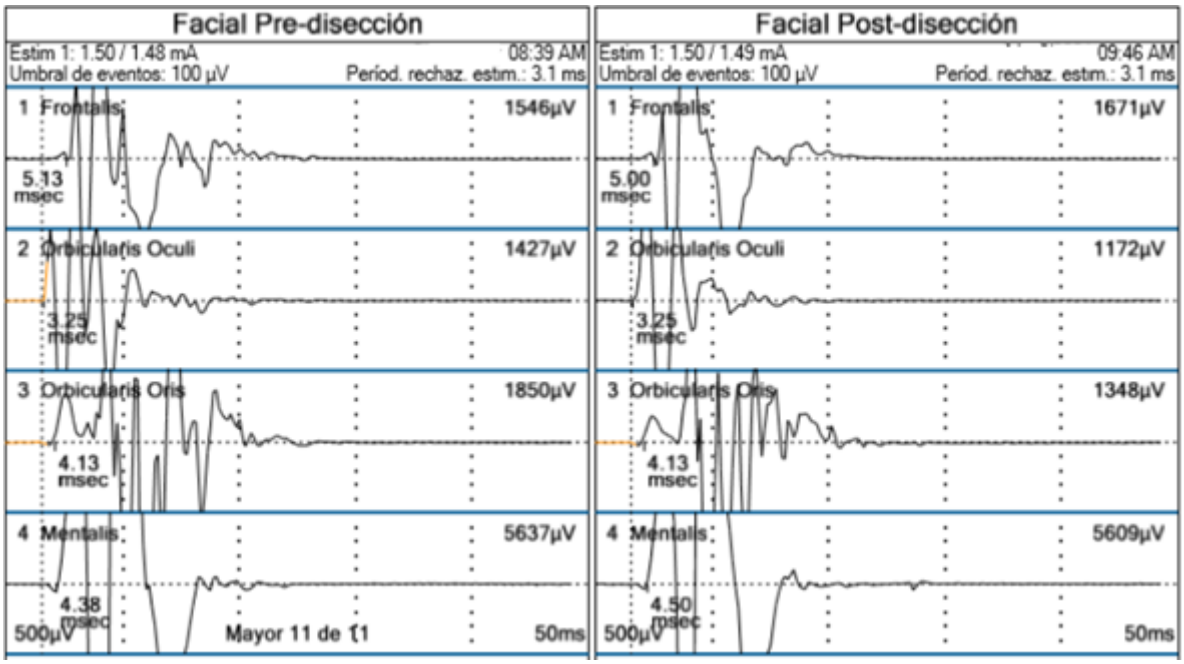

Figure 2

Main trunk responses upon stimulation. Pre-dissection done at 1.48 mA, as there is tissue volume covering the different branches; post-dissection is at 1.49 mA while all nerve branches have been dissected, preserved, and exposed. Even though the same electrical stimulus was done at the trunk for illustration-comparison purposes, the post-dissection check can definitively be done at a lower energy setting.

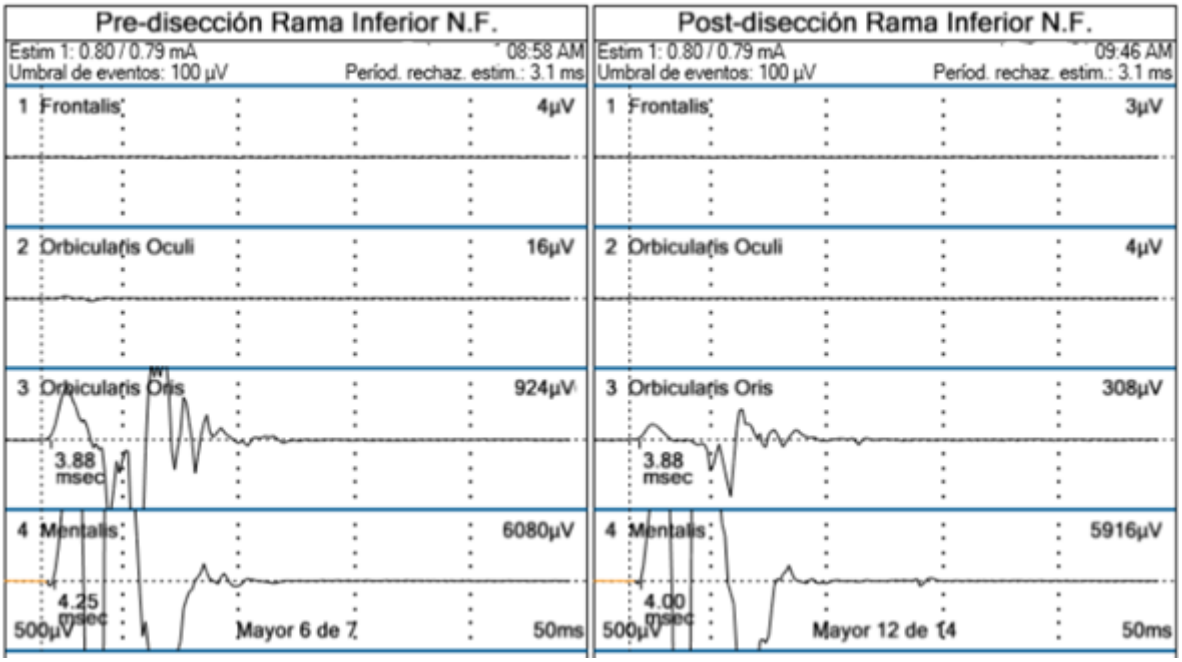

Figure 3

Inferior Branch pre- and post-operative responses, Orbicularis Oris decreasing Amplitude responses, with no change in Latency. Since this is a selective inferior stimulation at 0.79 milliamps, the superior branches show hardly any response.

Note: Images 1-3 were obtained for an illustrative example with consent from a recent patient who underwent a superficial parotidectomy due to a benign pleomorphic adenoma tumor. It does not form part of the series of cases described herein.