Comparison of Maxillary Tuberosity and Palatal Donor Sites for Soft Tissue Augmentation at Implant Placement.

Elli Anna Kotsailidi (elli_kotsailidi@urmc.rochester.edu)
University of Rochester

Dimitris N. Tatakis
The Ohio State University

Yo-wei Chen
Tufts University

Jack G. Caton
University of Rochester

Carlo Ercoli
University of Rochester

Abdul Basir Barmak
University of Rochester

Alexandra Tsigarida
University of Rochester

Research Article

Keywords: Autografts, Connective Tissue/transplantation, Dental Implants, Single-Tooth, Palate, Treatment outcome

Posted Date: May 20th, 2022

DOI: https://doi.org/10.21203/rs.3.rs-1633566/v1

Abstract

Objective: To compare the outcomes of soft tissue augmentation (STA) during one-stage implant placement using grafts harvested from the hard palate (PAL) or the maxillary tuberosity (TUB).

Materials and Methods: Non-smoking adults with single missing tooth, between the premolar region, and ridge dimensions adequate for implant placement were enrolled. Each received single implant and connective tissue graft harvested either from PAL (n=10) or TUB (n=10). Digital impressions were taken pretreatment (T0), and at 2 (T1) and 12 months (T2) postoperatively. Soft tissue thickness (STT) changes was the primary study outcome. Secondary outcomes included marginal bone level (MBL) changes over time, pain levels at the first two postoperative weeks (W1, W2), pink esthetic score (PES) and patient-reported outcomes (PROMs) at T2. Data analysis included repeated measures analysis of variance for intergroup comparisons.

Results: STT significantly increased in both groups ($p \leq 0.002$), at all apico-coronal levels examined, with no significant intergroup differences. There was no significant intergroup difference in MBL changes ($p=0.376$). PAL group experienced higher donor site pain levels at W1 ($p=0.023$). PES and PROMs were similar between groups at T2.

Conclusions: STA during one-stage implant placement results in significant STT increases.

Clinical relevance: When performed simultaneously with single one-stage implants, palatal and tuberosity grafts result in similar and significant soft tissue augmentation outcomes.

Introduction

Alveolar ridge resorption occurring after tooth extraction may lead to alveolar ridge deficiencies. [1] With or without alveolar ridge preservation, implant placement (IP) has been reported to be feasible in most cases, albeit additional ridge augmentation may be needed [2]. Mild buccal horizontal ridge deficiency can be compensated with soft tissue augmentation (STA) using autogenous grafts and substitutes, either at IP time or later [3–5]. Connective tissue grafts (CTG) have been documented as a predictable treatment for the contouring of buccal alveolar ridge deficiencies [6].

The timing of peri-implant STA does not affect soft tissue outcomes [7]. However, STA performed concurrently with one-stage IP may eliminate a second surgery. Additionally, graft adaptation around the implant/healing abutment simultaneously thickens the flap margin, which contributes to marginal bone level stability [6, 8].

The hard palate (PAL) and the maxillary tuberosity (TUB) are the most common intraoral CTG donor sites and both have been used for root coverage and edentulous ridge or peri-implant STA [9–13]. Besides differences in availability, structural and histological differences exist, with TUB grafts containing more lamina propria, less submucosa, and less vascular structures [12, 14]. These differences may affect

operators' decision on donor site selection. Previous studies compared PAL and TUB for STA performed either 6 or 12 weeks after IP and demonstrated similar clinical and esthetic outcomes at 12 months [10, 15]. To the best of the authors' knowledge, the literature lacks studies on the soft tissue, hard tissue, and patient outcomes when comparing PAL and TUB for simultaneous STA around one-stage implants.

The aim of the present study is to compare PAL and TUB for simultaneous STA around one-stage single implants, in terms of peri-implant soft tissue thickness (STT) and marginal bone level (MBL) changes, esthetics, and patient-reported outcomes (PROMs).

Materials And Methods

Study design and study population

This prospective controlled clinical trial was conducted at the Department of Periodontology, University of Rochester, after approval by the Institutional Review Board (STUDY00067871). Eligible participants with a single missing tooth and buccal horizontal ridge deficiency who were seeking implant therapy were identified through screening visits. Eligible patients were enrolled consecutively. All included patients provided written informed consent according to the Declaration of Helsinki. The trial adhered to the CONSORT 2010 guidelines [16].

Assuming a difference in mean STT change between groups of 1.2mm (with 1.1mm common standard deviation) [11], a sample size of 10 patients per group achieves 85% power with significance level set at $\alpha = 0.05$. Hence, 20 patients were recruited. All participants received a one-stage implant and CTG on the implant facial aspect. Group assignment (PAL/TUB) was performed based on tissue availability at the respective donor site, with TUB being the first option explored; if TUB was not adequate, PAL was harvested. Once the TUB group was completed, the remaining patients (n = 1) received PAL. A periodontal resident (EAK) performed all surgeries, under supervision by an experienced periodontist (AT).

Patients were selected based on the following inclusion criteria:

- Age ≥ 18 years old, able to provide written informed consent and comply with study procedures.
- Systemically and periodontally healthy.
- Full-mouth bleeding/plaque scores ≤ 20%.
- Missing a single tooth, from second to second premolar.
- Site having normal apicocoronal ridge height and buccal horizontal ridge deficiency ≤ 3mm, measured with a periodontal probe (UNC15) relative to the adjacent ridge contour.
- Site amenable to prosthetically-driven IP and simultaneous STA without bone grafting.

Patients were excluded based on the following exclusion criteria:

- Pregnant female.

- Current/former smoker.
- Systemic conditions/intake of medications that would be contraindications for IP.
- Intake of medications known to interfere with periodontal tissue health or healing.
- Untreated periodontitis.
- Site requiring bone augmentation prior to or simultaneously with IP, or previously treated with STA.

Surgical procedure

Recipient site preparation

All patients received premedication (2g Amoxicillin or 600mg Clindamycin if allergic to penicillin) one hour before surgery [17]. After establishment of adequate local anesthesia, mid-crestal incision was performed and intrasulcular incisions on each adjacent tooth, allowing full-thickness flap elevation on both buccal and palatal/lingual aspects. The flap thickness was measured with a digital caliper (Grobet File Co of America, Henry Schein, Inc, Palatine, IL, USA), at 1mm apical to the incision line, and recorded to the nearest mm. Osteotomy preparation was performed according to manufacturer's recommended protocol, using surgical guide representing the final crown. One-stage bone level tapered implants (3.3mm or 4.1mm diameter; Straumann, BLT SLActive, Institute Straumann AG, Basel, Switzerland) were placed 1mm subcrestally [18]. Healing abutments were hand-tightened when implant insertion torque was ≥ 35Ncm.

Graft harvesting

STT at potential donor sites was determined by bone sounding; tissue thickness of at least 6mm (TUB) or 3mm (PAL) was required for site selection. If patients' anatomy met both criteria, patients were enrolled in the TUB group, until the group reached the predetermined enrollment number.

A double-blade scalpel (SKU 10-130-05D; Hu-Friedy, Chicago, IL, USA) was used to standardize graft thickness to 1.5mm. For PAL, the double incision was performed 2–3 mm apical to the palatal gingival margin of the premolars and site closure was achieved with cross and horizontal sling mattress sutures. For TUB, the double incision was performed in a distomesial direction, distal to the last tooth, along with a perpendicular incision at the distal end to allow CTG harvesting; simple interrupted sutures were used for closure.

Graft handling and placement

All grafts were trimmed to 5mm length and 8mm width. Any remaining epithelial collar was removed, unlike any glandular or adipose tissue. Grafts were secured horizontally on the facial aspect of the implants, at the implant-abutment connection level, with 5 – 0 absorbable sling sutures (Figure I). Flaps were replaced to cover the grafts and sutured with 5 – 0 absorbable simple interrupted sutures placed on the mesial and distal aspect of each abutment.**Fig. I** Clinical procedure of soft tissue augmentation. Top row: representative palatal donor group case. (a) clinical presentation at baseline, (b) harvested graft and

before trimming, (c) graft and flap secured at surgery completion, (d) 2 months postoperatively, (e) 12 months postoperatively. Bottom row: representative tuberosity donor group case. (f) clinical presentation at baseline, (g) harvested graft and before trimming, (h) graft and flap secured at surgery completion, (i) 2 months postoperatively, (j) 12 months postoperatively. Note differences in appearance between palatal (b) and tuberosity (g) grafts, reflecting the anatomical/structural differences between donor sites

Post-operative protocol

Post-operatively, ibuprofen (600mg three times daily for 3 days) or acetaminophen (1g three times daily for 3 days) and 0.12% chlorhexidine gluconate mouthrinse (twice daily for 2 weeks) were prescribed. Sutures were removed from donor sites after 1 week (W1) and after 2 weeks (W2) from recipient sites. All patients received the definitive implant crown at 4 months post-operatively and were followed for a total of 12 months from surgery.

Outcome measurements

Soft tissue thickness (STT)

Intraoral optical scans of the implant site and at least one adjacent tooth, were obtained with an intraoral scanner (3M™ True Definition) at T0 (baseline), T1 (2 months), T2 (12 months) by a sole experienced and calibrated operator (EAK). Three stereolithographic (STL) files were generated for each patient and imported to a three-dimensional inspection software (Geomagic Control X 2020; 3D Systems, Rock Hill, SC, USA). STL file superimposition, using adjacent teeth and their gingival margins as landmarks, allowed for evaluation of STT changes along the implant site midfacial aspect.

On the superimposed models, sagittal planes passing through the middle of each implant site were created and the linear distances between the three different outlines (T0-T1, T1-T2 and T0-T2) were measured by a sole calibrated and blinded examiner (YWC) (Figure II). These linear distances represent STT changes over time. Measurements were conducted at 5 apico-coronal levels; the level of the adjacent CEJs (A_0) and at a distance of 1, 2, 3, and 4mm apical to that level (A_i, A_{ii}, A_{iii} and A_{iv}). For each implant, the planes and levels where measurements were conducted were kept constant to allow for pairwise comparisons over time.

Fig. II Example of superimposition of stereolithographic files of a patient (TUB group), captured with intraoral scan pre-operatively and at 12 months postoperatively. (a) Buccal view. (b) Buccal view with crown virtually removed. (c): Occlusal view with crown virtually removed. (d) Cross section with soft tissue contours pre-operatively (black outline) and at 12 months (colored outline) and their difference outlined. Measurements were taken at five different apico-coronal levels (see text for details)

Marginal bone levels (MBL)

To assess mesial and distal MBL, standardized digital vertical bitewing radiographs were taken immediately after IP, and at T1 and T2, using phosphor plates and radiographic holders, positioned

reproducibly using bite registration material. Radiographic measurements were conducted using imaging software (Dolphin ImplannerTM; Dolphin Imaging and Management Solutions, Oakdale, CA), as described previously [19]. Briefly, the bone crest to implant platform linear distance (mm) was measured on the trajectory of vertical lines passing tangentially on the mesial and distal implant surfaces. Marginal bone loss on the mesial and distal was reported as an absolute number and the two values were averaged to calculate the overall marginal bone loss per implant. MBL measurements were conducted by a sole, calibrated, and blinded examiner (AT).

Pain assessment

Post-operative pain at recipient (RS) and donor sites (DS) was rated at W1 and W2 with a Visual Analogue Scale (VAS) ranging from 0 to 10 (0 = no pain, 10 = very severe pain).

Esthetic outcome assessment (PES)

Peri-implant soft tissue esthetic assessment was performed at T2 by a sole, calibrated, and blinded examiner (AT), using clinical photographs to calculate the pink esthetic score (PES) [20].

Patient-reported outcomes (PROMs)

PROMs were assessed at T2 through a two-item survey using a numerical scale from 1 to 5 (1 = Not satisfied/Not likely, 5 = Highly satisfied/Highly likely). Participants were informed of the meaning of each category prior to completing the survey. The two questions on the survey were: “Are you satisfied with the esthetic outcome of the gums surrounding the implant?” and “Would you undergo the same procedure again?”

Examiner reliability

Each standardized examiner (YWC for STT; AT for MBL and PES) measured 5 randomly selected patients twice, one week apart, to assess intra-examiner reliability. The resulting ICC was ≥ 0.91 for all measurements.

Data analysis

Study population demographics were analyzed using Chi-square and independent sample t-test. Data normality was assessed using Kolmogorov-Smirnov and Shapiro-Wilk tests. Descriptive statistics were calculated for STT and MBL changes, post-operative pain, and PES. Repeated measures analysis of variance (ANOVA) was used to compare STT changes between groups, levels and across time, as well as MBL changes and pain scores between groups and across time. Independent-samples Mann-Whitney U test was used to compare MBL changes, post-operative pain, and PES. Tukey’s test was used for post-hoc analyses. Level of significance was set at $\alpha = 0.05$. Data analysis was performed with statistical software (IBM SPSS Statistics for Windows, Version 25.0. Armonk, NY: IBM Corp).

Results

Study population

A total of 20 patients (8 males/12 females) aged 46.4±14.7 years were recruited and 19 completed all study procedures. One female PAL group patient withdrew before T2, due to relocating. Data from all patients are reported. There were no significant differences regarding age, gender, implant location and flap thickness between groups (Table I), even with removal of the one subject. Implant diameter was significantly different as the 4 out of the 10 patients in the PAL group received narrower diameter implants (3.3mm), while all patients in the TUB group received standard diameter implants (4.1mm) (Table I).

Table I. Population characteristics

Characteristics		PAL	TUB	Total	*p*-value
N		10	10	20	
Gender	Males	5	3	8	0.1†
	Females	5	7	12	
Age (mean±SD)		48.9±14.5	44.0±14.2	46.5±14.7	0.5‡
Location	Maxilla	8	6	14	0.1†
	Mandible	2	4	6	
	Lateral incisor	1	0	1	
	Canine	1	0	1	
	First premolar	4	3	7	
	Second premolar	4	7	11	
Implant diameter (*mm*)	4.1	6	10	16	**0.03**†
	3.3	4	0	4	
Flap thickness (*mm*, mean±SD)		1.2±0.5	1.3±0.6		0.7‡
Drop-outs		1*	0	1	

PAL, palatal graft group; TUB, tuberosity graft group; N, number of participants; SD, standard deviation.

† Chi-square test, boldface indicates statistical significance.

‡ Independent sample T-test

*Patient dropped out between T1 and T2

STT changes

STT changes are detailed in Table II. For both groups, STT changes differed significantly by time ($p<0.002$) and by level ($p=0.000$). The greatest STT changes were observed between T0 and T2, and the smallest between T1 and T2. STT change magnitude decreased from the most coronal (A_0) to the most apical tissue levels (A_{iv}). However, no significant STT change differences were observed between groups, at any level or time point (Supplemental Table I).

Table II. Soft tissue thickness changes (*mm*) over time, at different apico-coronal levels.

Levels	Groups	T1-T0	T2-T0	T2-T1	At-level group effect (*p*-value) †	At-level time effect (*p*-value) †
A_0	PAL	1.7±1.4	2.2±1.2	0.4±0.7	0.503	**0.001**
	TUB	1.9±1.1	2.5±1.3	0.6±0.4		
A_i	PAL	1±1	1.4±0.8	0.4±1.2	0.244	**0.002**
	TUB	1.4±1	1.9±1.1	0.5±0.6		
A_{ii}	PAL	1±0.4	1.1±0.6	0±0.7	0.111	**0.000**
	TUB	1.2±0.9	1.6±1.2	0.4±0.6		
A_{iii}	PAL	0.9±0.2	0.9±0.5	0±0.6	0.894	**0.000**
	TUB	0.8±0.7	0.9±0.9	0.1±0.5		
A_{iv}	PAL	0.7±0.2	0.6±0.7	-0.1±0.8	0.886	**0.001**
	TUB	0.6±0.6	0.6±0.6	0.1±0.3		

Values reported are mean±SD. Data from $n_{PAL}= n_{TUB}=10$, except for T2 where $n_{PAL}=9$.

SD, standard deviation; PAL, palatal graft group; TUB, tuberosity graft group.

Time points: T0, baseline; T1, 2 months postoperatively; T2, 12 months postoperatively.

T1-T0, change between T0 and T1; T2-T0, change between T0 and T2; T2-T1, change between T1 and T2.

Levels: A_0, level of adjacent CEJs; A_i, 1mm apical to A_0; A_{ii}, 2mm apical to A_0; A_{iii}, 3mm apical to A_0; A_{iv}, 4mm apical to A_0.

† Repeated measures ANOVA, Tukey's test; boldface indicates statistical significance.

MBL changes

MBL changes are detailed in Table III. For both groups, time significantly affected MBL changes ($p=0.008$). The greatest MBL change was observed between IP and T2 and the smallest between T1 and T2, for both groups. However, no significant intergroup differences in MBL changes were found during any time period.

Table III. Marginal bone loss (*mm*) over time.

	T1-IP	**T2-IP**	**T2-T1**	Group effect (*p*-value) ‡	Time effect (*p*-value) ‡	Group:Time effect (*p*-value) ‡
PAL	0.9±0.7	1.3±0.9	0.4±0.5	0.194	**0.008**	0.481
TUB	0.5±0.4	1±0.8	0.5±0.6			
p-value†	0.142	0.376	0.786			

Values reported are mean±SD. Data from n_{PAL}= n_{TUB}=10, except for T2 where n_{PAL}=9.

SD, standard deviation; PAL, palatal graft group; TUB, tuberosity graft group; IP, time of implant placement; T1: 2 months postoperatively; T2: 12 months postoperatively.

† Independent-samples Mann-Whitney U test

‡ Multivariate analysis of variance; boldface indicates statistical significance (p<0.05).

Pain outcomes

Pain outcomes are detailed in Table IV. For both groups, and for both RS and DS, time had a significant effect (p≤0.014), with mean pain scores significantly reduced from W1 to W2. Group had a significant effect only for DS (p=0.010), with mean pain scores significantly lower for TUB at W1 (p=0.023).

Table IV. VAS pain scores for recipient and donor sites over time

	Recipient site pain score		**Donor Site pain score**	
	W1	W2	W1	W2
PAL	3.2±2.5	1.6±2.4	3.9±3.2*	1.5±2.4
TUB	1.5±1.3	0.4±0.5	1.3±1*	0.4±0.5
Group effect (*p*-value) †	0.108		**0.010**	
Time effect (*p*-value) †	**0.014**		**0.002**	
Group:Time effect (*p*-value) †	0.390		0.675	

Values reported are mean±SD. Data from n_{PAL}= n_{TUB}=10

VAS, visual analogue scale; SD, standard deviation; PAL, palatal graft group; TUB, tuberosity graft group; W1, end of 1st post-operative week; W2, end of 2nd post-operative week.

*Significant difference between groups at specific time point (p<0.05).

†Multivariate analysis of variance; boldface indicates statistical significance (p<0.05).

PES outcomes

The mean PES score was 9.6±2.2 and 10.1±1.6 for PAL and TUB group, respectively, at T2. No significant intergroup differences were observed (p=0.54, Independent-samples Mann-Whitney U test).

Patient-reported outcomes (PROMs)

PROMs were almost identical between groups. All patients in both groups were “highly satisfied” with the esthetic outcome and reported that it was “highly likely” they would choose to undergo the same procedure again, except for one PAL group patient, who replied that it was “likely” they would choose to undergo the same procedure again.

Discussion

The present study is the first to compare soft tissue thickness changes after soft tissue augmentation with connective tissue grafts taken either from palate (PAL) or tuberosity (TUB) and performed simultaneously with one-stage implant placement. Results of the present study demonstrate that STT increased on the facial aspect of the implants one year postoperatively, with no significant differences between groups. These novel results suggest that, under the reported surgical protocol, structural CTG differences may have limited impact on the observed STT changes. MBL changes, post-operative pain, PES and patients’ willingness to undergo the same procedure in the future, were all similar for the two groups.

The present study outcomes are consistent with the results of similar studies on peri-implant augmentation. Rojo et al. compared PAL and TUB as donor sites of 1.5mm thick CTGs placed either 6 or 12 weeks after IP, using a similar approach and technology [10, 15], and found that both tissues demonstrated similar STT changes after 3 and 12 months. Dellavia et al. compared 3.5mm thick CTGs harvested from PAL and TUB for ridge augmentation, and evaluated the outcomes through transgingival probing [11]. In contrast to the previous study, TUB grafts exhibited a tendency for a hyperplastic response after 1 year, with PAL grafts remaining stable over time. The authors histologically identified greater collagen crosslinking in TUB grafts and, therefore, reduced susceptibility to degradation. This discrepancy in TUB outcomes among studies may reflect the significant differences in graft thickness. In the present study and the one by Rojo et al [10, 15] TUB grafts were 1.5mm thick and much thinner than

those used by Dellavia et al. [11]. In this context, Dellavia et al. suggested to always trim grafts to a 3mm thickness to avoid any hyperplastic response [11].

In the present study, the TUB harvesting approach used was akin to a distal wedge incision [10, 15, 21], as opposed to gingivectomy and gingival flap [22, 23]. There are no studies reporting on any possible differences in TUB graft structure or outcomes when different harvesting approaches are used.

Significant differences in STT changes were observed at different apico-coronal levels, with smallest STT changes occurring at the most apical level in both groups. This could be potentially explained by the standardized graft size and graft orientation during placement, along with the fact that the grafts, at their apical extension, were likely covered by mobile alveolar mucosa rather than attached peri-implant mucosa, a condition that might have negatively impacted graft healing in the more apical areas. Furthermore, the intragroup mean STT changes at 12 months and compared to baseline (0.14mm for PAL and 0.34 for TUB) indicate that both grafts underwent significant shrinkage compared to their initial thickness of 1.5mm. Additionally, the STT change at 12 months in the most coronal portion of the grafted areas, may be partly attributed to the presence of the prosthetic abutment and implant crown at that time point [24]. Nevertheless, no significant intergroup differences in STT changes were observed at any level, throughout the study duration. This is in partial agreement with the recent finding of no significant differences between TUB and PAL in volume changes at 12 months postoperatively [15]. However, in the same study it was reported that TUB grafts resulted in greater volume gain at an apical extension of 5-7mm from the healing abutment at 3 months postoperatively [10]. This discrepancy may be partly due to differences in apico-coronal graft length between studies (present study: 5mm; Rojo et al.: 10mm).

Several studies have indicated that IP at sites with thicker soft tissue results in reduced marginal bone loss [25, 26]. In addition, STA during IP at sites with thin tissues, has been shown to significantly reduce marginal bone loss after 2 months and 1 year [27]. Considering the TUB grafts' reported greater dimensional stability [15] and hyperplastic tendency [11], it was hypothesized that TUB grafts placed at the implant/healing abutment connection level would result in reduced marginal bone loss. The lack of significant overall MBL intergroup differences at 2 and 12 months post-surgery can be attributed to the fact that there were no significant differences in the acquired STT between groups. Graft standardization, in terms of dimensions and placement, may have also contributed to this outcome. Despite the lack of statistically significant intergroup differences, there was a consistent trend for lesser marginal bone loss (by 0.4 and 0.35 mm at T1 and T2, respectively) in the TUB group. This trend could possibly result in significant intergroup differences longer-term or could be found to be significant in future studies with greater sample size. Furthermore, the potential influence of STA on buccal bone thickness [28] was not investigated in the present study. This aspect of hard tissue outcomes merits further investigation.

The present study observed higher pain levels associated with PAL donor sites at W1, with intergroup differences becoming non-significant at W2. This outcome is in general agreement with the study of Amin et al [29], who reported lower pain levels and painkiller consumption associated with TUB, compared to PAL, during the first 2 postoperative weeks.. However, the latter study reported combined

pain outcomes for epithelialized and subepithelial tissue grafts, unlike the present project. Notably, none of the participants in the current trial experienced sloughing/necrosis of the overlying palatal flap, which has been shown to contribute to greater post-operative pain [30] and pain killer consumption [31]. Additionally, both donor sites healed by secondary intention due to the uniform harvesting technique (double incision); however, healing mode hasn't been shown to influence post-operative pain [31]. It can be speculated that the observed differences are attributable to the harvesting method, the greater palatal surface area (corresponding to graft width) being left covered with only a thin portion of connective tissue and overlying flap upon PAL harvesting, as opposed to the more limited surface area exposed after TUB harvesting (corresponding to graft thickness), the assumed lack of friction during mastication or constant irritation from the tongue for TUB, compared to PAL sites [29], and possible innervation differences between the two anatomical sites.

Taking into consideration previous reports on TUB grafts' hyperplastic response [11], peri-implant esthetic outcomes were expected to be influenced in the present study. Nevertheless, no PES differences were observed at T2, a time corresponding to 8 months following crown delivery. This agrees with previous studies that reported similar esthetic outcomes for PAL and TUB grafts, of the same thickness as in the present study, at 2 weeks and 8 months after final restoration delivery [10, 15].

Patients' esthetic perception didn't differ among groups; in fact, all participants reported being completely satisfied with the outcome. This result, combined with the relatively low pain levels experienced at W1 and W2, likely explains the patients' reported willingness to undergo the same procedure again. In this context, a recent study on patients' experience of autogenous soft tissue grafting concluded that previous experience has an influence on their decision to undergo future treatment [32].

Strengths of the present study include graft standardization (thickness, overall dimensions, and placement), radiographic standardization, blinding of examiners performing the clinical (STT measurements), radiographic (MBL) and esthetic (PES) assessments, and use of a power-adjusted sample. The evaluation of linear STT changes through superimposition of STL files, captured by means of intraoral optical scans at different time points, is a technique that has been previously used effectively for STA assessment around implants [10, 33]. There are no studies comparing this digital evaluation method with other methods of dimensional evaluation such as transgingival probing, ultrasonography, etc. [33, 34]. Nevertheless, factors such as operators' calibration for scan acquisition and measurement conduction, short-span scanning [35] and utilization of a fixed level of reference for the linear measurements (adjacent tooth CEJs rather than peri-implant mucosal margin, which can easily undergo positional change), increase the accuracy of the method [36]. A recent study that used the same software, reported high precision, with a level of error of 0.007mm for buccal gingival thickness measurements [37], a value that is insignificant relative to the magnitude (in mm) of planned and anticipated thickness changes. The lack of randomization could be considered a limitation of the present study. However, due to the required standardized graft thickness and the harvesting method, a specific amount of tissue thickness was required at each donor site. Furthermore, clinical parameters such as probing depth, keratinized tissue width and peri-implant indices were not recorded nor evaluated. Additionally, it is

pertinent to mention that the reported lack of statistical significance for MBL change, PES and patient-reported outcomes may be attributed to the fact that the sample size was calculated on the basis of STT change difference between groups rather than of the above-mentioned parameters. Lastly, the final observation period of 1 year could be considered a relative shortcoming; longer observation periods would be desirable for long-term evaluation of both soft (STT) and hard (MBL) tissue changes following implant placement.

Conclusion

Soft tissue thickness augmentation during one-stage implant placement with either palatal or tuberosity grafts results, 12 months postoperatively, in similar soft tissue contour changes.

Declarations

Funding information: This project was supported by the Implant Dentistry Research & Education Foundation, a division of the International Congress of Oral Implantologists (GR501246).

Conflict of interest: Author AT received research grant by the Implant Dentistry Research & Education Foundation, a division of the International Congress of Oral Implantologists.

Ethics approval: This study was performed in line with the principles of the Declaration of Helsinki and CONSORT guidelines. Approval was granted by the Institutional Review Board of University of Rochester (STUDY00067871, approval date: 03/05/2018).

Authors' contribution: AT and DNT conceived the study. EAK, DNT, JGC, CE and DT contributed to study design. EAK and AT identified and enrolled eligible subjects. EAK performed the surgeries and follow-up visits. YWC contributed to the study measurements. ABB performed the statistical analyses. EAK, ABB and AT analyzed the study results. EAK and AT prepared the manuscript draft. All authors contributed to critical revision of the manuscript draft. All authors approved the final version.

References

1. Schropp L, Wenzel A, Kostopoulos L and Karring T (2003) Bone healing and soft tissue contour changes following single-tooth extraction: a clinical and radiographic 12-month prospective study. Int J Periodontics Restorative Dent 23:313–23.
2. Mardas N, Trullenque-Eriksson A, MacBeth N, Petrie A and Donos N (2015) Does ridge preservation following tooth extraction improve implant treatment outcomes: a systematic review: Group 4: Therapeutic concepts & methods. Clin Oral Implants Res 26 Suppl 11:180–201. doi: 10.1111/clr.12639
3. Esposito M, Maghaireh H, Grusovin MG, Ziounas I and Worthington HV (2012) Soft tissue management for dental implants: what are the most effective techniques? A Cochrane systematic

review. Eur J Oral Implantol 5:221–38.

4. De Angelis P, De Angelis S, Passarelli PC, Liguori MG, Pompa G, Papi P, Manicone PF and D'Addona A (2021) Clinical comparison of a xenogeneic collagen matrix versus subepithelial autogenous connective tissue graft for augmentation of soft tissue around implants. Int J Oral Maxillofac Surg 50:956–963. doi: 10.1016/j.ijom.2020.11.014
5. Hutton CG, Johnson GK, Barwacz CA, Allareddy V and Avila-Ortiz G (2018) Comparison of two different surgical approaches to increase peri-implant mucosal thickness: A randomized controlled clinical trial. J Periodontol 89:807–814. doi: 10.1002/JPER.17-0597
6. Noelken R, Geier J, Kunkel M, Jepsen S and Wagner W (2018) Influence of soft tissue grafting, orofacial implant position, and angulation on facial hard and soft tissue thickness at immediately inserted and provisionalized implants in the anterior maxilla. Clin Implant Dent Relat Res 20:674–682. doi: https://doi.org/10.1111/cid.12643
7. Lin CY, Chen Z, Pan WL and Wang HL (2018) Impact of timing on soft tissue augmentation during implant treatment: A systematic review and meta-analysis. Clin Oral Implants Res 29:508–521. doi: 10.1111/clr.13148
8. Tavelli L, Barootchi S, Avila-Ortiz G, Urban IA, Giannobile WV and Wang HL (2021) Peri-implant soft tissue phenotype modification and its impact on peri-implant health: A systematic review and network meta-analysis. J Periodontol 92:21–44. doi: 10.1002/jper.19-0716
9. Zucchelli G, Mazzotti C, Mounssif I, Mele M, Stefanini M and Montebugnoli L (2013) A novel surgical-prosthetic approach for soft tissue dehiscence coverage around single implant. Clin Oral Implants Res 24:957–62. doi: 10.1111/clr.12003
10. Rojo E, Stroppa G, Sanz-Martin I, Gonzalez-Martín O, Alemany AS and Nart J (2018) Soft tissue volume gain around dental implants using autogenous subepithelial connective tissue grafts harvested from the lateral palate or tuberosity area. A randomized controlled clinical study. J Clin Periodontol 45:495–503. doi: 10.1111/jcpe.12869
11. Dellavia C, Ricci G, Pettinari L, Allievi C, Grizzi F and Gagliano N (2014) Human palatal and tuberosity mucosa as donor sites for ridge augmentation. Int J Periodontics Restorative Dent 34:179–86. doi: 10.11607/prd.1929
12. Studer SP, Allen EP, Rees TC and Kouba A (1997) The thickness of masticatory mucosa in the human hard palate and tuberosity as potential donor sites for ridge augmentation procedures. J Periodontol 68:145–51. doi: 10.1902/jop.1997.68.2.145
13. Zuiderveld EG, Meijer HJA, den Hartog L, Vissink A and Raghoebar GM (2018) Effect of connective tissue grafting on peri-implant tissue in single immediate implant sites: A RCT. J Clin Periodontol 45:253–264. doi: 10.1111/jcpe.12820
14. Sanz-Martín I, Rojo E, Maldonado E, Stroppa G, Nart J and Sanz M (2019) Structural and histological differences between connective tissue grafts harvested from the lateral palatal mucosa or from the tuberosity area. Clin Oral Investig 23:957–964. doi: 10.1007/s00784-018-2516-9

15. Rojo E, Stroppa G, Sanz-Martin I, Gonzalez-Martín O and Nart J (2020) Soft tissue stability around dental implants after soft tissue grafting from the lateral palate or the tuberosity area - A randomized controlled clinical study. J Clin Periodontol 47:892–899. doi: 10.1111/jcpe.13292
16. Schulz KF, Altman DG and Moher D (2010) CONSORT 2010 statement: updated guidelines for reporting parallel group randomized trials. Ann Intern Med 152:726–32. doi: 10.7326/0003-4819-152-11-201006010-00232
17. Esposito M, Worthington HV, Loli V, Coulthard P and Grusovin MG (2010) Interventions for replacing missing teeth: antibiotics at dental implant placement to prevent complications. Cochrane Database Syst Rev:Cd004152. doi: 10.1002/14651858.CD004152.pub3
18. Ercoli C, Jammal G, Buyers M, Tsigarida AA, Chochlidakis KM, Feng C and Caton J (2017) Influence of Apico-Coronal Implant Placement on Post-Surgical Crestal Bone Loss in Humans. J Periodontol 88:762–770. doi: 10.1902/jop.2017.160802
19. Genetti L, Ercoli C, Kotsailidi EA, Feng C, Tsigarida A and Chochlidakis K (2021) Clinical Evaluation of Crestal Bone Levels, Peri-Implant Indices, and Mucosal Margin Position of Immediately Impressed Posterior Dental Implants: A Cross-Sectional Study. J Prosthodont. doi: 10.1111/jopr.13362
20. Fürhauser R, Florescu D, Benesch T, Haas R, Mailath G and Watzek G (2005) Evaluation of soft tissue around single-tooth implant crowns: the pink esthetic score. Clin Oral Implants Res 16:639–44. doi: 10.1111/j.1600-0501.2005.01193.x
21. Zuhr O, Bäumer D and Hürzeler M (2014) The addition of soft tissue replacement grafts in plastic periodontal and implant surgery: critical elements in design and execution. J Clin Periodontol 41 Suppl 15:S123-42. doi: 10.1111/jcpe.12185
22. Jung U-W, Um Y-J and Choi S-H (2008) Histologic Observation of Soft Tissue Acquired From Maxillary Tuberosity Area for Root Coverage. J Periodontol 79:934–940. doi: https://doi.org/10.1902/jop.2008.070445
23. Hirsch A, Attal U, Chai E, Goultschin J, Boyan BD and Schwartz Z (2001) Root coverage and pocket reduction as combined surgical procedures. J Periodontol 72:1572–9. doi: 10.1902/jop.2001.72.11.1572
24. Su H, Gonzalez-Martin O, Weisgold A and Lee E (2010) Considerations of implant abutment and crown contour: critical contour and subcritical contour. Int J Periodontics Restorative Dent 30:335–43.
25. Linkevicius T, Puisys A, Steigmann M, Vindasiute E and Linkeviciene L (2015) Influence of Vertical Soft Tissue Thickness on Crestal Bone Changes Around Implants with Platform Switching: A Comparative Clinical Study. Clin Implant Dent Relat Res 17:1228–36. doi: 10.1111/cid.12222
26. Berglundh T and Lindhe J (1996) Dimension of the periimplant mucosa. Biological width revisited. J Clin Periodontol 23:971–3. doi: 10.1111/j.1600-051x.1996.tb00520.x
27. Puisys A and Linkevicius T (2015) The influence of mucosal tissue thickening on crestal bone stability around bone-level implants. A prospective controlled clinical trial. Clin Oral Implants Res 26:123–9. doi: 10.1111/clr.12301

28. Zuiderveld EG, van Nimwegen WG, Meijer HJA, Jung RE, Mühlemann S, Vissink A and Raghoebar GM (2021) Effect of connective tissue grafting on buccal bone changes based on cone beam computed tomography scans in the esthetic zone of single immediate implants: A 1-year randomized controlled trial. J Periodontol 92:553–561. doi: 10.1002/jper.20-0217
29. Amin PN, Bissada NF, Ricchetti PA, Silva APB and Demko CA (2018) Tuberosity versus palatal donor sites for soft tissue grafting: A split-mouth clinical study. Quintessence Int 49:589–598. doi: 10.3290/j.qi.a40510
30. Harris RJ (1997) A comparison of two techniques for obtaining a connective tissue graft from the palate. Int J Periodontics Restorative Dent 17:260–71.
31. Zucchelli G, Mele M, Stefanini M, Mazzotti C, Marzadori M, Montebugnoli L and De Sanctis M (2010) Patient morbidity and root coverage outcome after subepithelial connective tissue and de-epithelialized grafts: a comparative randomized-controlled clinical trial. J Clin Periodontol 37:728–738. doi: https://doi.org/10.1111/j.1600-051X.2010.01550.x
32. Tavelli L, Barootchi S, Di Gianfilippo R, Kneifati A, Majzoub J, Stefanini M, Zucchelli G and Wang HL (2021) Patient experience of autogenous soft tissue grafting has an implication for future treatment: A 10- to 15-year cross-sectional study. J Periodontol 92:637–647. doi: 10.1002/jper.20-0350
33. Hosseini M, Worsaae N and Gotfredsen K (2020) Tissue changes at implant sites in the anterior maxilla with and without connective tissue grafting: A five-year prospective study. Clin Oral Implants Res 31:18–28. doi: 10.1111/clr.13540
34. Papi P, Penna D, Di Murro B and Pompa G (2021) Clinical and volumetric analysis of peri-implant soft tissue augmentation using an acellular dermal matrix: A prospective cohort study. J Periodontol 92:803–813. doi: 10.1002/jper.20-0219
35. Schmidt A, Klussmann L, Wöstmann B and Schlenz MA (2020) Accuracy of Digital and Conventional Full-Arch Impressions in Patients: An Update. J Clin Med 9:688. doi: 10.3390/jcm9030688
36. Tavelli L, Barootchi S, Majzoub J, Siqueira R, Mendonca G and Wang HL (2021) Volumetric changes at implant sites: A systematic appraisal of traditional methods and optical scanning-based digital technologies. J Clin Periodontol 48:315–334. doi: 10.1111/jcpe.13401
37. Fons-Badal C, Alonso Pérez-Barquero J, Martínez-Martínez N, Faus-López J, Fons-Font A and Agustín-Panadero R (2020) A novel, fully digital approach to quantifying volume gain after soft tissue graft surgery. A pilot study. J Clin Periodontol 47:614–620. doi: 10.1111/jcpe.13235

Figures

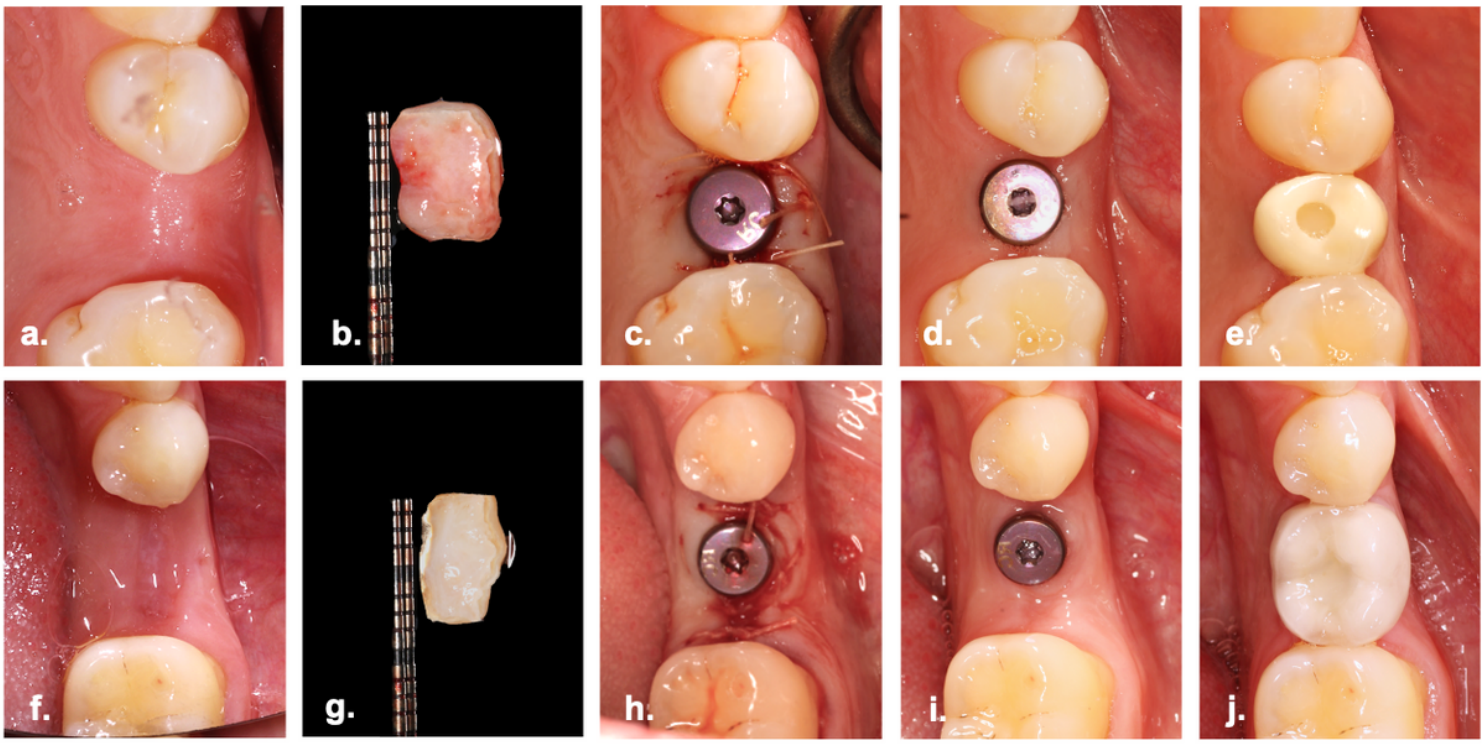

Figure 1

Clinical procedure of soft tissue augmentation. Top row: representative palatal donor group case. (a) clinical presentation at baseline, (b) harvested graft and before trimming, (c) graft and flap secured at surgery completion, (d) 2 months postoperatively, (e) 12 months postoperatively. Bottom row: representative tuberosity donor group case. (f) clinical presentation at baseline, (g) harvested graft and before trimming, (h) graft and flap secured at surgery completion, (i) 2 months postoperatively, (j) 12 months postoperatively. Note differences in appearance between palatal (b) and tuberosity (g) grafts, reflecting the anatomical/structural differences between donor sites

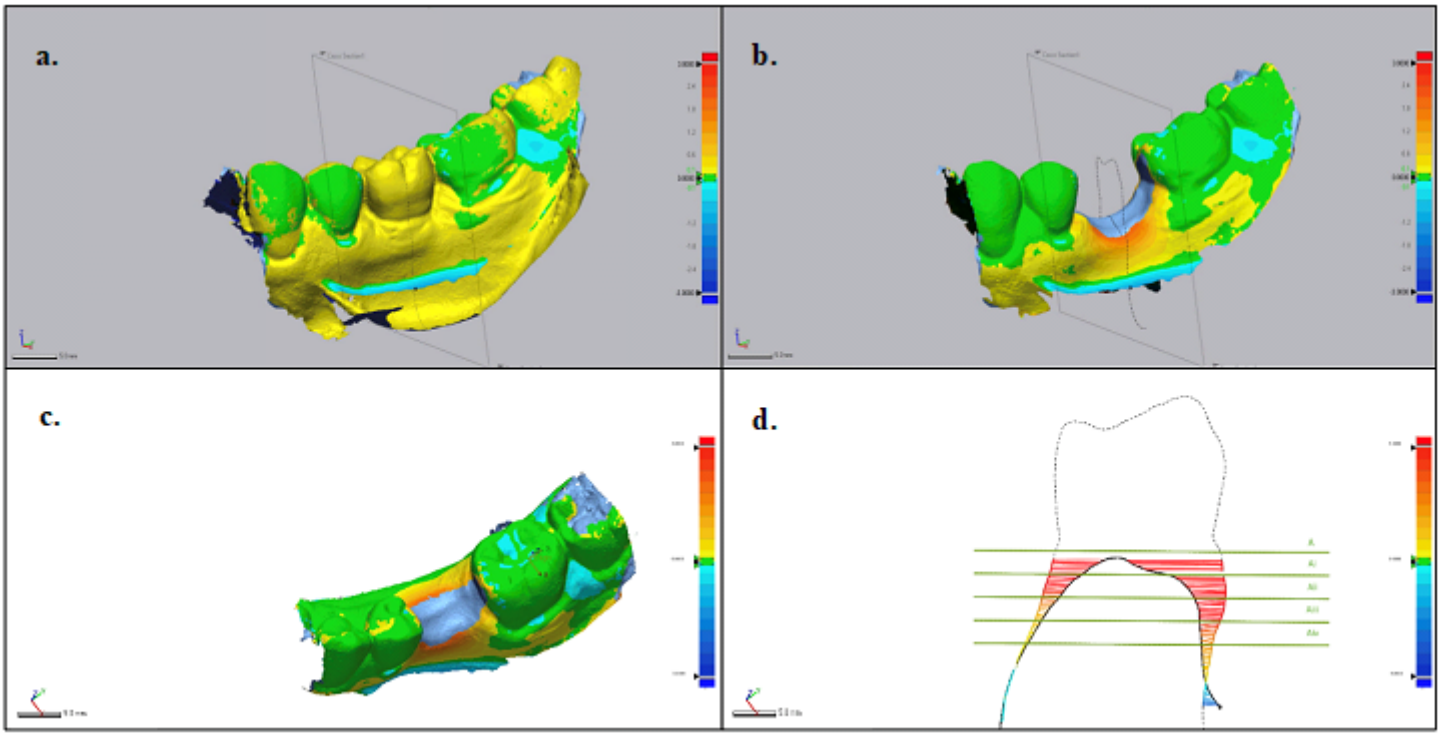

Figure 2

Example of superimposition of stereolithographic files of a patient (TUB group), captured with intraoral scan pre-operatively and at 12 months postoperatively. (a) Buccal view. (b) Buccal view with crown virtually removed. (c): Occlusal view with crown virtually removed. (d) Cross section with soft tissue contours pre-operatively (black outline) and at 12 months (colored outline) and their difference outlined. Measurements were taken at five different apico-coronal levels (see text for details)

Supplementary Files

This is a list of supplementary files associated with this preprint. Click to download.

- Appendix.docx