Modified Periprostatic Nerve Block Provides Better Anesthesia in Ultrasound-Guided Transperineal Prostate Biopsy

Chen Dong
the Third Affiliated Hospital of Kunming Medical University
Haitao Chen
the Third Affiliated Hospital of Kunming Medical University
Jiao Li
Children's Hospital Affiliated to Kunming Medical University
Zhirui Chuan
the Third Affiliated Hospital of Kunming Medical University
Yunying Wang
the Third Affiliated Hospital of Kunming Medical University
Zhi-qiang Ouyang
the Third Affiliated Hospital of Kunming Medical University
Hong yin Yang
the Third Affiliated Hospital of Kunming Medical University
Xiaomao Luo
the Third Affiliated Hospital of Kunming Medical University
Zhiyao Li
the Third Affiliated Hospital of Kunming Medical University
Chengde Liao (chengdeliao@qq.com)
the Third Affiliated Hospital of Kunming Medical University

Research Article

Keywords: Prostate cancer, Perineal Nerve Block, Biopsy, Anesthesia

Posted Date: May 20th, 2022

DOI: https://doi.org/10.21203/rs.3.rs-1635335/v1

Abstract

Background: To determine the efficacy and safety of perineal nerve block (PNB) and modified perineal nerve block (PNB-1) in ultrasound-guided transperineal prostate biopsy(TPBx).

Methods:910 patients were enrolled from March 2019 to December 2021. They were divided into two groups based on their anesthesia methods: PNB group (375 patients) and PNB-1 group (535 patients). The pain scores were evaluated using visual analogue scale (VAS) at the start of anesthesia, during puncture biopsy, and one hour after operation.The chi-square test was used for comparison.

Result:At the start of anesthesia, there was no significant difference in pain scores between the PNB and PNB-1 groups (P>0.05), but there was a significant difference in pain scores between the two groups at the time of puncture (P<0.05).Among them, the pain score for patients with a larger prostate volume in the PNB group was significantly higher than that for patients with a smaller prostate volume (P<0.05), whereas the pain score for patients with a different prostate volume in the PNB-1 group was not significantly different (P>0.05). Postoperative complications in the PNB-1 group were significantly less than those in the PNB group, and the postoperative urinary tract irritation sign was significantly less than that in the PNB group (P<0.05).

Conclusion:PNB-1 was a effective and safe anesthesia method, which could significantly reduce the pain during puncture biopsy, improve the anesthetic effect and provide the basis for puncture biopsy.

Background

With the incidence rate of prostate cancer(PCa) increasing, the number of prostate biopsies(PBx) were increasing every year, PBx was the most important method for diagnosing PCa[1–3]. The disadvantage of TPBx was poor pain control, and most of the pain in the prostate biopsy was derived from the prostate capsule[4].How to block the pain of the structure between the skin and the prostate capsule was the key to relieve the pain of TPBx.Nash et al.First reported in 1996 that anesthetics were injected into the area between the prostate and seminal vesicle, which could directly penetrate the neurovascular bundle and reduce the pain associated with TRUS guided prostate biopsy[5].PNB was the best anesthesia for prostate biopsy in the past decade[6–9].Further studies showed that PNB combined with perineal subcutaneous anesthesia and intra rectal lidocaine gel was a safer and more effective method for PBx local anesthesia,it could almost replace the total intravenous anesthesia[10, 11]. However, the anesthetic effect of some patients receiving PNB was still poor, especially some patients with large prostate volume still could not stand the pain during biopsy[12]. The main reason for the poor anesthetic effect of some PNB was that the anesthetic was mainly injected into the area between the prostate and seminal vesicle, which could not completely diffuse to the prostate puncture area[13]. In this study, anesthesia modified on the basis of PNB,by increasing the injection site of the anesthetic, the anesthetic could diffuse in the capsule area during prostate puncture, thereby reducing the pain of patients undergoing ultrasound-guided TPBx.

Methods

2.1.Patients and ethics

The patients who underwent ultrasound-guided TPBx from March 2019 to December 2021 in our hospital were retrospectively analyzed. Criteria for inclusion:Serum TPSA>4ng/ml or abnormal f/t;Prostatic lesions detected by MRI, ERUS and PET-CT;Lesions detected by digital rectal.Exclusion criteria: Abnormal cardiopulmonary function;Urinary tract infection;Anorectal disease or anal closure;Abnormal coagulation function and oral antiplatelet drugs.The study enrolled 910 patients who were divided into two groups according to their anesthesia method:PNB group (375 patients) and PNB-1 group (535 patients).(Fig.1). The clinical data such as age, height, weight, body mass index, prostate volume, hematuria,TPSA, FPSA, F/T, Gleason score, ISUP group,TNM staging and postoperative complications of the two groups were collected respectively.The study was approved by Institutional Review Board of Yunnan Cancer Hospital Hospital (KY201944).Informed consent was obtained from all individual participants included in the study. All procedures implemented in studies involving human participants were in accordance with the ethical standards of the institutional and/or national research committee, and with the 1964 Helsinki Declaration and its later amendments or comparable ethical standards.

2.3. Preoperative evaluation

The blood count, coagulation function, infection immunity, urinary routine, and the presence of cardiovascular and anal canal diseases were evaluated. An enema was performed two hours before the operation. The patient adopts the lithotomy position, fixes the scrotum upward, completely exposes the anus, and disinfects the perineum, anus, and anal canal area with disinfectant iodophor.

2.4.Anesthesia method

Patients were anesthetized with PNB between March 2019 and July 2020, and patients were anesthetized with PNB-1 between August 2020 and December 2021. All puncture and anesthesia processes were completed independently by two doctors. Each doctor had the basis of ultrasound-guided prostate biopsy for more than 5 years.

Peripheral nerve block were used 25ml anesthetic agents (5ml 2% lidocaine +20ml saline) ,and lidocaine gel was used in the rectum. Subcutaneous infiltration anesthesia is infiltration anesthesia from 9: 00 to 3: 00 under the perineum.

Anesthesia method of PNB:10ml anesthetic was injected into the area between prostate and seminal vesicle under the guidance of biplane ultrasound probe (BK profocus2202-8848), and the anesthetic was injected in the same way on the opposite side; Slowly inject 2.5ml anesthetic into the left and right puncture paths during needle withdrawal.

Anesthesia method of PNB-1：Firstly, 5ml anesthetic was injected into the space between the back of prostate and rectum under the guidance of biplane ultrasound(Fig.2.C.D);Secondly, 5ml anesthetic was injected into the space between the left side of prostate and levator ani muscle(Fig.2.E.F), and the anesthetic was injected in the same way on the opposite side; Finally, 5ml of anesthetic was injected into the area between the left side of the tip of the prostate and the rectum and levator ani muscle(Fig.2.G.H), and the anesthetic was injected in the same way on the opposite side.

2.5. Biopsy

18G×20cm biopsy needle was used for system biopsy or system+targeted biopsy[14]. The presence of hematuria, urinary tract irritation, fever and chills, and adverse reactions caused by lidocaine were evaluated within 4 hours after operation. The long-term complications of each patient were recorded 1 week after operation. The pathological diagnosis results of patients were recorded in time after operation.

2.6. Pain score

All patients were informed that they were given anesthesia pain score during the anesthesia, puncture biopsy and 30min after puncture, and they were told about the pain scoring standard of VAS. A doctor assistanted who did not know the type of nerve block asked and recorded the pain degree of each patient during local anesthesia, puncture biopsy and 30min after puncture. VAS was used as the evaluation standard[15, 16]: 0 score was no pain,scores of less than 3 was tolerable slight pain,4-6 scores were tolerable pain,7-10 scores were intolerable severe pain.

2.7. Statistical analysis

Statistical analysis uses IBM SPSS statistical software (version 21.0;IBM Corporation)for statistical analysis.Measurement data were expressed as x±s, count data were expressed as rate, and chi-square test was used for comparison between groups.$P<0.05$ was regarded as a statistically significant difference.

Results

1. Comparison of clinical baseline characteristics of patients

571 of 910 patients were PCa.Age, height, weight, body mass index, prostate volume, hematuria, TPSA, FPSA, F/T, Gleason score, ISUP group, and TNM stage were all counted for patients in the PNB and PNB-1 groups, respectively. There were significant difference in TPSA and FPSA between the two groups ($P < 0.05$), but there were no significant difference in other variables.(Tab.1).

2. Comparison of VAS scores

According to VAS score, 327 patients in PNB group had pain score of 0-3 and 48 patients had pain score of 4-6 during anesthesia; there were 223 patients with pain score of 0-3 and 152 patients with pain score

of 4-6 during puncture; one hour after puncture, the pain score of all patients was less than 3. In PNB-1 group, 457 patients had pain scores of 0-3 and 78 patients had pain scores of 4-6 during anesthesia; there were 514 patients with pain score of 0-3 and 21 cases with pain score of 4-6; one hour after puncture, the pain score of all patients was less than 3. There was no significant difference in pain score between PNB group and pnb-1 group during anesthesia ($P > 0.05$), but there was significant difference in pain score between PNB group and pnb-1 group ($P < 0.05$).(Tab.2).

The pain scores of patients with different prostate volume during anesthesia and puncture were compared between the two groups. There was no significant difference in the pain scores of patients with different prostate volume during anesthesia in PNB group and PNB-1 group ($P>0.05$). The patients with larger prostate volume in the PNB-1 group had higher pain scores during puncture, and the pain scores of patients with different prostate volumes were significantly different ($P<0.05$).There was no significant difference in pain score and prostate volume in PNB-1 group ($P>0.05$).(Tab.3).

3. Comparison of complications of puncture biopsy

Among 375 patients in PNB group,44(11.73%) had complications and 331(88.27%) had no complications. Among 535 patients in PNB-1 group,29(5.4%) had complications and 506(94.60%) had no complications.The incidence of postoperative complications in PNB-1 group was significantly lower than that in PNB group (11.73% vs 5.4%). There was significant statistical difference between the two groups (P 0.05).(Tab.4).

In PNB group, hematuria, infection, pain and urinary tract irritation were 17 cases, 1 case, 6 cases and 20 cases respectively.In PNB-1 group, hematuria, infection, pain and urinary tract irritation were 14 cases, 4 cases, 2 cases and 9 cases respectively. There was significant difference in urinary tract irritation between the two groups ($P<0.05$), and there were no significant difference in other complications.(Tab.5).

Discussion

In this study, we used PNB-1 anesthesia for prostate biopsy.Under the same anesthetic dose, the anesthetic effect of PNB-1 was significantly better than that of PNB. The proportion of patients with VAS score of 4–6 in PNB-1 group was significantly lower than that in PNB group (10.05% vs 40.53%). In addition, the anesthetic effect of PNB-1 was no longer affected by the prostate volume of patients, and also could provide more stable puncture anesthetic effect for patients with large prostate volume. Finally, the incidence of postoperative complications in the PNB-1 group was only half that in the PNB group (5.4% vs 11.3%).

The pain during prostate biopsy was mainly caused by the traction of the probe in the rectum and caused by the walking of the biopsy needle between the skin and the prostate capsule.Studies found that the sensory nerves of the prostate runed along the neurovascular bundles on both sides of the prostate capsule. Before entering the prostate, their branches entered the prostate at the bottom of the prostate and the lower ends of the seminal vesicles on both sides, and branch off to the apex of the

prostate[1].First, the overall anesthetic effect of PNB-1 was better than that of PNB. The main reason was that PNB anesthesia blocked the neurovascular bundles on the lateral side of the prostate capsule[17].While PNB-1 increased the injection site of anesthetic, and its nerve block was more extensive than PNB.Secondly, there was no significant difference in pain between prostate patients with different sizes in PNB-1 group at the beginning of anesthesia and biopsy, while there was no significant difference in pain between PNB and prostate patients with different sizes at the beginning of anesthesia, but the anesthetic effect of biopsy was poor in patients with larger prostate volume, which was consistent with previous studies[18].The main reason was that PNB-1 increased the injection of anesthetic in the area between the prostate capsule and the anal body muscle,the anesthetic injected in this gap could diffuse upward and outward to block the vascular and nerve bundles distributed above and outside the prostate apex,It could effectively reduced the pain caused by stimulation of the autonomic sensory nerve when the biopsy needle entered the prostate capsule.Finally,the overall incidence of complications between the PNB group and the PNB-1 group was statistically significant. Further analysis found that the incidence of urinary tract irritation in the PNB group was higher than that in the PNB-1 group, and the comparison between the two groups was statistically significant.The lower complication rate in the PNB-1 group was related to the reduction of the patient's pain during puncture, the technical proficiency of the puncture physician, and the increase in the number of needles for larger prostate puncture[19].Of course, we also analyzed the potential interference factors in the study and found that there was no difference between PNB-1 group and PNB group.The differences of age, height, weight, body mass index, prostate volume, hematuria, f/T, Gleason score, ISUP group, TNM stage and other variables between the two groups were excluded. Although There were significant difference in TPSA and FPSA between the two groups, it did not seem to affect the main results of the study.In conclusion, PNB-1 could effectively reduce the pain of transperineal prostate biopsy.

Accurately locating the peripheral nerve of the prostate was a critical step in PNB[20].In this study, the localization and injection sequence of PNB-1 followed: firstly, the anesthetic was injected into the space between the the prostate and the rectum, and the anesthetic was diffused throughout the space between the prostate and rectum.Secondly, the anesthetic was injected between the left and right sides of the prostate and the levator ani muscle[21]. The area between the apex of the prostate and the rectum is finally injected; the anesthetic was injected during the withdrawal of the needle.PNB was located in the area between prostate and seminal vesicle gland[13]. Compared with PNB-1, PNB puncture path was longer, and some prostate cancers growed irregularly[22], which increased the accuracy of localization.This study had some limitations.The individual pain threshold was not measured to minimize the impact of individual differences on the accuracy of the experiment. However, this study had a relatively sufficient sample size to reduce the experimental deviation caused by individual differences of patients, and subsequent studies will incorporate pain threshold determination. In addition, PNB-1 anesthesia in this study needed to be accurately injected into three anesthesia areas under the guidance of ultrasound, and the puncture doctor needed to be skilled in using ultrasound to avoid damaging the rectum and urethra during anesthesia.

The anesthesia method of PNB-1 could effectively reduce the pain of transperineal puncture biopsy, solve the problem of poor anesthesia effect in PNB in patients with larger prostate volume, and also reduce the incidence of complications after puncture and puncture. With the increase in the incidence of prostate cancer, effective local anesthesia can improve the success rate of needle biopsy and enable early diagnosis of prostate cancer.

Conclusion

Through the analysis of the anatomical structure of the prostate and the distribution of nerves,PNB-1 anesthesia can effectively reduce the pain of TPBx, solve the problem of poor anesthesia effect in PNB for patients with large prostate volume, reduce the incidence of complications after puncture, improve the success rate of biopsy.

Declarations

Availability of data and materials

All data generated or analysed during this study are included in this published article [and its supplementary information files].

Acknowledgements

The authors would like to thank Department of Ultrasound, the Third Affiliated Hospital of Kunming Medical University, Yunnan Cancer Hospital.

Funding

This study was funded by Science and Technology Project of Yunnan Provincial Science and Technology Department (grant no.2019FE001(-241)) and Training plan for medical discipline leaders of Yunnan Provincial Health Commission (grant no. D-2018009).

Author information

Affiliations

Dong Chen,Haitao Chen and Jiao Li contributed equally to this work.

Department of Ultrasound, the Third Affiliated Hospital of Kunming Medical University, Yunnan Cancer Hospital, Kunming,People’s Republic of China

Dong Chen,Haitao Chen,Zhirui Chuan.Yunying Wang,Hong yin Yang,Xiaomao Luo&Zhiyao Li

Department of Radiology, the Third Affiliated Hospital of Kunming Medical University, Yunnan Cancer Hospital, Kunming, Yunnan, People’s Republic of China

Zhi-qiang Ouyang&Chengde Liao

Department of Ultrasound,Children's Hospital Affiliated to Kunming Medical University, Kunming Children's Hospital, Kunming,People’s Republic of China

Jiao Li Contact us

Contributions

Dong Chen:data management,data analysis,manuscript writing/editing.Haitao Chen.Jiao Li:data collection, data analysis.Zhirui Chuan.Yunying Wang.Zhi-qiang Ouyang.Hong yin Yang:data collection data analysis. Xiaomao Luo.Zhiyao Li:project development.Chengde Liao:project development, manuscript editing.All authors read and approved the final manuscript.

Corresponding author

Correspondence to Chengde Liao,Xiaomao Luo or Zhiyao Li

Ethics approval and consent to participate

The study was approved by Institutional Review Board of Yunnan Cancer Hospital Hospital.Written informed consents were obtained from all participants. We confirm that all methods were performed in accordance with the relevant guidelines and regulations.

Consent for publication

Written consent to publish the attached was obtained from study participants, and the pdf of the consent was submitted as an additional file.

Competing interests

The authors declare that they have no competing interests

References

1. Nazir B. Pain during transrectal ultrasound-guided prostate biopsy and the role of periprostatic nerve block: what radiologists should know. Korean J Radiol. 2014;15(5):543–53.
2. Omer A, Lamb AD. Optimizing prostate biopsy techniques. Curr Opin Urol. 2019;29(6):578–86.

3. Stefanova V, Buckley R, Flax S, Spevack L, Hajek D, Tunis A, et al. Transperineal Prostate Biopsies Using Local Anesthesia: Experience with 1,287 Patients. Prostate Cancer Detection Rate, Complications and Patient Tolerability. J Urol. 2019;201(6):1121–6.
4. Stirling BN, Shockley KF, Carothers GG, Maatman TJ. Pain perception during transrectal ultrasound guided prostate needle biopsy: an objective analysis of local anesthesia use. Prostate Cancer Prostatic Dis. 2002;5(3):209–11.
5. Nash PA, Bruce JE, Indudhara R, Shinohara K. Transrectal ultrasound guided prostatic nerve blockade eases systematic needle biopsy of the prostate. J Urol. 1996;155(2):607–9.
6. Kim DK, Hah YS, Kim JW, Koo KC, Lee KS, Hong CH, et al. Is Pelvic Plexus Block Superior to Periprostatic Nerve Block for Pain Control during Transrectal Ultrasonography-Guided Prostate Biopsy? A Double-Blind, Randomized Controlled Trial. J Clin Med. 2019;8(4).
7. Kim DK, Lee JY, Jung JH, Hah YS, Koo KC, Lee KS, et al. What is the most effective local anesthesia for transrectal ultrasonography-guided biopsy of the prostate? A systematic review and network meta-analysis of 47 randomized clinical trials. Sci Rep. 2019;9(1):4901.
8. Ding XF, Luan Y, Wang F, Xu YZ, Guo CH, Zhu LY. The application of a targeted periprostatic nerve block in transperineal template-guided prostate biopsies. Quantitative Imaging in Medicine and Surgery. 2020;10(11).
9. Ding H, Ning Z, Ma H. Pelvic Plexus Block Versus Periprostatic Nerve Block for Ultrasound-Guided Prostate Biopsy: A Meta-Analysis. Front Oncol. 2021;11:655906.
10. Kim SJ, Lee J, An DH, Park CH, Lim JH, Kim HG, et al. A randomized controlled comparison between periprostatic nerve block and pelvic plexus block at the base and apex of 14-core prostate biopsies. World J Urol. 2019;37(12):2663–9.
11. Zhengtong L, Huichuan J, Xiheng H, Changzhao Y, Harripersaud C, Congyi T, et al. Efficacy and safety of periprostatic nerve block combined with perineal subcutaneous anaesthesia and intrarectal lidocaine gel in transrectal ultrasound guided transperineal prostate biopsy: A Prospective Randomised Controlled Trial. PROSTATE CANCER AND PROSTATIC DISEASES. 2020;23(1).
12. Yang L, Tian-Bao H, Xiao G, Guang-Chen Z, Sheng-Ming L, Hua-Zhi T, et al. Effect of prostate volume on the peripheral nerve block anesthesia in the prostate biopsy: A strobe-compliant study. Medicine (Abingdon). 2016;95(28).
13. Ingber MS, Ibrahim I, Turzewski C, Hollander JB, Diokno AC. Does periprostatic block reduce pain during transrectal prostate biopsy? A randomized, placebo-controlled, double-blinded study. Int Urol Nephrol. 2010;42(1):23–7.
14. Liu H, Ruan M, Wang H, Wang H, Li X, Song G. Can fewer transperineal systematic biopsy cores have the same prostate cancer detection rate as of magnetic resonance imaging/ultrasound fusion biopsy. Prostate Cancer Prostatic Dis. 2020;23(4):589–95.
15. Gurbuz C, Canat L, Bayram G, Gokhan A, Samet G, Caskurlu T. Visual pain score during transrectal ultrasound-guided prostate biopsy using no anaesthesia or three different types of local anaesthetic application. Scand J Urol Nephrol. 2010;44(4):212–6.

16. Hui D, Zhongyun N, Hongwu M. Pelvic Plexus Block Versus Periprostatic Nerve Block for Ultrasound-Guided Prostate Biopsy: A Meta-Analysis. Frontiers in Oncology. 2021;11.
17. Li M, Wang Z, Li H, Yang J, Rao K, Wang T, et al. Local anesthesia for transrectal ultrasound-guided biopsy of the prostate: A meta-analysis. Sci Rep. 2017;7:40421.
18. Gómez-Gómez E, Ramírez M, Gómez-Ferrer A, Rubio-Briones J, Iborra I, Carrasco-Valiente J, et al. Assessment and clinical factors associated with pain in patients undergoing transrectal prostate biopsy. Actas Urol Esp. 2015;39(7):414–9.
19. Leibovici D, Shilo Y, Raz O, Stav K, Sandbank J, Segal M, et al. Is the diagnostic yield of prostate needle biopsies affected by prostate volume. Urol Oncol. 2013;31(7):1003–5.
20. Maccagnano C, Scattoni V, Roscigno M, Raber M, Angiolilli D, Montorsi F, et al. Anaesthesia in transrectal prostate biopsy: which is the most effective technique. Urol Int. 2011;87(1):1–13.
21. Kubo Y, Kawakami S, Numao N, Takazawa R, Fujii Y, Masuda H, et al. Simple and effective local anesthesia for transperineal extended prostate biopsy: application to three-dimensional 26-core biopsy. Int J Urol. 2009;16(4):420–3.
22. Konyalioglu E, Tarhan H, Cakmak O, Pala EE, Zorlu F. Prostate cancer volume estimations based on transrectal ultrasonography-guided biopsy in order to predict clinically significant prostate cancer. Int Braz J Urol. 2015;41(3):442–8.

Tables

Table 1 Comparison of clinical and pathological characteristics of prostate cancer patients in PNB group andPNB-1 group

Variables	Total	PNB	PNB-1	c^2	*P*-value
Age(years)	68.70±8.390	68.75±8.546	68.67±8.287	85.620	0.196
Height(cm)	166.16±7.029	166.34±6.090	166.16±7.029	32.692	0.995
Weight(kg)	62.80±9.427	62.23±9.512	63.20±9.355	60.227	0.959
BMI				6.063	0.109
<18.5	79	40（10.67%）	39（7.29%）		
18.5-24	537	226（60.27%）	311（58.13%）		
24-28	248	89（23.73%）	159（29.72%）		
≥28	46	20（5.33%）	26（4.86%）		
Prostate volume mL				0.494	0.920
（40	300	123（32.8%）	177（33.02%）		
40-60	228	91（24.27%）	137（25.56%）		
60-80	148	60（16.0%）	88（16.42%）		
（80	235	101（26.93%）	134（25.0%）		
TPSA level （ng/mL）				7.197	0.007
≤10	280	97（25.87%）	183（34.21%）		
（10	630	278（74.13%）	352（65.79%）		
FPSA level （ng/mL）				11.087	0.001
≤0.93	176	53（14.13%）	123（22.99%）		
（0.93	734	322（85.87%）	412（77.01%）		
F/T				0.050	0.822
（0.25	801	329（87.73%）	472（88.22%）		
0.25-1.0	109	46（12.27%）	63（11.78%）		
Gleason score				4.481	0.214
≤6 score	29	12（5.0%）	17（5.52%）		
3+4 score	57	32（13.33%）	25（8.12%）		

4+3 score	78	36（15.0%）	42（13.64%）		
≥8 score	384	160（66.67%）	224（72.73%）		
ISUP group				5.406	0.248
1	29	12（5.06%）	17（5.52%）		
2	57	32（13.5%）	25（8.12%）		
3	78	36（15.19%）	42（13.64%）		
4	237	94（39.66%）	143（46.34%）		
5	144	63（26.58%）	81（26.3%）		
Hematuria				0.345	0.557
Yes	255	109（29.07%）	146（27.29%）		
No	655	266（70.93%）	389（72.71%）		
Pathology				3.540	0.060
Benign	341	123（32.80%）	214（40.0%）		
malignant	569	252（67.20%）	321（60.0%）		

Table 2 Comparison of VSA scores of PNB group and PNB-1 group during anesthesia and puncture biopsy

	VAS scores		c2	*P*-value
	0-3	4-6		
Anesthesia			0.585	0.444
PNB	327（82.2%）	48（12.8%）		
PNB-1	457（85.26%）	78（14.74%）		
Puncture biopsy			191.897	0.000
PNB	223（59.47%）	152（40.53%）		
PNB-1	514（97.07%）	21（10.05%）		

Table 3 Comparison of pain scores of patients with different prostate volume in PNB group and PNB-1 group during anesthesia and puncture biopsy

	VAS scores		c^2	P-value
	0-3	4-6		
Anesthesia				
PNB			2.107	0.550
≤40	111（29.60%）	12（3.20%）		
40-60	78（20.80%）	13（3.50%）		
60-80	53（14.13%）	7（1.90%）		
≥80	85（22.67%）	16（4.20%）		
PNB-1			5.741	0.125
≤40	153（28.60%）	24（4.50%）		
40-60	109（20.37%）	28（5.20%）		
60-80	76（14.20%）	12（2.20%）		
≥80	119（22.24%）	14（2.80%）		
Puncture biopsy				
PNB			17.319	0.001
≤40	90（24.00%）	33（8.80%）		
40-60	52（13.87%）	39（10.40%）		
60-80	26（6.94%）	34（9.06%）		
≥80	55（14.66%）	46（12.27%）		
PNB-1			0.710	0.871
≤40	169（31.59%）	7（1.30%）		
40-60	131（24.49%）	6（1.12%）		
60-80	86（16.07%）	2（0.38%）		
≥80	129（24.12%）	5（0.93%）		

Table 4 Comparison of postoperative complications between PNB group and pnb-1 group

	PNB	**PNB-1**	c^2	*P*-value
Complication	44(11.3%)	29(5.4%)	11.907	0.001
Non complication	331（88.27%）	506（94.60%）		

Table 5 Comparison of postoperative complication subtypes between PNB group and pnb-1 group

	PNB	PNB-1	c^2	*P*-value
Bleeding	17	14	2.461	0.117
Non bleeding	358	521		
Infection	1	4	0.933	0.334
Non infection	374	531		
Pain	6	2	3.804	0.051
Non pain	369	533		
Urinary tract irritation	20	9	9.980	0.002
Non urinary tract irritation	346	526		

Figures

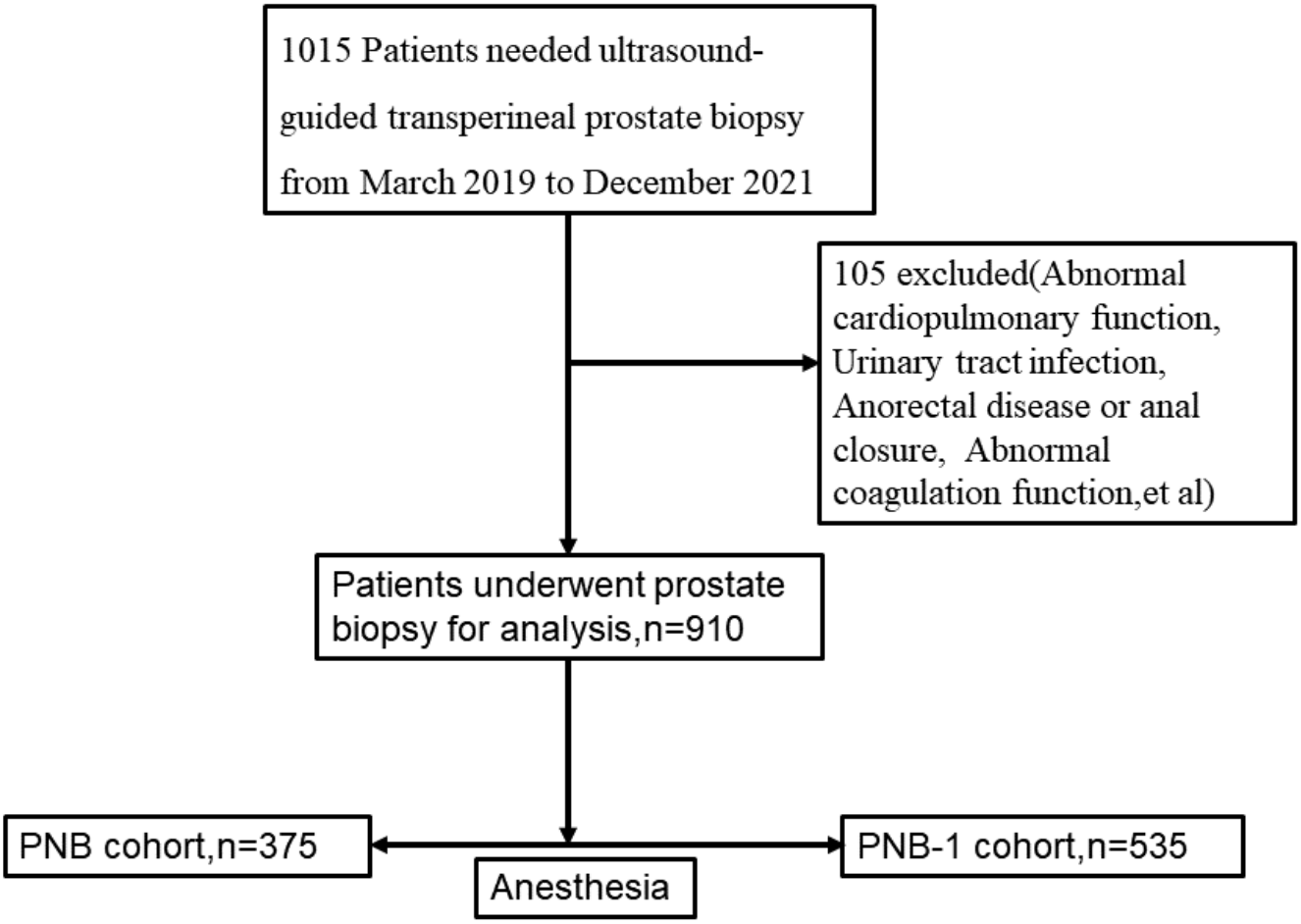

Figure 1

Flow chart for patients of PNB cohort and PNB-1 cohort

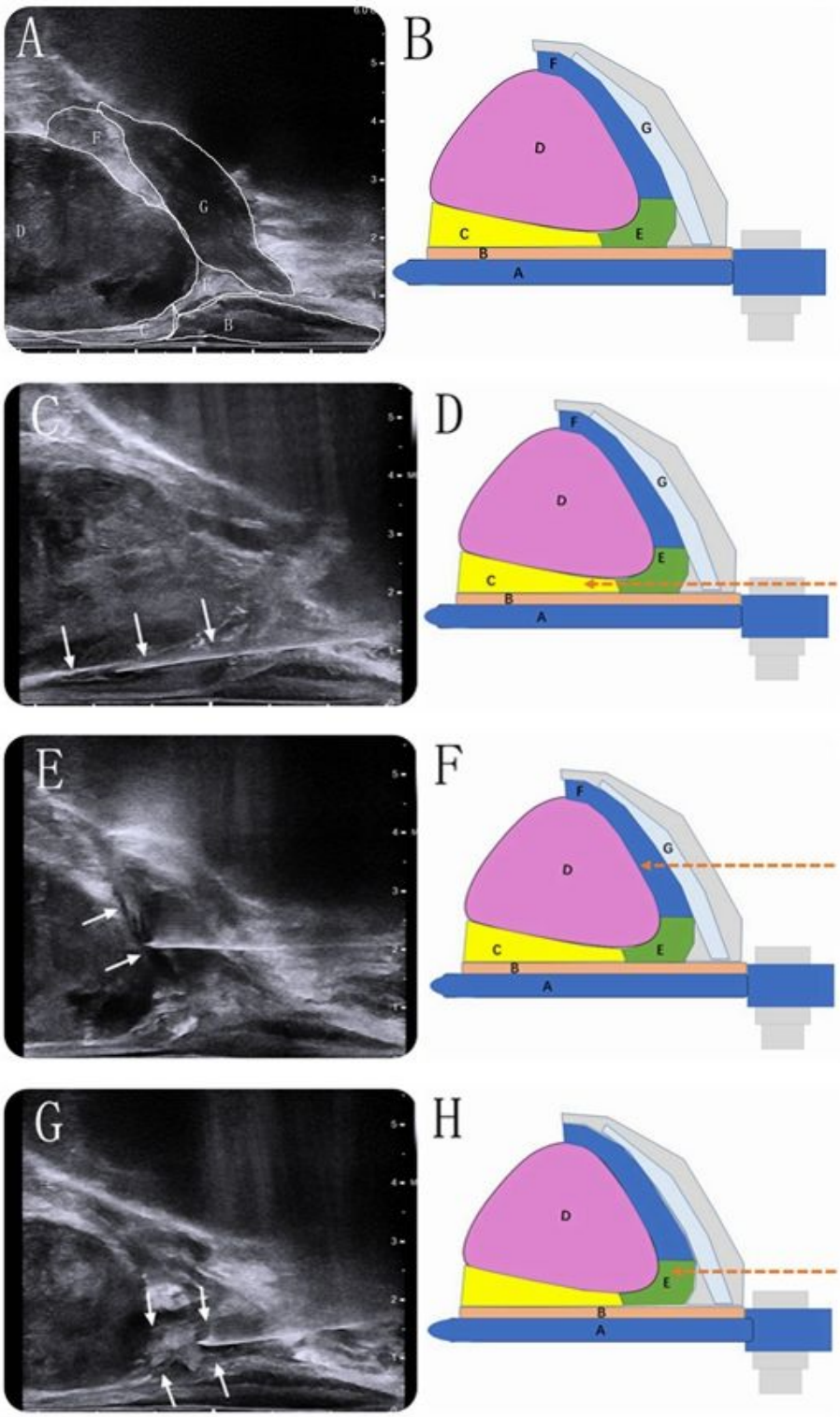

Figure 2

Ultrasonic image and schematic diagram of anesthesia

Fig.A and Fig.B:A was the intracavity probe,B was the anterior wall of rectum,C was the space between prostate and rectum,D was prostate, E was the space between prostate tip and rectum,F was the space between prostate and levator ani muscle, and G was levator ani muscle.Fig.C:anesthetics were injected into the space between prostate and rectum under ultrasound guidance.Fig.D:area C was the space between prostate and rectum.Fig.E:anesthetics were injected into the space between prostate and levator ani muscle under ultrasound guidance.Fig.F:Area F was the space between prostate and levator ani muscle.Fig.G:Anesthetics were injected into the tip of the prostate and the rectum under ultrasound guidance.Fig.H:Area F was the tip of the prostate and the rectum.