Application of intracardiac echocardiography in the radiofrequency ablation of atrial fibrillation

feng xue (szlongman@126.com)
First Affiliated Hospital of Soochow University https://orcid.org/0000-0001-8042-2139

Yunjuan Sun
First Affiliated Hospital of Soochow University

ling lin
First Affiliated Hospital of Soochow University

Fangfang Zhang
First Affiliated Hospital of Soochow University

Shasha Zhu
First Affiliated Hospital of Soochow University

Xiao Guo
First Affiliated Hospital of Soochow University

Shuhuan Wang
First Affiliated Hospital of Soochow University

Ming Liu
First Affiliated Hospital of Soochow University

Jie Hui
First Affiliated Hospital of Soochow University

tingbo Jiang
First Affiliated Hospital of Soochow University

Research Article

Keywords: intracardiac echocardiography, atrial fibrillation, radiofrequency ablation

Posted Date: June 3rd, 2022

DOI: https://doi.org/10.21203/rs.3.rs-1640965/v1

Abstract

Background Intracardiac echocardiography (ICE) has been used in the radiofrequency ablation of arrhythmia since 1994. This study investigated the efficacy and safety of ICE assiting the ablation of atrial fibrillation.

Methods From May 2020 to February 2021, 100 patients with atrial fibrillation underwent radiofrequency ablation assisted by ICE and three-dimensional mapping system. They were enrolled in ICE group. In the same period, 100 patients with atrial fibrillation who only received radiofrequency ablation assisted by three-dimensional mapping system were enrolled in control group. The patients were followed up and the fluoroscopy times, complications and success rates were compared.

Results 1. The X-ray fluoroscopy times in ICE group was significantly shorter than that in control group. In ICE group there was no pericardial tamponade during atrial septal puncture. But in control group there were three cases of pericardial tamponade during atrial septal puncture; 2. The injury of vagus nerve around esophagus in ICE group was significantly less than that in control group; 3. There was no significant difference in the success rate between the two groups.

Conclusions ICE can significantly increase the safety of the radiofrequency ablation of atrial fibrillation.

Background

Since the 1980s, many tachyarrhythmias can be cured by radiofrequency ablation. However, with the development of this technology, many electrophysiology doctors still have the feeling of "blind man touching an elephant" in the face of abnormal cardiac structure or arrhythmia originating from special structure. Although X-ray can assist the positioning of catheter, it is very harmful to human body. In addition, it cannot distinguish some complex structures inside the heart. In 1994, the first article about a successful ablation on arrhythmia guiding by intracardiac echocardiography (ICE) came out [1]. The ICE probe is placed inside the heart cavity without air interference. It has high space and time resolution in the blood. It is superior to any other imaging technology in the display of cardiac tissue characteristics and structure. In this study, ICE assisting radiofrequency ablation of 100 cases of atrial fibrillation were used to explore its clinical value.

Methods

Study populations

From May 2019 to February 2021, 200 patients with atrial fibrillation received radiofrequency ablation in our center. 100 patients who received ICE and carto3 three-dimensional mapping system assisted ablation were in ICE group. There were 51 cases of paroxysmal atrial fibrillation (PAF), 49 cases of persistent atrial fibrillation (AF). 100 patients who only received radiofrequency ablation assisted by Carto3 three-dimensional mapping system served as the control group. There were 53 cases of PAF, 47

cases of AF. The basic clinical characteristics of the two groups are shown in Table 1. 199 patients underwent routine ECG, ambulatory ECG, transthoracic echocardiography and coronary CT angiography. 198 patients underwent transesophageal echocardiography to eliminate left atrial appendage thrombosis. One patient in ICE group did not undergo coronary CT angiography due to renal insufficiency, and two patients did not undergo transesophageal echocardiography due to intolerance.

Table 1
Clinical Characteristics of Patients

characteristics	ICE group	Control group	*P* value
Patients(cases)	100	100	1
Gender(man/woman)(cases)	63/37	63/37	1
age(years)	61.49 ± 11.98	59.32 ± 12.26	0.18
Hypertension(cases)	68	58	0.143
Diabetes mellitus(cases)	12	10	0.651
organic heart diseases(cases)	20	13	0.182
PAF(cases)	51	53	0.777
AF(cases)	49	47	
anterior posterior diameter of left atrium(cm)			
PAF	41.43 ± 5.78	40.36 ± 3.89	0.337
AF	46.46 ± 3.34	44.16 ± 5.86	0.043

Instruments and methods

1. Soundstar three-dimensional intracardiac ultrasound catheter (Biosense Webster, Diamond Bar, CA, USA) is with an outer diameter of 10F and a probe frequency of 10MHz. The catheter is respectively connected with portable ultrasonic machine (vid-q, American general company) and Carto3 three-dimensional electrophysiological mapping system (Biosense Webster, Diamond Bar, CA, USA) which is equipped with special software (Cartosound). There are 4 knobs for bending the catheter forward (A), backward(P), rightward (R), and leftward (L). Send it into the right atrium through the femoral vein. If the blood vessel is tortuous, slightly turn forward and send it up. First, show the most basic view (homeview, Fig. A), which is composed of tricuspid valve, right ventricle and a small part of right ventricular outflow tract. Other views are derived from the homeview by adjusting the ultrasonic catheter. If the position of the ultrasound catheter and the heart cavity structure in the view are not clear, it is necessary to return to the homeview. Before ultrasonic modeling, it is necessary to bend forward to make it close to the interval, and then do respiratory gating. After success the bend is loosen and the ultrasound catheter is rotated clockwise gradually. Then these structures such as the atrial septum, left atrial appendage, left atrium, left upper pulmonary vein, left lower pulmonary vein,

left atrial posterior wall, esophagus, descending aorta and right pulmonary vein can be displayed in turn. The anatomical structures related to atrial arrhythmia can be seen at a glance.

2. Patients with atrial fibrillation should receive transseptal puncture. Between two groups there was obviously difference in this step. Patients in ICE group underwent atrial septal puncture with the aid of ICE. when the left superior pulmonary vein and the left inferior pulmonary vein appeared simultaneously in the same view (Rabbit Ear Sign, Fig. B), the needle was taken out to puncture the atrial septum. Then a tenting phenomenon (Tenting Sign, Fig. B) could be seen. After the successful puncture the star mapping electrode (PentaRay, Biosense Webster, Diamond Bar, CA, USA) was sent into the left atrium for modeling again and fusion with the ultrasound model. The patients with atrial arrhythmia in control group underwent atrial septal puncture with the aid of X-ray and sent the catheter to the left atrium.
3. Thermocool SmartTouch catheter (Biosense Webster, Diamond Bar, CA, USA) was used for radiofrequency ablation under the guidance of Carto3 three-dimensional electrophysiological mapping system.
4. Postoperative treatment and follow-up: Patients with atrial fibrillation had taken antiarrhythmic drugs and anticoagulants for 3 months routinely. After 3 months they received 48 hour ambulatory electrocardiogram and transthoracic echocardiography. If there was no atrial arrhythmia for more than 30 seconds, They stopped taking antiarrhythmic drugs. Whether they continued to take the anticoagulants depended on the CHA_2DS_2-VASc score. If the score was ≥ 2, the patient should take an anticoagulant for life. If there was atrial arrhythmia lasting for more than 30 seconds, it was recommended to receive ablation twice.

Statistical analysis

Statistical analyses were conducted with SPSS, version 23.0 (SPSS Inc., Chicago, IL). All non-numeric variables were reported as percentages, and all numeric variables were presented as mean ± SD. The differences between 2 numeric variables were analyzed by independent samples *t*- test. χ^2 test or four grid table exact probability method was used to analyzed the difference between 2 non-numeric variables. When the theoretical number was less than 5, the corrected χ^2 test was used. Statistical significance was defined as a 2-sided *P* value ≤ 0.05 for all analyses.

Results

1. Intraoperative conditions

The X-ray fluoroscopy time in ICE group was significantly shorter than that in control group (2.65 ± 1.98min vs 6.33 ± 1.89min, $P < 0.01$). Among patients in ICE group, there were 2 cases with flat and narrow left atrium, 1 case with ascending aortic aneurysm, 1 case with dextrocardia, 3 cases with atrial septal thickening, 2 cases with atrial septal bulge. There were no pericardial tamponade during atrial septal puncture in ICE group. There were 3 cases of pericardial tamponade in control group. Pericardial

effusion was found during ablation in one patient with paroxysmal atrial fibrillation in ICE group (Fig. C). The patient pulled through after the pericardial puncture .

2. Postoperative conditions (Tables 2 and 3)

Table 2
Follow-up

characteristics	ICE group	Control group	*P* value
Missing cases			
AF	5	10	0.135
PAF	6	11	0.215
Recurrent cases			
AF	11	10	0.89
PAF	3	7	0.32

Table 3
Complications

Complications	ICE group	Control group	*P*
pericardial tamponade	1	3	0.621
arteriovenous fistula	2	3	1
pseudoaneurysm	0	1	1
hematoma	3	2	1
peripheral esophageal vagus nerve injury	9	21	0.017

There was no significant difference in intraoperative and postoperative complications such as pericardial tamponade and vascular access-related complications which includes hematoma, femora artery pseudoaneurysm and arteriovenous fistula between the two groups. But the symptoms of peripheral esophageal vagus nerve injury such as nausea and vomiting were significantly increased in control group. All patients were followed up for one year. 11 people in ICE group were lost to follow-up, including 5 patients with AF, 6 patients with PAF. 21 people in control group were lost to follow-up, including 10 patients with AF, 11 patients with PAF. There was no difference between the two groups. The success

rates of PAF, AF in ICE group were 93%, 75%, respectively. The success rates of PAF, AF in control group were 83%, 73%. There was no difference between the two groups.

Discussion

The advantage of ICE-assisted ablation is obvious. Through the rotation, advance, retreat and bending of ultrasonic catheter, the heart structure and the adhesion between catheter and tissue can be seen at a glance. ICE combining with Carto3 is even more powerful. It can directly establish a three-dimensional model of the heart on the electrophysiological mapping system, so as to guide the operator to operate the catheter under very low radiation quantity[2]. The author's personal experience is that the learning curve of ICE manipulation is significantly shorter than that of ablation catheter manipulation. Therefore both the popularity of this technology and the accuracy of the cardiac cavity model constructed by ICE is high. Combining with the pressure sensing catheter, the catheter can be safely and smoothly sent to any position of the cardiac cavity under zero ray. It greatly reduces radiolesion. If the patient cannot receive coronary CT angiography or esophageal ultrasonography for some reason before operation, he can choose ICE to assist radiofrequency ablation of atrial fibrillation. ICE can clearly display the left atrial structure and exclude of thrombus[3].

Can the mapping and ablation that guided by ICE improve the success rate of ablation? Fei et al. concluded through the follow-up of 110 patients with PAF receiving ablation that ICE has no advantage in effectiveness [4]. Our study showed that the ablation success rate in ICE group was higher than that in control group, but there was no significant difference. We believe that one of the reasons is that after the application of ICE, the puncture point of atrial septum is ideal, which is convenient for the manipulation of ablation catheter. Because of this there are relatively few leakage points. The second reason is that the atrial model built by ICE has high simulation. These are two reasons why the ablation success rate was higher in ICE group. But in our study the size of the left atrium of AF patients in ICE group was larger than that of AF patients in control group. A meta-analysis of 22 clinical studies which related to atrial fibrillation ablation from 2004 to 2011 concluded that the enlarged left atrium significantly increased the recurrence rate of atrial fibrillation after radiofrequency ablation [5]. Therefore, our study shows that ICE assisted radiofrequency ablation of atrial fibrillation can improve the success rate, but its advantage is still limited by the size of the left atrium.

Improper atrial septal puncture is the main cause of pericardial tamponade during catheter ablation of atrial fibrillation. In 2007, the literature reported that the incidence of pericardial tamponade in the perioperative period of atrial fibrillation radiofrequency ablation was 3% [6]. In 2013, aldhoon et al reported that the incidence of pericardial tamponade during perioperative period of radiofrequency ablation of atrial fibrillation with ICE was only 0.25% [7]. Due to the application of ICE the operator can look directly at the atrial septum and puncture the septum when the Tent Sign and Rabbit Ear Sign appear, so as to avoid damaging the aorta, the posterior wall of the left atrium or the left atrial appendage. For patients with anatomical abnormalities, such as flat and narrow left atrium (anterior and posterior diameter < 30mm), aortic aneurysm, dextrocardia, atrial septal thickening or atrial septal bulge,

ICE ensures the correctness of puncture and facilitates the subsequent catheter ablation. Similar patients were also encountered in this study. All patients successfully punctured the atrial septum under the guidance of ICE. No complication occurred during atrial septal puncture in ICE group. In control group, 3 cases had pericardial tamponade at this time. In addition, during radiofrequency ablation ICE being sent into the right ventricle can be used to monitor and detect pericardial effusion in real time. In this study, one patient in ICE group was found pericardial effusion after right upper pulmonary vein supplementary ablation, but the patient had no obvious discomfort and abnormal vital signs. If there was no ICE, the complication would not be noticed in time. The patient recovered after pericardiocentesis. Although the diameter of ICE catheter was 10F, the complications caused by femoral vein puncture showed no difference between the two groups.

The safety of ICE is also reflected in its ability to display the relationship between esophagus and posterior wall of left atrium in real time during ablation. The esophagus is located behind the left atrium and 3.3-13.5mm away from the atrium. Whether the esophagus is left or right behind the left atrium can be determined by cardiac CT or MRI before operation, but the positional relationship between the esophagus and the left atrium may change during atrial fibrillation ablation [8]. ICE can observe the position of the two in real time during ablation, which is also a more reliable means to observe the position relationship between the esophagus and the posterior wall of the left atrium during atrial fibrillation ablation. In this study, the position of the esophagus was marked on the posterior wall of the model of the left atrium of every patient in ICE group. Its relationship with the left and right pulmonary veins was clear at a glance. During ablation, the ablation power and time were appropriately reduced near the esophagus, so as to reduce the damage to the esophagus. Therefore after atrial fibrillation ablation cases with injuries of peripheral esophageal vagus nerve in ICE group were less than that in control group.

Conclusions

ICE can significantly increase the safety of the radiofrequency ablation of atrial fibrillation. Its effect on the success rate of ablation need more lage-sample studies.

Abbreviations

ICE Intracardiac echocardiography

PAF paroxysmal atrial fibrillation

AF atrial fibrillation

Declarations

Ethics approval and consent to participate

This study's ethics approval was approved by the Ethics Committee of the first affiliated Hospital of Suzhou University [No. 091(2022)]. All written informed consent was obtained from all patients.

Consent for publication

Not applicable

Availability of data and materials

The datasets used and/or analysed during the current study are available from the corresponding author on reasonable request.

Competing interests

There are no financial or non-financial interests that are directly or indirectly related to the work submitted for publication.

Funding

H211252, Horizontal Project of Soochow University

The founder financed the study such as literature search and paper publishing fee.

Authors' contributions

The first five authors were electrophysiology doctors who took part in the ablation. XG,SW and MLwere techincians who assited the operation. JH and TJ were instructors of the operation. All authors have read and approved the manuscript.

Acknowledgements

Not applicable

References

1. Chu E, Kalman JM, Kwasman MA, et al. Intracardiac echocardiography during radiofrequency catheter ablation of cardiac arrhythmias in humans[J]. J Am Coll Cardiol. 1994;24(5):1351-1357. DOI: 10.1016/0735-1097(94)90119-8.

2. Jan M, Zizek D, Kuhelj D, et al. Jan M, Zizek D, Kuhelj D, et al. Combined use of electro-anatomic mapping system and intracardiac echocardiography to achieve zero-fluoroscopy catheter ablation for treatment of paroxysmal atrial fibrillation: a single centre experience. Int J Cardiovasc Imaging. 2020 ;36(3):415-422. DOI: 10.1007/s10554-019-01727-1.
3. Baran J, Stec S, Pilichowska-Paszkiet E, et al. Intracardiac Echocardiography for Detection of Thrombus in the Left Atrial Appendage—Comparison With Transesophageal Echocardiography in Patients Undergoing Ablation for Atrial Fibrillation: The Action-Ice I Study. Circ Arrhythm Electrophysiol. 2013;6(6):1074-1081. DOI: 10.1161/CIRCEP.113.000504.
4. Hang F, Cheng L, Liang Z, et al. Study on the Curative Effect and Safety of Radiofrequency Catheter Ablation of Paroxysmal Atrial Fibrillation via Zero-Fluoroscopy Transseptal Puncture under the Dual Guidance of Electroanatomical Mapping and Intracardiac Echocardiography. Cardiol Res Pract. 2021:5561574. DOI: 10.1155/2021/5561574.
5. Zhuang J, Wang Y, Tang K, et al. Association between left atrial size and atrial fibrillation recurrence after single circumferential pulmonary vein isolation: a systematic review and meta-analysis of observational studies. Europace. 2012;14(5):638-45. DOI: 10.1093/europace/eur364.
6. strong> Calkins H, Brugada J, Packer DL, et al. HRS/EHRA/ECAS expert consensus statement on catheter and surgical ablation of atrial fifibrillation: recommendations for personnel, policy, procedures and follow-up[J].Heart Rhythm 2007;4(6):816–861. DOI 10.1016/j.hrthm.2007.04.005.
7. Aldhoon B, Wichterle D, Peichl P, et al.Complications of catheter ablation for atrial fibrillation in a high-volume centre with the use of intracardiac echocardiography[J]. Europace. 2013;15(1):24-32. DOI: 10.1093/europace/eus304.
8. Gupta T, Cheema N, Randhawa A, et al. Translational anatomy of the left atrium and esophagus as relevant to the pulmonary vein antral isolation for atrial fibrillation[J]. Surg Radiol Anat. 2020;42(4):367-376. DOI: 10.1007/s00276-019-02327-3.

Figures

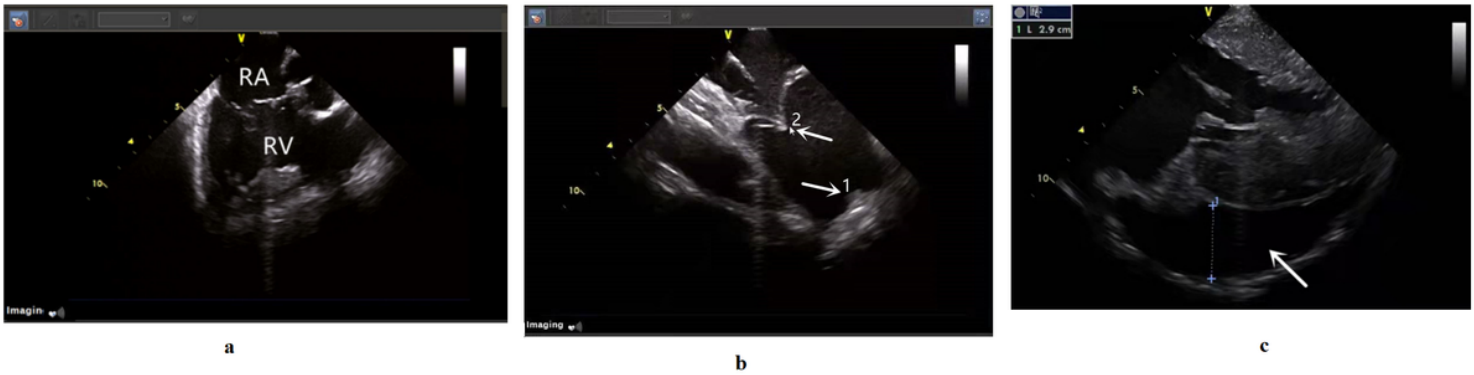

Figure 1

a. home view RA:right atrium RV:right ventricle

b. 1.Rabbit Ear Sign 2.Tenting Sign

c. cardiac tamponade

the arrow pointing to a large amount of pericardial effusion