The Relationship of T2 Hypointensity and Diffusion Restriction of Brain Metastases with the Presence and Amount of Vasogenic Edema in Magnetic Resonance Imaging

Ezel Yaltırık Bilgin (ezelyaltirik@yahoo.com)
Ankara Onkoloji Eğitim ve Araştırma Hastanesi
Özkan Ünal
Ankara Onkoloji Eğitim ve Araştırma Hastanesi
Nazan Çiledağ
Ankara Onkoloji Eğitim ve Araştırma Hastanesi

Research Article

Keywords: Brain edema, metastatic disease, brain metastasis, magnetic resonance imaging, brain neoplasms

Posted Date: May 23rd, 2022

DOI: https://doi.org/10.21203/rs.3.rs-1649107/v1

Abstract

Brain metastases are seen in 15–40% of patients diagnosed with cancer. We aimed to search the relationship between the T2 hypointensity, diffusion weighted imaging characteristics and the presence and amount of vasogenic edema of Brain metastasis in Magnetic Resonance Imaging (MRI). 292 patients with brain metastasis were included in the study. T2 signals of metastatic lesions, accompanying diffusion restriction and perilesional vasogenic edema findings were investigated. In metastases accompanied by vasogenic edema, the largest dimension of the vasogenic edema-mass complex on T2-weighted sequences and the largest dimension of the mass in contrast-enhanced T1-weighted series were measured and the edema-mass ratio (EMR) was calculated by comparing these two values.The incidence of vasogenic edema was statistically significantly higher in T2 hypointense metastases*(89.1% vs 58.8%, $\chi 2 = 18.949$, $p = < 0.001$)* and metastases accompanied by diffusion restriction*(81% vs 61.5%, $\chi 2 = 6.971$, $p = 0.008$)*. EMR value were found to be statistically significantly higher in T2 hypointense metastases *(EMR→ $Z=-4.507$, $p = < 0.001$)* and metastases with diffusion restriction*(EMR→ $Z=-3.819$, $p = 0.001$).* The incidence of vasogenic edema and EMR rates were higher in patients in T2 hypointense metastases and metastases accompanied by diffusion restriction in MRI.

Introduction

Although most of them are asymptomatic, brain metastases are seen in 15–40% of patients diagnosed with cancer(1). Conventional MR examination (MRI) is an imaging method with high sensitivity in the diagnosis of brain metastases and evaluation of response to treatment.

Although diffusion-weighted MR(DWI) imaging of the brain is primarily used for the diagnosis of acute infarction in the brain, it is also widely used in the evaluation of tumor pathology in the neuro-oncology field (2). Specifically, DWI-derived ADC values have been shown to correlate with tumor cellularity, grade and treatment response(3).

Most brain metastases are hyperintense on T2-weighted series and hypointense on T1-weighted imaging. Studies have suggested that the T2 hypointensity seen in brain metastases is due to the natural T2 effect associated with calcium, mucin and iron(4). In addition, there are publications in the literature that associate T2 hypointensity with the degree of tumor differentiation(5).

Some metastases may be accompanied by vasogenic edema. It has been concluded in the studies that accompanying vasogenic edema is independent of the size of the lesion (6).

In the studies in the literature, the pathogenesis of the T2 hypointensity, diffusion restriction and the amount of vasogenic edema in metastases could not be clearly presented. In our study, we aimed to search the relationship between the T2 hypointensity, diffusion characteristics and the presence and amount of vasogenic edema.

Methods

Patient Population and Study Design

Local ethics committee approval was gained (2021-12/23). Informed consent was received from the patients before contrast-enhanced imaging.

The clinical information and MRI examinations of 480 patients who had contrast-enhanced MRI due to brain metastasis in our radiology clinic between 07/2017-10/2021 were evaluated retrospectively. Among these patients, those who did not have MRI before treatment (surgery or chemoradiotherapy), whose clinical information could not be reached, who could not be diagnosed with primary cancer, who had neurodegenerative disease and who received corticosteroid therapy for any reason were excluded from the study.

292 patients were included in the study. Demographic characteristics of the patients, T2 signals of metastatic lesions, diffusion characteristics, ADC values and perilesional vasogenic edema were investigated

Lesions with hypointense T2-signals relative to the contralateral brain parenchyma were considered T2 hypointense lesions. Lesions with suspected bleeding and calcification were excluded by evaluating CT examination.

Restricted diffusion term is used for lesions showing ADC(mean) values less than 1.14×10^{-6} mm^2/s on the ADC map(6).

In metastases accompanied by vasogenic edema, the largest dimension of the vasogenic edema-mass complex on T2-weighted sequences and the largest dimension of the mass in contrast-enhanced T1-weighted series were measured and the edema-mass ratio (EMR) was calculated by comparing these two values (Fig. 1). In patients with multiple metastases EMR measurement and characterization were performed from the largest lesion.

MRI examinations of the patients were evaluated by 2 radiologists with more than 10 years of MRI experience. In case of disagreement, the evaluation was repeated and a joint decision was made.

Statistical Analysis

While evaluating the findings of the study, SPSS (Statistical Package for the Social Sciences) version 25.0 (IBM Corp., Armonk, NY, USA) program was used for statistical analyses. Descriptive statistics methods (number, percentage, median, etc.) were used to evaluate the study data. Whether the data showed normal distribution or not was evaluated with the Kolmogorov Smirnov test. Quantitative comparisons between groups were made by using the Mann-Whitney U-test and the Kruskal-Wallis H-test. Bonferroni correction was used to determine which groups the difference originated from in more than two-group comparisons. In qualitative comparisons between groups, Chi-square tests *(Pearson Chi-Square Test, Continuity Correction Test, and Fisher's Exact Test)* were used. Logistic and linear regression analyses were used to determine the independent factors associated with the presence of vasogenic

edema and EMR. The results were evaluated within a 95% confidence interval, and significance was evaluated at $p < 0.05$ level.

Results

The mean age of 292 patients with brain metastasis was 59.80 ± 11.47 years and 54.1% (n = 158) of the patients were male.

Of the patients with brain metastasis, 29.5% (n = 86) had a primary tumor of the breast, 50% (n = 146) of the lung, 3.1% (n = 9) of the head and neck, and 4.8% (n = 14) of the digestive system. It was determined that 7.2% (n = 21) were urogenital, 3.8% (n = 11) were skin (malignant melanoma) and 1.7% (n = 5) were from other localizations.

It was found that 65.4% (n = 191) of patients had vasogenic edema with metastases. In patients with edema the mean edema- mass ratio (EMR) was 1.80 ± 0.85.

Diffusion restriction was found in 19.9% (n = 58) of the metastases, and T2- hypointensity was found in 21.9% (n = 64) of the metastases on T2-weighted sequences.

The incidence of vasogenic edema was statistically significantly higher in metastases accompanied by diffusion restriction. *(81% vs 61.5%, $\chi 2 = 6.971$, $p = 0.008$)*.

The incidence of vasogenic edema was statistically significantly higher in T2-hypointense metastases. *(89.1% vs 58.8%, $\chi 2 = 18.949$, $p = < 0.001$)(*Table 1*).*

Table 1
Presence of Vazogenic Edema

			Presence of vasogenic edema	*χ2*	*p*
Diffusion Restriction	+	58	47(81%)	**6.971[b]**	**0.008***
	-	234	144(61.5%)		
T2 Hypointensity	+	64	57(89.1%)	**18.949[b]**	**< 0.001***
	-	228	134(58.8%)		
*=p < 0.05, χ2 **=** Chi-Square Tests *(*b = *Continuity Correction)*					

In metastases with diffusion restriction, the diameter of the edema mass complex and the EMR value were found to be statistically significantly higher. *[(Edema mass complex diameter→Z=-3.485, p = < 0.001), (EMR→ Z=-3.819, p = 0.001)].*

In T2-hypointense metastases, the diameter of the edema mass complex and EMR values were found to be statistically significantly higher. *[(Edema mass complex diameter→ Z=-3.240, p = 0.001) and (EMR→ Z=-4.507, p = < 0.001)].(*Table 2*).*

Table 2
Edema-Mass Ratio(EMR)

	n	EMR	P value
Difusion Restriction			**< 0.001[a]***
+	58	2.19(0.98)	
-	234	1.70(0.79)	
T2 Hypointensity			**< 0.001[a]***
+	64	2.15(0.80)	
-	228	1.70(0.84)	
*=p < 0.05			

Discussion

Diffusion-weighted MR imaging of the brain relies on different diffusion rates of water, or Brownian motion. Although it is primarily used for the diagnosis of acute infarction in the brain due to its ability to detect cytotoxic edema caused by water diffusion that changes due to cellular damage, it is also widely used in the evaluation of tumor pathology in the field of neuro-oncology (2). Specifically, DWI-derived ADC values have been shown to correlate with tumor cellularity, glioma grade, and treatment response(3).

Although the findings of restriction on DWI of the solid portion of brain metastases may be associated with their histology and tumor cellularity, these relationships continue to be systematically investigated. In studies, it was determined that the restriction in diffusion-weighted images predicted the histology of metastases and ADC values reflected the cellularity of the tumor(5). Studies have supported this finding by detecting lower ADC values in metastases of poorly differentiated cancers such as melanoma and small cell cancer(6). In addition, it has been thought in the literature that ADC values in the peritumoral region may be related to the infiltration pattern of metastases or the underlying vascular permeability(7).

Most metastases have a hyperintense signal on T2-weighted series. Studies have found T2 hypointensity in approximately 15% of metastases(8). T2 hypointensity was observed in 20.9% of metastases in our study.

In the literature, the hypointensity observed in brain metastases was thought to be due to the natural T2 effect due to calcium, mucin and iron(4) Egelhof et al. found that T2 hypointensity was statistically significantly higher in metastatic gastrointestinal adenocarcinomas, and they attributed this to

intralesional mucin deposition(9). On the other hand, Carrier et al. did not find a significant relationship between the presence of mucin and T2 hypointense appearance in their study(10).

Contrary to the vasogenic edema that occurs due to infiltration in gliomas, both the cause and the survival of the accompanying vasogenic edema in metastasis cases remain unclear. Studies have suggested that vasogenic edema accompanying metastases is due to mass effect or inflammatory cytokines(11). In some studies, the theory that metastasis is due to direct infiltration has been studied, but living tumor cells could not be detected in the adjacent brain parenchyma(12). In the study of Berghoff et al.(13), autopsy brain specimens of patients with brain metastasis were examined for integrins and adhesion molecules to evaluate infiltration patterns, and diffuse vascular infiltration was detected only in 50% of the specimens.

In our retrospective study, we evaluated the relationship between T2 hypointensity, diffusion restriction, presence and amount of vasogenic edema in 292 metastatic brain lesions.

Unlike studies that evaluated perilesional edema independently of lesion size, we evaluated the size of edema by proportioning it to the size of the metastatic lesion in our study. We could not find any other study evaluating edema in this way in the English literature.

According to the results of our study, we found that the incidence of vasogenic edema and EMR rates were higher in patients in T2 hypointense metastases and metastases accompanied by diffusion restriction in MRI. We thought that this result of our study may be related to the hypercellularity of the metastatic lesions and pathogenesis may be common.

Declarations

Data availability statement

The datasets generated during and/or analysed during the current study are available from the corresponding author on reasonable request.

Author Contributions

E.Y.B. and N.Ç. conceived of the presented idea. E.Y.B developed the theory and performed the computations. E.Y. B. and Ö.Ü. verified the analytical methods. Ö.Ü. encouraged E.Y. to investigate and supervised the findings of this work. All authors discussed the results and contributed to the final manuscript.

Conflict of interests

No conflict of interest

Funding sources

No funding sources

Ethics aproval

Ethics committee approval was received(2021-12/23)

References

1. Kaal EC, Taphoorn MJ, Vecht CJ. Symptomatic management and imaging of brain metastases. J Neurooncol. 2005;75:15–20.
2. Wieduwilt MJ, Valles F, Issa S, et al. Immunochemotherapy with intensive consolidation for primary CNS lymphoma: a pilot study and prognostic assessment by diffusion-weighted MRI. Cancer Res Treat 2012;18:1146–55.
3. Lee EJ, Lee SK, Agid R, et al. Preoperative grading of presumptive low-grade astrocytomas on MR imaging: diagnostic value of minimum apparent diffusion coefficient. AJNR .2008;29:1872–77.
4. Carrier DA, Mawad ME, Kirkpatrick JB, et al. Metastatic adenocarcinoma to the brain: MR with pathologic correlation. AJNR.1994;15:155–59.
5. Y. Hayashida, T. Hirai, S. Morishita, M. Kitajima, R. Murakami, Y. Korogi, K. Makino, H. Nakamura, I. Ikushima, M. Yamura, M. Kochi, J.-i. Kuratsu and Y. Yamashita. AJNR. 2006; 27 (7) 1419-1425;
6. Zakaria R, Das K, Radon M, et al. Diffusion-weighted MRI characteristics of the cerebral metastasis to brain boundary predicts patient outcomes. BMC Med Imaging. 2014;14:26.
7. Kienast Y, von Baumgarten L, Fuhrmann M, Klinkert WE, Goldbrunner R, Herms J, Winkler F. Real-time imaging reveals the single steps of brain metastasis formation. Nat Med. 2010;16(1):116–122.
8. Faiz K., Botsford A., Sinha N., Walling S., Shankar j., T2 Hypointensity Aids in the Diagnosis of Intracranial Metastatic Adenocarsinoma. Canadian Journal of Neurological Sciences.2020;47(2):210-2013.
9. Egelhoff, JC, Ross, JS, Modic, MT, Masaryk, TJ, Estes, M. MR imaging of metastatic GI adenocarcinoma in brain. AJNR. 1992;13(4):1221–4.
10. Carrier, DA, Mawad, ME, Kirkpatrick, JB, Schmid, MF. Metastatic adenocarcinoma to the brain: MR with pathologic correlation. AJNR.1994;15(1):155–9.
11. Miwa K, Shinoda J, Yano H, Okumura A, Iwama T, Nakashima T, Sakai N: Discrepancy between lesion distributions on methionine PET and MR images in patients with glioblastoma multiforme: insight from a PET and MR fusion image study. J Neurol Neurosurg Psychiatry 75: 1457-1462, 2004.
12. Li B, Yu J, Suntharalingam M, Kennedy AS, Amin PP, Chen Z, Yin R, Guo S, Han T, Wang Y, Yu N, Song G, Wang L: Comparison of three treatment options for single brain metastasis from lung cancer. Int J Cancer 90: 37-45, 2000.
13. Berghoff AS, Rajky O, Winkler F, Bartsch R, Furtner J, Hainfellner JA, Goodman SL, Weller M, Schittenhelm J, Preusser M: Invasion patterns in brain metastases of solid cancers. Neuro Oncol 15: 1664-1672, 2013.

Figures

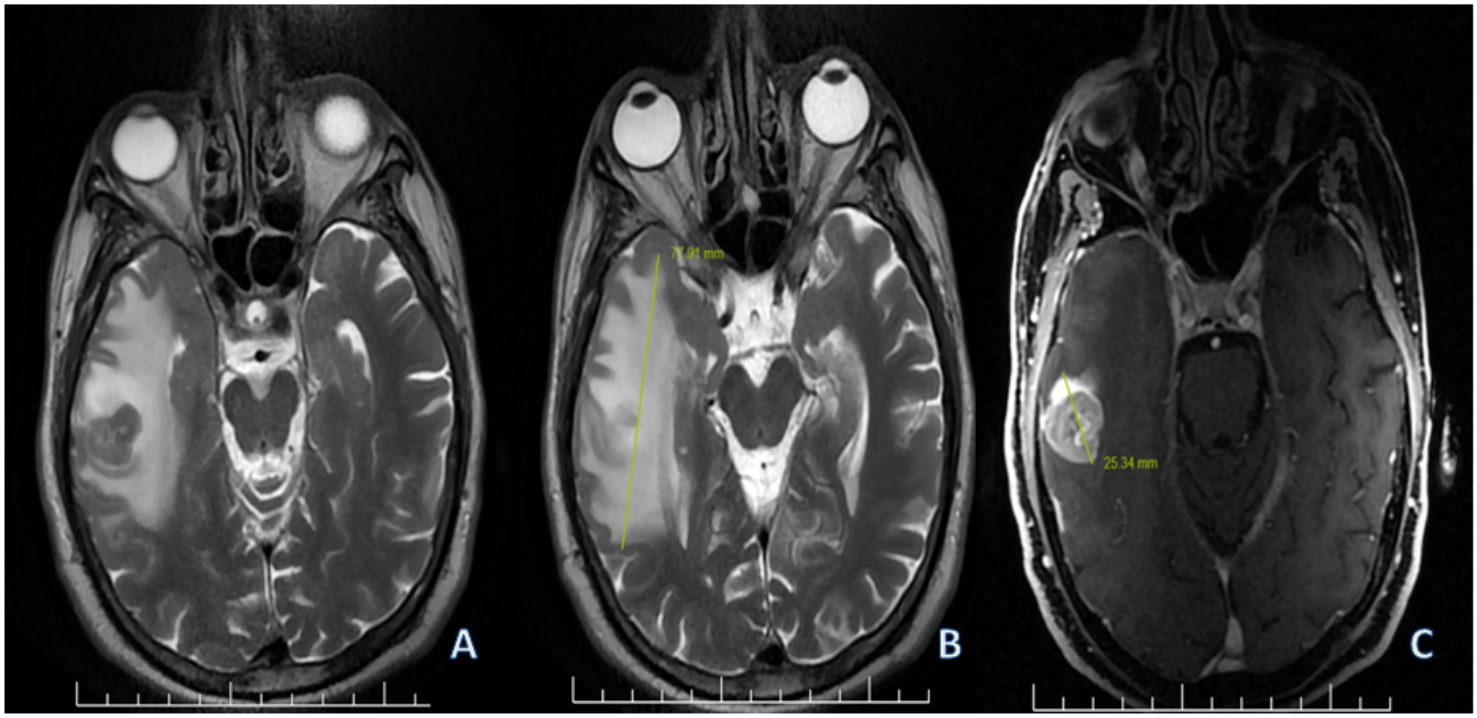

Figure 1

EMR. Ratio of largest size of vasogenic edema-mass complex to largest size of metastasis.