Clinical application of Improved VSD and VSD in the treatment of SSI after abdominal surgery

Tao Huang
The Second Hospital of Jilin University
Tong Liu
The Second Hospital of Jilin University
Mei Shang
The Second Hospital of Jilin University
An Shang
The Second Hospital of Jilin University
Gang Han (hangang@jlu.edu.cn)
The Second Hospital of Jilin University

Research Article

Keywords: Surgical site infection, Vacuum sealing drainage, Improved vacuum sealing drainage

Posted Date: May 19th, 2022

DOI: https://doi.org/10.21203/rs.3.rs-1655274/v1

Abstract

Aim

To explore the feasibility of clinical application and promotion of Improved vacuum sealing drainage devices by comparing the efficacy and cost of Improved vacuum sealing drainage devices and vacuum sealing drainage (VSD) devices in the treatment of postoperative abdominal surgical site infection.

Methods

from October 2019 to December 2021, we retrospectively analyzed 55 patients with surgical site infection after abdominal surgery in our hospital, including 30 patients treated with improved VSD and 25 patients treated with VSD. Wound healing efficacy, total dressing change cost during treatment, total hospitalization cost, hospital days, and bacteria culture results of wound secretions before and after treatment were compared between the two groups.

Results

Wound healing was achieved in both groups after vacuum sealing drainage treatment, and there was no significant difference in wound healing time and secondary suture rate ($P > 0.05$), but the hospitalization cost and dressing change cost of the Improved VSD group were significantly lower than those of VSD, with significant difference ($P < 0.05$).

Conclusions

The efficacy of simple VSD in the treatment of surgical site infection after abdominal surgery is similar to that of VSD. Compared with VSD, the total dressing change cost and hospitalization cost of improved VSD device in the treatment process are lower. Improved VSD has a wider application scope and is suitable for clinical application and promotion.

Introduction

Surgical Site Infection (SSI) occurs at the surgical incision and organ space infection after surgery. SSI is the most common postoperative complication after abdominal surgery [1], including Superficial Surgical Site Infection, Deep surgical site infection and Organ Space Infection. According to data from the 2018 SSI prevention Guidelines published by the World Health Organization (WHO), In low and middle-income countries (LMICs), the pooled incidence of SSI was 1.2–23.6% [2]. Although SSI incidence is much lower in high-income countries, it remains the second most frequent type of HAI in Europe and the United States of America (USA), the hospitalization cost of each SSI patient increases by 20,842, and the length of stay increases by 9.7 days [3]. According to the NICE guideline, the cost of hospitalization increases by approximately $90,000 per SSI patient. SSIs are associated with an increased risk of postoperative morbidity, prolonged hospitalization, postponement of chemotherapy, increased healthcare costs, and in some cases poor long-term outcomes. VSD has many advantages in the treatment of surgical site

infection, it is a new method for the treatment of surgical site infection, and it is also revolutionary progress [4]. VSD can accelerate the recovery time of patients with abdominal surgical site infection, reduce the patient's pain, lighten the staff workloads, lay a good foundation for further treatment [5, 6]. At present, the price of VSD we get clinically is very expensive, and many patients are difficult to get it. In clinical practice, many patients need it, especially in patients with open abdominal cavities combined with intestinal fistula, incision drainage is difficult to control, and VSD is the key technology to solve this problem. According to the theory and mechanism of action of VSD, an improved vacuum sealing drainage device (improved VSD) is designed. This paper retrospectively compared and analyzed the efficacy and cost of vacuum sealing drainage and improved vacuum sealing drainage in the treatment of surgical site infection after abdominal surgery.

Material And Methods

General information

From October 2018 to October 2021, fifty-five patients with surgical site infection after abdominal surgery admitted to our hospital were retrospectively analyzed. Among them, thirty patients with SSI were treated with improved vacuum sealing drainage. twenty-five patients with SSI were treated with vacuum sealing drainage. There were 13 males and 12 females in vacuum sealing drainage, aged from 46 to 79 years, with an average of (64.09±15.07) years. In improved vacuum sealing drainage: there were 19 males and 11 females between 47 and 84 years old, with an average of (52.16±17.54) years old. There was no statistically significant difference in the basic data of subjects in the two groups ($P > 0.05$), which were comparable, as shown in **Table 1** and **Table 2.** There was no statistical significance in the number of patients in each type of surgery in the two groups ($P > 0.05$), as shown in **Table 3**. There was no statistical significance in the number of patients in each subgroup in the classification of surgical site infection in the two groups ($P > 0.05$) (**Figure 1**).

Experimental materials and methods

Experimental Materials and Equipment

VSD Group:

1. Sterile black polyurethane foam dressings and polyvinyl-alcohol foam dressing Specification: 15cm* 10cm * 1cm) (Manufacturer: Shenzhen Qi Kang Medical Instrument Co., LTD);
2. Biological semi-permeable adhesive film; (Manufacturer: Shenzhen Qi Kang Medical Equipment Co., LTD.);
3. Negative pressure drainage bottle;
4. Central negative pressure system;

Improved VSD Group:

(1) Sterile absorbent gauze

(2) Disposable enema packs

(3) Biological semipermeable adhesive film; (Manufacturer: Shenzhen Qi Kang Medical Instrument Co., Ltd.)

(4) Suction Catheter, Gastric tube

(3) Negative pressure drainage bottle;

(4) Central negative pressure system;

Treatment methods

Debridement: The operation of SSI patients should strictly comply with the principle of aseptic operation. Before routine debridement, bacterial culture and drug susceptibility of secretions should be carried out, and then the wound surface should be repeatedly cleaned with hydrogen peroxide, 0.9% normal saline, and iodophor disinfectant[7]. At the same time, the necrotic tissue, necrotic fascia, Pus moss, and sutures at the infected site must also be removed. The debridement must be thorough. It may not be fully cleaned at one time. To ensure that there is no pus and necrotic materials must be debridement several times. During the debridement process, granulation tissue may inevitably ooze blood. It is necessary to fully stop the bleeding. It is also necessary to fully explore the wound, observe, measure the size of the wound, the depth of the wound, and sneak into the wound. The size and direction of the cavity need to be paid attention to Whether there is an intestinal fistula in the incision, if so, adequate drainage should be done.

VSD GROUP

After the incision is fully debridement, wipe the skin around the wound with medical alcohol cotton balls to ensure that the skin around the wound is clean, and dry the skin around the wound with dry gauze, according to the results of the exploration incision, cut the PVA foam, and spread the foam on the entire wound surface to ensure full contact with the wound surface. Cover the outer layer of the biological semipermeable membrane with foam. The semipermeable membrane should exceed the edge of the wound by 5 cm to ensure airtightness. The place where it is difficult to seal the drainage tube should be sealed by the " Mesangial method ". Be sure to ensure the airtightness of the VSD device, and then Connect the suction pipe to the irrigation pipe, connect the irrigation pipe with sterile saline solution connect the suction pipe to the wall center negative pressure system adjust the negative pressure, see the collapse of the transparent film outside the foam of the VSD device[8], and the foam is closely combined with the wound surface, indicating that the negative pressure is nice, Perform negative pressure drainage with continuous irrigation of normal saline. The amount of irrigation and the dripping speed is determined according to the condition of the incision and the properties of the drainage material.

Improved VSD GROUP

Step 1:

Item preparation: Prepare one or more double cannulas (the Li-style double cannula as shown below) according to the type of infection at the surgical site and the size of the surgical incision. Choose a soft, tough, transparent disposable anal tube as the outer cannula. Use surgical scissors to cut several circular side holes evenly at the front end of the tube wall, choose a disposable silicone suction tube as the inner suction tube, cut the top side-hole of the suction tube, and insert it into the outer thimble as a suction tube, use scissors to cut off the sharp part at the front of the scalp needle, and fix it with silk thread to the end of the outer cannula. It is used as a flushing tube. The double catheterization cannula is made. Prepare sterile medical gauze and 3M surgical film, as shown in **Figure 2**.

Step 2:

Placement of drainage: After debridement and dressing of the incision, wipe the skin around the wound with an alcohol wipe, then dry the skin around the wound with dry gauze, and then measure and assess the size of the wound, wound depth, and the cavity sneaking in the wound. Packing gauze, and compared with VSD dressings, gauze treatment of such complex wounds is also more advantageous. The gauze can easily fill the cavities that sneak into the wounds to ensure that no dead space is left. After filling the inner gauze, lay the double catheterization cannula flat on the outside of the gauze, fill the gaps in other parts with gauze until it is level with the, and then cover the double catheterization cannula with a layer of gauze. This structure is similar to a "Hamburger" and is called a Hamburg-type negative pressure drainage device, as shown in **Figure 2**.

Step 3:

Closure: The next step is to apply film to the wound. The order of filming is around the wound and then the middle. When cutting, make sure that the size of the surgical film is about 4-5cm larger than the edge of each wound to fully ensure the airtightness of the device. The difficulty of filming is drainage. At the tube, it is sealed by the mesangial method. After the wound is fixed, the centrifugal end of the suction tube is drawn out of the wound, connected to the connecting tube, and then connected to the negative pressure drainage bottle. When the wound surface is large or many cavities are sneaking into the wound, multiple double catheterization cannula can be used to enhance the drainage effect, and a three-way tube can be used to connect the internal suction tubes. **Figure 2**.

Step 4:

Connect the negative pressure device: then connect the suction pipe and the flushing pipe, connect the saline to the flushing pipe, connect the connecting pipe on the other connection port of the negative pressure drainage bottle to the negative pressure system in the center of the hospital wall, and adjust the negative pressure, see the outer transparent film of the VSD device covered by the wound collapsed, and the dressing was closely combined with the wound, indicating that the negative pressure was good. After the negative pressure was good, perform negative pressure drainage with continuous irrigation of normal

saline. The amount of flushing and dripping speed was based on the incision condition, and the volume of purulent secretions drained, as shown in **Figure 2**.

 The top end of the double catheterization cannula must be wrapped in gauze, and the granulation tissue cannot be directly contacted. The improved VSD is concentrated around the double catheterization cannula, for patients with large wounds or patients with more gaps in the wound, they can use multiple double catheterization cannula to use in parallel so that they can attract more comprehensive, and they can also cover the entire wound evenly.

Other treatments

In the treatment process, both groups' simultaneous treatment and control of basic diseases should be paid attention to. In the process of closed negative pressure drainage treatment, if any incision was treated, the incision granulation tissue was fresh, flat, and granular, the granulation did not have edema, and the wound secretion was negative in bacterial culture, it could be changed to standard dressing. If there is edema at the base of the incision, hypertonic saline gauze can be used with a wet compress to reduce tissue edema. If in the treatment process, the granulation tissue of the incision is flat and fresh and the incision is still deep, to accelerate the incision healing and shorten the incision healing time, the wound should be sutured as soon as possible for the second phase.

Key points of operation during secondary suturing

Full-thickness suture incision, no tension suture, as shown in **Figure 3**, the suture needle should not be too deep, avoid suture to the intestinal wall, needle distance 1.5 cm, stitching margin is not less than 3 cm, on the edge of incision 2 cm, not suture, abdominal cavity and incisional drainage outflow, the VSD on the surface of the incision, and then continue to use the closed negative pressure drainage treatment for a few days, as shown in **Figure 3**.

Evaluation Criteria

The wound healing of the two groups was compared, the wound secondary suture rate wound healing time, total dressing cost, total hospitalization cost, and wound exudation culture results before and after treatment in the two groups.

Statistical analysis

SPSS22.0 statistical software was used for statistics. Independent sample T-test was used for measurement data, Chi-square test or Fischer accurate probability test, R-C column table and other test methods were used for counting data. The test degree was set as A =0.05, $P<0.05$.

Results

Wound the two groups after treatment for VSD, incision, it grows fast, finally, all healing, which improved the VSD patients, including 13 cases of direct healing of patients after treatment, 12 patients with healing after secondary suture, VSD patients after treatment of 19 patients with direct healing, healing of patients after two secondary sutures in 11 cases, there was no statistical difference in the secondary suture rate between the two groups (P > 0.05), As shown in **Table 4**, no patient caused death, no adverse reactions, no wound bleeding and another discomfort during the treatment process. A few patients had a small number of small blisters due to repeated films, but the total exchanges for the total drug and the inpatient cost of the improved VSD group are significantly lower than that of the VSD group. The difference is statistically significant (P <0 .05), as shown in **Table 5**.

Comparison of bacterial negative conversion rates

After the third week of treatment, the wounds of the two groups of patients had completely turned negative for bacterial culture, and there was no statistical difference in the bacterial negative conversion rates between the two groups in the first week and the second week (P > 0.05), as shown in **Table 6** below.

Discussion

Many reasons hinder the healing of abdominal SSI, including, diabetes, Hypoproteinemia, a large number of bacteria in the infected incision, necrotic fascia, and tissue edema in the incision [9-11], and the main reason is still poor drainage. Vacuum sealing drainage is different from the previous point-like drainage, but planar drainage changes [12] the open wound into a relatively closed wound to prevent contamination and subsequent infection [13-15]. The continuous high negative pressure drainage provided by the VSD provides a centripetal pulling force on the incision, which is superior to the centrifugal compression caused by traditional gauze packing, VSD can completely remove the exudation in the wound surface [16]and cavity and reduce tissue edema by continuous high negative pressure suction [17, 18]. VSD improves the microcirculation blood flow velocity of the wound, increases perfusion, accelerates the absorption of necrotic substances, enhances the formation of granulation tissue [19], reduces bacterial levels [20-22], decreases proinflammatory cytokines, decreases proteases [23], and compresses hemostasis. These factors are all conducive to the control of incision infection, accelerate wound healing, shorten the incision healing time, reduce the frequency of wound dressing changes, reduce the pain of patients during dressing changes, and reduce the psychological pressure of patients.

At present, the price of VSD we get clinically is very expensive. According to the theory and mechanism of action of VSD, we designed an improved vacuum sealing drainage device (improved VSD) using cheap materials that are easily obtained in the clinic, and shortened the dressing change. The interval is (1-2 d) [12], while the current mainstream VSD requires a long time between dressing changes (5-7 d), and the necrotic fascia or sutures and pus moss in the incision should be removed in time.

Industrial VSD is relatively expensive because of the material device used in it. However, according to the basic principle of industrial VSD, we designed an improved vacuum sealing drainage device (improved

VSD) using cheap materials that are easy to obtain clinically and shortened the interval time of dressing change to (1-2 days). However, the current mainstream closed drainage technology has a long interval of dressing replacement (5-7 d) [24], and it can remove the necrotic fascia or sutures and pus moss in the incision again in time, and find the focus of infection that was not found in the initial debridement. Each time, the incision is flushed with hydrogen peroxide and normal saline to reduce the number of bacteria in the incision. The comparison showed that the wounds of the two groups were finally healed. There was no statistical difference in the rate of secondary suture of the wounds in the two groups, the time of incision healing, and the bacterial negative conversion rate at one week and two weeks after treatment ($P>0.05$), but there was no statistical difference in improved VSD group. The cost of dressing change and total hospitalization costs were much lower than those of the VSD group, and the difference was statistically significant ($P < 0.05$). In the process of treatment, we observed that the improved VSD dressing used degreased gauze to easily adhere to the wound granulation tissue. Continuous rapid rinsing with 0.9% normal saline is required for 10 minutes before dressing change. When changing the dressing, infiltrate with 0.9% normal saline. The dressing, especially the contact between the wound granulation tissue and the gauze, needs to be careful and gentle during the process of peeling off the gauze. After taking the above measures, the patient did not feel uncomfortable during the dressing change process. During dressing change, 0.9% normal saline should be used to infiltrate the wound gauze, especially the contact between the granulation tissue of the wound and the gauze. During the process of stripping the gauze, the patient should be careful and gentle. After adopting the above methods, the patient did not feel uncomfortable during the dressing change.

In clinical practice, for complex wounds, such as intestinal fistulas, especially low intestinal fistulas, and colon fistulas, the secretion is thicker mucus or feces, and the diameter of the VSD drainage tube is small, the number of the lateral aperture is limited and fixed. Mucus and feces can block the drainage tube, often rendering the drainage ineffective and prolonging the healing time of the incision. Complex incisions like this are often combined with abdominal wall defects. The incision is large, and there are often multiple sneaking cavities in the incision. Compared with foam dressings, gauze is easier to pack the wound. In addition, the double catheterization cannula can be flexibly placed according to the size and direction of lacunae in the wound, and the number and size of the lateral aperture of the double catheterization cannula casings can be increased according to the characteristics of drainage. Besides, due to its short dressing cycle, it is also convenient to observe the incision, find the focus of infection not found in the initial debridement and timely clean up the necrotic tissue at the wound. And, each time, the incision is flushed with hydrogen peroxide and normal saline to reduce the number of bacteria in the incision, at the same time can promote wound healing. In VSD, the dressing change interval is long (5-7 days). If the initial debridement is incomplete or the deep local infection is not found, the replacement cycle is also long, which will prolong the incision healing time and increase the medical expenses.

Conclusion

VSD is a good wound treatment, but because of its high price, its popularization and application are limited. The efficacy of improved VSD in the treatment of SSI in this study is comparable to that of VSD,

and the price is only one-tenth of its price. Because the selected materials are common and easy to obtain in the clinic, the price is low, the operation process is simple, and both nurses and residents can be replaced independently after training, which is conducive to popularization and application.

Precautions During Vacuum Sealing Drainage

 For patients with deep incisional infection and the dehiscence of abdominal incision, and the vacuum sealing drainage is used to avoid the aggravation of the dehiscence of abdominal incision in three ways

1The negative pressure state in the incision attracts both sides of the incision to the middle;

2Pull the skin on both sides of the wound (the film is pulled) (**Figure 4);**

3The abdominal band is pressurized to protect the incision **(Figure 4);**

 VSD use contraindications: VSD is not recommended for patients with malignancy and localized wound invasion. Robert [6]et al have shown that VSD can stimulate tumor vascular production and stimulate the growth of tumors. HoweverVSD is not recommended for patients with hypersensitivity to polymer materials and 3M film, as well as patients with coagulation dysfunction and active bleeding on the wound surface

Core tip:

In the improved vacuum sealing drainage device, we use the double catheterization cannula

for the drainage tube. Compared with the suction tube used in the simple negative pressure drainage device of previous scholars, the drainage effect is better because of the unique structure of the double catheterization cannula (**Figure 5**). The sputum suction tube is used as an internal suction tube, and a soft and tough disposable anal canal is selected as the outer cannula. This design can avoid the dressing being adsorbed on the tube wall of the internal suction tube, resulting in poor drainage and wound exudate entering between the inner and outer tubes. There is a gap of 0.3-0.6cm, which is then sucked off by an internal suction tube with negative pressure, and according to the characteristics of drainage, the number and size of the lateral aperture of the double catheterization cannula casings can be increased.

Abbreviations

SSI: surgical site infection. BMI: Body Mass Index. NRS: nutrition risk screening. VSD: vacuum sealing drainage. Improved VSD: Improved vacuum sealing drainage.

Declarations

Availability of date and materials

The datasets generated and analyzed during the current study available from the corresponding author on reasonable request.

Acknowledgements

None.

Funding

Supported by Jilin Province Science and Technology Development Plan Fund, No. 2016KJT-092

Author information

Affiliations

Department of Gastrointestinal Nutrition and Hernia Surgery, The Second Hospital of Jilin University, No. 218, Ziqiang Dist, Changchun, 130041, Jilin.

Tao Huang, Tong Liu, Mei Shang, An Shang&Gang Han.

contributions

TH and GH conceived the study design. TL,and MS acquired the data for the study. TH, TL, and AS analyzed and interpreted the data. TH drafted the manuscript. TL and MS revised the manuscript critically. The authors read and approved the final manuscript.

Ethics declarations

Ethics approval and consent to participate

The study protocol was approved by the institutional review board of The Second Hospital of Jilin University. Due to the retrospective design of the study, the local ethic committee confirmed that informed consent was not necessary from participants. The demand of patient informed consent was deserted because of the retrospective nature of this study.

Consent for publication

Not applicable

Competing interests

The authors declare that they have no competing interests

References

1. Javed AA, Teinor J, Wright M, Ding D, Burkhart RA, Hundt J, Cameron JL, Makary MA, He J, Eckhauser FE, et al: **Negative Pressure Wound Therapy for Surgical-site Infections: A Randomized Trial**. Ann Surg 2019, **269**:1034–1040.
2. Allegranzi B, Bischoff P, de Jonge S, Kubilay NZ, Zayed B, Gomes SM, Abbas M, Atema JJ, Gans S, van Rijen M, et al: **New WHO recommendations on preoperative measures for surgical site infection prevention: an evidence-based global perspective**. Lancet Infect Dis 2016, **16**:e276-e287.
3. Leaper DJ, Tanner J, Kiernan M, Assadian O, Edmiston CE, Jr.: **Surgical site infection: poor compliance with guidelines and care bundles**. Int Wound J 2015, **12**:357–362.
4. Kim PJ, Attinger CE, Constantine T, Crist BD, Faust E, Hirche CR, Lavery LA, Messina VJ, Ohura N, Punch LJ, et al: **Negative pressure wound therapy with instillation: International consensus guidelines update**. Int Wound J 2020, **17**:174–186.
5. Ma J, Zhao J, Bai Q, He S, Yu J, Gou Y: **[Application of VSD in 6 Cases of Postoperative Infection -A Clinical Experience Sharing]**. Zhongguo Fei Ai Za Zhi 2018, **21**:343–347.
6. Robert N: **Negative pressure wound therapy in orthopaedic surgery**. Orthop Traumatol Surg Res 2017, **103**:S99-s103.
7. Du WL, Shen YM, Hu XH, Cheng L: **[Exploration on clinical treatment of incisional wound infection after orthopedic internal fixation for lower extremity joint injuries]**. Zhonghua Shao Shang Za Zhi 2021, **37**:216–224.
8. Chen B, Hao F, Yang Y, Shang Q, Guo C: **Prophylactic vacuum sealing drainage (VSD) in the prevention of postoperative surgical site infections in pediatric patients with contaminated laparotomy incisions**. Medicine (Baltimore) 2017, **96**:e6511.
9. Brathwaite S, Latchana N, Esemuede I, Harzman A, Husain S: **Risk Factors for Surgical Site Infection in Open and Laparoscopic Hartmann Closure: A Multivariate Analysis**. Surg Laparosc Endosc Percutan Tech 2017, **27**:51–53.
10. Jaschinski T, Mosch CG, Eikermann M, Neugebauer EA, Sauerland S: **Laparoscopic versus open surgery for suspected appendicitis**. Cochrane Database Syst Rev 2018, **11**:Cd001546.
11. Hennessey DB, Burke JP, Ni-Dhonochu T, Shields C, Winter DC, Mealy K: **Risk factors for surgical site infection following colorectal resection: a multi-institutional study**. Int J Colorectal Dis 2016, **31**:267–271.
12. Heller L, Levin SL, Butler CE: **Management of abdominal wound dehiscence using vacuum assisted closure in patients with compromised healing**. Am J Surg 2006, **191**:165–172.
13. Scalise A, Calamita R, Tartaglione C, Pierangeli M, Bolletta E, Gioacchini M, Gesuita R, Di Benedetto G: **Improving wound healing and preventing surgical site complications of closed surgical incisions: a possible role of Incisional Negative Pressure Wound Therapy. A systematic review of the literature**. Int Wound J 2016, **13**:1260–1281.
14. Matatov T, Reddy KN, Doucet LD, Zhao CX, Zhang WW: **Experience with a new negative pressure incision management system in prevention of groin wound infection in vascular surgery patients**. J Vasc Surg 2013, **57**:791–795.

15. Sahebally SM, McKevitt K, Stephens I, Fitzpatrick F, Deasy J, Burke JP, McNamara D: **Negative Pressure Wound Therapy for Closed Laparotomy Incisions in General and Colorectal Surgery: A Systematic Review and Meta-analysis**. JAMA Surg 2018, **153**:e183467.
16. Howe LM: **Current concepts in negative pressure wound therapy**. Vet Clin North Am Small Anim Pract 2015, **45**:565–584.
17. Fitzgerald JE, Gupta S, Masterson S, Sigurdsson HH: **Laparostomy management using the ABThera™ open abdomen negative pressure therapy system in a grade IV open abdomen secondary to acute pancreatitis**. Int Wound J 2013, **10**:138–144.
18. Mouës CM, Heule F, Hovius SE: **A review of topical negative pressure therapy in wound healing: sufficient evidence?** Am J Surg 2011, **201**:544–556.
19. Damiani G, Pinnarelli L, Sommella L, Tocco MP, Marvulli M, Magrini P, Ricciardi W: **Vacuum-assisted closure therapy for patients with infected sternal wounds: a meta-analysis of current evidence**. J Plast Reconstr Aesthet Surg 2011, **64**:1119–1123.
20. Wondberg D, Larusson HJ, Metzger U, Platz A, Zingg U: **Treatment of the open abdomen with the commercially available vacuum-assisted closure system in patients with abdominal sepsis: low primary closure rate**. World J Surg 2008, **32**:2724–2729.
21. Frykberg RG, Driver VR, Carman D, Lucero B, Borris-Hale C, Fylling CP, Rappl LM, Clausen PA: **Chronic wounds treated with a physiologically relevant concentration of platelet-rich plasma gel: a prospective case series**. Ostomy Wound Manage 2010, **56**:36–44.
22. Weed T, Ratliff C, Drake DB: **Quantifying bacterial bioburden during negative pressure wound therapy**: **does the wound VAC enhance bacterial clearance?** *Ann Plast Surg* 2004, **52**:276–279; discussion 279–280.
23. Labler L, Rancan M, Mica L, Härter L, Mihic-Probst D, Keel M: **Vacuum-assisted closure therapy increases local interleukin-8 and vascular endothelial growth factor levels in traumatic wounds**. J Trauma 2009, **66**:749–757.
24. Rasilainen SK, Mentula PJ, Leppäniemi AK: **Vacuum and mesh-mediated fascial traction for primary closure of the open abdomen in critically ill surgical patients**. Br J Surg 2012, **99**:1725–1732.

Tables

Table1 Patient demographics

Variable	VSD	Improved VSD	p
Gender			
Male	13	19	0.843
Female	11	11	
Age(year)	64.09±15.07	52.16±17.54	0.069
Re-operative hospital days (d)	2.27±1.35	2.16±0.96	0.787
BMI（kg/m2）	23.74±3.05	22.96±4.07	0.582
Pre-operative albumin (g/L)	36.65±5.37	37.12±7.91	0.863
Pre-operative hemoglobin（g/L）	120.36±23.61	122.50±29.41	0.869
Incision length (cm)	8.73±3.003	9.68±4.61	0.544
Preoperative blood glucose level	7.37±3.47	6.93±2.34	0.682
0peration time（min）	192.01±80.81	182.84±86.37	0.777
NRS2002	2.36±2.01	2.16±1.91	0.859
Postoperative SSI occurrence time	5.55±2.02	5.74±1.37	0.759
Diabetes（Yes	3	5	0.715
No	22	25	
Hypertension: Yes	1	4	0.362
No	24	26	
Smoker: Yes	3	5	0.715
No	22	25	

Abbreviation: SSI, surgical site infection. BMI, Body Mass Index. NRS, nutrition risk screening.

Table 2 Patient demographics

Variable	VSD	Improved VSD	P
Type of surgery			
elective surgery	6	7	0.963
emergency surgery	19	23	
Surgical method			
Laparoscopic surgery	2	3	0.838
Open surgery	16	21	
Laparoscopic-assisted	7	6	
Re-operation			
yes	5	8	0.652
no	20	22	
Incision classification			
Clean-contaminated	13	22	0.244
Contaminated	6	5	
Dirty	6	3	
Prophylactic antibiotics			
Cefminoxine	12	19	0.521
Ceftizoxime	7	6	
Etimicin	6	5	

Abbreviation: VSD, vacuum sealing drainage. Improved VSD Improved vacuum sealing drainage.

Table 3 Comparison of the number of different types of operations between the two groups

Term of operation	VSD	I Improved VSD	χ^2	PP
Radical resection of gastric cancer	22	33	2.76	0.996
Radical resection for colon cancer	33	44		
Radical resection of sigmoid colon cancer	22	33		
Rectal Malignant Resection	33	55		
Open appendectomy	11	11		
Total proctocolectomy	22	11		
E Exploratory laparotomy	55	77		
Intestinal fistula (laparotomy, adhesion lysis, intestinal resection, and anastomosis)	22	22		
I Ileostomy	22	22		
Colostomy	33	22		

Abbreviation: VSD, vacuum sealing drainage. Improved VSD Improved vacuum sealing drainage.

Table 4 Comparison of two sets of incision healing effects

Clinical data	VSD	Improved VSD	p
Wound healing:			
direct healing	13(52%)	19(63.3%)	0.392
Second phase suture	12(48%)	11(36.7%)	

Abbreviation: VSD, vacuum sealing drainage. Improved VSD Improved vacuum sealing drainage.

Table 5 Comparison of clinical outcomes:

Clinical data	VSD	Improved VSD	p
Healing time (d)	16.64±1.64	19.58±1.74	0.269
total dressing cost (yuan)	16963.94±1238.02	5058.04±1875.97	0.001
Hospital expenses (yuan)	109581.05±18911.24	94581.05±11541.76	0.032

Abbreviation: VSD, vacuum sealing drainage. Improved VSD Improved vacuum sealing drainage.

Table 6 the bacterial negative rate of the wound after one and two weeks of therapy

GROUP	Positive bacteria culture in before treatment	Negative bacteria culture after one week of treatment	Negative bacteria culture after two weeks of treatment
VSD	19	12(63.16%)	17(89.47%)
Improved VSD	24	14(58.33%)	22(91.6%)
p		0.748	0.806

Abbreviation: VSD, vacuum sealing drainage. Improved VSD Improved vacuum sealing drainage.

Figures

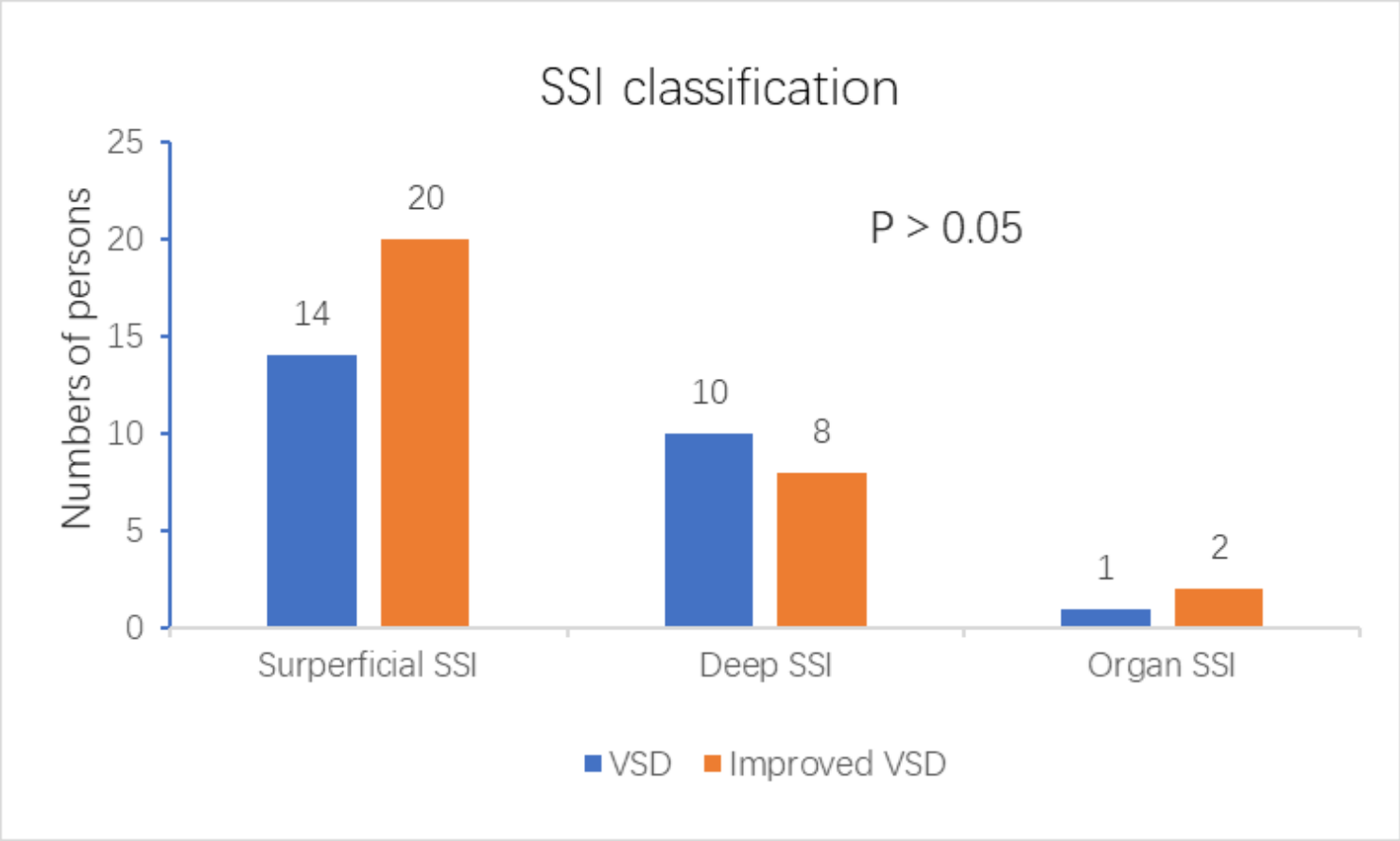

Figure 1

Number of subgroups in each SSI classification in the two groups Abbreviation: VSD vacuum sealing drainage. Improved VSD Improved vacuum sealing drainage.

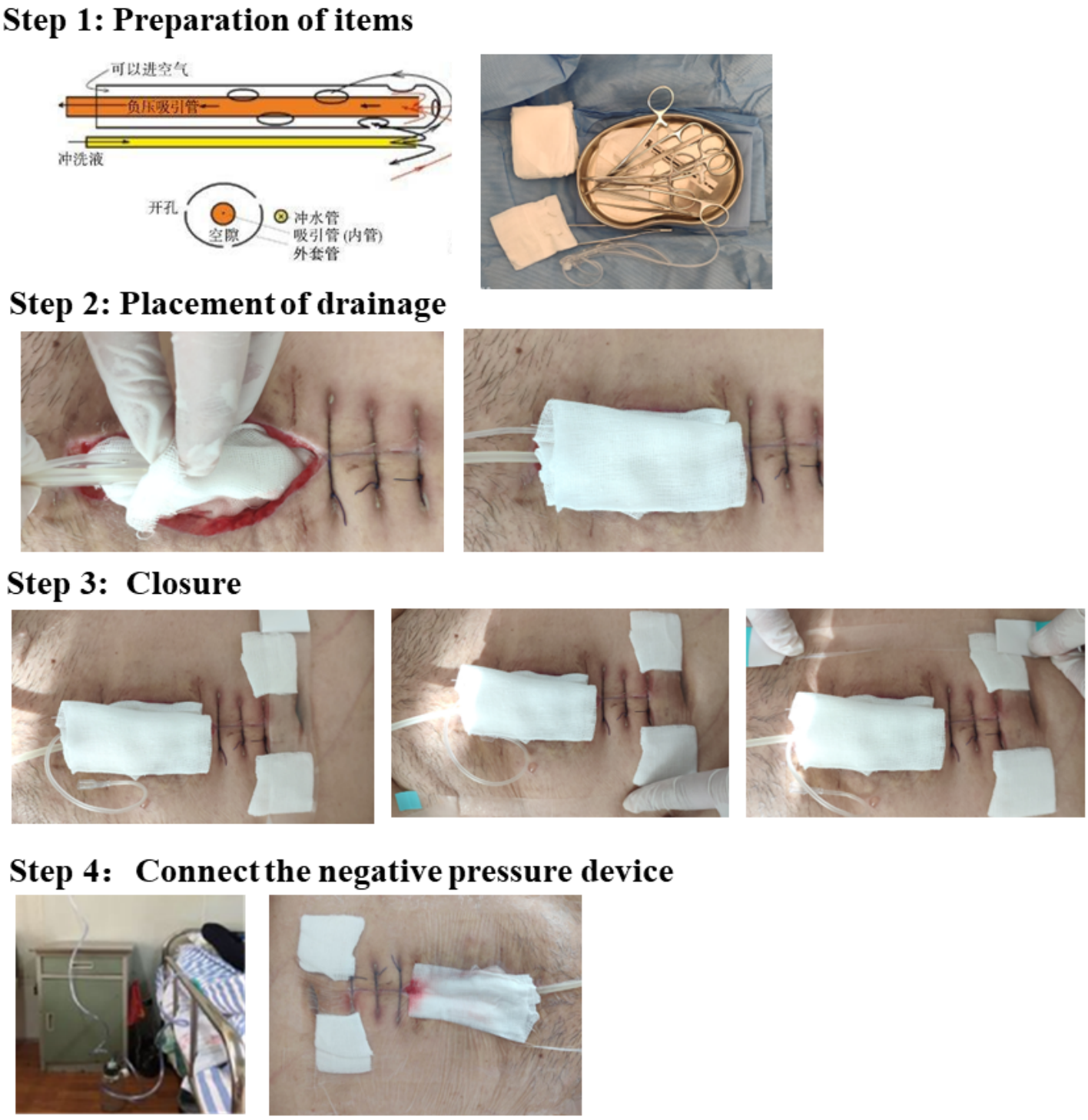

Figure 2

Device renderings

Secondary suture incision

VSD was continued after suturing

Figure 3

Key points of operation during secondary suturing

Figure 4

Legend not included with this version.

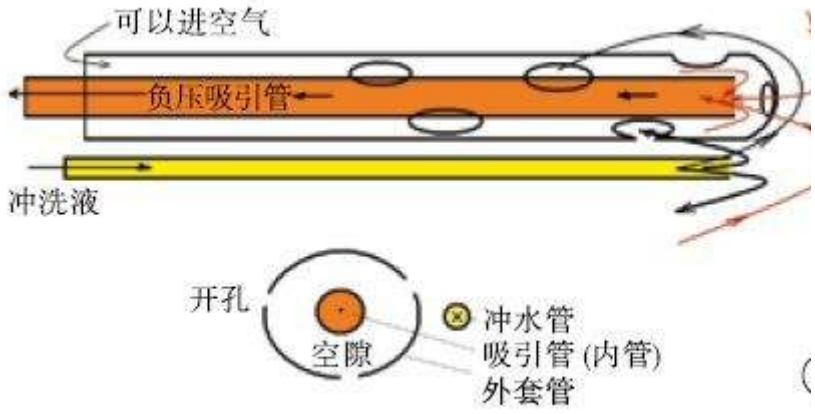

Figure 5

the double catheterization cannula