Study of Heterotopic Ossification after Alloplastic Temporomandibular Joint Replacement

Ruoyi Ding
Department of Oral Surgery, Ninth People's Hospital, Shanghai Jiao Tong University School of Medicine; Shanghai Key Laboratory of Stomatology & Shanghai Research Institute of Stomatology; National Cli

Chuan Lu
Department of Oral Surgery, Ninth People's Hospital, Shanghai Jiao Tong University School of Medicine; Shanghai Key Laboratory of Stomatology & Shanghai Research Institute of Stomatology; National Cli

Jieyun Zhao
Department of Oral Surgery, Ninth People's Hospital, Shanghai Jiao Tong University School of Medicine; Shanghai Key Laboratory of Stomatology & Shanghai Research Institute of Stomatology; National Cli

Dongmei He (lucyhe119@163.com)
Department of Oral Surgery, Ninth People's Hospital, Shanghai Jiao Tong University School of Medicine; Shanghai Key Laboratory of Stomatology & Shanghai Research Institute of Stomatology; National Cli

---

Research Article

Keywords: temporomandibular joint, alloplastic joint replacement, complication, heterotopic ossification

Posted Date: May 23rd, 2022

DOI: https://doi.org/10.21203/rs.3.rs-1656424/v1

Abstract

Background

Heterotopic ossification (HO) is one of the serious complications leading to the failure of alloplastic temporomandibular joint replacement (TJR). However, there was few research on its exact incidence and occurrence. Severe HO might result in pain and limited mouth opening after surgery. Therefore, it is necessary to clarify its clinical and imaging manifestations. The purpose of this study was to study the occurrence and classify HO after the alloplastic TJR.

Method

Patients who underwent standard TJR with fat graft and at least 1-year-follow-up were included. HO was classified into 4 types according to postoperative computed tomography (CT) scans. Type and occurrence in different TMJ disease were compared. Joint space was measured between HO and non-HO TJRs. Maximum mouth opening (MIO), pain, and quality of life (QoL) were recorded and their relevance with HO was analyzed statistically.

Result

81cases with 101 joints were included in the study. The mean follow-up time was 22.9 months. 48 joints (47.5%) had varying degrees of HO. Among them, 27 (56.3%) were type I (bone islands); 16 (33.3%) were type II (bone spurs from the mandibular ramus); 3 (6.3%) were type III (bone spurs from the fossa); and 2 (4.2%) were type IV (bone spurs from both the mandibular ramus and fossa). Joint space in type IV HO was significantly smaller than the other 3 types (9.9 ± 1.1mm, $p = 0.01$). Pain scores in HO were significantly greater than non-HO patients before and after operations ($p < 0.05$).

Conclusion

HO after alloplastic TJR with fat graft was not severe except for type IV, which was easy to cause ankylosis. Preserving sufficient TJR space was important for ankylosis prevention.

Introduction

Alloplastic temporomandibular joint replacement (TJR) is an important treatment for advanced diseases of temporomandibular joint (TMJ) such as tumor, late osteoarthritis and ankylosis. After more than 30 years of clinical application and follow-up, it can significantly increase patients' mouth opening and joint function, reduce pain, and improve the quality of life.[1,2] However, there are still some complications after TJR, such as infection, heterotopic ossification (HO), which may require prosthesis revision or

replacement.[3] HO was the secondly most common cause after infection in prosthesis revision or replacement, especially when ankylosis and severe pain happened.[4]

HO is the appearance of mature bone tissue in soft tissues including muscles, tendons, or articular capsules.[4] The incidence of HO in total hip/knee arthroplasty (THA/TKA) ranges from 15 to 90%.[5,6] However, there are few reports on the occurrence of the HO after TMJ TJR, as well as its affection on patients.

Based on clinical and CT follow-up of patients underwent standard alloplastic TJR, this study analyzed the occurrence of HO and its clinical relevance according to the proposed classification. By measuring postoperative TJR joint space in HO and non-HO joints, the possible affective reasons were clarified.

Patients And Methods

Study Design

This study was a retrospective study which was approved by the hospital ethical board (SH9H-2021-T111-2) and followed the guidelines of the Declaration of Helsinki. Patients who underwent standard alloplastic TJR in our department from June 2015 to December 2020 were enrolled. The inclusion criteria were as follows: (1) clinical and CT examination pre-and post-operation and at least 12 months follow-up; (2) operated by the same surgical method and using fat graft to fill dead space; (3) using standard prosthesis composed of ultra-high-molecular-weight polyethylene (UHMWPE) fossa prosthesis and Cr-Co-Mb mandibular prosthesis. Exclusion criteria were: (1) preserving the attachment of lateral pterygoid muscle; (2) postoperative infection; (3) TJR before.

Surgical procedure

Pre-auricular and retromandibular incisions were used to expose the glenoid fossa, condyle and lateral surface of the mandibular ramus. The condyle was cut at the neck and removed after lateral pterygoid muscle (LPM) detachment. The disc was salvaged and sutured to the LPM. After trimming the articular eminence, the ramus stump and lateral side of the mandibular ramus, bone graft was implanted to flat the fossa. Then the fossa prosthesis was placed and secured with at least 4 screws. Dressings and gloves were changed after intermaxillary fixation. The condylar prosthesis was installed with the head seat superior-posteriorly in the fossa. Subcutaneous free fat harvested from either the retromandibular or abdominal periumbilical incision was filled around the joint space. A drain was placed into the incision.[7]

CT evaluation and HO classification

CT scan was performed within 1 week after operation and during at least 1 year follow-up. The parameters of the 64-row-dual-source CT scanner (Somatom Definition Flash; Siemens, Forchheim, Netherlands) were continuous scanning with a layer thickness of 0.625 mm, 120 kV, and tube electricity current of 284 mAs. The image was saved in DICOM format and then imported into Proplan CMF 3.0

(Materialise, Leuven, Belgium). The bone window was selected. Then the coronal plane was reconstructed for evaluation.

According to Brooker's[5] classification of HO after TKA in 1986 and Turlington-Durr grading system[8] of TMJ TJR in 1993, we classified HO into 4 types (Figure 1).

Type Ⅰ, bone islands within the medial soft tissue of the condylar prosthesis.

Type Ⅱ, bone spurs from the mandibular ramus stump.

Type Ⅲ, bone spurs from the medial side of the fossa.

Type Ⅳ, bone spurs from both the mandibular ramus stump and fossa.

TJR joint space was measured from the coronal reconstruction of CT scan within 1 week after operation. The shortest distance between the stump of the mandibular ramus and the glenoid fossa was recorded by the software tools in millimeter with an accuracy of 0.1mm (Figure 2).

Clinical Evaluation

The maximum incisal opening (MIO) was measured and recorded in mm. Visual analogue scale (VAS) was used to evaluate patient-reported pain from 0 to 10 (0, no pain; 10 worst pain). Dimitroulis questionnaire[9] for quality of life (Qol) evaluation was adopted, which involved 8 questions on pain, diet speech, social activities, entertainment, subjective evaluation of disease state, anxiety severity, and an overall evaluation. Each question was followed by 5 options and had a score ranging from 1~5. The total score was calculated, 8–10 points was considered excellent, 11–14 points good, 15–19 points medium, and ≥20 points bad.

Statistical Analysis

IBM SPSS software package, version 24.0 (IBM Corp., Armonk, NY, USA) was carried out for statistical analysis. T test was used for comparing the significance of differences in MIO, VAS-pain scores and QoL scores within and between HO and non-HO patients before and after operation. Chi-square test was used to compare the incidence of HO among different diseases. One-way analysis of variance (ANOVA) was used to analyze the differences in joint space among the 4 HO types. An α level ≤.05 was considered significant.

Results

81 cases with 101 TJRs were included in the study. Among them, there were 20 males and 61 females with an average age of 47.2 ± 14.1 years (range, 18–84 years). 20 cases had bilateral TJR, and 61 cases were unilateral. The diseases included ankylosis in 26 cases with 37 joints, osteoarthritis in 42 cases with

51 joints, TMJ tumor in 13 cases with 13 joints. The mean follow-up period was 22.9 ± 11.3 months (range, 12–56 months).

48 TJRs had various degree of HO, which accounted for 47.5% (Table 1). There were 27 joints (56.3%) in type Ⅰ, 16 joints (33.3%) in type Ⅱ, 3 joints (6.3%) in type Ⅲ and 2 joints (4.2%) in type Ⅳ. The incidence of HO in different disease was 43.2% in ankylosis (16/37), 51.0% in osteoarthritis (26/51), and 46.2% in TMJ tumors (6/13). Although osteoarthritis had the highest incidence of HO, there was no statistical differences among the three diseases (p = 0.76, Table 2).

Table 1
Incidence, classification of HO and joint space measurement

Classification	Number of joints (%)	Joint space after operation
HO joints (%)	48 (47.5%)	$18.3 \pm 4.3^{\alpha}$
Type I	27	$19.3 \pm 3.3^{\beta}$
Type II	16	$17.4 \pm 4.6^{\beta}$
Type III	3	$19.6 \pm 4.0^{\beta}$
Type IV	2	$9.1 \pm 1.1^{\beta}$
Non-HO joints	53 (52.5%)	$19.4 \pm 4.2^{\alpha}$
Total	101 (100%)	
$^{\alpha}p = 0.31$, $^{\beta}p = 0.01$		

Table 2
HO distribution among different TMJ disease

	Ankylosis	Osteoarthritis	Tumors	Total
HO	16 (43.2%)#	26 (51.0%)#	6 (46.2%)#	48 (47.5%)
Type I	10	14	3	27 (56.3%)
Type II	4	11	1	16 (33.3%)
Type III	1	0	2	3 (6.3%)
Type IV	1	1	0	2 (4.2%)
Non-HO	21 (56.8%)	25 (49.0%)	7 (53.8%)	53 (52.5%)
Total	37 (100%)	51 (100%)	13 (100%)	101 (100%)
#p = 0.76				

The mean TJR joint space was 19.4 ± 4.3mm in HO and 19.2 ± 4.4mm in non-HO joints without statistical difference ($p = 0.31$, Table 1). But it was significantly reduced in type IV HO (9.1 ± 1.1mm) compared with type Ⅲ (19.3 ± 3.5mm), type Ⅱ (17.4 ± 4.4mm), and type Ⅰ (19.2 ± 4.0mm, $p = 0.01$) HO.

Clinical follow-up showed that both HO and non-HO patients had their MIO, pain and QoL improved after TJR ($p < 0.01$, Table 3). Pain scores in HO patients were significantly higher than non-HO patients both before and after operations ($p < 0.05$). There were no significant differences of MIO and QoL between HO and non-HO patients both before and after operations ($p > 0.05$). There were 2 HO patients, one developed postoperative pain and the other had pain and MIO aggravated during follow-ups. The latter one had prosthesis revision surgery to remove type Ⅲ HO and improve MIO. The revision rate was 2.1% in HO patients and 1.0% in all TJR patients.

Table 3
Clinical follow-up of patients with and without HO

Patients	HO pre-	HO post-	Non-HO pre-	Non-HO post-
MIO(mm)	$24.1 \pm 11.8^{\alpha\#}$	$34.7 \pm 6.8^{\beta\#}$	$22.0 \pm 14.7^{\alpha!}$	$35.7 \pm 7.8^{\beta!}$
VAS-Pain	$4.4 \pm 2.9^{\gamma@}$	$1.8 \pm 2.3^{\delta@}$	$3.0 \pm 2.8^{\gamma\$}$	$0.9 \pm 1.1^{\delta\$}$
QoL	$19.4 \pm 6.0^{\varepsilon\wedge}$	$13.8 \pm 4.9^{\zeta\wedge}$	$18.6 \pm 5.8^{\varepsilon\&}$	$12.2 \pm 3.0^{\zeta\&}$
$^{\alpha}p = 0.49$, $^{\beta}p = 0.54$, $^{\gamma}p = 0.03$, $^{\delta}p = 0.04$, $^{\varepsilon}p = 0.55$, $^{\zeta}p = 0.09$, $^{\#!@\wedge\&\$}p < 0.01$				

Discussion

Alloplastic TJR has been widely used as a major method of TMJ reconstruction since material and design improvements in the 1990s.[1] However, infection and HO are the main causes of prosthesis revision or replacement.[10] There were few reports on the TMJ HO after alloplastic TJR compared to the one from orthopedics, especially after Wolford[11] proposed using abdominal periumbilical fat to fill the dead space around the joint prosthesis in 1997. The incidence of HO has been significantly reduced than before.[12] In this study, we used subcutaneous or abdominal periumbilical fat for TJR. CT follow-up showed that HO was happened only in the medial side of the prosthesis.

In 1993, Turlington and Durr proposed TMJ HO grading system[8] according to Brooker's THA HO classification.[11] It is as follows: Grade 0: no bone islands visible; Grade 1: Islands of bone visible within soft tissue around joint; Grade 2: Periarticular bone formation; Grade 3: Apparent bony ankylosis. Grades 1, 2, and 3 were further classified as symptomatic (S) and asymptomatic (A). Symptomatic ossification includes severe pain, decreased interincisal opening (15 mm or less), closed locking of the jaw, or decreased lateral or protrusive movement. In this study, we referred the above classification and described the HO according to its location based on coronal CT reconstruction. Our results showed that

the incidence of HO after alloplastic TJR was 47.5%. Among them, 56.3% of HO was bone islands in the soft tissue medial to the condylar prosthesis. 33.3% bone spurs were grown from the mandibular ramus. Only 6.3% of the HO came from the medial side of the fossa and 4.2% developed ankylosis.

The incidence of HO among TMJ ankylosis, osteoarthritis and tumors had no significant difference. By measuring postoperative TJR space, we found that type IV HO had significantly reduced space with an average of 9.1mm than the other three types, which is a risk factor for ankylosis. Studies have shown that when the gap between bone stumps was less than 10mm, ankylosis was more likely to occur.[13] When the bone defect is larger than critical-sized defect (CSD), osseous connection will not formed. Animal experiments on dogs with similar mandibular size as human showed that CSD is about 15mm.[14,15] At present, there is no requirement for the minimum TJR space when implanting the prosthesis. Although the position of condylectomy is suggested to be at the level of sigmoid notch with removal of coronoid process, for patients with short mandibular ramus, sacrificing a certain joint space to provide sufficient bone support for the mandibular prosthesis may increase the risk of ankylosis. Therefore, it is recommended to use a customized prosthesis with mandibular body extension instead of a standard prosthesis which only fixes the mandibular ramus.

We also analyzed the relevance between HO type and clinical signs and symptoms. Except for type IV HO, which was prone to cause ankylosis and requires revision or replacement of the prosthesis, the clinical symptoms (pain and limited mouth opening) of the other 3 types of HO were mild. This was similar to the report after THA, although the incidence of small-volume HO can be up to 50%, only 10–20% of the patients have significant discomfort due to the severely affected joint mobility.[16,17] In addition, we found that pain scores were significantly higher in HO patients than non-HO patients both before and after operation. High pain scores may reflect local inflammation around the joint which may affect bone metabolism and lead to the occurrence of HO after surgery.[18–20] HO is also a major cause of postoperative pain. So it is important to prevent HO after TJR surgery.

Studies on the etiology of HO have shown that surgical trauma can cause inflammation and activate mesenchymal stem cells in tissues, thus differentiating into osteogenesis.[21–23] In addition, the tension of masticatory muscle can also lead to the bone formation.[24,25] Tendons and ligaments may ossified,[26] and disc ossification was also reported after operation.[27]In this study, HO occurred on the medial side of the joint, with bone islands possibly derived from the external pterygoid muscle or the articular disc, as well as bone spurs growing from the ramus stumps after condylectomy. The mechanism of HO formation after alloplastic TJR remains to be further investigated.

Except periarticular autogenous fat grafting to prevent HO, postoperative radiotherapy and oral non-steroidal anti-inflammatory drugs (NSAIDs) such as indomethacin, celecoxib and bisphosphonates are also reported effective.[17] In 1993, Durr et al.[8] found that early postoperative administration of 10 Gy radiation five times a day could prevent 67% of HO after TJR with a history of ankylosis. Jensen et al.[28] also demonstrated that postoperative radiotherapy could prevent long term HO reformation in 50% of the

TJR patients. NSAIDs is another method to prevent HO and relief pain by inhibiting the synthesis of inflammatory factor Prostaglandin E2 (PGE2).[29] Bhatt et al.[30] found that indomethacin was effective in the prevention of HO after recurrent ankylosis. Naylor et al.[31] found that celecoxib significantly reduced the incidence of HO from 14.3–4.3% after THA. Ouyang et al.[32] proved that celecoxib was effective in post-traumatic TMJ HO in animal models. These methods above can be prophylactic used in high-risk patients such as ankylosing spondylitis, hypertrophic osteoarthritis, and recurrent HO.

This study involved patients with more than 1 year follow-up. HO can be shown from CT scan 3 months after operation and matured without change around 6–12 months after operation. In the future, quantitative measurement of HO and long-term follow-up can be taken to observe HO development and the relationship with inflammation. The incidence of HO in the customized TMJ prosthesis with different materials will be studied and compared with the standard TJR.

In conclusion, HO happened in various degrees after alloplastic TJR with fat graft. Most of which have little impact on patients' mouth opening or quality of life. However, type Ⅲ HO is prone to cause ankylosis, which need surgical removal to improve MIO and pain relief. Sufficient TJR space may reduce the risk of ankylosis.

Abbreviations

CSD: critical-sized defect; CT: computed tomography; HO: heterotopic ossification; LPM: lateral pterygoid muscle; MIO: maximum mouth opening; QoL: quality of life; THA/TKA: total hip/knee arthroplasty; TJR: temporomandibular joint replacement; TMJ: temporomandibular joint; UHMWPE: ultra-high-molecular-weight polyethylene; VAS: Visual analogue scale.

Declarations

Ethics approval and consent to participate

The study was conducted in accordance with the Declaration of Helsinki (as revised in 2013). The study was approved by the Independent Ethics Committee of Shanghai Jiao Tong University School of Medicine Affiliated 9th Peoples Hospital (SH9H-2021-T111-2) and informed consent was taken from all individual participants.

Consent for publication

Written informed consent for publication was obtained from the participants.

Availability of data and materials

The data collected and analyzed in the current study are not publicly available due to ethical restrictions, but are available from the corresponding author upon reasonable request.

Competing interests

All other authors declare that they have no competing interests.

Funding

This study was supported by grants from the Science and Technology Commission of Shanghai Municipality Science Research Project (20Y11903900, 20S31902500).

Authors' contributions

DH designed the study and performed all the operations. RD, JZ and CL collected the data. RD analyzed the data and wrote the draft. DH revised the paper. All authors were contributed in the paper and approved the final manuscript.

Acknowledgements

We thank Luxiang Zou for the help of collecting patients' clinical data.

References

1. Zou L, He D, Ellis E. A Comparison of Clinical Follow-Up of Different Total Temporomandibular Joint Replacement Prostheses: A Systematic Review and Meta-Analysis. J Oral Maxillofac Surg. 2018;76(2):294–303.
2. Johnson NR, Roberts MJ, Doi SA, Batstone MD. Total temporomandibular joint replacement prostheses: a systematic review and bias-adjusted meta-analysis. Int J Oral Maxillofac Surg. 2017. 46(1): p. 86–92.
3. Hoffman D, Puig L. Complications of TMJ surgery. Oral Maxillofac Surg Clin North Am. 2015;27(1):109–124.
4. Mercuri LG, Saltzman BM. Acquired heterotopic ossification of the temporomandibular joint. Int J Oral Maxillofac Surg. 2017;46(12):1562–1568.
5. Łęgosz P, Otworowski M, Sibilska A, Starszak K, Kotrych D, Kwapisz A, Synder M. Heterotopic Ossification: A Challenging Complication of Total Hip Arthroplasty: Risk Factors, Diagnosis, Prophylaxis, and Treatment. Biomed Res Int. 2019;2019:3860142.
6. Gkiatas I, Xiang W, Nocon AA, Youssef MP, Tarity TD, Sculco PK. Heterotopic Ossification Negatively Influences Range of Motion After Revision Total Knee Arthroplasty. J Arthroplasty. 2021;36(8):2907–2912.
7. ShanYong Z, Liu H, Yang C, Zhang X, Abdelrehem A, Zheng J, Jiao Z, Chen M, Qiu Y. Modified surgical techniques for total alloplastic temporomandibular joint replacement: One institution's experience. J Craniomaxillofac Surg. 2015;43(6):934–939.

8. Durr ED, Turlington EG, Foote RL. Radiation treatment of heterotopic bone formation in the temporomandibular joint articulation. Int J Radiat Oncol Biol Phys. 1993;27(4):863–869.
9. Dimitroulis G, McCullough M, Morrison W. Quality-of-life survey comparing patients before and after discectomy of the temporomandibular joint. J Oral Maxillofac Surg. 2010;68(1):101–106.
10. Amarista FJ, Mercuri LG, Perez D. Temporomandibular Joint Prosthesis Revision and/or Replacement Survey and Review of the Literature. J Oral Maxillofac Surg. 2020;78(10):1692–1703.
11. Wolford LM, Morales-Ryan CA, Morales PG, Cassano DS. Autologous fat grafts placed around temporomandibular joint total joint prostheses to prevent heterotopic bone formation. Proc (Bayl Univ Med Cent). 2008;21(3):248–254.
12. Mercuri LG, Ali FA, Woolson R. Outcomes of total alloplastic replacement with periarticular autogenous fat grafting for management of reankylosis of the temporomandibular joint. J Oral Maxillofac Surg. 2008;66(9):1794–1803.
13. Al-Moraissi EA, El-Sharkawy TM, Mounair RM, El-Ghareeb TI. A systematic review and meta-analysis of the clinical outcomes for various surgical modalities in the management of temporomandibular joint ankylosis. Int J Oral Maxillofac Surg. 2015;44(4):470–482.
14. Hosseinpour S, Bastami F. Critical-Sized Bone Defects in Mandible of Canine Model. Tissue Eng Part A. 2017;23(9–10):470.
15. Arzi B, Stover SM, Garcia TC, Leale DM, Verstraete FJ. Biomechanical evaluation of two plating configurations for critical-sized defects of the mandible in dogs. Am J Vet Res. 2016;77(5):445–451..
16. Sun Y, Cai J, Li F, Liu S, Ruan H, Fan C. The efficacy of celecoxib in preventing heterotopic ossification recurrence after open arthrolysis for post-traumatic elbow stiffness in adults. J Shoulder Elbow Surg. 2015;24(11):1735–1740.
17. Y Yim CR, Uhrich RM, Perez L Jr. Treatment of Temporomandibular Joint Heterotopic Ossification: A Novel Protocol With Multimodal Therapy Based on Literature Review and Presentation of a Unique Case Report. J Oral Maxillofac Surg. 2021;S0278-2391(21)01516–0.
18. Harth M, Nielson WR. Pain and affective distress in arthritis: relationship to immunity and inflammation. Expert Rev Clin Immunol. 2019;15(5):541–552.
19. Kraft CT, Agarwal S, Ranganathan K, Wong VW, Loder S, Li J, Delano MJ, Levi B. Trauma-induced heterotopic bone formation and the role of the immune system: A review. J Trauma Acute Care Surg. 2016;80(1):156–165.
20. Hu X, Sun Z, Li F, Jiang C, Yan W, Sun Y. Burn-induced heterotopic ossification from incidence to therapy: key signaling pathways underlying ectopic bone formation. Cell Mol Biol Lett. 2021;26(1):34.
21. Steward AJ, Kelly DJ. Mechanical regulation of mesenchymal stem cell differentiation. J Anat. 2015;227(6):717–731.
22. Ranganathan K, Loder S, Agarwal S, Wong VW, Forsberg J, Davis TA, Wang S, James AW, Levi B. Heterotopic Ossification: Basic-Science Principles and Clinical Correlates. J Bone Joint Surg Am. 2015;97(13):1101–1111.

23. Cholok D, Chung MT, Ranganathan K, Ucer S, Day D, Davis TA, Mishina Y, Levi B. Heterotopic ossification and the elucidation of pathologic differentiation. Bone. 2018;109:12–21.
24. Tagliaferri C, Wittrant Y, Davicco MJ, Walrand S, Coxam V. Muscle and bone, two interconnected tissues. Ageing Res Rev. 2015;21:55–70.
25. Buvinic S, Balanta-Melo J, Kupczik K, Vásquez W, Beato C, Toro-Ibacache V. Muscle-Bone Crosstalk in the Masticatory System: From Biomechanical to Molecular Interactions. Front Endocrinol (Lausanne). 2021;11:606947.
26. Zhang Q, Zhou D, Wang H, Tan J. Heterotopic ossification of tendon and ligament. J Cell Mol Med. 2020;24(10):5428–5437.
27. Bechtold TE, Saunders C, Mundy C, Um H, Decker RS, Salhab I, Kurio N, Billings PC, Pacifici M, Nah HD, Koyama E. Excess BMP Signaling in Heterotopic Cartilage Forming in Prg4-null TMJ Discs. J Dent Res. 2016;95(3):292–301.
28. Jensen AW, Viozzi CF, Foote RL. Long-term results of radiation prophylaxis for heterotopic ossification in the temporomandibular joint. J Oral Maxillofac Surg. 2010;68(5):1100–1105.
29. Lisowska B, Kosson D, Domaracka K. Lights and shadows of NSAIDs in bone healing: the role of prostaglandins in bone metabolism. Drug Des Devel Ther. 2018;12:1753–1758.
30. Bhatt K, Pandey S, Bhutia O, Roychoudhury A. Use of indomethacin as an adjuvant to surgery for recurrent temporomandibular joint ankylosis in adults. Natl J Maxillofac Surg. 2014;5(2):198–201.
31. Naylor BH, Iturriaga CR, Bisen YB, Caid MJ, Reinhardt KR. Heterotopic Ossification Following Direct Anterior Total Hip Arthroplasty With and Without Postoperative Analgesic Nonsteroidal Anti-inflammatories. J Arthroplasty. 2021;36(10):3471–3477.
32. Ouyang N, Zhao Y, Chen Q, Chen L, Fang B, Dai J, Shen G. The effect of celecoxib in traumatic heterotopic ossification around temporomandibular joint in mice. Osteoarthritis Cartilage. 2020;28(4):502–515.

Figures

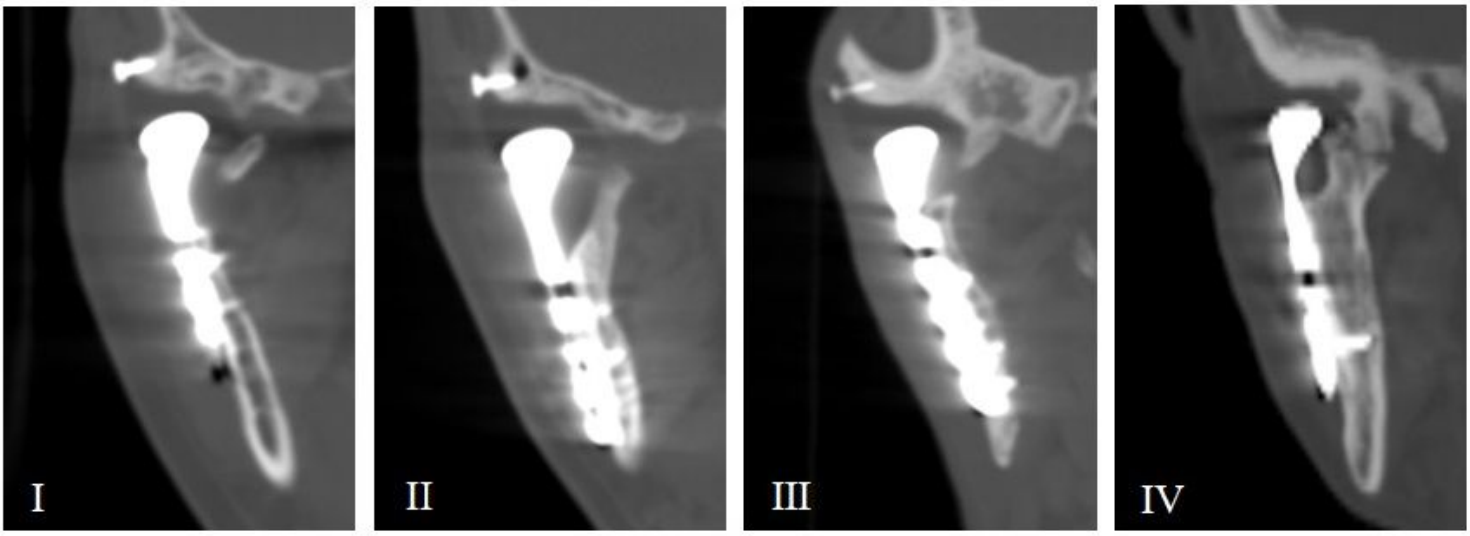

Figure 1

The classification of heterotopic ossification after alloplastic temporomandibular joint replacement.

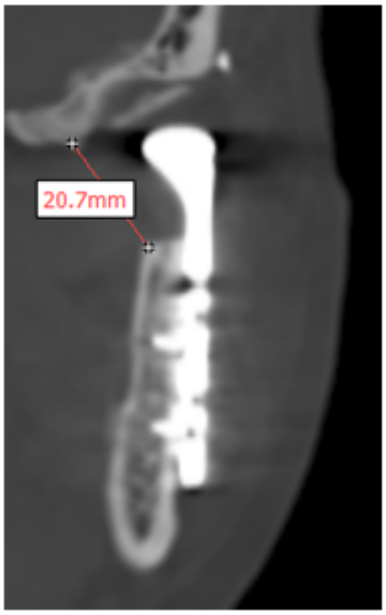

Figure 2

Joint space measurement in the CT coronal reconstruction 1 week after operation.