Efficacy of Anastomosis Enhancing Suture in Laparoscopic Anterior Resection of Middle-Low Rectal Cancer: A Prospective Cohort Study

Jin-Shui Chen
Departmetn of Surgery, No.991 Hospital of People's Liberation Army, Hubei, China
Jia Zang
Department of Surgery, Changzheng Hospital, Shanghai, China
Shu-Xun Wei
Shanghai Changzheng Hospital
Wen-Tao Yan
Department of Surgery, Changzheng Hospital, Shanghai, China
Hai-Yang Zhou
Department of Surgery, Changzheng Hospital, SHanghai, China
Can-Ping Ruan
Department of Surgery, Changzheng Hospital, Shanghai, China
Wei-Jun Wang
Department of Surgery, Changzheng Hospital, Shanghai, China
Yi Wang
Department of Surgery, Changzheng Hospital, Shanghai, China
Yan-Ping Sun
Department of Surgery, Changzheng Hospital, Shanghai, China
Jian Zhang (zhangjian_czhsp@163.com)
Changzheng Hospital, Shanghai, China https://orcid.org/0000-0002-0126-6172
Zhi-Qian Hu
Department of Surgery, Changzheng Hospital, Shanghai, China

Technical innovations

Keywords: Middle-low rectal cancer, Laparoscopic anastomosis enhancing suture, Preventive enterostomy, Transanal drainage tube, Laparoscopic anterior resection, Double-stapling technique, Anastomotic leakage, Anastomotic bleeding, Anastomotic stricture

Posted Date: February 4th, 2021

DOI: https://doi.org/10.21203/rs.3.rs-165686/v1

Abstract

Background：Anastomotic leakage (AL) limits the outcome after laparoscopic anterior resection (LAR) for middle-low rectal cancer. The study investigated the efficacy of laparoscopic anastomosis enhancing suture (LAES), preventive ileostomy and transanal drainage tube placement in reducing anastomotic leakage after LAR for middle-low rectal cancer.

Methods：From April 2016 to April 2019, a prospective cohort study was performed on consecutive patients who underwent LAR for middle-low rectal cancer in Changzheng hospital. The patients were divided into group A, B, C and D in which LAES, transanal drainage tube placement, protective ileostomy, and no preventive treatment were applied, respectively. Clinical characteristics, operative variables and postoperative complication were compared between the groups.

Results：Among 320 patients, 24 (7.5%) developed AL and incidence rate of AL was 1.3%, 12.5%, 1.3% and 15.0% in the four groups, respectively. Left colic artery preservation and neoadjuvant chemotherapy were found not associated with the incidence of AL. A total of 0, 2, 2 and 5 patients had anastomotic bleeding in the four groups, respectively. No patient underwent reoperation in group A and group C, while 5.0% (4/80) of the patients had reoperation in group B and group D due to grade C AL with severe symptoms.

Conclusions：Compared with preventive ileostomy, LAES was effective in preventing AL after LAR for middle-low rectal cancer and relieving the complications of AL. The transanal drainage tube placement did not reduce the risk of AL.

The study was retrospectively registered with the Chinese Clinical Trial Registry on 28th June 2016 (code: ChiCTR-IOR-17011777).

What Does This Paper Add To The Literature?

In the current prospective cohort study, we observed the efficacy of a new suture technique, naming laparoscopic anastomosis enhancing suture (LAES) in preventing anastomotic leakage after laparoscopic anterior resection (LAR) for middle-low rectal cancer, and found that LAES is effective in lowering the incidence of AL.

Background

Laparoscopic anterior resection (LAR) with total mesorectal excision (TME) has been the cornerstone in the treatment of middle-low rectal cancers[1]. However, anastomotic leakage (AL) remains one of the most devastating complications with an incidence ranging from 1.3 to 12.9 %[2–4]. The risk factors can be classified as patient-related factors and operation-related factors. Patient-related factors mainly consist of male sex, higher body mass index (BMI), diabetes mellitus and smoking, while operation factors included lower tumor location, larger tumor size, more intraoperative blood loss and longer operation time, etc[5, 6]. Many solutions, including defunctioning stoma (DS) and transanal drainage tube (TDT)

placement, have been proposed to address the problem of AL and its complications. Despite its efficacy in preventing AL, defunctioning stoma has been overused in current surgical practice, while the effectiveness of transanal drainage tube placement needs to be confirmed with further studies[7–10].

With the development of laparoscopic techniques, laparoscopic anastomotic enhancing suture (LAES) has come into sight to lower anastomotic tension and reduce risks of AL. The purpose of this study was to investigate whether laparoscopic anastomosis enhancing suture can reduce AL following LAR for middle-low rectal cancer.

Method

Study population

From January 2016 to April 2019, 320 cases of middle-low rectal cancer undergoing LAR with TME and double-stapling technique (DST) in Changzheng hospital were enrolled in this prospective cohort study. All the patients underwent standard treatment for CRC according to the Chinese guideline 2017. The eligibility criteria were as follows: 1) age: over 18 years; 2) tumor location: 5 ~ 8cm from the anal verge; 3) pathologic stage: Tis/T1 ~ 4a, N0-2, M0, AJCC-7th TNM stage); 4) American Society of Anesthesiologist (ASA) function: class I to class III. The exclusion criteria included: 1) age: younger than 18 years; 2) tumor location: less than 5cm or greater than 8cm from the anal verge; 3) emergency surgery for intestinal perforation or obstruction; 4) self-expanding stent insertion for obstruction; 5) preoperative major pelvic surgery; 6) neoadjuvant radiotherapy; 7) locally advanced(T4b) and/or distant metastasis; 8) recurrent rectal cancer; 9) Patients with severely compromised cardio-pulmonary function were also excluded.

Eligible patients were divided into A, B, C and D groups in which LAES, TDT placement, DS, and no preventive treatment were applied, respectively. Each group included 80 cases and preventive measures used in the four groups were the routine operative techniques of the four surgical teams, which were all led by senior surgeons with more than 20 years' experience in TME and laparoscopic surgery.

The study was approved by the Ethics Committee of the Changzheng hospital and was registered with the Chinese Clinical Trial Registry (code: ChiCTR-IOR-17011777) in June 2016.Written inform consent was obtained from all the patients enrolled in this study.

Surgery procedure

The establishment of anastomosis was performed with standard practice according to the Chinese expert consensus on diagnosis, prevention and treatment of rectal anastomotic leakage of 2019[11]. Good blood supply and low longitudinal tension were confirmed by the senior surgeons.

After the construction of anastomosis, LAES was performed in group A patients as shown in Fig. 1. The anterior half of anastomosis was reinforced with knotless absorbable sutures (Quill RA*, 3 – 0 PDO suture) and 26mm, 3/8 circle needles in a running full-layer fashion. In the process of LAES, we recommend the first suture be medially placed in the front part of the anastomosis, which could make the

following sutures easier, especially when the pelvis is narrow or the anastomosis is close to the anus. We didn't suture the whole circumference of the anastomosis as anastomotic stenosis could occur postoperatively.

In Group B, transanal drainage tube (Marecot catheter, 28Fr, 1.0cm diameter) was placed 3-5cm from the anastomotic site without any resistance and the tube was fixed with skin sutures and connected to a drainage bag (Fig. 2). Protective ileostomy was performed in group C and no additional preventive treatment were used in group D.

After discharge, patients were followed in accordance with a standardized protocol, in which the patients underwent abdominal computed tomography scan and colonoscopy every 3 months for the first 6 months after operation, every 3 months for the next 18 months and every 6 months afterwards. All the imaging outcomes were carefully analyzed by the experienced radiologists and surgeons. Information on recurrence date, last follow-up, and death were recorded.

Definition of anastomotic leakage

The endpoint in the study was occurrence of anastomotic leakage. According to the definition of the International Study Group of Rectal Cancer (ISREC)[12, 13], AL in this study was defined as postoperative signs of peritonitis with high fever caused by leakage from any surgical stapler line, recto-vaginal fistula, or pelvic abscess upon clinical assessment. Diagnosis of AL was made based on feces, pus or gas from the abdominal drain or a peri-anastomotic abscess, and confirmed by CT scan, ultrasonic examination, rectoscopy and/or radiological investigations. AL was classified into Grade A□B and C on the basis of the definition proposed by Rahbari et al[13]. All the patients diagnosed with clinical AL in the study were identified within 30 days. Anastomotic Bleeding (AB) was defined as fresh blood or clots deriving from the anus or TDT and confirmed by postoperative colonoscopy.

Clinicopathologic and operative variables

Detailed information on clinicopathologic and operative variables was carefully collected from patients. Patient-related information included demography like weight, height, gender, preoperative serum hemoglobin, albumin, and history of neoadjuvant chemotherapy. Operation-related variables included operation time, intraoperative blood loss, left colonic artery preservation, tumor size, tumor location, anastomosis level, postoperative pathology, AL, AB, anastomotic stricture intestinal obstruction, postoperative hospital stay, treatment cost and complications (using Clavien-Dindo classification system). Concentration of serum hemoglobin, albumin, pre-albumin and pre-operative carcinoembryonic antigen (CEA) were obtained one week before the surgery.

Statistical analysis

All statistical analyses were performed in SPSS statistical package (version 19.0; IBM, Chicago, USA). Continuous variables were expressed as the means ± standard deviation. Differences of continuous variables between the groups were compared with one-way analysis of variance (ANOVA), Kruskal-Wallis test and Least significant difference test (LSD-test). Differences in the distribution of categorical variables

were analyzed with Chi-squared test. All the statistical and $P < 0.05$ was considered statistically significant.

Results

Clinical characteristics

All the patients in four groups underwent successful laparoscopic operations without conversion to laparotomy. The patients' demographic and clinical data were shown in Table 1. There was no significant difference between the 4 groups in terms of age, gender, body mass index, comorbidities, serum hemoglobin, albumin, pre-albumin, pre-operative CEA concentration and ASA score ($P > 0.05$).

Table 1
Comparisons of patients' demographical characteristics and operative variables and perioperative outcomes after construction of rectal anastomosis

Variable	Anastomosis reinforcement suture (N = 80)	Transanal drainage tube (N = 80)	Protective ileostomy (N = 80)	No preventive treatment (N = 80)	P
Age (years)*	61.6 ± 10.4	58.6 ± 10.6	64.3 ± 9.8	62.3 ± 9.1	0.013
Sex (male)	44(55.0%)	53(66.2%)	55(68.7%)	60(75.0%)	0.058
BMI (kg/m^2)*	23.1 ± 2.9	22.6 ± 2.9	23.1 ± 3.2	23.6 ± 3.2	0.406
Hemoglobin(g/L)*	127.5 ± 17.5	134.2 ± 14.0	130.6 ± 15.0	134.5 ± 14.5	0.057
Albumin(g/L)*	39.9 ± 4.4	41.2 ± 4.8	39.1 ± 4.1	40.2 ± 4.7	0.043
Pre-Albumin(mg/L)*	249.0 ± 73.2	250.1 ± 73.1	238.5 ± 65.4	223.3 ± 68.6	0.175
Preoperative CEA ≥ 5.0 ug/L	31(38.8%)	32(40.0%)	32(40.0%)	31(38.8%)	0.997
ASA score > 2	33(41.3%)	36(40.0%)	34(42.5%)	29(36.3%)	0.866
Tumor Size(cm)*	3.5 ± 1.2	3.8 ± 1.0	3.5 ± 1.1	3.5 ± 1.0	0.329
Tumor location(cm)*					
Male + Female	7.1 ± 0.8	6.4 ± 0.8	7.3 ± 0.7	7.6 ± 0.5	< 0.001
Male	7.3 ± 0.5	7.3 ± 0.7	6.6 ± 0.7	7.6 ± 0.5	
Female	6.8 ± 0.9	7.2 ± 0.8	6.0 ± 0.9	7.7 ± 0.5	
Operation time (min)*	150.7 ± 54.4	122.0 ± 24.9	160.6 ± 46.9	125.1 ± 34.9	< 0.001
Intraoperative blood loss > 150 ml	49(61.2%)	52(65.0%)	39(48.8%)	53(66.2%)	0.093
TNM stage					
0-II	51(63.7%)	44(55.0%)	53(66.2%)	49(61.2%)	0.500
III	29(36.3%)	36(45.0%)	27(33.8%)	31(38.8%)	
Tumor poor differentiation	2(3.2%)	3(4.4%)	4(6.2%)	3(4.8%)	0.988
Number of lymph nodes harvested	13(10,17)	13(10,17)	14(11,17)	15(11,18)	0.266

* Values are mean ± standard deviation or median with range unless otherwise indicated.

Variable	Anastomosis reinforcement suture (N = 80)	Transanal drainage tube (N = 80)	Protective ileostomy (N = 80)	No preventive treatment (N = 80)	P
Left colonic artery preservation	44(55.0%)	41(51.2%)	38(47.5%)	37(46.3%)	0.682
Anastomosis location (cm)*					< 0.001
Male + Female	5.1 ± 0.7	4.4 ± 0.7	5.2 ± 0.7	5.0 ± 0.8	< 0.001
Male	5.3 ± 0.6	5.2 ± 0.7	4.4 ± 0.6	5.1 ± 0.7	
Female	4.8 ± 0.7	5.2 ± 0.8	4.2 ± 0.7	7.7 ± 0.5	
Anastomotic leakage	1(1.3%)	10(12.5%)	1(1.3%)	12(15.0%)	< 0.001
Grade A/B	1(1.3%)	6(7.5%)	1(1.3%)	8(10.0%)	0.019
Grade C	0	4(5.0%)	0	4(5.0%)	0.042
Anastomotic bleeding	0	2(2.5%)	2(2.5%)	5(6.3%)	0.120
Anastomotic stricture	0	0	2(2.5%)	0	0.110
Intestinal obstruction	0	2(2.5%)	8(10.0%)	1(1.3%)	0.002
Reoperation	0	4(5.0%)	0	4(5.0%)	0.042
Postoperative hospital stay (d)	7.6 ± 2.7	7.5 ± 2.3	9.3 ± 4.0	12.7 ± 5.1	< 0.001
Treatment cost ($\times 10^4$ yuan)	51.4 ± 9.1	55.2 ± 10.0	59.4 ± 11.5	55.2 ± 10.9	< 0.001

* Values are mean ± standard deviation or median with range unless otherwise indicated.

Operative characteristics

Distance from anal margin to tumor distal edge and distance from anal margin to the anastomosis was measured under the view of the rigid rectoscope after anesthesia. The operative characteristics were shown in Table 1. Operation time, left colic artery preservation, estimated intra-operative blood loss, distance from anal margin to tumor distal edge, tumor size and distance from anal margin to the anastomosis were compared among the four groups. There was a significant difference among the four groups in the operation time ($P < 0.001$). The average operation time of group A (150.7 ± 54.4min) was significantly longer than that of group B(122.0 ± 24.9min) and group D(125.1 ± 34.9min) ($P < 0.001$) but similar with group C. The rate of left colic artery preservation, intra-operative estimated blood loss and

tumor size did not differ among the four groups ($P > 0.05$). The average distance from anal margin to tumor distal edge of group A (7.1 ± 0.8cm) was significantly shorter than that of group B(7.3 ± 0.7cm) and longer than that of group C(6.4 ± 0.8cm) ($P < 0.001$). The average distance from anal margin to anastomosis of group A (5.1 ± 0.7cm) was similar with that of group B(5.2 ± 0.7cm) ($P = 0.155$) and that of group D(5.0 ± 0.8cm) ($P = 0.776$), but longer than that of group C(4.4 ± 0.7cm) ($P < 0.001$).

Postoperative characteristics

The postoperative characteristics were shown in Table 1, and the patients' comorbidities and pathological types were summarized in eTable 1. There was no case of positive circumferential resection margin among the four groups. The postoperative hospital stay, TNM tumor stage, number of lymph nodes harvested, pathological type, and differentiation level of carcinoma were compared among the four groups. There was a significant difference between the four groups in the postoperative hospital stay($P < 0.001$). The postoperative hospital stay of group A(7.6 ± 2.7d) was similar with group B(7.5 ± 2.3d) ($P = 0.962$), and significantly shorter than group C and group D (9.3 ± 4.0d, $P = 0.962$; 12.7 ± 5.1d, $P < 0.001$, respectively). There were no significant differences among the four groups in terms of TNM tumor stage, number of lymph nodes harvested, pathological type and differentiation levels of carcinoma ($P > 0.05$).

Complications

As shown in Table 1, overall incidence rate of AL was 7.5 %. The complications and reoperation rate among the four groups was compared. The rate of AL was 1.3%, 12.5%, 1.3%, 15.0% in group A, B, C and D, respectively. Both group A and group C had one patient of grade B AL, which was treated with conservative treatment. But four patients of grade C AL occurred in both group B and D, in which the incidence rate of AL was significantly higher than that in group A and C($P < 0.05$).

A total of 0, 2, 2 and 5 patients had AB in the four groups, respectively, without significant difference($P > 0.05$). Two cases of anastomotic stricture occurred in group C. Postoperative intestinal obstruction happened in 8 patients of group C, 2 patients of group B and one patient of group D, while none in group A. Compared with the other groups, intestinal obstruction rate after operation in group C was significantly higher ($P < 0.05$). There was no significant difference in comorbidities such as pulmonary infection, heart failure or arrhythmia, urinary retention and infection among the 4 groups ($P > 0.05$). There were 4 cases of postoperative anastomotic stenosis in the group C, which was considered related to the disuse of anastomotic site and the lower site of the anastomosis.

Treatment cost

The average treatment cost was shown in Table 1. There were significant differences among the four groups in the treatment cost ($P < 0.001$). The treatment cost in group A (51.4 ± 9.1 thousand yuan) was significantly lower than the other three groups (group B, 55.2 ± 10.0 thousand yuan; group C, 59.4 ± 11.5 thousand yuan; group D, 55.2 ± 10.9 thousand yuan) ($P < 0.001$).

In addition, there were 2 cases of incision infection, 2 cases of postoperative incisional hernia and 1 case of intraperitoneal bleeding in the second hospitalization for stoma reversal in group C. The second

average treatment cost in group C was 21.5 ± 4.6 thousand yuan, and second average postoperative hospital stay was 6.7 ± 2.0d.

Discussion

In the current study, we compared the incidence of AL in patients who underwent four different postoperative treatments after LAR for middle-low rectal cancer, and the results showed that the effect of LAES in preventing postoperative AL is the same as defunctioning stoma. The LAES technique made possible the laparoscopic resection of rectal cancer within 6.5cm from the anal verge for male patients, and 5cm for female patients. Tumors within 5cm from the anal margin could be resected safely by means of intersphincteric resection with the help of LAES. Considering the different distance of levator ani muscle to anal skin between the male and female, we recommend the anastomotic site be higher than levator ani muscle level for the achievement of LAES. Also, the anastomotic site was likely to be compressed and squeezed by the surrounding muscles, and LAES could provide resistance to the compression.

We believe that the satisfying performance of LAES in preventing AL can be explained as follows. First, enhancing suture could improve the resistance to transverse tension in that the enhancing suture fixes a half of the anastomosis and the other part could be protected from over extension, especially when the pressure in rectum suddenly increase. Second, LAES provides reliable fixation in the triangle area of the anastomosis, where AL frequently occurs. Third, the application of spiral suture averages the tension and avoid cutting of the tissue.

In this study, LAES also show definite effect in prevent postoperative AB and anastomotic stenosis. LAES is a simple, easy-to-perform and cost-effective technique. Of note, edema and thickening of the anastomotic site were easy to be mistaken with local recurrence within 3–6 months after surgery, which can be excluded by colonoscopy and pathological biopsy. Usually, thickening of the anastomotic site was gradually improved after 6 months postoperatively.

The importance of anastomotic tension on the incidence of AL has been fully realized by surgeons. As suggested by the Chinese expert consensus on diagnosis, prevention and treatment of rectal anastomotic leakage, sigmoid colon should be attached to the anterior side of sacrum after rectal anastomosis, avoiding bridge-like suspending, in order to prevent longitudinal tension on the anastomosis. According to our experience, the occurrence of AL is more associated with transverse tension on the anastomosis. Colonic peristalsis usually recovers 48–120 hours postoperatively and the contents in colon (feces, gas, blood, etc.) pass through the anastomosis. The contents are stopped by the constricted anal sphincter because of surgical injury, pain and inflammation, which form the transverse tension on dilatation of anastomosis. However, 48–120 hours postoperatively, edema of the anastomosis is happening that edema results in decreased tissue resistance to the shear force from staples and incidence of AL. Routine measures to lower the transverse tension on the anastomosis include reducing colon content (e.g.

preventive ileostomy and TDT, etc.) and enhancing anastomotic tissue resistance to the radial sheer force (e.g. reinforcement with glue and LAES, etc.).

Recently, preventive enterostomy is popular in many medical institutions to reduce the incidence of postoperative AL or relieve the complications of AL. More studies suggested that preventive enterostomy could reduce the incidence of symptomatic anastomotic leakage and avoid reoperation after LAR for rectal cancer[14, 15]. Therefore, although a preventive enterostomy reduces the risk of AL, there are several problems associated with preventive enterostomy such as stoma prolapsed, retraction, stenosis, bleeding, incision infection, parastomal hernia, postoperative incisional hernia, stoma re-creation and permanent stoma, all leading to unsatisfied life quality after operation[16–18]. Thus, it is important to reduce preventive enterostomy rate reasonably without increasing the risk of AL after LAR for middle-low rectal cancer and improve the patients' life quality after operation.

It is still controversial whether TDT placement can reduce the incidence of AL after LAR for rectal cancer. Several studies have reported the effect of transanal tube placement for the prevention of AL after LAR[10, 19–21]. However, Lee SY et al. reported that transanal tube placement did not prevent AL[22]. Our results also showed that TDT placement does not help to prevent the development of AL, which may be related to the diameter, material and depth of the tube. More clinical studies are needed to prove the efficacy of TDT, and we have been conducting a new clinical trial on the effect of membrane covered TDT in preventing AL.

There were also some limitations in our study. First, the study was not a randomized controlled study and was conducted at a single institution. Second, because of different surgeons performed the operation in this study, there is a theoretical influence of surgeon factors on AL and multicenter database is needed to prove the advantages of the LAES. Third, because of low incidence rate and small sample size, the study was underpowered to perform subgroup analyses for AB and anastomotic stenosis. Nevertheless, our results suggest that LAES plays different roles in preventing AL.

To our knowledge, this is the first study comparing the effect of LAES, transanal drainage tube and preventive enterostomy in preventing AL. In this study, although only rectal cancers within 5–8 cm from the anal verge were included, we believe that LAES is also effective for the rectal cancers higher than 8cm from the anal verge. Further studies are still needed to confirm our hypotheses.

Our results show that, compared with TDT and preventive ileostomy, LAES is effective in preventing AL and AB after LAR for middle-low rectal cancer. LAES is also cost-effective and can bring better life quality for patients and thus is worth of further clinical application.

Drs. Jin-Shui Chen, Jia Zang, Shu-Xun Wei, Wen-Tao Yan, Hai-Yang Zhou, Can-Ping Ruan, Wei-Jun Wang, Yi Wang, Yan-Ping Sun, Jian Zhang, Zhi-Qian Hu have no conflicts of interest or financial ties to disclose.

Declaration

Ethics approval, guidelines and consent to participate

The study was approved by the Ethics Committee of the Changzheng hospital and was registered with the Chinese Clinical Trial Registry (code: ChiCTR-IOR-17011777) in June 2017. The study was performed in accordance with the ethical standards of the Declaration of Helsinki (1964) and its subsequent amendments. Written inform consent for the publication of personal/clinical data was obtained from all the patients enrolled in this study.

Abbreviations

LAR, laparoscopic anterior resection; TME, total mesorectal excision; DST, double-stapling technique; LAES, laparoscopic anastomosis enhancing suture; DS, defunctioning stoma; TDT, Transanal drainage tube; AL, Anastomotic leakage; AB, anastomotic bleeding; AS, anastomotic stricture; ASA-PS, American Society of Anesthesiologists Physical Status; CEA, Carcinoembryonic antigen; BMI, body mass index; ANOVA, Analysis of Variance; LSD-test, least significant difference test.

Declarations

Ethics approval, guidelines and consent to participate

The study was approved by the Ethics Committee of the Changzheng hospital and was registered with the Chinese Clinical Trial Registry (code: ChiCTR-IOR-17011777) in June 2017. The study was performed in accordance with the ethical standards of the Declaration of Helsinki (1964) and its subsequent amendments. Written inform consent for the publication of personal/clinical data was obtained from all the patients enrolled in this study.

Consent for publication

Written inform consent for the publication of personal/clinical data was obtained from all the patients enrolled in this study.

Availability of data and materials

The datasets used and/or analyzed during the current study are available from the corresponding author on reasonable request.

Competing interests

No competing interests to declare.

Funding

Funding for the study was provided by the National Science and Technology Foundation for extraordinary young scholars of China (No. 2019-JCJQ-ZQ-002).

Authors' contributions

Drs Jin-Shui Chen, Jia Zang, Shu-Xun Wei and Wen-Tao Yan contributed equally to this work. Dr Zhang had full access to all the data in the study and take responsibility for the integrity of the data and the accuracy of the data analysis.

Study concept and design: Chen, Zang, Wei, Yan, Zhou, Ruan, Sun, Zhang, Hu.

Acquisition, analysis, or interpretation of data: Chen, Zang, Wei, Yan, Zhou, Ruan, Sun, W. Wang, Y. Wang, Zhang, Hu.

Drafting of the manuscript: Chen, Zang, Wei, Yan, Zhang.

Critical revision of the manuscript for important intellectual content: Chen, Yan, Zhang.

Statistical analysis: Chen, Zang, Wei, Yan, Zhang.

Obtained funding: Zhang.

Administrative, technical, or material support: Chen, Zang, Wei, Zhang, Hu. **Study supervision:** Zhang, Hu.

Acknowledgements

None

Study concept and design: Chen, Zang, Wei, Yan, Zhou, Zhang, Hu. **Acquisition, analysis, or interpretation of data:** Chen, Zang, Wei, Yan, Zhou, W. Wang, Y. Wang, Zhang, Hu. **Drafting of the manuscript:** Chen, Zang, Wei, Yan, Zhang. **Critical revision of the manuscript for important intellectual content:** Chen, Yan, Zhang. **Statistical analysis:** Chen, Zang, Wei, Yan, Zhang. **Obtained funding:** Zhang. **Administrative, technical, or material support:** Chen, Zang, Wei, Zhang, Hu. **Study supervision:** Zhang, Hu.

Conflict of Interest Disclosures: None reported.

Role of the Funder/Sponsor: The funding sources had no role in the design and conduct of the study; collection, management, analysis, and interpretation of the data; preparation, review, or approval of the manuscript; and decision to submit the manuscript for publication.

References

1. Zhang L, Xie Z, Zhang W, Lin H, Lv X. Laparoscopic low anterior resection combined with "dog-ear" invagination anastomosis for mid- and distal rectal cancer. Tech Coloproctol. 2018;22(1):65–8.
2. Zanguie M, Abdollahi A, Salek R, Jangjoo A, Jabbari Nooghabi M, Shabahang H, Golmohammadzadeh H. Three Anastomotic Techniques Following Laparoscopic Rectal Cancer Resection: Our Experience in 155 Patients. Surg Innov. 2018;25(1):57–61.

3. Kawada K, Hasegawa S, Hida K, Hirai K, Okoshi K, Nomura A, Kawamura J, Nagayama S, Sakai Y. Risk factors for anastomotic leakage after laparoscopic low anterior resection with DST anastomosis. Surg Endosc. 2014;28(10):2988–95.
4. Lim SB, Yu CS, Kim CW, Yoon YS, Park IJ, Kim JC. The types of anastomotic leakage that develop following anterior resection for rectal cancer demonstrate distinct characteristics and oncologic outcomes. Int J Colorectal Dis. 2015;30(11):1533–40.
5. Trencheva K, Morrissey KP, Wells M, et al. Identifying important predictors for anastomotic leak after colon and rectal resection: prospective study on 616 patients. Ann Surg. 2013;257(1):108–13.
6. Warschkow R, Steffen T, Thierbach J, Bruckner T, Lange J, Tarantino I. Risk factors for anastomotic leakage after rectal cancer resection and reconstruction with colorectostomy. A retrospective study with bootstrap analysis. Ann Surg Oncol. 2011;18(10):2772–82.
7. Snijders HS, van den Broek CB, Wouters MW, et al. An increasing use of defunctioning stomas after low anterior resection for rectal cancer. Is this the way to go. Eur J Surg Oncol. 2013;39(7):715–20.
8. Garg PK, Goel A, Sharma S, Chishi N, Gaur MK. Protective Diversion Stoma in Low Anterior Resection for Rectal Cancer: A Meta-Analysis of Randomized Controlled Trials. Visc Med. 2019;35(3):156–60.
9. Waterland P, Goonetilleke K, Naumann DN, Sutcliff M, Soliman F. Defunctioning Ileostomy Reversal Rates and Reasons for Delayed Reversal: Does Delay Impact on Complications of Ileostomy Reversal? A Study of 170 Defunctioning Ileostomies. J Clin Med Res. 2015;7(9):685–9.
10. Wang S, Zhang Z, Liu M, Li S, Jiang C. Efficacy of transanal tube placement after anterior resection for rectal cancer: a systematic review and meta-analysis. World J Surg Oncol. 2016;14:92.
11. Zhang ZT. Chinese expert consensus on diagnosis, prevention and treatment of rectal anastomotic leakage. Zhonghua Wei Chang Wai Ke Za Zhi. 2019;22(3):201–6.
12. Matsuda K, Hotta T, Takifuji K, Yokoyama S, Watanabe T, Mitani Y, Ieda J, Iwamoto H, Mizumoto Y, Yamaue H. Clinical characteristics of anastomotic leakage after an anterior resection for rectal cancer by assessing of the international classification on anastomotic leakage. Langenbecks Arch Surg. 2015;400(2):207–12.
13. Rahbari NN, Weitz J, Hohenberger W, Heald RJ, Moran B, Ulrich A, Holm T, Wong WD, Tiret E, Moriya Y, Laurberg S, den Dulk M, van de Velde C, Büchler MW. Definition and grading of anastomotic leakage following anterior resection of the rectum: a proposal by the International Study Group of Rectal Cancer. Surgery. 2010;147(3):339–51.
14. Abudeeb H, Hammad A, Ugwu A, Darabnia J, Malcomson L, Maung M, Khan K, Mclaughlin C, Mukherjee A. Defunctioning stoma- a prognosticator for leaks in low rectal restorative cancer resection: A retrospective analysis of stoma database. Ann Med Surg (Lond). 2017;21:114–7.
15. Mrak K, Uranitsch S, Pedross F, Heuberger A, Klingler A, Jagoditsch M, Weihs D, Eberl T, Tschmelitsch J. Diverting ileostomy versus no diversion after low anterior resection for rectal cancer: A prospective, randomized, multicenter trial. Surgery. 2016;159(4):1129–39.
16. Song O, Kim KH, Lee SY, Kim CH, Kim YJ, Kim HR. Risk factors of stoma re-creation after closure of diverting ileostomy in patients with rectal cancer who underwent low anterior resection or

intersphincteric resection with loop ileostomy. Ann Surg Treat Res. 2018;94(4):203–8.

17. Holmgren K, Kverneng Hultberg D, Haapamäki MM, Matthiessen P, Rutegård J, Rutegård M. High stoma prevalence and stoma reversal complications following anterior resection for rectal cancer: a population-based multicentre study. Colorectal Dis. 2017;19(12):1067–75.
18. Haksal M, Okkabaz N, Atici AE, Civil O, Ozdenkaya Y, Erdemir A, Aksakal N, Oncel M. Fortune of temporary ileostomies in patients treated with laparoscopic low anterior resection for rectal cancer. Ann Surg Treat Res. 2017;92(1):35–41.
19. Hidaka E, Ishida F, Mukai S, Nakahara K, Takayanagi D, Maeda C, Takehara Y, Tanaka J, Kudo SE. Efficacy of transanal tube for prevention of anastomotic leakage following laparoscopic low anterior resection for rectal cancers: a retrospective cohort study in a single institution. Surg Endosc. 2015;29(4):863–7.
20. Matsuda M, Tsuruta M, Hasegawa H, Okabayashi K, Kondo T, Shimada T, Yahagi M, Yoshikawa Y, Kitagawa Y. Transanal drainage tube placement to prevent anastomotic leakage following colorectal cancer surgery with double stapling reconstruction. Surg Today. 2016;46(5):613–20.
21. Shigeta K, Okabayashi K, Baba H, Hasegawa H, Tsuruta M, Yamafuji K, Kubochi K, Kitagawa Y. A meta-analysis of the use of a transanal drainage tube to prevent anastomotic leakage after anterior resection by double-stapling technique for rectal cancer. Surg Endosc. 2016;30(2):543–50.
22. Lee SY, Kim CH, Kim YJ, Kim HR. Impact of anal decompression on anastomotic leakage after low anterior resection for rectal cancer: a propensity score matching analysis. Langenbecks Arch Surg. 2015;400(7):791–6.

Figures

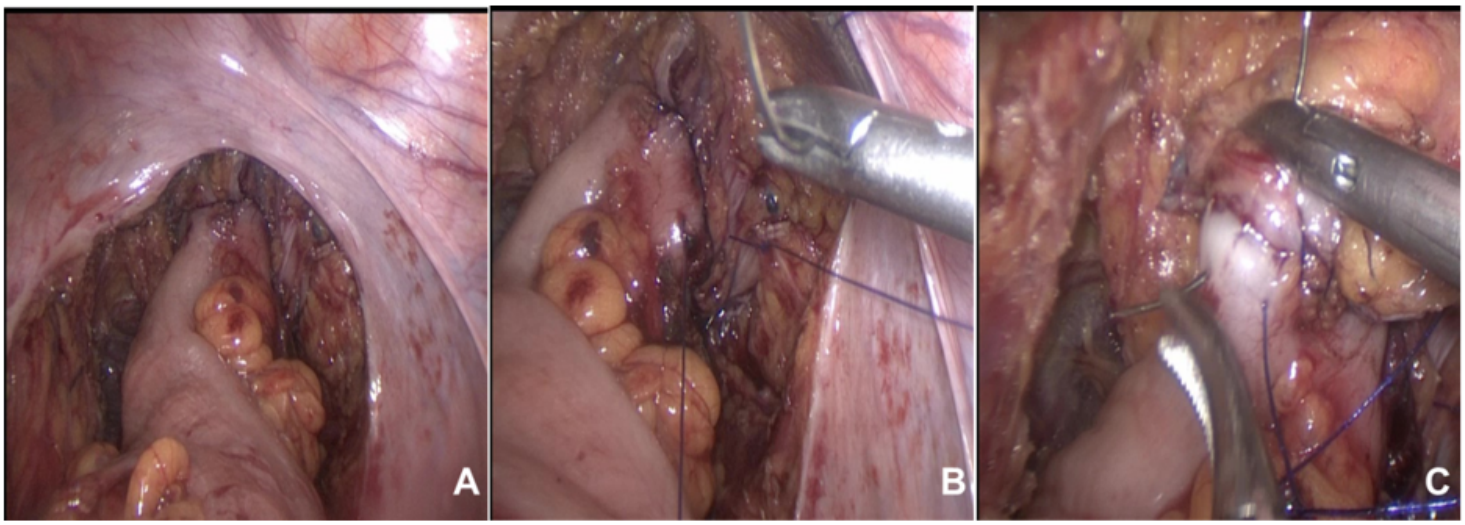

Figure 1

Procedure and Outcomes of Laparoscopic Anastomosis Reinforcement Suture A. End-to-end anastomosis was reconstructed using circular stapler. B. The first suture was medially placed in the front

part of the anastomosis. C. The anterior half of anastomosis was reinforced with knotless absorbable sutures in a running full-layer fashion.

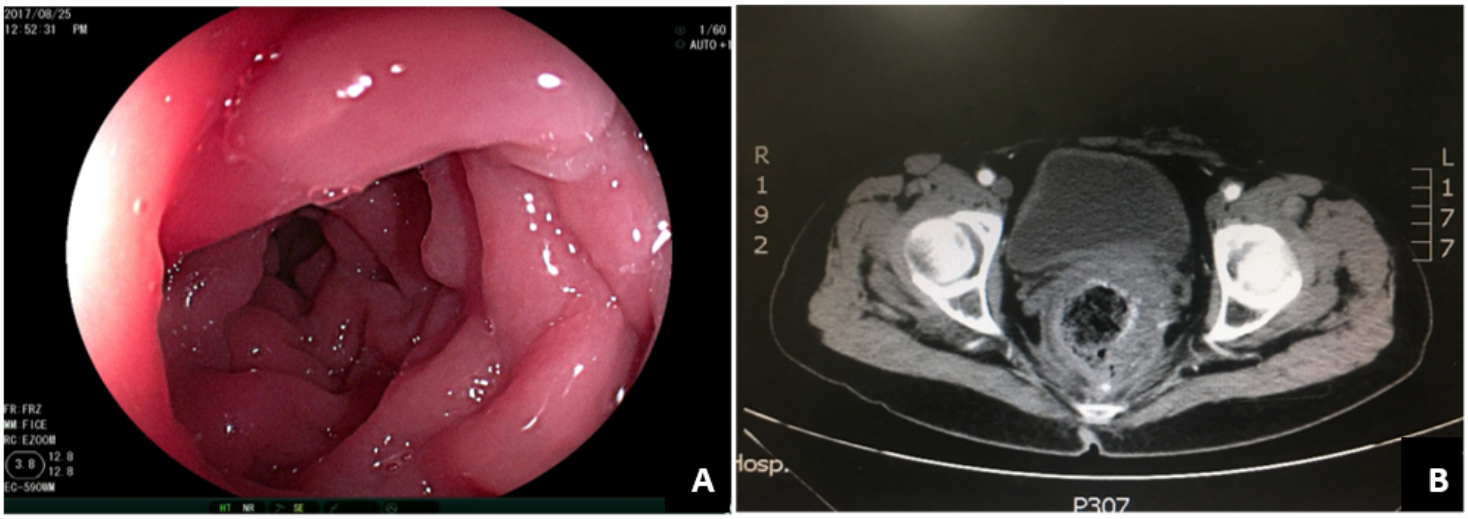

Figure 2

Imaging Outcomes of Laparoscopic Anastomosis Reinforcement Suture A. Colonoscopy showed the mucosa at the anastomotic site was smooth and no ulcer or neoplasm was found. B. Abdominal enhanced computed tomography scan 3 months after surgery showed that the wall of anastomotic site was locally thickened.

Supplementary Files

This is a list of supplementary files associated with this preprint. Click to download.

- Supplementarymaterial.doc