Outcomes of combined open-door laminoplasty with bilateral lateral mass screw fixation for traumatic unstable multilevel cervical stenosis: A retrospective case study

Guanyi Liu
Ningbo No. 6 Hospital
Lihua Hu
Ningbo No. 6 Hospital
Yongjie Gu
Ningbo No. 6 Hospital
Weihu Ma (weihu_ma@163.com)
Ningbo No. 6 Hospital

Research Article

Keywords: internal fixation, cervical spine, fracture

Posted Date: May 25th, 2022

DOI: https://doi.org/10.21203/rs.3.rs-1658467/v1

Abstract

Background

The purpose of this study was to report the outcomes of combined open-door laminoplasty with bilateral lateral mass screw fixation for traumatic unstable multilevel cervical stenosis.

Methods

Data from 11 patients who underwent combined open-door laminoplasty with bilateral lateral mass screw fixation for multilevel cervical stenosis with traumatic cervical instability and spinal cord injury between July 2016 and January 2020 were retrospectively reviewed. Patients treated via the anterior approach and those who did not undergo open-door laminoplasty were excluded. Neurological functional recovery was evaluated using the pre- and postoperative Japanese Orthopaedic Association (JOA) scores and Nurick scores.

Results

All patients underwent operative treatment without neurovascular complications. The average duration of follow-up was 26 months (range, 24 to 30 months). The mean JOA score improved from 5.0 ± 2.68 preoperatively to 12.54 ± 4.39 at final follow-up, and the mean JOA recovery rate was 61.5%. The mean Nurick disability score decreased from 3.27 ± 1.42 preoperatively to 1.45 ± 1.21 at final follow-up. Significant neurogenic recovery was indicated by both the JOA score ($t=-4.86$, $p = 0.000$) and the Nurick disability score ($t = 3.22$, $p = 0.009$). All patients achieved bone union of cervical fractures and fusion at an average of 3.5 weeks postoperatively (range, 12–16 weeks). No patient had segmental instability, laminar collapse, or internal fixation failure on postoperative radiographs.

Conclusion

Our findings suggest that combined open-door laminoplasty with lateral mass screw fixation achieves satisfactory cervical function in select patients with traumatic unstable multilevel cervical stenosis and spinal cord injury.

Background

Multilevel (more than three levels) cervical spondylotic myelopathy caused by ossification of the posterior longitudinal ligament or disc herniation is a common disease, and requires surgical treatment in patients with severe symptoms [1]. Surgery is performed via either the anterior or posterior approach. Degenerative multilevel cervical spondylotic myelopathy is most commonly treated using laminectomy with or without screw fixation and laminoplasty through the posterior approach [1, 2]. However, the optimal surgical technique for treating multilevel cervical stenosis caused by cervical spondylotic myelopathy with traumatic instability and spinal cord injury remains controversial [3–5].

In 2013, Son et al. [6] reported the successful combined use of open-door laminoplasty with unilateral screw fixation on the hinged side in six patients with unstable multilevel cervical stenosis, spinal cord signal changes, and cervical instability or kyphotic deformity. However, few studies have evaluated the combined use of bilateral lateral mass screw fixation and open-door laminoplasty for multilevel cervical stenosis with spinal cord injury. The present study aimed to evaluate the clinical application of open-door laminoplasty in combination with bilateral lateral mass screw fixation in patients with traumatic spinal cord injury and unstable multilevel cervical stenosis.

Methods

Between July 2016 and January 2020, 70 consecutive patients underwent cervical internal fixation and decompression of traumatic cervical instability via the posterior approach performed at our institution by an experienced orthopedic surgeon (G.Y.L). Eleven of 70 patients underwent combined open-door laminoplasty with bilateral lateral mass screw fixation for multilevel cervical stenosis with

traumatic cervical instability and were included in the present study. Patients treated via the combined anterior approach and those who did not undergo open-door laminoplasty were excluded.

The study protocol was approved by the Ethical Review Board of Ningbo No. 6 Hospital (approval no. L2022068). After reviewing the medical records and radiographs in our electronic medical record and imaging databases, we invited all patients who met the study inclusion and exclusion criteria to return to our hospital for follow-up clinical and radiographic evaluation. No patients were lost to follow-up.

All patients underwent routine computed tomography (CT) and magnetic resonance imaging (MRI) before surgery. CT was performed to identify small fractures. MRI was used to diagnose multilevel spinal cord compression and showed that no patient in the present cohort had posterior disc herniation compressing the anterior spinal cord. Dynamic plain radiography was not used to confirm segmental instability because all patients had traumatic injuries of the cervical ligaments or cervical vertebral fractures. Specific information for each patient is shown in Table 1.

Table 1
Presentation of the reviewed patients from this series.

Patient No.	Age	Gender	Diagnosis	Laminoplasty level	Screw fixation level	Nurick score before surgery	JOA scores before surgery	Follow-up (months)	Nurick score during follow-up	JOA score during follow-up
1	67	Male	Multi-level cervical canal stenosis Kyphotic deformity Cervical cord injury	C2-6	C3-7	2	6	24	1	16
2	55	Male	Multi-level cervical canal stenosis C5/6 facet fracture ALL injury Cervical cord injury	C3-7	C3-7	5	5	30	1	15
3	70	Male	Multi-level cervical canal stenosis C4-7 fractures Cervical cord injury	C3-7	C4-T2	5	3	26	1	13
4	68	Male	Multi-level cervical canal stenosis C5/6 fracture and dislocation Cervical cord injury	C3-7	C3-T1	5	0	28	5	0
5	58	Male	Multi-level cervical canal stenosis OPLL ALL injury Cervical cord injury	C3-6	C2-6	2	5	25	1	14
6	67	Male	Multi-level cervical canal stenosis C5 fracture Cervical cord injury	C3-7	C4-6	3	11	26	2	14
7	50	Male	Multi-level cervical canal stenosis ALL injury Cervical cord injury	C3-7	C4-6	2	5	27	1	15
8	51	Female	Multi-level cervical canal stenosis ALL injury Cervical cord injury	C3-7	C4-5	3	6	24	1	14
9	65	Male	Multi-level cervical canal stenosis Spondylolisthesis C4-5 ALL injury Cervical cord injury	C3-6	C5-6	2	6	26	1	12

Patient No.	Age	Gender	Diagnosis	Laminoplasty level	Screw fixation level	Nurick score before surgery	JOA scores before surgery	Follow-up (months)	Nurick score during follow-up	JOA score during follow-up
10	58	Male	Multi-level cervical canal stenosis C5 tear-drop fracture Cervical cord injury	C3-7	C4-6	2	5	30	1	11
11	69	Female	Multi-level cervical canal stenosis Spondylolisthesis C4-5 ALL injury Cervical cord injury	C3-7	C3-6	5	3	26	1	14
Mean	59.8	-	-	4.9	4	3.2	5	26.5	1.4	12.5

Operative Technique

The operative details varied depending on the surgical indication, need for decompression and fixation, and number of levels to be included in the spinal construct. Somatosensory-evoked potentials were monitored during surgery to record basic data and detect any iatrogenic spinal cord injury. All patients were placed in the prone position with their head and cervical spine maintained in neutral position using a Mayfield head holder. For patients with unstable cervical spine fractures, Gardner-Wells skull traction tongs were used to reduce the fracture and maintain the alignment of the cervical spine. The spinous processes, laminae, and lateral masses of the posterior cervical spine were exposed in the usual manner.

Posterior open-door laminoplasty was performed using the Hirabayashi technique with titanium miniplates [7]. The side with the most severe symptoms was used as the open side. A high-speed drill was used to create bilateral channels. Before opening the laminae, screws were placed bilaterally and a rod was inserted on the hinged side. Fixation constructs that included C2, C7, T1, and T2 were stabilized with pedicle screws using a previously described technique [8, 9]. For fixation constructs that included the C3–C6 levels, lateral mass screws were placed bilaterally using the technique described by Magerl et al. [10]. The laminae were then opened and fixed in elevated positions using titanium miniplates. Another rod was inserted and fixed on the open side. Finally, the articular cartilage of the facet joints at the screw fixation levels was decorticated using a high-speed drill. Bone chips obtained from the spinous processes or laminae were placed within the joint interfaces.

Postoperative Management And Evaluation

All patients were immobilized with a rigid cervical collar for 12 weeks postoperatively. The postoperative evaluation, including the clinical examination and radiographic evaluation, was performed by an independent observer. Radiographs and CT images were obtained in the immediate postoperative period to confirm the optimal positioning of all instrumentation. At 3–5 months postoperatively, follow-up anteroposterior and lateral radiographs of the cervical spine were obtained to assess the fracture union and instrumentation problems. Fusion was evaluated on dynamic radiographs. If the fusion could not be adequately assessed on radiographs, reconstructed CT images were obtained. When necessary, postoperative MRI was performed to verify the enlargement of the spinal canal and decompression of the spinal cord.

The overall neurological functional result was evaluated using the pre- and postoperative Japanese Orthopaedic Association (JOA) scores and Nurick scores [11]. The JOA recovery rate was calculated from the JOA score data [11].

Data analyses were performed with SPSS 18.0 (SPSS Inc., Chicago, IL). Data are presented as the mean ± standard deviation for continuous variables. The unpaired Student t-test was performed to compare the pre- and postoperative JOA and Nurick scores. All p values were two-sided and values less than 0.05 were considered statistically significant.

Results

The clinical results are summarized in Table 1. The study cohort comprised nine men and two women with a mean age of 61.6 ± 7.4 years. All patients underwent operative treatment without neurovascular complications(Fig. 1). The average duration of follow-up was 26 months (range, 24 to 30 months).

The mean JOA score improved from 5.0 ± 2.68 preoperatively to 12.54 ± 4.39 at final follow-up, and the mean JOA recovery rate was 61.5%. The mean Nurick disability score decreased from 3.27 ± 1.42 preoperatively to 1.45 ± 1.21 at final follow-up. Except for patient 4 who did not show any recovery from a complete cervical spinal cord injury, the overall cohort achieved neurogenic recovery indicated by significant pre- to postoperative improvements in both the mean JOA score ($t=-4.86$, $p = 0.000$) and mean Nurick disability score ($t = 3.22$, $p = 0.009$).

All patients achieved bone union of cervical fractures and fusion at an average of 3.5 weeks (range, 12–16 weeks). No patient had segmental instability, laminar collapse, or internal fixation failure identified on postoperative radiographs. There were no patients with serious persistent neck pain, neurological impairment, infection, or C5 nerve palsy.

Discussion

To our knowledge, this is the first reported case series of traumatic unstable multilevel cervical stenosis and spinal cord injury treated with open-door laminoplasty and screw fixation. The main findings of the present study were: (1) this combined surgical technique was indicated in select patients with multilevel cervical stenosis associated with traumatic cervical instability and spinal cord injury; (2) bilateral posterior cervical screw fixation did not interfere with laminoplasty.

Laminectomy or laminoplasty are the usual treatments of choice for multilevel cervical stenosis caused by cervical spondylotic myelopathy involving more than three levels [12–15]. Posterior laminectomy is widely used to achieve spinal cord decompression in patients with cervical canal stenosis. However, in patients with cervical spondylotic myelopathy and unstable vertebral fractures, posterior laminectomy may aggravate the cervical instability by destroying the posterior structures [12, 13]. Although the use of lateral mass screw fixation in combination with laminectomy reinforces the cervical stability, this results in substantial postoperative scarring [16].

The main aim of laminoplasty is to widen the spinal canal to achieve posterior decompression of the spinal cord. Open-door laminoplasty is a common laminoplasty technique that has advantages such as minimal scarring, early ambulation, and preservation of the range of motion of the cervical spine, and is recommended for degenerative multilevel cervical stenosis [17–19]. However, multilevel cervical stenosis may be associated with traumatic cervical fractures and ligament injuries. Laminoplasty cannot provide spinal stability or maintain the alignment of the cervical spine [17–19], and some patients may even develop chronic progressive kyphosis after laminoplasty [19]. Therefore, laminoplasty alone is not effective for patients with traumatic instability because of cervical fractures or ligament injuries; such patients require additional screw fixation to reinforce the stability of the cervical spine [6, 16, 18, 20, 21].

Posterior cervical fixation is most commonly achieved via bilateral lateral mass screw insertion and bony fusion [9, 10]. Laminoplasty in combination with uni- or bilateral lateral mass screw fixation provides immediate postoperative stabilization and enables early ambulation [20, 21]. Son et al. [6] successfully treated unstable multilevel cervical stenosis with combined open-door laminoplasty and unilateral screw fixation on the hinged side. Tang et al. [22] reported that 20 patients with multilevel cervical spondylotic myelopathy and short-segment instability or correctable local kyphosis who underwent expansive open-door laminoplasty with bilateral lateral mass instrumented fusion showed no implant loosening or laminar collapse on radiographic follow-up. Su et al. [16] reported that expansive open-door laminoplasty in combination with either uni- or bilateral C4–C6 lateral mass screw fixation and fusion without titanium miniplates to avoid door closure achieved satisfactory clinical outcomes in patients with cervical spondylotic myelopathy. We prefer to perform bilateral lateral mass screw fixation on both the open and hinged sides for the following four reasons. (1) It is convenient to place bilateral lateral mass screws and insert a rod on the hinged side before opening the laminae. (2) Lateral mass screws do not usually impede the insertion of titanium miniplates on the open side. (3) Bilateral lateral mass screw insertion may achieve better stability than unilateral fixation. The technique used in the present study achieves immediate stability and removes the need for additional anterior fixation and fusion. A previous study comparing the biomechanical stability of laminoplasty with unilateral lateral mass screw fixation, laminoplasty with bilateral fixation, laminectomy with bilateral fixation, and

laminectomy alone reported that laminectomy alone did not provide stabilization, while laminoplasty with bilateral stabilization provided maximal stabilization [21]. Furthermore, the reported fusion rates are 67% after unilateral lateral mass screw fixation and 92% after bilateral lateral mass screw fixation [18]. (4) The application of internal fixation after laminoplasty may effectively maintain cervical lordosis [20, 22].

The patients included in the present study achieved bone union of cervical fractures and overall good or excellent neurogenic recovery results. The mean JOA recovery rate was 61.5% and the mean Nurick grade improved by 1.5 (from 3 preoperatively to 1.5 at final follow-up). The outcomes of our cohort were comparable to or better than those reported in previous studies with similar patient populations. For example, Su et al. [16] reported a significant improvement in the mean JOA score from 10.07 ± 2.39 preoperatively to 12.85 ± 2.45 at final follow-up after expansive open-door laminoplasty with uni- or bilateral lateral mass screw fixation in 110 patients with cervical spondylotic myelopathy.

The present study has some limitations. First, the study cohort comprised a small number of patients with specific conditions. Second, the study was a retrospective case study. The findings require confirmation in a prospective study that compares different surgical procedures. There is also a need to evaluate the biomechanical outcomes and accurately determine the indications for the surgical technique used in the present study.

Declarations

Competing interests

The authors declare that they have no competing interests.

Availability of data and materials

The datasets used and/or analyzed during the current study are available from the corresponding author on reasonable request.

Authors' contributions

GYL: Surgical treatments. LHH: Data analysis and manuscript preparation. YJG: Study design and data collection. WHM: Study design and manuscript revision.

Ethics approval and consent to participate

Ethics approval was obtained from the Research Ethics Committee of Ningbo 6th Hospital (CODE: L2022068). Informed consent was obtained from all the participants. All methods were performed in accordance with the relevant guidelines and regulations.

Consent for publication

A written informed consent to publish this paper was obtained from the patient.

Funding

This work was supported by the Zhejiang Medical and Health Science and Technology Project [grant numbers 2022KY340].The fund gave us financial supports.

Acknowledgments:

We thank Kelly Zammit, BVSc, from Liwen Bianji (Edanz) (www.liwenbianji.cn/), for editing the English text of a draft of this manuscript.

References

1. Wadhwa H, Sharma J, Varshneya K, Fatemi P, Nathan J, Medress ZA, Stienen MN, Ratliff JK, Veeravagu A. Anterior Cervical Discectomy and Fusion Versus Laminoplasty for Multilevel Cervical Spondylotic Myelopathy: A National Administrative Database Analysis.World Neurosurg. 2021;152:e738-e744. doi: 10.1016/j.wneu.2021.06.064.

2. Lee JJ, Lee N, Oh SH, Shin DA, Yi S, Kim KN, Yoon DH, Shin HC, Ha Y. Clinical and radiological outcomes of multilevel cervical laminoplasty versus three-level anterior cervical discectomy and fusion in patients with cervical spondylotic myelopathy. Quant Imaging Med Surg. 2020;10(11):2112–2124.
3. Chen LF, Tu TH, Chen YC, Wu JC, Chang PY, Liu L, Huang WC, Lo SS, Cheng H. Risk of spinal cord injury in patients with cervical spondylotic myelopathy and ossification of posterior longitudinal ligament: a national cohort study. Neurosurg Focus. 2016;40(6):E4. doi: 10.3171/2016.3.FOCUS1663.
4. Tetreault LA, Skelly AC, Dettori JR, Wilson JR, Martin AR, Fehlings MG. Guidelines for the Management of Degenerative Cervical Myelopathy and Acute Spinal Cord Injury: Development Process and Methodology.Global Spine J. 2017;7(3 Suppl):8S-20S. doi: 10.1177/2192568217701715.
5. Perdomo-Pantoja A, Chara A, Liu A, Jin Y, Taylor M, El Demerdash N, Ahmed AK, Pennington Z, Cottrill E, Westbroek EM, Bydon A, Theodore N, Witham TF. Surgical Decompression for Cervical Spondylotic Myelopathy in Patients with Associated Hypertension: A Single-Center Retrospective Cohort and Systematic Review of the Literature.World Neurosurg. 2021;155:e119-e130.
6. Son S, Lee SG, Park CW, Kim WK. Combined open door laminoplasty with unilateral screw fixation for unstable multi-level cervical stenosis: a preliminary report. J Korean Neurosurg Soc. 2013,53(2):83–8. doi: 10.3340/jkns.2013.53.2.83.
7. Hirabayashi K, Watanabe K, Wakano K, Suzuki N, Satomi K, Ishii Y. Expansive
8. open-door laminoplasty for cervical spinal stenotic myelopathy. Spine (Phila
9. Pa 1976) 1983;8:693e9.
10. Abumi K, Itoh H, Taneichi H, et al. Transpedicular screw fixation for traumatic
11. lesions of the middle and lower cervical spine: description of the techniques
12. and preliminary report. J Spinal Disord 1994;7:19–28.
13. An HS, Gordin R, Renner K, et al. Anatomic considerations for plate-screw
14. fixation of the cervical spine. Spine 1991;16:S548–51.
15. Magerl F, Seemann PS: Stable posterior fusion of the atlas and axis by transarticular screw fixation, in Kehr P, Weidner A (eds): Cervical Spine I. New York: Springer, 1986, pp 322–327.
16. Hirabayashi K, Miyakawa J, Satomi K, Maruyama T, Wakano K. Operative results
17. and postoperative progression of ossification among patients with ossification of cervical posterior longitudinal ligament. Spine (Phila Pa 1976)1981;6:354e64.
18. van Geest S, de Vormer AM, Arts MP, Peul WC, Vleggeert-Lankamp CL. Long-term follow-up of clinical and radiological outcome after cervical laminectomy.
19. Eur Spine J. 2015, 24 Suppl 2:229 – 35. doi: 10.1007/s00586-013-3089-6.
20. Lee SE, Chung CK, Jahng TA, Kim HJ. Long-term outcome of laminectomy for cervical ossification of the posterior longitudinal ligament. J Neurosurg Spine. 2013, 18(5):465–71. doi: 10.3171/2013.1.
21. Akira Matsumura, Kiyoyuki Yanaka, Hiroyoshi Akutsu, Shouzou Noguchi, Takeshi Moritake, Tadao Nose. Combined laminoplasty with posterior lateral mass plate for unstable spondylotic cervical canal stenosis–technical note. Neurol Med Chir (Tokyo),2003 Oct;43(10):514–9.doi: 10.2176/nmc.43.514.
22. Jae-Ryong Cha, Han Wook Kim, Doo Guen Yang, Hee-Yoon Chung, Il-Yeong Hwang. Open-Door Laminoplasty Using Lateral Mass Anchoring Screws and Nonabsorbable Sutures in Patients with Multilevel Cervical Myelopathy. Clin Orthop Surg. 2020, 12(4):477–484.doi: 10.4055/cios20013.
23. Su N, Fei Q, Wang BQ, Kang N, Zhang QM, Tang HH, Li D, Li JJ, Yang Y. Comparison of clinical outcomes of expansive open-door laminoplasty with unilateral or bilateral fixation and fusion for treating cervical spondylotic myelopathy: a multi-center prospective study. BMC Surg. 2019, 22,19(1):116. doi: 10.1186/s12893-019-0583-8.
24. Zhang Z, Wang LN, Song YM, Wang L, Liu H, Liu LM, Xiu P, Zhou ZJ. Comparison of long-term clinical and radiographic outcomes between alternative-level and all-level fixation unilateral open-door laminoplasty.
25. Spine J. 2020 ,20(11):1761–1769. doi: 10.1016/j.spinee.2020.06.018.
26. Schmeiser G, Bergmann JI, Papavero L, Kothe R. Surgical treatment of multilevel degenerative cervical myelopathy: open-door laminoplasty and fixation via unilateral approach. A feasibility study. J Neurol Surg A Cent Eur Neurosurg. 2021,15. doi: 10.1055/s-0041-1739224. Online ahead of print.

27. Chen C, Yang C, Yang S, Gao Y, Zhang Y, Wu X, Hua W, Shao Z.
28. Clinical and radiographic outcomes of modified unilateral open-door laminoplasty with posterior muscle-ligament complex preservation for cervical spondylotic myelopathy. Spine (Phila Pa 1976). 2019, 15,44(24):1697–1704.
29. Hua Zhou, Zhong-Jun Liu, Shao-Bo Wang, Sheng-Fa Pan, Ming Yan, Feng-Shan Zhang, Yu Sun. Laminoplasty with lateral mass screw fixation for cervical spondylotic myelopathy in patients with athetoid cerebral palsy: A retrospective study. Medicine (Baltimore). 2016,95(39):e5033.doi: 10.1097/MD.0000000000005033.
30. Gregor Schmeiser, C Schilling, T M Grupp, L Papavero, K Püschel, R Kothe.
31. Unilateral laminoplasty with lateral mass screw fixation for less invasive decompression of the cervical spine: a biomechanical investigation. Eur Spine J, 2015;24(12):2781–7.doi: 10.1007/s00586-015-4230-5..
32. Tang HM, Yeh KT, Lee RP, Chen IH, Yu TC, Liu KL, Peng CH, Wang JH, Wu WT. Combined expansive open-door laminoplasty with short-segment lateral mass instrumented fusion for multilevel cervical spondylotic myelopathy with short segment instability. Ci Ji Yi Xue Za Zhi. 2016;28(1):15–19.

Figures

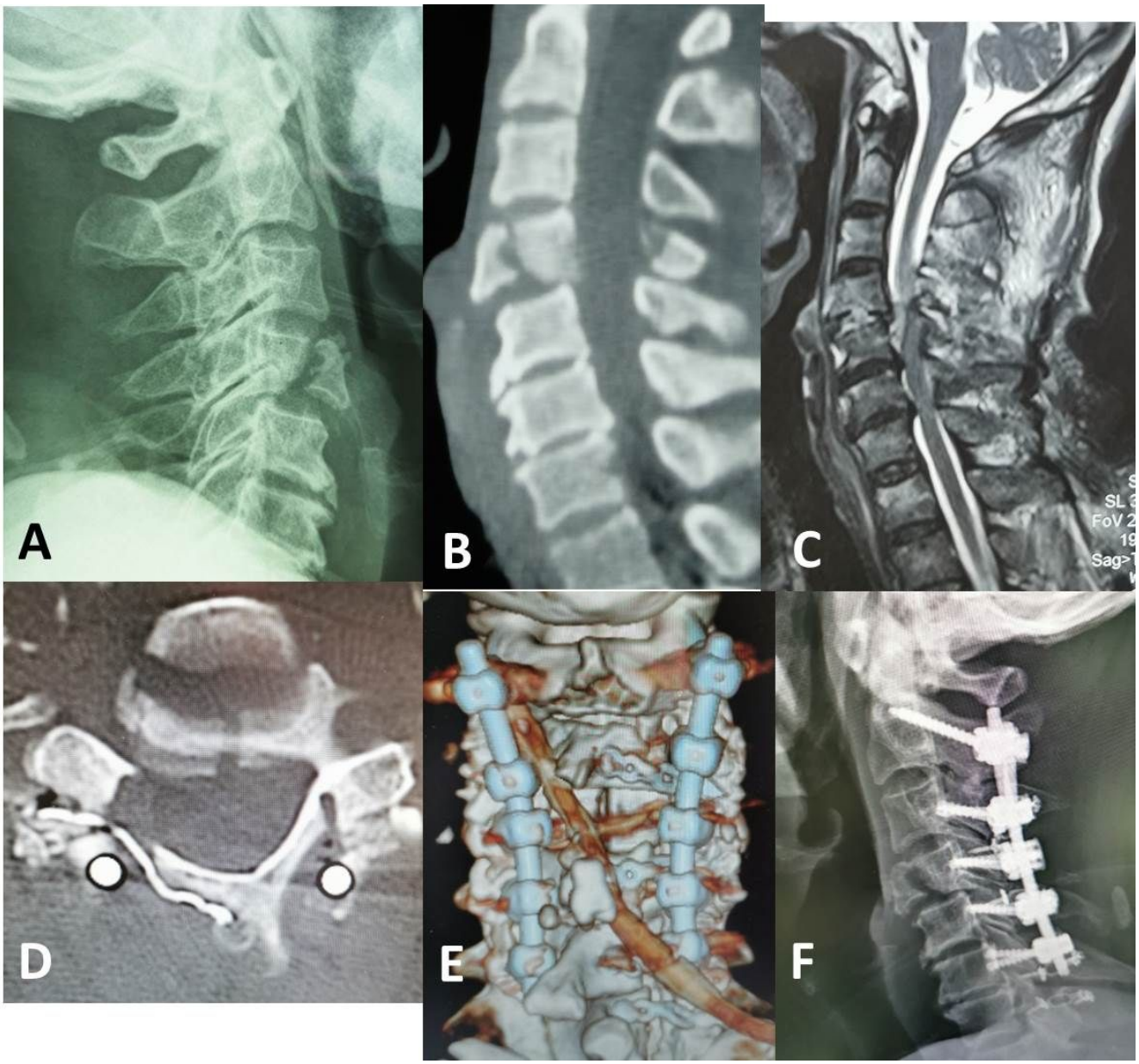

Figure 1

shows the pre- and postoperative images of a 70-year-old man with multilevel cervical canal stenosis, C4 fracture, and cervical cord injury treated with C3–C7 open-door laminoplasty combined with screw fixation and fusion of C2–C6 (patient 11 in Table 1). The patient's respective JOA and Nurick scores improved from 3 and 5 preoperatively to 14 and 1 at 2 years postoperatively; the JOA recovery rate was 78.5%. (A) Preoperative lateral radiograph showing a burst fracture of C4. (B) Preoperative sagittal CT image. (C) Preoperative sagittal T2-weighted magnetic resonance image showing C4–C6 cervical canal stenosis, C4 fracture, and cervical cord injury. (D) Postoperative axial CT image. (E) Postoperative three-dimensional reconstructed CT image showing correct positioning of the C2 pedicle screws and C3–C6 lateral mass screws. (F) Lateral radiograph showing intact hardware and stable fixation at 24 months postoperatively.