Satisfaction survey on a preoperative explanation method using 3-dimensional breast imaging for breast cancer patients considering breast conserving surgery

Yuri Ozaki (yozaki@aichi-cc.jp)
Aichi Cancer Center: Aichi-ken Gan Center https://orcid.org/0000-0001-8382-7473

Haruru Kotani
Aichi Cancer Center: Aichi-ken Gan Center

Yayoi Adachi
Aichi Cancer Center: Aichi-ken Gan Center

Masataka Sawaki
Aichi Cancer Center: Aichi-ken Gan Center

Masaya Hattori
Aichi Cancer Center: Aichi-ken Gan Center

Akiyo Yoshimura
Aichi Cancer Center: Aichi-ken Gan Center

Ayumi Kataoka
Aichi Cancer Center: Aichi-ken Gan Center

Kazuki Nozawa
Aichi Cancer Center: Aichi-ken Gan Center

Kayoko Sugino
Aichi Cancer Center: Aichi-ken Gan Center

Nanae Horisawa
Aichi Cancer Center: Aichi-ken Gan Center

Yuka Endo
Aichi Cancer Center: Aichi-ken Gan Center

Daiki Takatsuka
Aichi Cancer Center: Aichi-ken Gan Center

Ayaka Isogai
Aichi Cancer Center: Aichi-ken Gan Center

Hiroji Iwata
Aichi Cancer Center: Aichi-ken Gan Center

Research Article

Keywords: Breast cancer, breast conserving surgery, patient satisfaction, 3D imaging, shared decision making.

Posted Date: June 10th, 2022

DOI: https://doi.org/10.21203/rs.3.rs-1660260/v1

Abstract

Purpose

Women diagnosed with early breast cancer are faced with a choice of surgical procedures. Although one of the essential factors in surgical shared decision making is the impact on the body image, the breast morphology after breast conserving surgery is particularly difficult to explain in a uniform manner due to large individual differences.

Methods

Patients with breast cancer eligible for breast conserving surgery (BCS) were recruited between June 2020 and October 2021. We surveyed the patients' satisfaction with our explanation method about breast morphology after BCS using 3D breast imaging in the form of a questionnaire.

Results

A total of 162 patients were enrolled and 137 (84.6%) answered the questionnaire. One hundred and sixteen patients (84.6%) answered that they were very satisfied or satisfied with our explanation method and 100 (73.0%) patients were very satisfied or satisfied with the 3D breast imaging. Some patients answered that visually understanding the breast morphology by 3D breast imaging helped them to prepare for BCS, or on the contrary, made them chose mastectomy with breast reconstruction because the postoperative deformation of BCS was found to be unacceptable. Only a few patients who actually underwent BCS felt that their postoperative morphology was more deformed than the preoperatively imagined one.

Conclusion

Our results suggest that our preoperative explanation method using 3D breast imaging was useful for shared decision making. We think that 3D breast imaging can help the patients to visualize the individual shape of their breast, and the tumor position and size.

Introduction

Breast cancer is the most common carcinoma among women, with more than 93,000 Japanese women diagnosed annually [1]. Women who are diagnosed with early breast cancer are faced with a choice of surgical procedures, such as breast conserving surgery (BCS) or total mastectomy with or without breast reconstruction. In Japan, about 60% of operable breast cancer patients undergo BCS [2]. In terms of overall survival, BCS combined with postoperative whole breast irradiation has been shown to be comparable to total mastectomy [3, 4]. For this reason, the patient's wishes are taken into consideration when deciding the surgical procedure.

However, a previous study revealed that approximately half of the Japanese women with early breast cancer reported some regret regarding the treatment decision–making process [5]. Another study on decision aids for surgical procedures identified the need for better communication between the patient and physician [6]. During shared decision-making for early breast cancer treatment, it is essential to include not only information on survival, but also information on the postoperative alteration in body image. On the other hand, the breast morphology after BCS is particularly difficult to explain in a uniform manner due to large individual differences, since each patient has a different original breast size, and tumor size and location.

Various efforts have been made to explain the postoperative breast morphology after BCS. Vos et al. reported that a higher tumor volume/breast volume ratio measured by magnetic resonance imaging (MRI) is related to a poor cosmetic result; therefore, this ratio could enable more informed surgical treatment decision making [7]. Another study evaluated the acceptability of 3-dimensional (3D)-printed breast models derived from MRI and their impact on the decisional conflict. The authors concluded that 3D-printed breast models were acceptable tools [8]. However, it remains unclear how explaining postoperative breast morphology to patients can achieve satisfactory results.

At our institution, we use 3D breast imaging to explain the breast morphology after BCS in cases where BCS is judged to be feasible. The purpose of this study was to improve shared decision-making by surveying the satisfaction of patients with our explanation method, and how patients who actually underwent BCS think the postoperative morphology compared to the preoperatively imagined morphology.

Methods

Study design

Patients with breast cancer aged 20 years or older who were judged to be eligible for BCS at our institution were recruited between June 2020 and October 2021. Patients with metachronous bilateral breast cancer, previous ipsilateral breast surgery, men, or other patients deemed ineligible for study participation were excluded. Written informed consent was obtained from all individual participants. This study was approved by an institutional review board.

When deciding on the surgical procedure in the outpatient consultation, the physician provided a verbal explanation about the breast morphology after BCS, and by using hand-drawn drawings, postoperative photographs of other patients, and 3D breast imaging. The patient made the final decision regarding their surgical procedure. In this study, we surveyed the patients' satisfaction with the preoperative explanation in the form of a questionnaire. Patients were given explanations regarding the consent explanatory document and written consent was obtained during hospitalization for surgery. The questionnaires were to be filled out at home after discharge from the hospital, and sent by mail in principle. Most questionnaires were returned within one month after surgery.

3d Breast Imaging

Prediction of breast morphology after BCS was presented using 3D breast imaging (SYSPLAN Inc., Japan). The patient's body size and breast morphology (size and droopiness) can be set to any level from small to large. The predicted postoperative morphology is displayed by selecting any location in the breast and setting the expected deformation strength based on the tumor size. The imaging can be rotated in any direction. Figure 1 shows the predicted morphologies. Tugging at the excision site, elevation of the affected breast, and deviation of the nipple position are also expressed.

Patient Satisfaction

A questionnaire was used to survey the patients' satisfaction. The questionnaire consisted of items for all patients, an item for patients who underwent BCS, and an item for patients who underwent a surgery other than BCS. All patients were surveyed to determine their satisfaction with the preoperative explanation of breast morphology after BCS, the method(s) that were useful in visualizing the breast morphology after BCS, and satisfaction with the explanation using 3D breast imaging. For patients who underwent BCS, we investigated the degree of discrepancy between the expected morphology by 3D breast imaging and the actual postoperative morphology. Patients who underwent a surgical procedure other than BCS were surveyed about the surgical procedure they chose and the reasons why they chose the procedure.

Endpoints

The primary endpoint was satisfaction with our preoperative explanation of breast morphology after BCS. The secondary endpoints were the percentage of patients who found each of the methods to visualize breast morphology after BCS useful, satisfaction with the explanation using 3D breast imaging, patient-rated agreement between the imagined morphology and actual postoperative morphology of patients who underwent BCS, and the reasons why patients who underwent procedures other than BCS did not undergo BCS.

Results

A total of 162 patients were found to be eligible and underwent an operation. Two patients had bilateral breast cancer. Clinical data of the study population are shown in Table 1. The median age was 51 (30–84) years. The mean body mass index (BMI, kg/m^2) was 21.9. The tumor was located in the upper-outer area in about 60% of the cases, and the tumor diameter including that of carcinoma in situ was 20 mm or less in about 90% of the cases. The actual surgical procedure chosen by the patients was BCS in 101 cases, mastectomy without breast reconstruction in 36 cases, and mastectomy with breast reconstruction in 27 cases. The questionnaire was answered by 137 out of 162 cases (84.6%) (Fig. 2). Figure 3 shows the survey results of the patients' satisfaction with the preoperative explanation of breast

morphology after BCS evaluated on a 5-point scale. A total of 116 patients (84.6%) answered that they were very satisfied or satisfied. The most useful method to visualize breast morphology after BCS was 3D breast imaging (69.3%), followed by oral explanations and handwritten drawings by a doctor (65.7%), and postoperative photos of other patients (40.1%) (Fig. 4). There was an opinion that the combination of these explanation methods deepened the understanding.

The survey result of satisfaction with 3D breast imaging revealed that 100 patients (73.0%) patients were very satisfied or satisfied with the 3D breast imaging (Fig. 5). The reasons for supporting 3D breast imaging were that it was visual and easier to understand than a verbal explanation, it was three-dimensional and could be seen from various directions, and the position of the nipple was expressed as having a slight difference between the affected and unaffected sides. Some patients answered that visual understanding of the morphology by 3D breast imaging made them prepared to undergo BCS, or on the contrary, made them chose mastectomy with breast reconstruction because the postoperative deformation of BCS was found to be unacceptable. On the other hand, there was an opinion that it was difficult to visualize the postoperative morphology of the breasts because the image was not very realistic. Some patients also answered that the shock caused by the diagnosis of breast cancer was so great that they did not remember the details of the explanation.

Seventy-five of the 88 patients (85.2%) felt that their breast morphology after surgery was as good as or better than expected before surgery (Fig. 6). The most common reason for choosing a procedure other than BCS (49 patients) was to reduce the risk of ipsilateral breast cancer recurrence (32 patients). Eight patients chose mastectomy with breast reconstruction because they found the deformity after BCS unacceptable. Six patients answered that they did not want to undergo irradiation.

Discussion

Previous studies have pointed out that better communication between the patient and physician is needed for breast cancer surgical decisions [6], as approximately half of Japanese women with early breast cancer reported some regret regarding the treatment decision–making process [5]. In this regard, improving the patients' satisfaction with the preoperative explanation has been an issue. In order to solve this problem, we explained the postoperative morphology after BCS using 3D breast imaging in addition to the conventional methods such as oral explanations and handwritten drawings by a doctor and postoperative photos of other patients. Our study surveyed patient satisfaction with this explanation method and found that many patients were satisfied with this explanation method, and that the patients found 3D breast imaging to be particularly useful among the various preoperative explanation methods.

Three-dimensional imaging has begun to be applied clinically in the field of plastic surgery such as breast augmentation or breast reconstruction. Efforts are being made to improve the decision-making process and improve patient satisfaction by showing preoperative simulations using 3D imaging [9–11]. Two studies of breast augmentation showed that 3D imaging was useful in envisaging breast augmentation [10] and choosing an implant [11]. Another study on breast reconstructive surgery reported that 3D

imaging is an effective method for enhancing patient preparedness prior to surgery [9]. In the field of BCS, there have been reports on the use of 3D imaging as a method for assessing postoperative morphology [12, 13], but only a few studies have examined its use in preoperative morphological prediction [14, 15].

Our results are consistent with the findings of previous studies on plastic surgery, where 3D imaging was reported to be useful as a preoperative explanation. More patients answered that 3D imaging was useful than those who answered conventional methods such as oral explanations and handwritten drawings by a doctor or postoperative photos of other patients were useful. The advantage of 3D imaging is that the patients can visually recognize the individual shape of their breast, and the tumor position and size. The patients' opinion that a more accurate understanding of the postoperative breast morphology helped them to prepare for BCS and, conversely, that they decided to undergo breast reconstruction after finding the deformity unacceptable suggests that 3D breast imaging may be useful as a decision making tool.

When patients who actually underwent BCS were asked about the degree of postoperative deformation, 85.2% answered it was comparable or better than what they had imagined. Although it is necessary to take into consideration that this survey was conducted at approximately one month postoperatively, the fact that only a few patients felt that their morphology after BCS was more deformed than what they had preoperatively imagined suggests that they had been adequately prepared for the postoperative breast morphology.

The 3D breast imaging used in this study produces a predictive postoperative morphology by inputting the preoperative breast morphology, tumor location, and its size. Because scanned photographs of the patient were not used, the skin tones and textures may not be reproduced satisfactorily, as noted in some of the survey responses. However, since this 3D breast imaging setup is not time consuming, it can be performed on many patients in a limited time during outpatient care. From this point of view, this tool is easily applicable in actual daily clinical practice.

A limitation of this study is that it was not a randomized control trial. Although the impact of 3D breast imaging may not have been directly assessed, we chose this study design because 3D breast imaging is noninvasive, yet it is likely to be beneficial based on the results of previous studies in the field of plastic surgery. We believe that the results of this study sufficiently demonstrate that 3D breast imaging is beneficial to breast cancer patients.

In conclusion, our study suggests that our preoperative explanation method using 3D breast imaging is useful for shared decision making. We think that 3D breast imaging can help patients to visualize the individual shape of their breast as well as the tumor position and size. Further studies are needed to confirm the long-time patient satisfaction to widely translate this explanation method into daily clinical practice.

Declarations

Conflicts of interest:

There are no conflicts of interest

References

1. Cancer statistics. Cancer Information Service, National Cancer Center, Japan (National Cancer Registry, Ministry of Health, Labour and Welfare)
2. Kurebayashi J, Miyoshi Y, Ishikawa T, Saji S, Sugie T, Suzuki T et al (2015) Clinicopathological characteristics of breast cancer and trends in the management of breast cancer patients in Japan: based on the Breast Cancer Registry of the Japanese Breast Cancer Society between 2004 and 2011. Breast Cancer 22:235–244. https://doi.org/10.1007/s12282-015-0599-6
3. Veronesi U, Cascinelli N, Mariani L, Greco M, Saccozzi R, Luini A et al (2002) Twenty-year follow-up of a randomized study comparing breast-conserving surgery with radical mastectomy for early breast cancer. N Engl J Med 347:1227–1232. https://doi.org/10.1056/NEJMoa020989
4. Fisher B, Anderson S, Bryant J, Margolese RG, Deutsch M, Fisher ER et al (2002) Twenty-year follow-up of a randomized trial comparing total mastectomy, lumpectomy, and lumpectomy plus irradiation for the treatment of invasive breast cancer. N Engl J Med 347:1233–1241. https://doi.org/10.1056/NEJMoa022152
5. Yamauchi K, Nakao M, Nakashima M (2019) Correlates of regret with treatment decision-making among Japanese women with breast cancer: results of an internet-based cross-sectional survey. BMC Womens Health 19:86. https://doi.org/10.1186/s12905-019-0783-5
6. Janz NK, Wren PA, Copeland LA, Lowery JC, Goldfarb SL, Wilkins EG (2004) Patient–physician concordance: preferences, perceptions, and factors influencing the breast cancer surgical decision. J Clin Oncol 22:3091–3098. https://doi.org/10.1200/JCO.2004.09.069
7. Vos EL, Koning AH, Obdeijn IM, van Verschuer VM, Verhoef C, van der Spek PJ et al (2015) Preoperative prediction of cosmetic results in breast conserving surgery. J Surg Oncol 111:178–184. https://doi.org/10.1002/jso.23782
8. Santiago L, Volk RJ, Checka CM, Black D, Lee J, Colen JS et al (2021) Acceptability of 3D-printed breast models and their impact on the decisional conflict of breast cancer patients: A feasibility study. J Surg Oncol 123:1206–1214. https://doi.org/10.1002/jso.26420
9. McCrorie AD, Begley AM, Chen JJ, McCorry NK, Paget G, McIntosh SA (2021) Improving preparedness prior to reconstructive breast surgery via inclusion of 3D images during pre-operative counselling: a qualitative analysis. BMC Womens Health 21:323. https://doi.org/10.1186/s12905-021-01463-6
10. de Runz A, Boccara D, Bertheuil N, Claudot F, Brix M, Simon E (2018) Three-dimensional imaging, an important factor of decision in breast augmentation. Ann Chir Plast Esthet 63:134–139. https://doi.org/10.1016/j.anplas.2017.07.019
11. Donfrancesco A, Montemurro P, Hedén P (2013) Three-dimensional simulated images in breast augmentation surgery: an investigation of patients’ satisfaction and the correlation between

prediction and actual outcome. Plast Reconstr Surg 132:810–822. https://doi.org/10.1097/PRS.0b013e3182a014cb

12. O'Connell RL, Di Micco R, Khabra K, Wolf L, deSouza N, Roche N et al (2017) The potential role of three-dimensional surface imaging as a tool to evaluate aesthetic outcome after Breast Conserving Therapy (BCT). Breast Cancer Res Treat 164:385–393. https://doi.org/10.1007/s10549-017-4256-y
13. Godden AR, O'Connell RL, Barry PA, Krupa KCD, Wolf LM, Mohammed K et al (2020) 3-Dimensional objective aesthetic evaluation to replace panel assessment after breast-conserving treatment. Breast Cancer 27:1126–1136. https://doi.org/10.1007/s12282-020-01117-9
14. Vavourakis V, Eiben B, Hipwell JH, Williams NR, Keshtgar M, Hawkes DJ (2016) Multiscale Mechano-biological finite element modelling of oncoplastic breast surgery-numerical study towards surgical planning and cosmetic outcome prediction. PLoS ONE 11:e0159766. https://doi.org/10.1371/journal.pone.0159766
15. Godden AR, Micha A, Wolf LM, Pitches C, Barry PA, Khan AA et al (2021) Three-dimensional simulation of aesthetic outcome from breast-conserving surgery compared with viewing photographs or standard care: randomized clinical trial. Br J Surg 108:1181–1188. https://doi.org/10.1093/bjs/znab217

Tables

Table 1 is available in the Supplementary Files section.

Figures

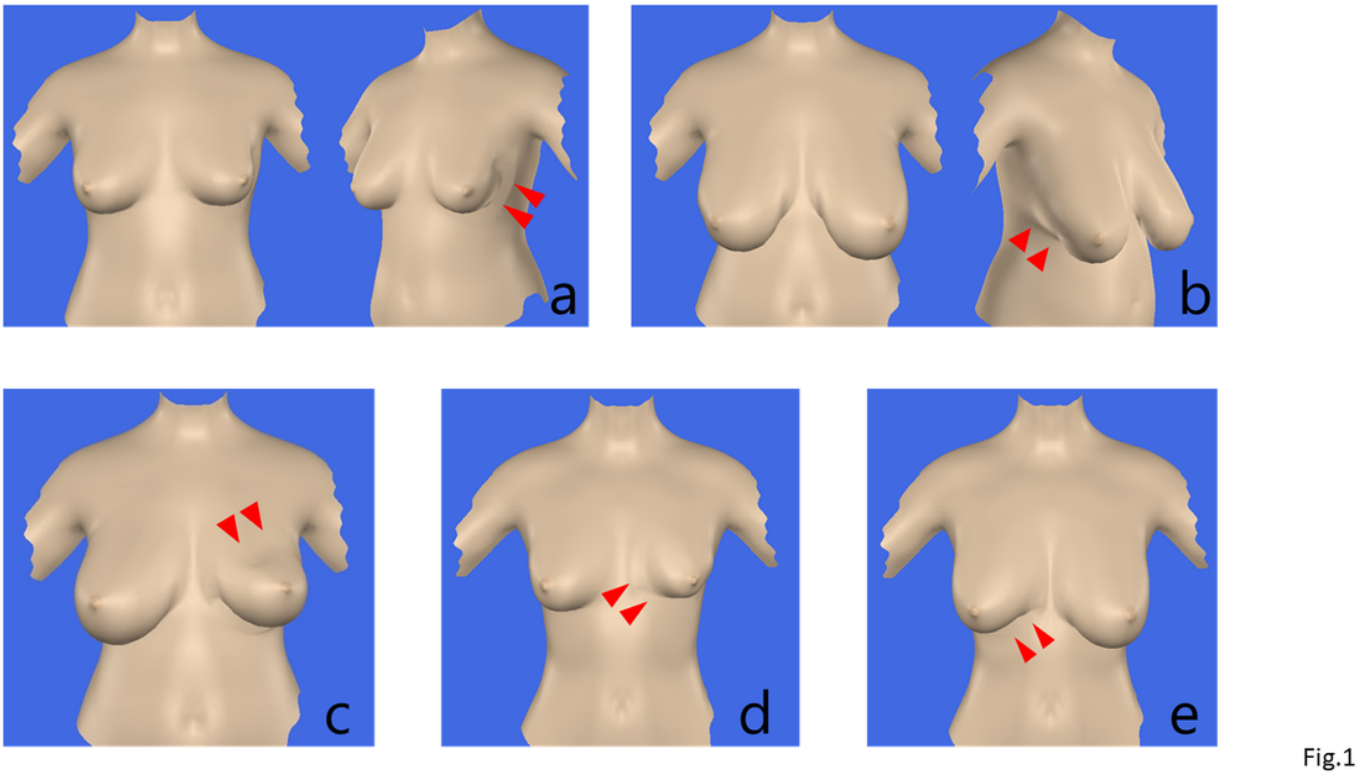

Figure 1

Predicted morphologies using 3D breast imaging of various body shapes and the surgical excision amount. Tugging at the excision site, elevation of the affected breast, and deviation of the nipple position are expressed

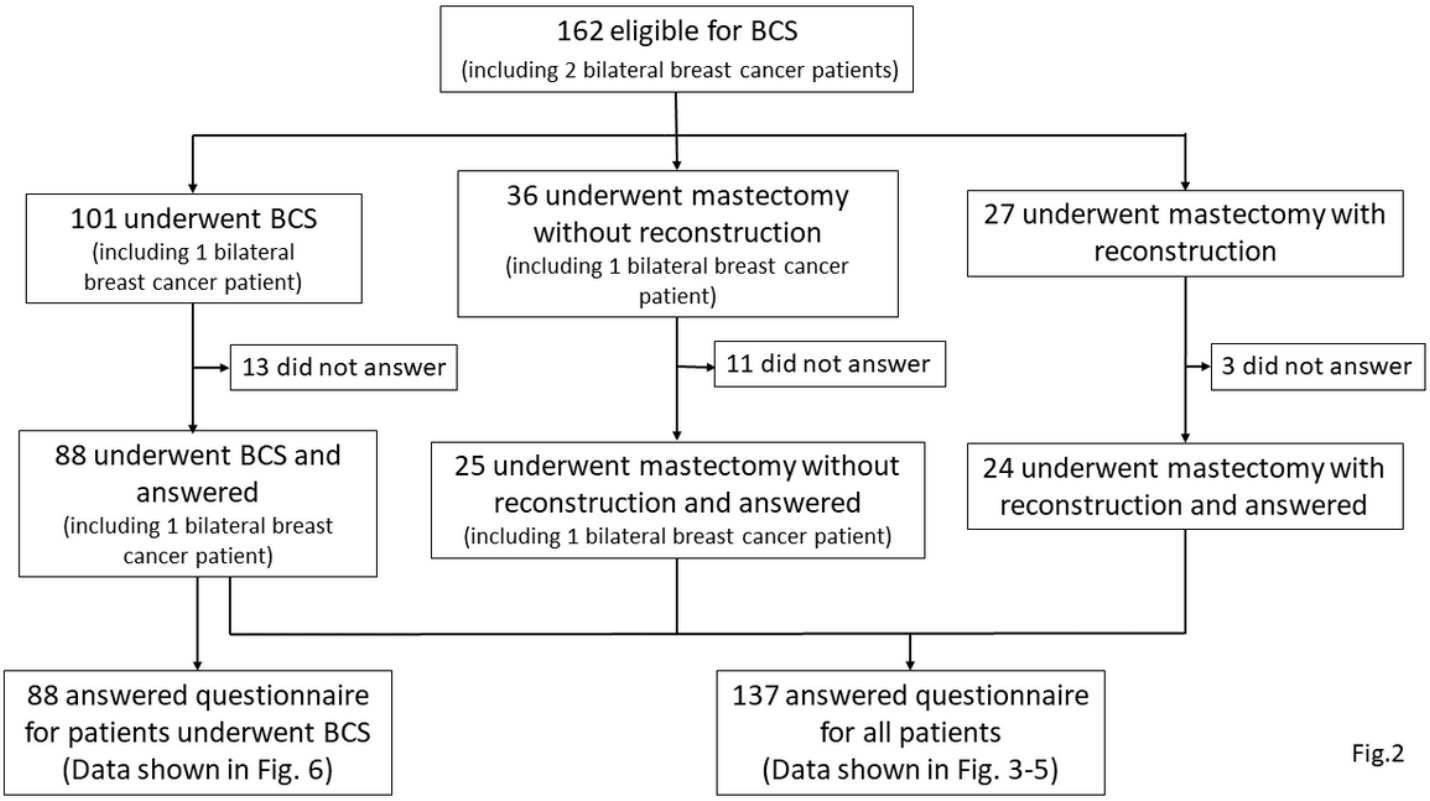

Figure 2

Consort diagram

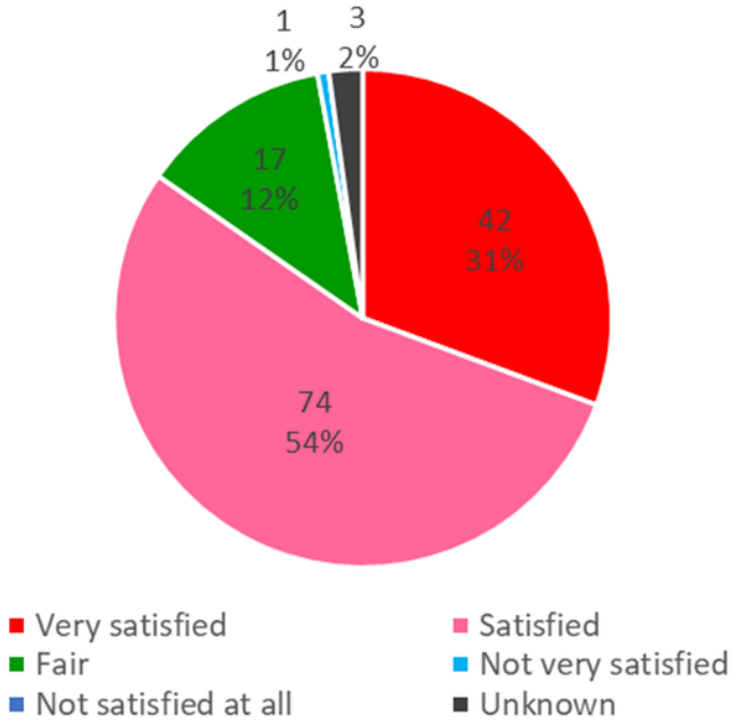

Figure 3

Survey result of patient satisfaction with the preoperative explanation of breast morphology after breast conserving surgery (BCS) on a 5-point scale (For all patients, n=137)

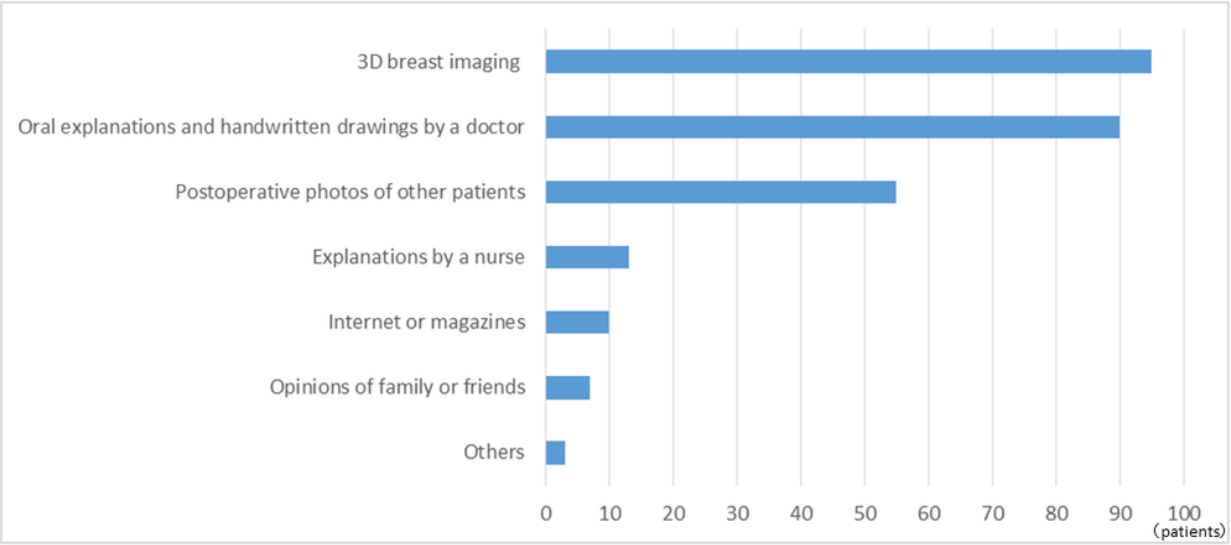

Fig.4

Figure 4

Result of the most useful method(s) to visualize breast morphology after breast conserving surgery (BCS) (For all patients, n=137)

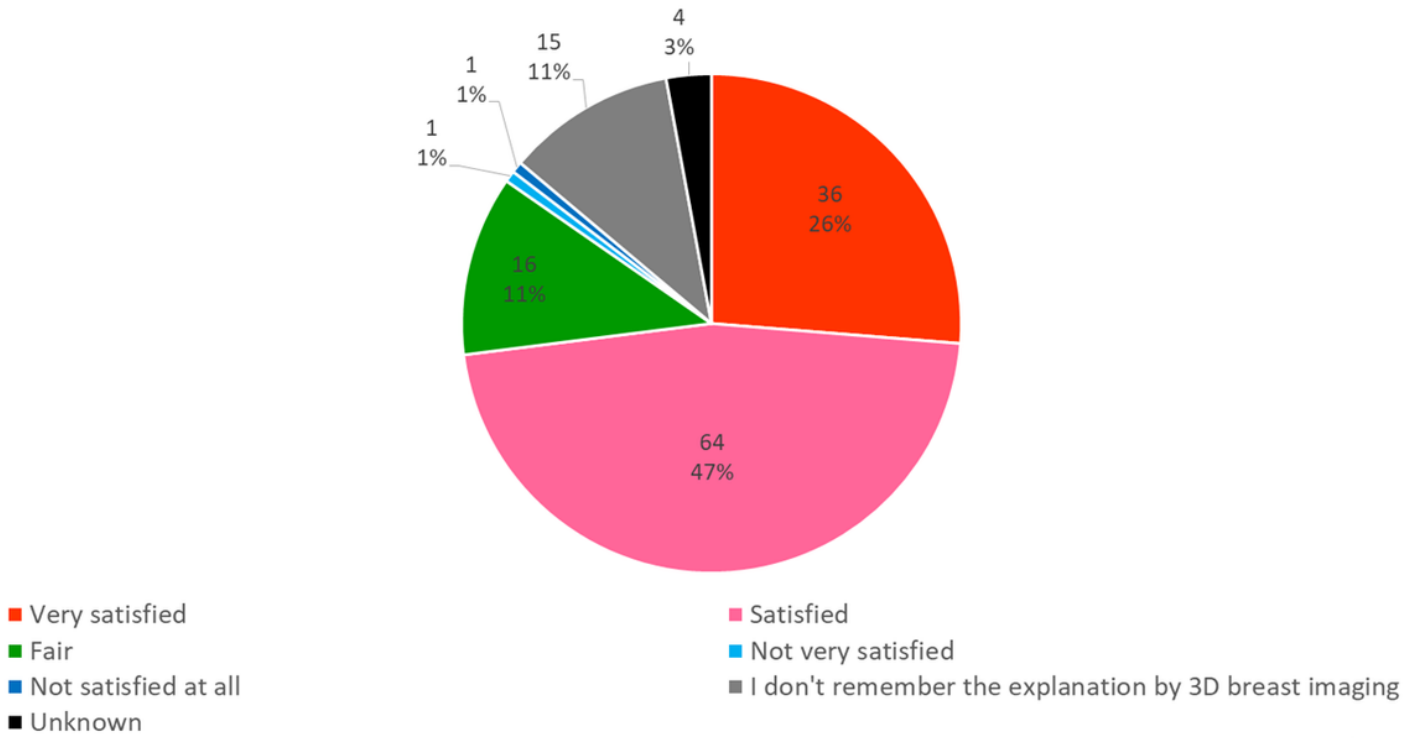

Fig.5

Figure 5

Result of patient satisfaction with the explanation using 3D breast imaging (For all patients, n=137)

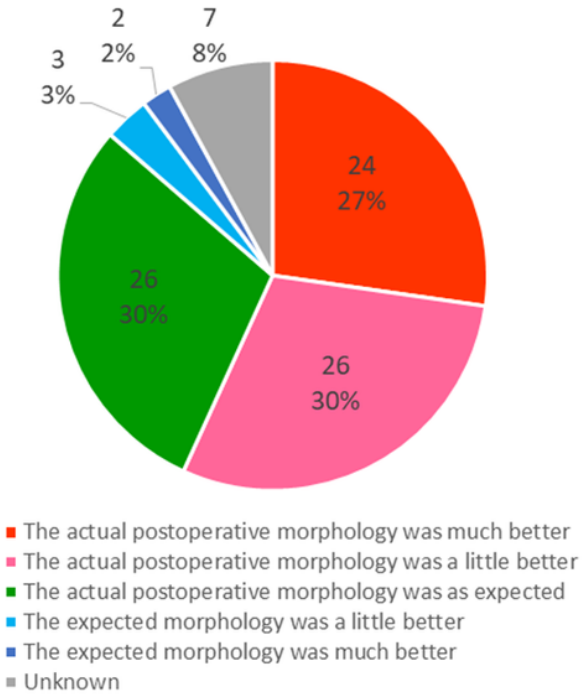

Fig.6

Figure 6

Result of the degree of discrepancy between the expected morphology by 3D breast imaging and the actual postoperative morphology (For patients who underwent breast conserving surgery [BCS], n=88)

Supplementary Files

This is a list of supplementary files associated with this preprint. Click to download.

- Table20220416.xlsx