Modified submandibular mandibulotomy approach versus lip-splitting approach in tongue cancer surgery: a retrospective paired-cohort study

Youyuan Wang (wangyy78@mail.sysu.edu.cn)
Sun Yat-sen University

Bin Zhou
Sun Yat-sen University

Liujuan Sha
Sun Yat-sen University

Tao Rui
Sun Yat-sen University

Min Fu
Sun Yat-sen University

Chaobin Pan
Sun Yat-sen University

Weiliang Chen
Sun Yat-sen University

Research Article

Keywords: Tongue cancer, Mandibulotomy, Lip split, Esthetic outcome, Quality of life, Prognosis

Posted Date: May 24th, 2022

DOI: https://doi.org/10.21203/rs.3.rs-1661679/v1

Abstract

BACKGROUND: Lip-splitting approach for oncologic resection and defect reconstruction of tongue squamous cell carcinoma (TSCC) needs modification to avoid unfavorable aesthetic results.

METHODS: Forty-three patients with TSCC underwent surgery using the modified submandibular mandibulotomy(MSMM) approach without lip-splitting and another matched 43 patients using lip-splitting mandibulotomy (LSM) approach were reviewed retrospectively. Clinical outcomes evaluation consisted of tumor exposure, resection margin, surgical morbidity, locoregional recurrence, survival status, scar scores and quality of life (QOL).

RESULTS: All the tumors were en bolc removed by MSMM approach and LSM approach through combined intraoral routes with excellent tumor exposure and R0 resection margins. Tumor recurrence rates and swallowing, chewing, speech were similar in both groups. The MSMM approach was associated with significantly better facial appearance and recreation than LSM approach.

CONCLUSION: The MSMM approach without lip-splitting is safe and effective, achieves better aesthetic results and QOL compared to LSM approach in patients with TSCC.

Introduction

Oral cavity and pharynx cancers account for around 4% of cancer of all sites in recent years and the tongue cancer is the most common type of oral cancer [1, 2]. Surgery remains the mainstream treatment for the tongue cancer, along with radiotherapy or chemoradiotherapy. Good access to the tumor for adequate three-dimensional resection is the key surgical procedure for good survival of the patient with tongue cancer. The lip-splitting mandibulotomy (LSM) approach allows the proximal mandible to be swung outwards to gain full access to all areas of the oral cavity and oropharynx [3]. But LSM approach inevitably leads to facial scar and other complications. In 1990s, the mandibular lingual releasing(MLR) and visor flap (VF) techniques had been becoming alternative approaches in resection of oral cavity and oropharynx cancers, which avoided facial scar and other morbidities associated with lip-splitting mandibulotomy[4, 5]. It was difficult to balance the need for adequate margins with the goal of minimizing facial scar and preserving oral functions. The surgical approaches used also depended on the surgeon’s comfort and experiences with the surgical procedure. Never the less, surgeons appreciated not lip-splitting approach in resection of oral cancer because it achieved both good tumor control and aesthetic outcomes [4, 6, 7].

Traditionally, survival rate had been the only outcome used to measure the success or failure of cancer treatment [5]. In this point, the LSM approach provided a safe and efficient mean of curative surgery [3, 8]. However, it is increasingly recognized that the prolong survival gains may be offset by a substantial loss in quality of life (QOL). Facial disfigurement following surgery is considered to be the most distressing aspect of QOL in oral cancer patients. Thus, the assessment of QOL of these patients after surgery, especially the aesthetic results, has a profound effect on measuring treatment success and failure[9, 10].

So far, there are no guidelines regarding the surgical approach for oral cavity and pharynx cancers. Any method that gains adequate access to the tumor and provides optimal margin clearance is acceptable [11]. In order to balance the need for margin clearance with the goal of better aesthetic outcomes, we modified mandibulotomy with submental incision instead of lip-splitting incision in resection of tongue cancers and reconstructed following defects with free flaps. Furthermore, we evaluated clinical outcomes including survival status, QOL, aesthetic and functional outcomes of the patients with tongue cancer in two cohorts: modified submandibular mandibulotomy (MSMM) approach without lip-splitting and traditional lip-splitting mandibulotomy (LSM) approach.

Patients And Methods

Six hundred and fifty-six consecutive patients of primary TSCC surgically treated from January 2016 to December 2019 were identified in oral and maxillofacial surgery database of Sun Yat-sen Memorial Hospital,Sun Yet-sen University. Patients were included as follows: primary tumor resection via a MSMM approach or LSM approach, neck dissection and free flap reconstruction. Patients were excluded as follows: mandibulectomy, uncontrolled diabetes mellitus, connective tissue diseases. Included patients were separated into two groups: MSMM approach or LSM approach. MSMM approach group included 43 patients was the control. They were then paired into cohorts based on age, gender and TNM stage. The only difference in aesthetic results between the cohorts was the lip-splitting incision or submandibular incision between MSMM or LSM approach group. Appearance and life quality of the patients were assessed at 1 month, 6 months, 12 months and 24 months after surgery. This study was approved by the Ethics Committee Board of Sun Yat-sen Memorial Hospital. Informed consent was obtained from all of the TSCC patients.

Surgical procedure

For the MSMM approach of hemiglossectomy, an incision is made from mastoid to submental (Fig. 1A and C). neck dissection, the attached points of mylohyoid muscle to hydroid bone and mandible are transected. The hyoglossal muscle to hydroid bone is transected and the lingual artery is ligated.The oral floor mucosa outside the sublingual gland is incised and the midline of the anterior tongue is split. Following the mandibulotomy is carried out, the posterior segment of the mandible is retracted in a lateral upward direction and digastric muscle in a lateral downward direction. The anterior-split tongue is pulled out to the submandibular space with excellent tumor exposure and the tumor is safely resected with adequate margins (Fig. 1A,E).The primary tumor, the sublingual gland, the submandibular gland, the neck dissection tissue, and the mylohyoid, hyoglossal and genioglossal muscles are en bolc removed. The surgical defect is reconstructed with a free flap. After inset of the flap, suture proceeded anteriorly from the area of the tongue base and oral floor when divided segment of the mandible is retracted upward. Then the tongue with a flap is pushed up to the oral cavity. The mandibulotomy site is repaired with the pre-bent titanium internal fixation plates. The anterior tongue and lingual frenum is sutured with the flap to completely repair oral incision (Fig. 1G). For the MSMM approach of subtotal glossectomy and glossectomy, the incision is made from mastoid to mastoid and bilateral digastric muscles are

transected. The tongue is pulled out and is en bloc resected through the similarly previous procedure. The reconstruction with free flap and incision closed are similar to previous procedure.

For the LSM approach, the lower lip and anterior mandibular labial sulcus are incised, in continuity with the neck dissection incision (Fig. 1B and D). Following neck dissection, The mandibulotomy is carried out and the divided segments of mandible are swung out to gain excellent tumor exposure (Fig. 1F). Then the primary tumor, the sublingual gland, the submandibular gland, the neck dissection tissue, and the mylohyoid, hyoglossal and genioglossal muscles are en bolc removed. The surgical defect is reconstructed with a free flap (Fig. 1G). After the vascular anastomosis is completed, the mandibulotomy site is repaired with the pre-bent titanium internal fixation plates. The lip and neck incision is repaired layer by layer. For the LSM approach of subtotal glossectomy and glossectomy, the incision is made from mastoid to mastoid in continuity with the lower lip and anterior mandibular labial sulcus.

Prognosis analysis

Clinical outcomes evaluation consisted of tumor exposure, resection margin and surgical morbidity. This study evaluated tumor recurrence and survival status, including the number of patients with localoregional recurrence, and disease-free survival (DFS), alive with a disease (AWD), and died of a disease (DOD), which is often used to evaluate the survival status as a clinical outcome of cancer treatment.

Appearance analysis

Patients in the study were provided with a standardized, well validated and objective scar evaluation tool, the Patient and Observer Scar Assessment Scale (POSAS), to assess aesthetic outcomes after surgery[9, 12, 13]. The POSAS, has an objective clinician-directed score (observer scar assessment scale, OSAS) and a subjective patient-directed score (patient scar assessment scale, PSAS), have to be completed by the patient and the observer, respectively. For the scales a lower score indicates a better result and a higher score means a worse appearance. The observer from our clinician team and the patient scored the overall scars of lip, chin, submental and neck and then rated the overall disfigurement of the MSMM and LSM scars on a 10-point Likert scale. For this scale a lower score indicates a better result. The patients in this study were followed-up and the scales were completed at 1,6,12 and 24 months after surgery. OSAS of all patients was assessed by an observer and data collection was performed by another observer in our team.

Lip Function analysis

The sensation and movement function of lower lip were tested as described in previous study[12] at 12 and 24 months after surgery. Sensation was assessed at four points of vermillion border: 3 mm medial to commissure of lower lip of patients in LSM group and the mid-point of lower lip of patients in MSMM group. The other two points were 5 mm medial to those positions. The points of upper lip were used as a control. Pressure sensation and temperature sensation were tested for these points. Scores were given as: (3) equivalent sensation, (2) decreased sensation, (1) no sensation. The Patients were also asked to say

and hold “ee” and “oh” to assess lip movement[12]. The movements were shown to naive observer to rate as this scale: (2) symmetrical or (1) asymmetrical.

Quality of life analysis

The University of Washington Quality of Life (UW-QOL) questionnaire is the most commonly used tool for patients’ clinical outcomes with head and neck cancer and we applied it to evaluate clinical outcomes of patients with head and neck cancer previously[14]. This study evaluated clinical outcomes including functional outcomes and appearance of patients based on UW-QOL questionnaire. The domains in the questionnaire are scored on a scale ranging from 0 (worst) to 100 (best).The patients in this study completed the UW-QOL version 4 questionnaire before surgery (baseline) and at the follow-up period (at 1,6,12 and 24 months after surgery). Data collection was performed by two examiners in the same maxillofacial team and was calibrated.

Statistical analysis

Data were recorded and analyzed using the SPSS version 16.0 statistical software (SPSS, Chicago, IL). Mean differences for continuous data were assessed using the *t*-test. Chi-square analysis or Fisher's exact test was used to compare the patient-reported symptoms, surgical complications and assessments between the MSMM and LSM groups. Statistical significance was set at $p < .05$.

Results

Of 656 patients identified, 78 patients with a MSMM approach and 415 with a LSM approach were included. Seventy-one MSMM and 372 LSM patients were considered because other patients met exclusion criteria. The 55 most recent patients in each group were contacted for enrollment. Forty-three in each arm agreed to participate and became paired cohorts, whose characteristics were listed in Table 1. There was no statistically significant difference in age, gender and tumor stage between MSMM and LSM group.

Both MSMM and LSM approach showed good tumor exposures and all tumors were resected in an en bloc fashion with negative resection margins. The neck dissection of patients was similar in both groups and they were received functional neck dissection, radical neck dissection or bilateral neck dissection based on clinical imaging evaluation of cervical lymph node(P 0.05). The defects were reconstructed with an anterolateral thigh free flap, a radial forearm free flap, or a posterior tibial artery free flap. There was no difference in application of free flaps between MSMM group and LSM group(P 0.05). The number of patients received postoperative tracheostomy was similar in MSMM group and LSM group (88.4% *VS.* 90.7%, P 0.05). The operation time was shorter in MSMM group than that in LSM group (295 ± 93 *VS.* 323 ± 78, minutes, P=0.037). The cases of patients stayed in ICU (intensive care unit) postoperatively were similar in both groups (16.3%% *VS.* 16.3%%, P 0.05). The number of patients received tube feeding was similar in MSMM group and LSM group (67.4% *VS.* 72.1%, P 0.05), but the patients in MSMM group return to oral feeds were earlier than LSM group (5.5± 2.1 *VS.* 7.1± 3.3, P=0.023). These data indicated that the function of lip was recovered faster in MSMM group. The

two groups have similar durations of postoperative hospital stay (8.2± 2.5 *VS.* 8.9± 2.9, *P* 0.05). The perioperative characteristics were demonstrated in Table 1.

The median follow-up time was 39 months and 40 months in MSMM group and LSM group respectively. There was no significant difference in postoperative complications, including wound dehiscence, fistulae between the MSMM group and LSM group. The patients received postoperative radiotherapy or radiochemotherapy were comparable in both groups (41.9% *VS.* 39.5%, *P* 0.05). In follow-up period, there was 1 and 2 patients were found osteoradionecrosis in MSMM group and LSM group respectively. There was no difference of recurrence, distant metastasis and patient survival status in both groups (*P* 0.05). DFS of patients was 36/43 (83.7%) and 37/43 (86%) in MSMM group and LSM group respectively. Patients were AWD and DOD were 5 (11.6%) and 2 (4.7%), 3 (7%) and 3 (7%) in MSMM group and LSM group respectively. Those data was demonstrated in Table 2.

Scar assessment was performed at 1, 6, 12 and 24 months after surgery for patients of DFS. The scale scores of scar assessment and disfigurement were shown in Table 3. The scores of both OSAS and PSAS were significant higher in LSM group than MSMM group. The scores about overall disfigurement based on 10-point Likert scale from both patients and clinician observers were higher in LSM group than MSMM group (Table 3, $P<0.05$). These data indicated that the subjective and objective scar was better in MSMM group and they have better facial appearance after surgery (Table 3 and Fig2, $P<0.05$). The lip functional assessments were shown in Table 3. There was no difference of lip function between patients in LSM group than MSMM group.

All patients of DFS in this study were completed the UW-QOL version 4 questionnaires at 1, 6, 12 and 24 months after surgery. The scores of questionnaires were shown in Table 4. There were no differences in the baseline scores of all domains between MSMM group and LSM group. The patients in both groups scored similarly for pain, activity, speech, swallowing, chewing, taste, shoulder and salvia at every time point in follow-up period. However, there was significant difference between the MSMM group and LSM group for the appearance at every time point in follow-up period. The scores of appearance from patients in MSMM group were much higher than that in LSM group. The findings for recreation, mood and anxiety were better in the MMSM group than that in the LSM group at 1 month, but there was no difference at 6, 12 and 24 months. The overall QOL of the patients in the MSMM group was better than that in the LSM group at 1 and 6 months based on the questionnaire scores.

Discussion

The surgical approach for resection of tongue cancer is highly variable and the optimal approach remains an open question[7, 12]. However, the anesthetic and functional outcomes about lip-splitting are controversial[4, 12]. This study performed a MSMM approach differed from previous non-lip-splitting approach for oncologic resection and defect reconstruction of different stage TSCC. The purpose of this retrospective paired-cohort study was to assess tumor recurrence, functional and aesthetic outcomes of the MSMM approach versus LSM approach.

An adequate three-dimensional tumor exposure is crucial to extensive tongue tumor resection and the en bloc R0 resection further affects patient's prognosis[15, 16]. The clinical application of non-lip-splitting incision for patient with TSCC is not widely accepted by surgeons. They worry that this incision can't provide adequate tumor exposure which will lead to tumor recurrence and poor patient prognosis. However, some other surgeons appreciated non-lip-splitting incision for oral cancer because it achieved both good tumor control and aesthetic outcomes [4, 6-8]. The tumor recurrence and patient prognosis was similar in patients between non-lip-splitting incision and lip-splitting incision. The MSMM approach applied in this study is differed from previous non-lip-splitting approach. Firstly, the incision of lip is transfer to submental region which will increase the width of visor flap and expose the mandible. Secondly, the mandibulotomy is easy to apply with this incision. Thirdly, transoral incision of oral floor and semi-tongue-splitting is performed before mandibulotomy. The tongue is released for good tumor exposure and negative margin is achieved for resection of tumor with different sites and sizes. As previous reports, this study also showed similar tumor recurrence and patient prognosis of patients with TSCC between MSMM and LSM approach. Thus, MSMM approach without lip-splitting is safe for oncologic resection of patients with TSCC.

The mandibulotomy in surgical treatment of oral and oropharyngeal cancer is controversial. The tumor control and frequency of complications associated with this procedure varies in many studies [11, 17, 18]. A meta-analysis showed that no significant difference was found regarding the surgical margins, overall survival rate, total and local recurrence rates, and speech and tongue movement between the mandibular preservation approach and the mandibulotomy approach in oral and oropharyngeal cancer patients. The mandibular preservation approach showed a lower complication rate after surgery[17]. However, another study showed that mandibulotomy approach provided superior local control and disease-free survival compared to transoral resection without mandibulotomy in pT2 tongue cancers [11]. In this study, mandibulotomy approach was applied in both groups and this method gained adequate access to the tumor and provided optimal margin clearance. The complication rate of fistula and ostecoradionecrosis of mandible was low in this study and adequate soft-tissue closure with free flaps and reliable fixation was important for prevention of complications after surgery.

Besides survival rate, QOL has been considered to be one of the most important outcomes in oral cancer treatment[19]. Facial disfigurement, especially the scar of lower lip following lip-splitting incision, is considered to be the most distressing aspect of QOL. We applied the modified mandibulotomy with submental incision instead of lip-splitting incision in resection of tongue cancers. As previous studies [4, 6, 7, 19], we found aesthetic and functional outcomes and other QOL domains were superior through this modified approach without lip-splitting based on the results of the POSAS and UW-QOL questionnaire in this study. Nevertheless, another study concluded that scarring and facial disfigurement were no statistically significant differences between lip-splitting and non-lip-splitting approach based on their results of the POSAS[12][1212]. They showed that the lip-splitting mandibulotomy approach also provided satisfactory scarring and low self-perception of disfigurement for oral cancer patients after surgery[12][12]. The gender and age of patients may affect the results of objective scales and

questionnaire. We found that female patients with age under than 40 years old in LSM group showed lower scores of patient scar scale and decreased QOL for the lip-splitting incision caused high levels of patient anxiety, self-consciousness of oral cancer patients after surgery.

Conclusions

The modified submandibular mandibulotomy (MSMM) approach without lip-splitting is safe and effective in tongue cancer patients underwent oncologic resection and defects reconstruction. This study shows similar surgical morbidity and tumor control compared to LSM approach, achieves better QOL associated with facial appearance and mood.

Declarations

Acknowledgements

Not applicable.

Authors' contributions

Youyuan Wang: Study concepts, study design and manuscript preparation

Bin Zhou: Data acquisition

Liujuan Sha: Quality control of data and algorithms

Tao Rui: Data acquisition

Min Fu: Statistical analysis

Chaobin Pan: Data analysis and interpretation

Weiliang Chen: Manuscript review

Funding

None.

Availability of data and materials

All data generated or analyzed during this study are included in this published article.

Declarations

Ethics approval and consent to participate

This study was approved by the Ethics Committee Board of Sun Yat-sen Memorial Hospital (KY-117).

Consent for publication

Informed consent was obtained from each participant involved in the study.

Competing interests

The authors declare that they have no competing interests.

Author details

[1]Department of Oral and Maxillofacial Surgery, Sun Yat-sen Memorial Hospital, Sun Yat-sen University, [2]The Guangdong Provincial Key Laboratory of Malignant Tumor Epigenetics and Gene Regulation, Sun Yat-sen Memorial Hospital, Sun Yat-sen University, [3]Craniomaxillofacial Surgery Center, Sun Yat-sen University, Guangzhou City, China

References

1. Siegel RL, Miller KD, Jemal A: **Cancer statistics, 2020**. *CA Cancer J Clin* 2020, **70**(1):7-30.
2. Chen W, Zheng R, Baade PD, Zhang S, Zeng H, Bray F, Jemal A, Yu XQ, He J: **Cancer statistics in China, 2015**. *CA: A Cancer Journal for Clinicians* 2016, **66**(2):115-132.
3. Rapidis AD, Valsamis S, Anterriotis DA, Skouteris CA: **Functional and aesthetic results of various lip-splitting incisions: A clinical analysis of 60 cases**. *Journal of oral and maxillofacial surgery : official journal of the American Association of Oral and Maxillofacial Surgeons* 2001, **59**(11):1292-1296.
4. Devine JC, Rogers SN, McNally D, Brown JS, Vaughan ED: **A comparison of aesthetic, functional and patient subjective outcomes following lip-split mandibulotomy and mandibular lingual releasing access procedures**. *International journal of oral and maxillofacial surgery* 2001, **30**(3):199-204.
5. Cilento BW, Izzard M, Weymuller EA, Futran N: **Comparison of approaches for oral cavity cancer resection: lip-split versus visor flap**. *Otolaryngology–head and neck surgery : official journal of American Academy of Otolaryngology-Head and Neck Surgery* 2007, **137**(3):428-432.
6. Li W, Li R, Safdar J, Huang S, Xu Z, Tan X, Sun C: **Modified visor approach applied to total or subtotal glossectomy and reconstruction: avoidance of lip splitting and mandibulotomy and cutting off mental nerve**. *Tumour biology : the journal of the International Society for Oncodevelopmental Biology and Medicine* 2014, **35**(8):7847-7852.
7. Li H, Li J, Yang B, Su M, Xing R, Han Z: **Mandibular lingual release versus mandibular lip-split approach for expanded resection of middle-late tongue cancer: A case-control study**. *Journal of cranio-maxillo-facial surgery : official publication of the European Association for Cranio-Maxillo-Facial Surgery* 2015, **43**(7):1054-1058.
8. Baek CH, Lee SW, Jeong HS: **New modification of the mandibulotomy approach without lip splitting**. *Head & neck* 2006, **28**(7):580-586.

9. Katre C, Johnson IA, Humphris GM, Lowe D, Rogers SN: **Assessment of problems with appearance, following surgery for oral and oro-pharyngeal cancer using the University of Washington appearance domain and the Derriford appearance scale**. *Oral oncology* 2008, **44**(10):927-934.
10. Djan R, Penington A: **A systematic review of questionnaires to measure the impact of appearance on quality of life for head and neck cancer patients**. *Journal of plastic, reconstructive & aesthetic surgery : JPRAS* 2013, **66**(5):647-659.
11. Ong HS, Gokavarapu S, Tian Z, Li J, Cao W, Zhang CP: **Does a mandibular access osteotomy improve survival in pT2 oral tongue cancers? Retrospective study at a single institution**. *International journal of oral and maxillofacial surgery* 2018, **47**(3):289-295.
12. Dziegielewski PT, O'Connell DA, Rieger J, Harris JR, H. S: **The lip-splitting mandibulotomy: aesthetic and functional outcomes**. *Oral oncology* 2010, **46**:612-617.
13. Draaijers LJ, Tempelman FR, Botman YA, Tuinebreijer WE, Middelkoop E, Kreis RW, van Zuijlen PP: **The patient and observer scar assessment scale: a reliable and feasible tool for scar evaluation**. *Plastic and reconstructive surgery* 2004, **113**(7):1960-1965; discussion 1966-1967.
14. Zhou B, Liao J, Zhu C, Yuan K, Liu Z, Lin Z, Huang Z, Chen W, Li J, Wang Y: **Full cheek defect reconstruction using ALTF versus RFF: Comparison of quality of life, clinical results, and donor site morbidity**. *Oral diseases* 2020.
15. Buchakjian MR, Tasche KK, Robinson RA, Pagedar NA, Sperry SM: **Association of Main Specimen and Tumor Bed Margin Status With Local Recurrence and Survival in Oral Cancer Surgery**. *JAMA Otolaryngology–Head & Neck Surgery* 2016, **142**(12):1191.
16. Ettl T, El-Gindi A, Hautmann M, Gosau M, Weber F, Rohrmeier C, Gerken M, Müller S, Reichert T, Klingelhöffer C: **Positive frozen section margins predict local recurrence in R0-resected squamous cell carcinoma of the head and neck**. *Oral oncology* 2016, **55**:17-23.
17. Pang P, Li R-W, Shi J-P, Xu Z-F, Duan W-Y, Liu F-Y, Huang S-H, Tan X-X, Sun C-F: **A comparison of mandible preservation method and mandibulotomy approach in oral and oropharyngeal cancer: A meta-analysis**. *Oral oncology* 2016, **63**:52-60.
18. Store G, Boysen M: **Mandibular access osteotomies in oral cancer**. *ORL; journal for oto-rhino-laryngology and its related specialties* 2005, **67**(6):326-330.
19. Cohen LE, Morrison KA, Taylor E, Jin J, Spector JA, Caruana S, Rohde CH: **Functional and Aesthetic Outcomes in Free Flap Reconstruction of Intraoral Defects With Lip-Split Versus Non–Lip-Split Incisions**. *Annals of Plastic Surgery* 2018:1.

Tables

Tables 1 to 4 are available in the Supplementary Files section

Figures

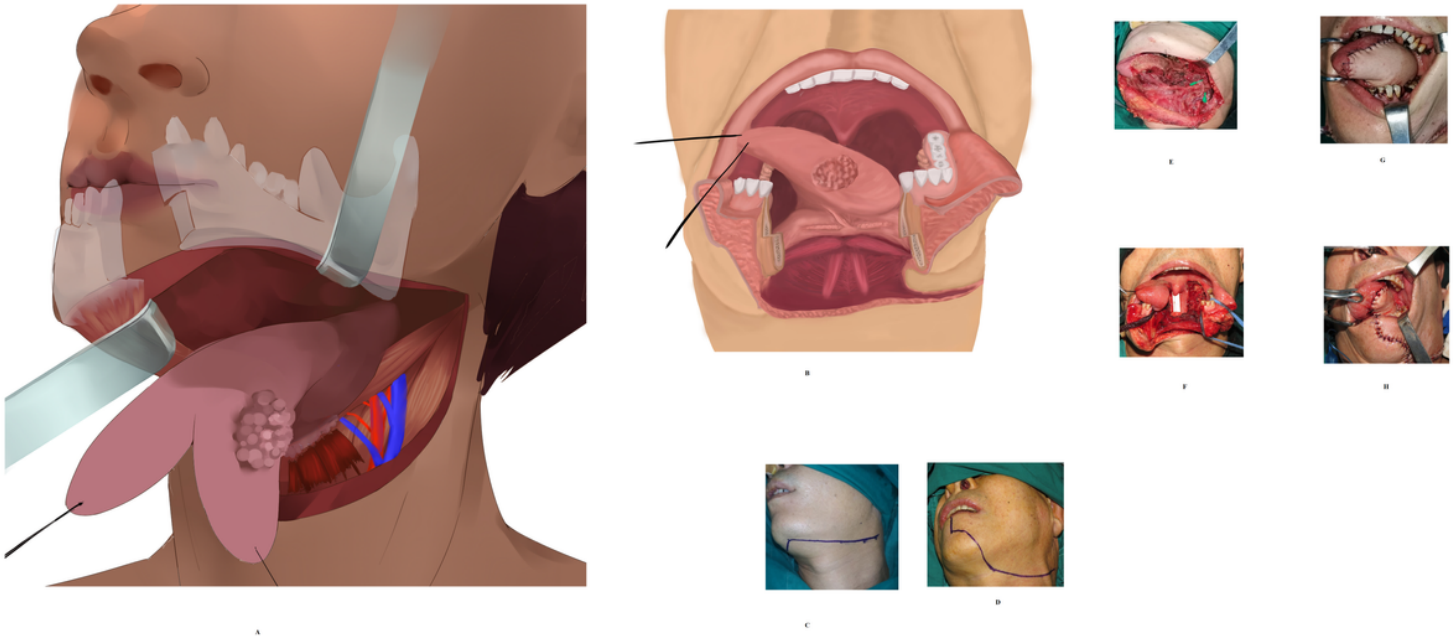

Figure 1

Modified submandibular mandibulotomy(MSMM) approach and lip-splitting mandibulotomy(LSM) approach in resection and defect reconstruction of tongue squamous cell carcinoma (TSCC). Schematic diagram of modified submandibular mandibulotomy approach (MSMM, A) and lip-splitting mandibulotomy approach (LSM, B). The incision of MSMM (C) and LSM (D) approaches. Oncologic resection (E,F) and defect reconstruction (G,H) of TSCC through MSMM and LSM approaches.

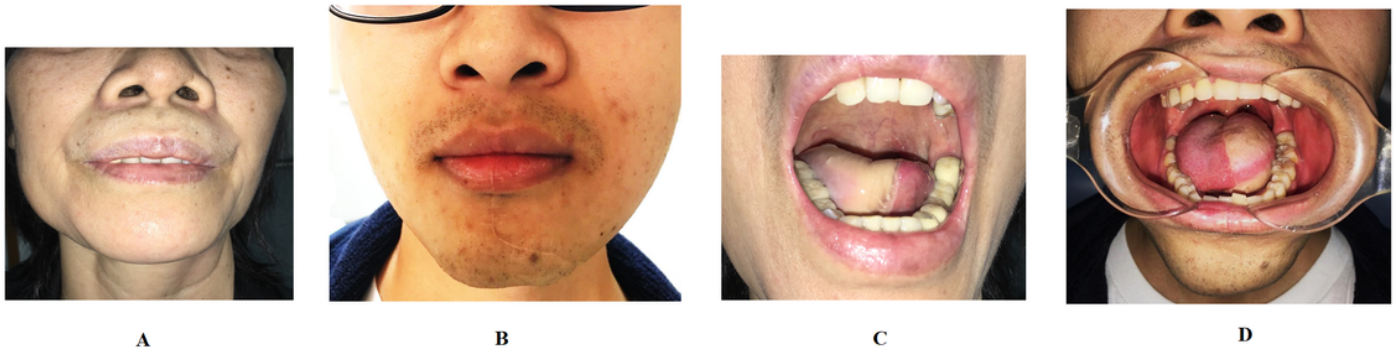

Figure 2

Facial appearance (A,B) and appearance of reconstructed tongues (C,D) at 2 years after surgery through MSMM and LSM approaches.

Supplementary Files

This is a list of supplementary files associated with this preprint. Click to download.

- Table1.docx
- Table2.docx
- Table3.docx
- Table4UWQOL.docx