Early Chest CT Features of Patients with 2019 Novel Coronavirus (COVID-19) Pneumonia: Relationship to Diagnosis and Prognosis

Hui Juan Chen
Department of Radiology, Hainan General Hospital (Affiliated Hainan Hospital of Hainan Medical College)

Jie Qiu
Department of Ultrasound, Hainan General Hospital (Affiliated Hainan Hospital of Hainan Medical College)

Biao Wu
Department of Infectious Disease, Hainan General Hospital (Affiliated Hainan Hospital of Hainan Medical College)

Tao Huang
Department of Laboratory Medicine, Hainan General Hospital (Affiliated Hainan Hospital of Hainan Medical College)

Yunsuo Gao
Medical Records Room, Hainan General Hospital (Affiliated Hainan Hospital of Hainan Medical College)

Zhen Ping Wang
Department of Radiology, Hainan General Hospital (Affiliated Hainan Hospital of Hainan Medical College)

Yang Chen
Department of Radiology, Hainan General Hospital (Affiliated Hainan Hospital of Hainan Medical College)

Feng Chen (fenger0802@163.com)
Department of Radiology, Hainan General Hospital (Affiliated Hainan Hospital of Hainan Medical College)

Research Article

Keywords: COVID-19, Tomography, Pneumonia, Thorax

Posted Date: March 9th, 2020

DOI: https://doi.org/10.21203/rs.3.rs-16702/v1

Version of Record: A version of this preprint was published at European Radiology on June 9th, 2020. See the published version at https://doi.org/10.1007/s00330-020-06978-4.

Abstract

Objective: To elucidate the consistency between CT findings and real time reverse-transcription–polymerase chain- reaction (RT-PCR) results and investigate the relationship between CT features and clinical prognosis in COVID-19.

Methods: The clinical manifestations, laboratory parameters and CT imaging findings were analyzed in thirty-four patients with COVID-19 confirmed by RT-PCR from January 20 to February 4 in Hainan province. CT score was compared between the discharged patients and ICU patients.

Results: Fever (85%) and cough (79%) were most commonly seen. 10 (29%) patients demonstrated negative results on their first RT-PCR.22/34(65%) patients showed pure ground glass opacity (GGO). 17/34 (50%) patients had five lobes of lung involvement, while the 23(68%) patients had lower lobes were involved and 24/34 (71%) were subpleural. Lesions of 24 (71%) patients were distributed mainly in the subpleural. During follow-up, the initial CT lesions of ICU patients are distributed in both subpleural and parenchyma (80%) and the lesions are scattered. 60% of ICU patients had five lobes involved, while this was seen in only 25% discharged patients. Lesions of discharged patients are mainly in the subpleural (75%). 62.5% of discharged patients showed pure ground-glass opacity. 80% ICU demonstrated progressive stage on their first CT scan. 75 % discharged patients were at an early stage. CT score of ICU patients were significantly higher than that of the discharged patients.

Conclusion: Chest CT plays a crucial role in the early diagnosis of COVID-19, particularly for those patients with negative RT-PCR. The initial features in CT may be associated with prognosis.

Authors Hui Juan Chen and Jie Qiu contributed equally to this work.

Key Points

Chest CT is valuable for early diagnosis of COVID–19 particularly for those patients with negative RT-PCR.

The early CT findings of COVID–19 in ICU patients differed from that of discharged patients.

Abbreviations

COVID–19 2019 Novel Coronavirus

CT Computed tomography

RT-PCR Real time reverse-transcription–polymerase chain- reaction

GGO Ground glass nodules

ICU Intensive care unit

MERS Middle East respiratory syndrome

SARS Severe acute respiratory syndrome

Introduction

The outbreak of new viral pneumonia induced by a novel beta coronavirus, the Corona Virus Disease (COVID–19) had received much attention over the past one and a half months. The WHO declared that the global outbreak of COVID–19 is a public health emergency of international on January 30, 2020. By the time February 9, 2020, the total confirmed cases around the world are 37554, including 37253 cases in China and 301 cases abroad. Twenty-four countries have been affected by COVID–19. Coronaviruses are enveloped non-segmented positive-sense RNA viruses. They belong to the family Coronaviridae and the order Nidovirales and widely distributed in humans and other mammals [1]. Most of the time, humans with coronavirus infections present with mild symptoms. However, the breakout of the two betacorona viruses, severe acute respiratory syndrome coronavirus (SARS-CoV) [2–4] and Middle East respiratory syndrome coronavirus (MERS-CoV) [5; 6], posed a significant threat to human health. The newly described COVID–19 have been confirmed with transmission from human to human [7]. This coronavirus has caused 813 deaths by February 9, 2020.

Up till now, real time reverse-transcription–polymerase chain- reaction (RT-PCR) test is the gold standard of COVID–19. However, the RT-PCR largely depends on the samples. This may limit the accuracy of its results. Besides, it takes a relatively long time to do the RT-PCR. No one has ever compared the consistency between RT-PCR and CT findings. Chest CT imaging stages regarding COVID–19 have rarely been reported. In the present study, we aim at systematically analyze the RT-PCR results, CT scan manifestations, and the accompanied clinical outcomes of COVID–19 infection in Hainan, China from January 26 to February 4,2020. The chest CT findings and clinical outcomes showed that lesion characteristics discriminated patients with worse prognosis from those with a better outcome.

Material And Methods

Patients

This retrospective study was approved by the Institutional Review Board of Hainan General Hospital and informed consent was gained from each patient.

From January 21, 2020, until February 4, 2020, 36 patients with confirmed COVID–19 infection were admitted to our hospitals. Among them, two patients were excluded because they did not perform the chest CT examination because of severe conditions. Thus, thirty-four patients who performed the chest CT scan in our hospital using the (NeuViz 128 CT, Neusoft, China) were included in this study. The chest CT parameter as follows: 120 kV; automatic tube current (300 mA–496 mA); iterative reconstruction method; detector, 128 mm; section thickness, 5 mm; pitch, 1.5; matrix, 512*512; and breath-hold at full

inspiration. Reconstruction was kernel used was lung smooth with a thickness of 1 mm and an interval of 0.8 mm.

CT review

All CT images were analyzed by two trained radiologists with 14 years, eight years of experience F.C and H. J.C by using the same standard. They reviewed the images independently. When disagreement occurred, a third trained radiologist (Y.C) adjudicated a final decision.

CT scans were evaluated for the following features: (1) lesion number, (2)lesions distribution, (3) primary location of the lesions, (4) the lobe involvement, (5) presence and (6) lesion patterns including pure ground-glass opacity(GGO)[8], which were defined as a hazy increase in lung attenuation with no obscuration of the underlying vessels; GGO with interlobular septal thickening or reticulation, or intralobular networks in GGO; GGO with consolidation, which was defined as an area of opacification obscuring the underlying vessels in GGO; cavity;(7) Other abnormalities including pleural effusion, lymphadenopathy (defined as a lymph node >1 cm in short-axis diameter), pleural thickening, and pericardial effusion.

A follow-up study was performed in these patients. During follow- up, a semi-quantitative scoring standard was used to quantitatively assess the pulmonary involvement of all lesions according to the area involved [9]. 5 lobes of the lung were assessed based on the criterion: 0, no involvement; 1, <5% involvement; 2, 5%–25% involvement; 3, 26%–49% involvement; 4, 50%–75% involvement: 5.>75% involvement. The total CT score was summed by all five lobe scores and ranged from 0 (no involvement) to 25 (maximum involvement). The lesion number, lesions location, primary location of lesions, numbers of lobe involved, lesion patterns and scores were allow compared between discharged patients and ICU patients.

Statistical analysis

Continuous variables were showed as mean ± standard deviation; categorical variables were demonstrated as number (%). Statistical analyses were performed using SPSS software version 21 (SPSS Inc., Chicago, IL, USA).

Results

Clinical manifestations

By February 4, 2020, 36 patients confirmed with COVID–19 admitted hospitals were admitted to Hainan General Hospital. Two patients were excluded because they did not perform the CT because of a severe condition. The average age of the patients was 54.5 years (*Table 1)*.. 23 (62%) men were infected in this study. All patients had exposure histories. The most common symptoms at the onset of illness were fever

(29 [85%] of 34 patients), cough (27 [79%]) (*Table 1)..* On admission, most patients had regular (24 [71%] patients) or decreased (9 [26%] patients) white blood cell count. 23 [68%] patients showed lymphopenia (lymphocyte count <1·0 × 10⁹/L; *Table 1),*, 27(79%) patients presented with decreased eosinophils. Most patients (25[76%]) had increased C-reactive protein levels on admission (33 patients performed) (*Table 1)..*

32 in 34 chest CT scan revealed COVID–19 pneumonia typical abnormalities on admission. The average days from the first symptom onset to CT scan was 6.4±6.5(range 0–31). Among these patients were confirmed with COVID–19 infection, 10 (29%) patients demonstrated negative results on the first RT-PCR. All these ten patients presented with typical positive findings on CT. *Figure 1* illustrated a patient showed positive CT findings but with a negative RT-PCR on first sampling.

Early stage (0–4 days after first symptom onset): Subpleural GGO in the unilaterally or bilaterally lungs was the main feature of this stage (*Figure 2a, Figure 3a).* Progressive stage/Rapidly progressive stage (5–13 days after the onset of the initial symptom): During this stage, the lesions showed relatively slow (*Figure 2b)*//rapid progression (*Figure 2c,2d),*, the lesions can extend to muti-lobes. Various imaging features include diffuse GGO, crazy-paving pattern and consolidation coexisted. Absorption stage (≥14days after the first symptom onset): At this stage, the lesion was gradually absorbed. Fourteen (41%) were defined as an early stage on initial CT scan, 16 (47%) patients were on the progressive stage, three (9%) belong to a rapidly progressive stage and one (3%) was in the stage of the consolidation period.

Six patients (18%) had a single lesion on the first CT scan, two (6%) had double lesions, most patients had multiple lesions (26, 76%). The lesions of 24 (71%) patients are mainly distributed in the subpleural. Ten patients (29%) had both subpleural and parenchyma lesions. Six patients (18%) of the total 34 patients showed one lung lobe involved, four (12%) showed two involved lobes, 1 (2%) showed three affected lobes, six (18%) had four lobes affected，seventeen had five lobes affected (50%).

The lower lobes were mostly involved (23, 68%, *Table 2),*, five patients (15%) had the upper lobe as the primary lesion location, while the lesions on six patients (18%) were scattered. No one showed lung cavitation and lymphadenopathy. One patient (3%) had small amounts of pleural effusion. Fourteen (41%) patients showed pleural thickening. Three patients (9%) showed mild pericardial effusion.

Prognosis

Eight patients showed apparent absorption during follow-up (*Table 3, Figure3, Figure 4)* and were discharged from the hospital on February 10, 2020. Six patients are still receiving treatment in the intensive care unit, and twenty-eight patients are still receiving treatment in the general wards. 80% of ICU patients demonstrated progressive stage on their first CT scan, particularly 60% of patients had experienced rapidly progressive stages. On the contrary, 75% of discharged patients were on the early stage of the disease. 4 (80%) ICU patients had multiple lesions and the distribution of the lesions involved

both subpleural and parenchyma *(Figure 2c,2d, 5)*,, while only two (25%) of the discharged patients involved both subpleural and parenchyma. 3 (60%) ICU patients had scattered lesions; the primary location of lesions in discharged patients was mainly in the lower lobe. 3(60%) ICU patients and 2(25%) discharged patients had five lobes involved, respectively. 3 (60%) ICU patients and discharged patients (37.5%) had GGO with reticular and/or interlobular septal thickening/ consolidation, respectively. ICU patients had significantly higher scores in the right upper lobe, right middle lobe, right lower lobe and total score.

Discussion

The outbreak of COVID–19 had been regarded as a global public health concern. Plain chest CT plays a crucial role in the early diagnostic, particularly for those patients with negative RT-PCR. The present study showed that 10 patients had encountered negative results at first RT-PCR. However, all these patients displayed typical CT manifestations at their first CT examination.

Our study highlighted the importance of CT examination in the early diagnosis of COVID–19. Ten patients had encountered negative nucleic acid tests of new coronavirus, while CT had positive typical findings. At present, the golden standard for confirmation of pneumonia with COVID–19 is the virus nucleic acid test. Though the specificity of the RT-PCR test is high, the accuracy of the virus nucleic acid test largely depends on the sampling personnel and samples obtained from patients. As COVID–19 is a new coronavirus, the knowledge of the detection, diagnosis, and treatment is limited. Additionally, long detection time of virus nucleic acid detection makes it difficult to solve the problem of outbreak COVID–19 of in a short time. Our study indicated that patients with positive CT and the negative viral nucleic acid test should also be included in the isolation treatment, which may be helpful in controlling the source of infection as soon as possible.

The pulmonary lesions of COVID–19 are mostly multiple with bilateral pulmonary affected. The lesions were mainly distributed in the subpleural. Parenchyma affected alone is not found in the present study. Previous studies demonstrated that the lesions of both H1N1 and SARS are located mainly in the peripherally[10; 11]. COVID–19 belongs to the family Coronaviridae. Therefore, the imaging findings might resemble those H1N1 and SARS. Recent studies [12; 13] also found the subpleural distribution in COVID–19. Our results are fitted well with the findings. Our research also indicates that the lower lobes are the most affected area, which may be specifically characteristic in these patients.

The imaging characteristics of progressive lesions may determine the prognosis. Eight patients showed lesions were getting smaller and were discharged from the hospital during follow up. Five are receiving intensive care at the time of the study. Specifically, 60% of ICU patients experiencing a rapidly progressive stage. No one in the discharged group had this stage. Most of the discharged patients were on the early stage at their first CT scan. CT is helpful in monitoring the disease progression and evaluating the effectiveness of treatment. Therefore, when a rapidly progressive stage occurred, clinicians should pay more attention to the changes in patients' conditions. Besides, our study found that discharged patients

showed fewer lobes involvement and lesions mainly located in the subpleural and lower lobe, while the ICU patients seemed to have more lobes involved and lesions are scattered distributed. The lesion involvement and distribution may be used as an indicator for the subsequent outcomes. This is consistent with the results by Huang et al. [14]. Pure GGO may be associated with a better outcome, while more lobes involvement and the scatter distribution should be used as an alert for the clinicians.

This study had several limitations that should be mentioned. The sample size is relatively small. Besides, not all the patients had 1mm in slice thickness. The present results are mainly from 5 mm in slice thickness, which may misdiagnose some subtle findings such as tiny pulmonary nodules.

In conclusion, this is a preliminary study of COVID–19 in CT plain scan results. CT imaging is valuable in the early diagnosis of the COVID–19. This is particular of great significance for those who are symptomatic but with the negative nucleic acid tests. CT is also useful for monitoring the development of the disease. Early features in CT may be associated with prognosis in these patients. Whether the treatment is beneficial could also be assessed with a chest CT scan so that the clinicians could timely fine-tune the therapy according to the change of the disease. Being scanning fast, CT screening of the COVID–19 is beneficial for both the individual and the public health surveillance systems. So far, the CT findings of COVID–19 are found to resemble other viral pneumonia diseases. Future work should find out specific imaging characteristics of new coronavirus, which could be helpful in differentiating from other diseases.

Declarations

Funding

This work was supported by the National Nature Science Foundation of China [grant number 81971602, 81760308, 81801684, 81871346]; the Program of Hainan Association for Science and Technology Plans to Youth R & D Innovation [QCXM201919]; Hainan Provincial Natural Science Foundation of China [818MS124]; the Key science and technology project of Hainan Province [grant number ZDYF2016156]; and the Chinese Key Grant [grant number BWS11J063, 10z026].

References

1Richman DD, Whitley RJ, Hayden FG e (2016) Clinical virology, 4th edn. Washington: ASM Press

2Ksiazek TG, Erdman D, Goldsmith CS et al (2003) A novel coronavirus associated with severe acute respiratory syndrome. N Engl J Med 348:1953–1966

3Kuiken T, Fouchier RA, Schutten M et al (2003) Newly discovered coronavirus as the primary cause of severe acute respiratory syndrome. Lancet 362:263–270

4Drosten C, Gunther S, Preiser W et al (2003) Identification of a novel coronavirus in patients with severe acute respiratory syndrome. N Engl J Med 348:1967–1976

5de Groot RJ, Baker SC, Baric RS et al (2013) Middle East respiratory syndrome coronavirus (MERS-CoV): announcement of the Coronavirus Study Group. J Virol 87:7790–7792

6Corman VM, Ithete NL, Richards LR et al (2014) Rooting the phylogenetic tree of middle East respiratory syndrome coronavirus by characterization of a conspecific virus from an African bat. J Virol 88:11297–11303

7Chan JF, Yuan S, Kok KH et al (2020) A familial cluster of pneumonia associated with the 2019 novel coronavirus indicating person-to-person transmission: a study of a family cluster. Lancet. 10.1016/s0140–6736(20)30154–9

8Franquet T (2011) Imaging of pulmonary viral pneumonia. Radiology 260:18–39

9Chang YC, Yu CJ, Chang SC et al (2005) Pulmonary sequelae in convalescent patients after severe acute respiratory syndrome: evaluation with thin-section CT. Radiology 236:1067–1075

10Yuan Y, Tao XF, Shi YX, Liu SY, Chen JQ (2012) Initial HRCT findings of novel influenza A (H1N1) infection. Influenza Other Respir Viruses 6:e114–119

11Wong KT, Antonio GE, Hui DS et al (2004) Severe acute respiratory syndrome: thin-section computed tomography features, temporal changes, and clinicoradiologic correlation during the convalescent period. J Comput Assist Tomogr 28:790–795

12Song F, Shi N, Shan F et al (2020) Emerging Coronavirus 2019-nCoV Pneumonia. Radiology. 10.1148/radiol.2020200274:200274

13Chung M, Bernheim A, Mei X et al (2020) CT Imaging Features of 2019 Novel Coronavirus (2019-nCoV). Radiology. 10.1148/radiol.2020200230:200230

14Huang C, Wang Y, Li X et al (2020) Clinical features of patients infected with 2019 novel coronavirus in Wuhan, China. Lancet. 10.1016/s0140–6736(20)30183–5

Tables

Table 1: Demographics and baseline characteristics of patients infected with COVID-19

Gender	
Female	13（38%）
Male	21（62%）
Age(years) (28-73)	54.5 ±11.8
Exposure History	100%
Clinical symptoms	
fever	29(85%)
cough	27(79%)
fatigue	17(50%)
Nasal congestion	2(6%)
rhinorrhea	1(3%)
sneezing	0(0%)
Sputum production	10(29%)
Hemoptysis	1(3%)
Sore throat	7(19%)
Pleura pain	0(0%)
diarrhea	1(3%)
Chest tightness	8(24%)
Biochemical Results	
White blood cell count; (normal range3·5–9·5×10e9/L)	24normal(71%),9decreased(26%),1(3%)increased
Lymphocyte percentage (normal range20-50%)	23normal(68%)，11(32%)decreased,0 increased
Neutrophil count; (normal range1.8-6.3×10e9/L)	27(79%)normal,5decreased(15%),2(6%)increased
Lymphocyte count (normal range1.1-3.2×10e9/L)	10(29%)normal,23(68%)decreased,1(3%)increased
Monocytes count; (normal range0.1-0.6×10e9/L)	30(88%)normal,0decreased,4(12%)increased
Eosinophils count; (normal range0.02-0.52×10e9/L)	7(21%)normal，27(79%)decreased,0 increased
Basophils count (normal range0-0.06×10e9/L)	33 (97%)normal,0 decreased,1(3%) increased
RBC Male (normal range4.3-5.8×10e12/L) Female (normal range3.8-5.1×10e12/L)	28(82%)normal,4decreased(12%),2(6%)increased
Hemoglobin Male (normal range130-175g/L) Female (normal range115-150g/L)	29(85%)normal,5(15%)decreased,0 increased
Hematocrit Male (normal range0.4-0.5) Female (normal range0.35-0.45)	27(79%)normal,6decreased(18%),1(3%)increased
Mean corpuscular volum; (normal range82-100fL)	32(94%)normal,2(6%)decreased,0 increased
Mean Corpuscular Hemoglobin (normal range 27-34pg)	32(94%)normal,2(6%)decreased,0 increased
Mean Corpuscular hemoglobin concentration MCHC (normal range 316-354g/L)	32(94%)normal,2(6%)decreased,0 increased
Red blood cell volume distribution width RDW-CV (normal range ≤15%)	33(97%)normal, no decreased,1(3%) increased
serum retinol-binding; (normal range25-70mg/L)	12(43%)normal,16(57%)decreased,0 increased
C-reactive protein; (normal range0.068-8.2mg/L)	8(24%)normal,0decreased,25(76%)increased

Table 2 Manifestations of first CT in 34 Patients

Details of imaging examination	
Days from first symptom onset to first CT scan	6.4±6.5days
Nucleic acid test	
Negative in the first RT-PCR	10(31%)
Positive in the first RT-PCR	24(69%)
CT Imaging stages on admission	
Early stage	15(44%)
Progressive stage	16(47%)
Rapidly progressive stage	3(9%)
Absorption period	0
Lesion Number	
Single	6(18%)
Double	2(6%)
Multiple	26(76%)
Lesions distribution	
subpleural	24(71%)
Parenchyma	0
Both subpleual and parenchyma	10(29%)
Primary location of lesions	
Upper lobe	5(15%)
Middle lobe	0(0%)
Lower Lobe	23(68%)
Scattered distribution	6 (17%) (ICU,3; no ICU, 3)
Numbers of Lobe involved	
0	0
1	6(18%)
2	4(12%)
3	1(3%)
4	6(18%)
5	17(50%)
Lesion Patterns	
Pure ground-glass opacity	22(65%)
GGO with reticular and/or interlobular septal thickening	9(27%)
GGO with Consolidation	3(8%)
Cavity	0
Other findings	
Pleural Effusion	1(3%)
Lymphadenectasis	0
Pleural thickening	14(4%)
pericardial effusion	3(9%)

Table 3 CT patterns between ICU and discharged patients on initial CT scan

CT patterns	ICU (5)	Discharged (8)
Stage		
Early stage	1(20%)	6(75%)
Progressive stage	1(20%)	2(25%)
Rapidly progressive stage	3(60%)	0
Consolidation period	0	0
Lesion Number		
Single	1(20%)	1(12.5%)
Double	0	1(12.5%)
Multiple	4(80%)	6(75%)
Lesions distribution		
subpleural	1(20%)	6(75%)
Parenchyma	0	0
Both subpleual and parenchyma	4(80%)	2(25%)
Main location of lesions		
Upper lobe	1(20%)	2(25%)
Middle lobe	0	0
Lower Lobe	1(20%)	5(62.5%)
Scattered distribution	3(60%)	1(12.5%)
Numbers of Lobe involved		
1	0	1(12.5%)
2	1(20%)	2(25%)
3	0	1(12.5%)
4	1(20%)	2(25%)
5	3(60%)	2(25%)
Lesion Patterns		
Pure ground-glass opacity	2(40%)	5(62.5%)
GGO with reticular and/or interlobular septal thickening	1(20%)	2(25%)
GGO with Consolidation	2(40%)	1(12.5%)
Cavity	0	0
CT score of every lobe		
Right upper lobe	1±1	3±1*
Right middle lobe	1±1	3±2*
Right lower lobe	1±1	4±2*
Left upper lobe	1±1	3±2
Left lower lobe	1±1	3±2
Total score	5±3	15±8*

NNote: Quantitative dada were expressed as mean ± standard deviation(minimun-maximum). * Mann-Whitney U test showed statistical difference in the right upper lobe, right middle lobe, right lower lobe and total score between the discharged patients and ICU patients.

Figures

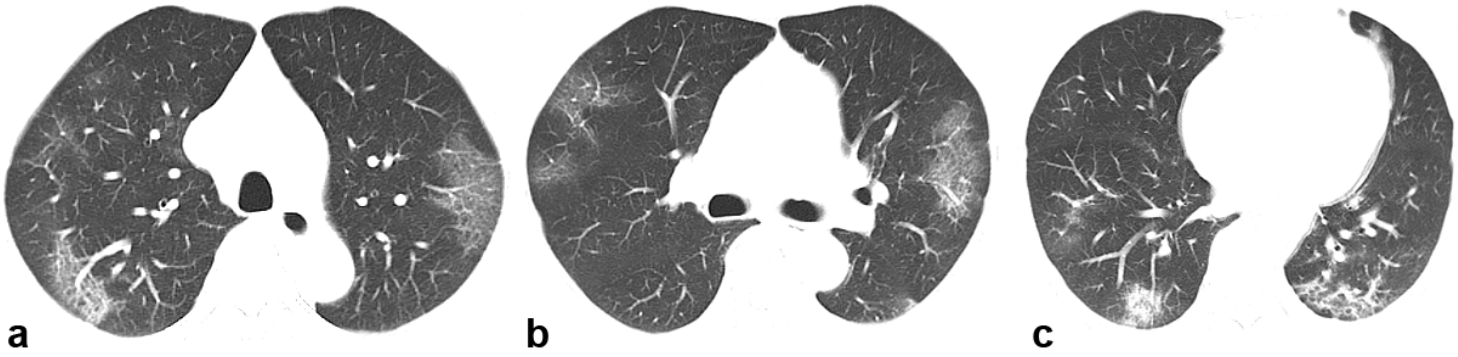

Figure 1

A 62-year old man with exposure history, presenting with fever, cough, expectorating white phlegm, nausea and vomiting. A chest CT scan reveals multiple confluent and patchy ground-glass and consolidative pulmonary opacities in the subpleural of bilateral lungs on hospital admission on January 29,2020. The patient underwent the swabs tested positive for COVID-19 by real-time reverse-transcriptase–polymerase-chain-reaction (RT-PCR) assay on January 30, 2020 and the result was negative. The patient underwent a second swab RT-PCR test on January 31, 2020 and the COVID-19 infection was finally confirmed.

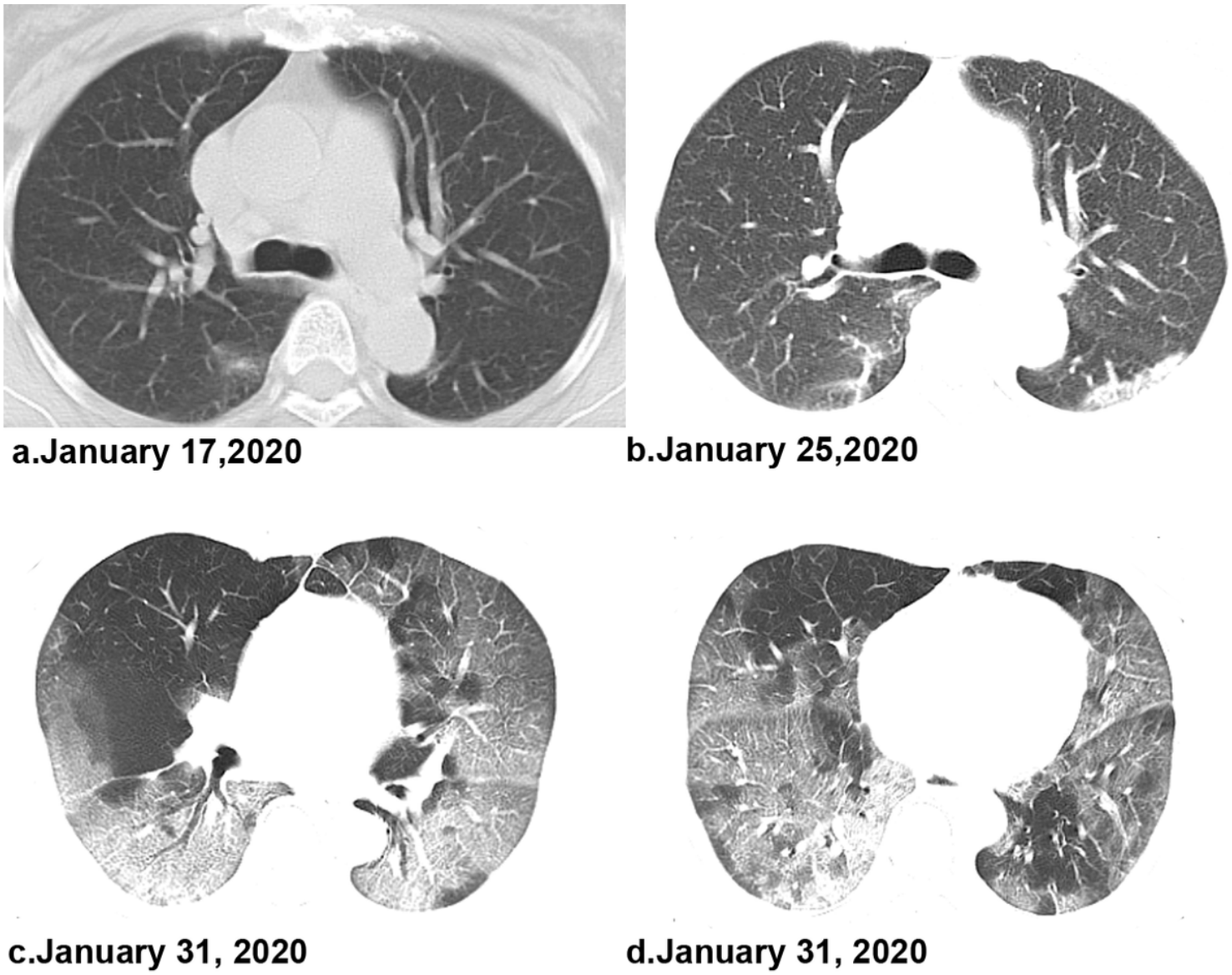

Figure 2

A 64-year woman of Wuhan local resident, presenting with fever on January 16. CT plain scan revealed patchy ground-glass in the lower lobe of the right lung on January 17(a). Follow-up CT revealed the infection progressed and the lesions extended to a bilateral multi-lobe distribution with consolidation (b). (c, d) A 73-year old man presented with cough 8 days ago. The CT images on admission showed bilateral

multiple lobular and subsegmental areas of GGO with subsegmental areas of consolidation, indicating the disease was undergoing a rapidly progressive stage.

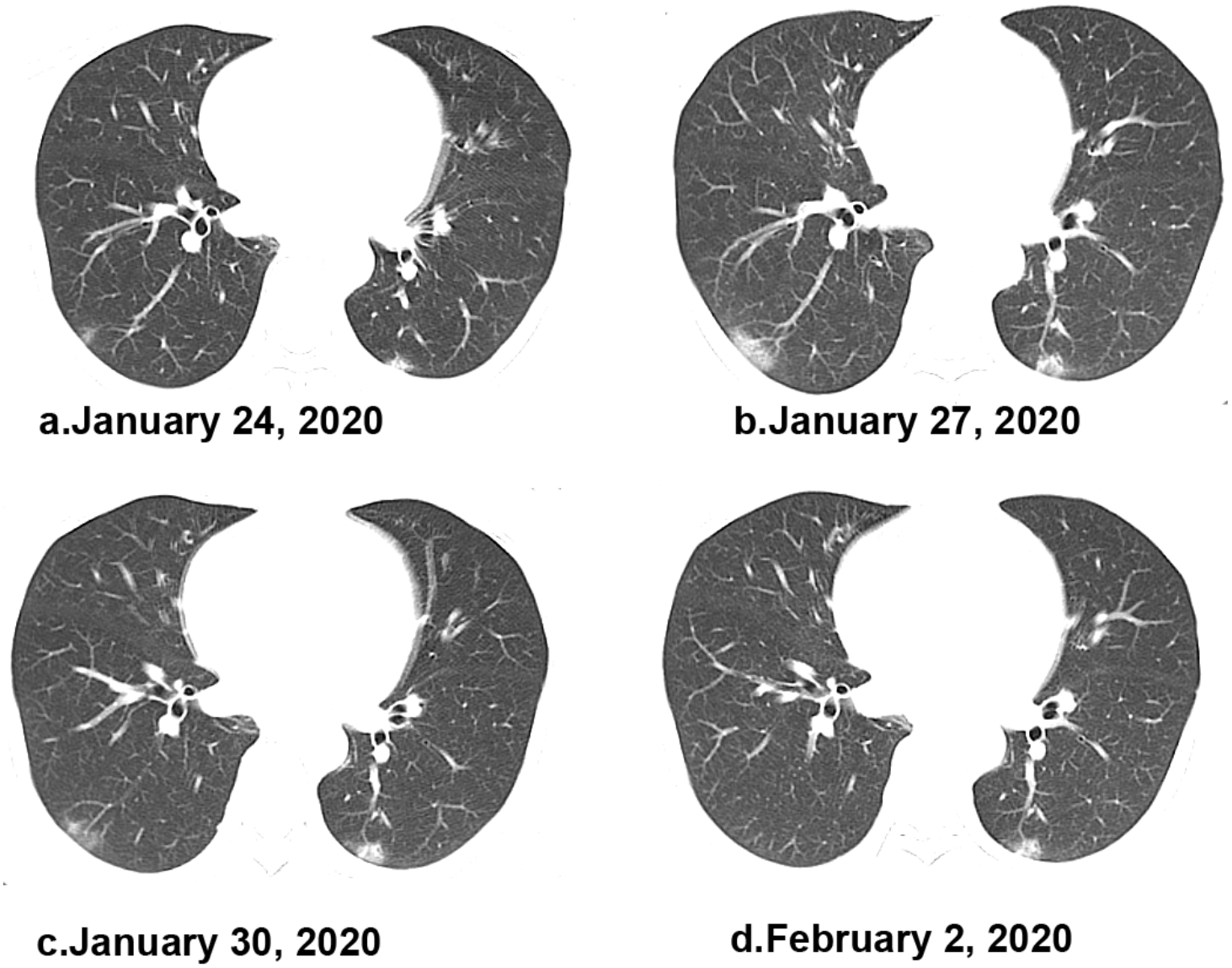

Figure 3

A 50-year older woman with exposure history, presenting with cough and white phlegm for four days, accompanied by headache, muscle ache and no fever. A chest CT scan shows small patchy ground-glass lesions in the left lung and the inferior lobe of the right lung on hospital admission on January 24, 2020 (a). The patient was confirmed with COVID-19 acid infection on January 26, 2020. The lesion shows progression on January 27, 2020(b). The lesions on CT plain scan are smaller by January 30, 2020(c). The lesion was absorbed than previously by February 2,2020 (d). This patient was discharged four days later.

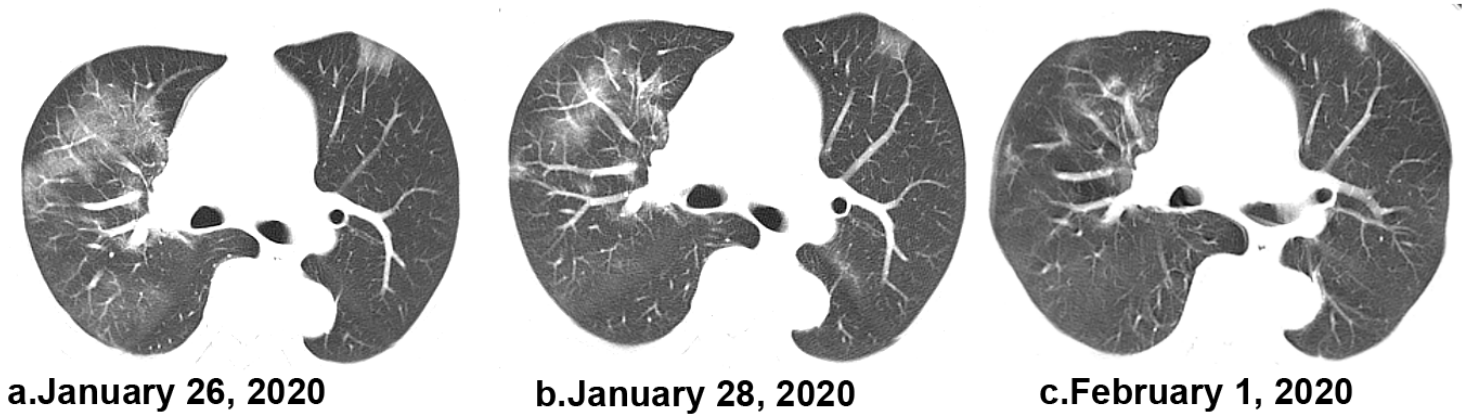

Figure 4

A 55-year old man of Wuhan local resident, displayed with cough and fever. Fever was accompanied by dizziness, headache, chest tightness, shortness of breath and diarrhea. CT scan showed multiple small patchy ground-glass lesions in bilateral lungs on hospital admission on January 26, 2020 (a). After treatment, the lesions on CT plain scan shows gradual absorbed on January 28, 2020 and February 1, 2020 (b, c). This patient was discharged five days later without clinical symptoms.

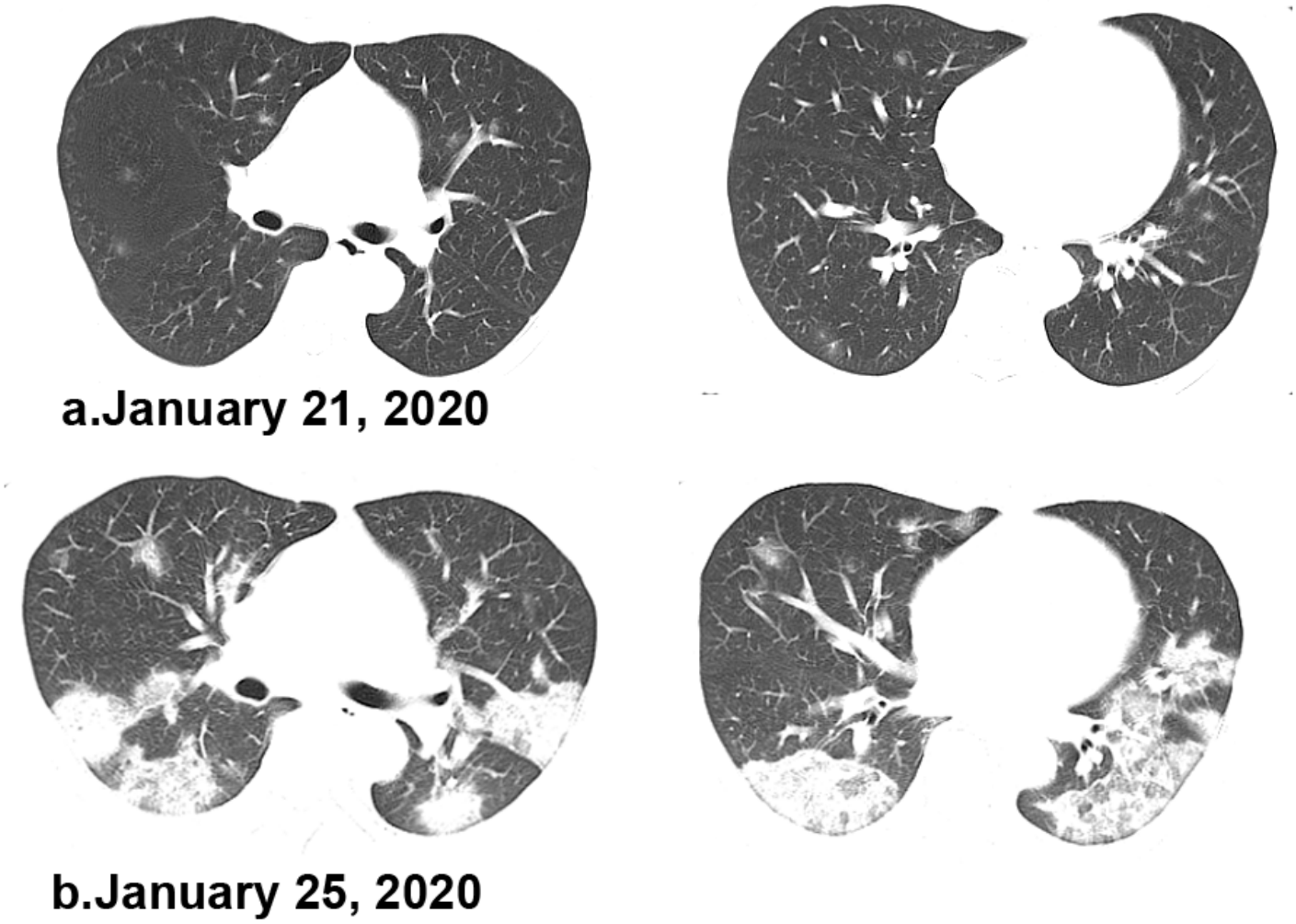

Figure 5

A 45-year old man of Wuhan local resident with exposure history, presenting with fever, cough, expectorating yellow phlegm, stuffy nose, runny nose, headache and obvious muscle ache. CT scan reveals multiple sparse patchy ground-glass lesions in the subpleural and parenchyma of bilateral lungs on hospital admission on January 21, 2020. The patient was administered into an intensive care unit. CT revealed obvious progression in the disease on January 25, 2020.