A retrospective clinical comparative study of intramedullary nailing and minimally invasive plate osteosynthesis for extra-articular distal tibia fractures

Chaofeng Wang (fengwcf2007@163.com)
Hong Hui Hospital, Xi'an Jiaotong University College of Medicine

Qiang Huang
Hong Hui Hospital, Xi'an Jiaotong University College of Medicine

Dongsheng Lu
Hong Hui Hospital, Xi'an Jiaotong University College of Medicine

Ning Duan
Hong Hui Hospital, Xi'an Jiaotong University College of Medicine

Conming Zhang
Hong Hui Hospital, Xi'an Jiaotong University College of Medicine

Qian Wang
Hong Hui Hospital, Xi'an Jiaotong University College of Medicine

Teng Ma
Hong Hui Hospital, Xi'an Jiaotong University College of Medicine

Kun Zhang
Hong Hui Hospital, Xi'an Jiaotong University College of Medicine

Zhong Li
Hong Hui Hospital, Xi'an Jiaotong University College of Medicine

---

Article

Keywords: Extra-articular fracture, MIPO, IMN, functional outcome, distal tibia fracture

Posted Date: May 31st, 2022

DOI: https://doi.org/10.21203/rs.3.rs-1675197/v1

Abstract

The treatment of extra-articular distal tibia fractures is a difficult challenge. Minimally invasive plating osteosynthesis (MIPO) and intramedullary nailing (IMN) are satisfactory extra-articular distal tibia fractures. The optimal surgical treatment for extra-articular distal tibia fractures remains controversial. The purpose of this retrospective study was to compare the clinical and functional outcomes of patients with extra-articular distal tibia fractures treated with MIPO or IMN. For this retrospective study, a total of 266 patients with closed extra-articular distal metaphysis (OA type 43-A) or closed distal tibial fracture (AO type 42) were enrolled and included; 110 patients were treated with MIPO, and 156 patients underwent IMN. There was no significant difference in the primary operation union rate, AOFAS score, deep surgical site infection or malalignment between the MIPO and IMN groups. However, there was a longer operation time, more prospective times, more intraoperative blood loss and more frequent anterior knee pain in the IMN groups than in the MIPO group. There was a significantly shorter time to union in the IMN group than in the MIPO group (138.8 ± 11.0 vs. 153.5 ± 17.1 days, $p < 0.05$) and a lower superficial surgical site infection in the IMN group than in the MIPO group (1.9% vs. 8.2%, $p < 0.05$). We found that extra-articular distal tibia fractures can be treated satisfactorily with IMN or MIPO. Pollor blocking screws have a main role in improving the efficacy of IMN. Regardless of the operation time, intraoperative blood loss and occurrence of anterior knee pain, IMN was recommended as the choice to treat extra-articular distal tibia fractures.

Introduction

The treatment of extra-articular distal tibia fractures is a hard challenge because of the peculiar anatomy of the distal tibia, paucity of soft tissue coverage, relatively poor blood supply and injury of bone and soft tissue caused by high-energy injury. Conservative treatment has a poor functional result and more late complications. The main purpose of operative treatment is to restore the anatomical alignment of the distal tibia and to provide sufficient stability to promote fracture healing and decrease late complications [1]. The traditional surgical treatment for distal tibia fractures using open reduction and international fixation with plating has more serious soft tissue interference and larger blood supply destruction. In recent years, minimally invasive techniques, such as minimally invasive plating osteosynthesis (MIPO) and intramedullary nailing (IMN), have been reported to treat distal tibia fractures [2–10]. IMN has been used for the management of these fractures because of its minimal invasiveness, reduced blood loss during surgery, early weight bearing, lower infection rate of the surgical site and faster healing of the fracture. However, IMN is associated with higher nonunion, a higher occurrence rate of anterior knee pain [11–14] and a more obvious tendency towards malalignment [2–6]. The MIPO technique has a simple operation, is minimally invasive, and provides better protection of the periosteal blood supply and a more stable fracture end [8–10]. However, some studies have shown that MIPO might be associated with higher rates of infection and implant-related complications [15–16]. Therefore, the optimal surgical treatment for extra-articular distal tibia fractures remains controversial.

Materials And Methods

Distal tibial fracture was defined as a fracture involving the distal third, distal to the isthmus of the tibia, and within 10 cm of the joint line [17-18]. For this retrospective study, patients with closed extra-articular distal metaphysis (OA type 43-A) or closed distal tibial fracture (AO type 42) who were treated in Xi'an Honghui Hospital from January 2016 to January 2021 either with MIPO or IMN, aged >18 years and duration of injury<2 weeks, were enrolled, whereas patients with compound fractures, vascular injuries, poly-trauma or pathological fractures were excluded from the study. Furthermore, patients whose follow-up information was incomeplete (<12 months) were excluded from the study. All methods in this study were carried out in accordance with relevant guidelines and regulations. All experimental protocols were approved by Honghui Hospital Ethics Committee.

Surgical technique and fellow-up

The timing of the surgery was decided according to the status of the soft tissue and degree of swelling. If there are blisters or blood blisters on the skin, the operation is usually performed in 7 to 10 days. All the patients lay on the fluoroscopic operating table in a supine position. All patients received a single dose of 1.5 g cefuroxime sodium 30 min prior to surgery as an antibiotic prevention. All patients received intravenous infusion of 1.5 g of tranexamic acid 15 min prior to surgery to reduce intraoperative bleeding. All patients underwent surgery after application of a tourniquet at the root of the thigh.

MIPPO technique

An approximately 3-5 cm medial median longitudinal incision from the tip of the medial malleolus to the proximal end was made to prevent injury to the saphenous nerve and vein. The epiperiosteal tunnel was made either by a blunt periosteal detacher or by a blunt tip of a plate inserted through the incision towards the proximal. After traction, manipulation and reduction of the fracture, the distal tibial locking plate was positioned on the anteromedial aspect of the tibia shaft. For fractures with unsatisfactory manual reduction, pointed bone holding forceps or lag screw technology are used to help reduce fractures. After insertion of the plate and achieving reduction, the plate was fixed to the bone with a locking screw in the distal tibia and with a combination of cortical nonlocking and locking screws in the proximal tibia. The fibula was fixed when the fracture was within the syndesmosis region or the lower tibiofibular joint was unstable.

IMN technique

A medial longitudinal incision of the patella tendon of approximately 5-6 cm was made in the IMN group. After the patellar tendon was pulled to the outside, an entry portal was made in the anterior bare area of the tibial plateau. The entry point was confirmed in the C-arm with anteroposterior and lateral views. A guide wire was passed through the entry portal to the distal end of the tibia after provisional reduction of the fracture with pointed bone holding forceps. Sequential reaming was performed and fixed with suitable length IMN. The nail was fixed with 2 or 3 distal locking screws and 2 proximal locking screws.

In the IMN group, most patients needed 1 or 2 poller blocking screws to help reduce fracture, adjust the alignment or enhance the fracture stability. The fibula was fixed when the fracture was within the syndesmosis region or the lower tibiofibular joint was unstable.

Postoperative protocol

Prophylactic antibiotic therapy by intravenous administration of cefuroxime sodium (2nd generation of cephalosporin) was started during the surgery and continued until 24 hours after the operation. During the hospitalization period, all patients received low molecular weight heparin to prevent deep venous thrombosis. Rehabilitation exercises began from the first postoperative day, including quadriceps femoris training, ankle pump training and flexion and extension of adjacent joints. During the 2 weeks after the operation, a walking aid was used to assist in walking without weight bearing. Then, weight bearing was performed gradually based on the clinical and radiological improvements.

Data measurement

Operation time, perspective times by C-arm, and intraoperative **blood loss in the two groups were** extracted from the hospital's patient records. These data were used to evaluate the level of surgical difficulty and its impact on patients.

In our hospital, all patients were routinely followed up at 0, 4, 8, 12, 16, 20, 24, 32, 40, 48 and 52 weeks. The radiographs and clinical results extracted from the hospital's patient records were evaluated by all authors. Clinical union was defined as lack of pain in the full weight-bearing time. Radiological union was determined based on the modified radiological union scale for tibia (mRUST) score [19] in anteroposterior and lateral radiographs. An mRUST score of 10 or more than 10 was considered to accurately predict the healing of fractures [20-21]. Nonunion was defined as an mRUST score less than 10 at the 12-month follow-up. [21].

The American Orthopaedic Foot and Ankle surgery (AOFAS) scoring system [22] and occurrence of anterior knee pain associated with surgery were used to evaluate the function of the ankle and the effect of surgery on patient's knee function, respectively, at 12 months after operation follow-up examination by all authors.

Main Complications.

Data on complications, including infection, malalignment (angular malalignment and rotational alignment), and nonunion, were extracted from patient records. Rotational malalignment was defined as an iatrogenic rotational deformity of ≥10° based on clinical CT measurements [23-24]. Angular malalignment was defined as angular deformities of ≥ 5° in the coronal or sagittal plane [25-27]. Surgical site infections (SSI) were divided into superficial surgical site infections and deep surgical site infections according to the definition of the Centers of Disease Control (CDC) [28].

Statistical methods

The statistical software package SPSS 18.0 was used to analyse the results. Descriptive statistics were provided for all baseline characteristics and study endpoints. Quantitative variables were documented as the mean ± standard deviation. Quantitative variables between the two groups were assessed by independent Student's t test, while qualitative data between two groups were assessed by either the chi-square test or Fisher's exact test. A p value < 0.05 was considered statistically significant.

Results

From January 2016 to January 2021, 266 patients with distal tibial fracture were included in the retrospective study; 110 patients were treated with MIPO, and 156 patients were treated with IMN. The mean follow-up was 18 months (range 12–44 months). Baseline characteristics are described in Table 1. There were several significant differences between the two treatment groups.

The study results showed that there was a significant difference in operation time, perspective times by C-arm and intraoperative blood loss between the two groups (Table 2). Operation time in the IMN group was significantly longer than that in the MIPO group (109.8±18.4 min vs. 81.8±12.6min). Perspective times by C-arm in the IMN group were significantly greater than those in the MIPO group (39.6±10.9 times vs. 26.1±8.7 times). Intraoperative blood loss in the IMN group was significantly greater than that in the MIPO group (222.8±70.6ml vs. 91.3±25.7 ml).

Fracture healing and clinical results

The study results showed that there were significant differences in the time to union and occurrence of anterior knee pain between the two groups (Table 3). After excluding the data of patients with nonunion, time to union in the IMN group (138.8±11.0 days) was significantly shorter than that in the MIPO group (153.5±17.1 days). The X-ray image of the typical patient treated by IMN have been shown in figure 1. The X-ray image of another typical patient treated by MIPO have been shown in figure 2. All patients in the MIPO group had no anterior knee pain during the 12-month follow-up. However, 22 patients in the IMN group (14.1%) suffered from anterior knee pain during the 12-month follow-up. After the primary operation, there were 12 patients with nonunion in the IMN group and 5 patients in the MIPO group at 12 months after surgery. Although the primary operation union rate (95.5%, 105/110) was higher in the MIPO group than in the IMN group (92.3%, 144/156), there was no statistically significant difference between the two groups. Moreover, there was no difference in the AOFAS score between the two groups 12 months after surgery (87.3±7.7 vs. 86.3±6.9) (Table 3) (Table 3).

Main complications

In total, 14 SSI were observed, 10 (9.1%) in the MIPO group and 4 (2.6%) in the IMN group. There was one deep SSI and 9 superficial SSI in the MIPO group. There was one deep SSI and 3 superficial SSI in the IMN group. The results showed that there was no significant difference in deep SSI rate between the two groups. However, the superficial SSI rate in the MIPO group (8.2%) was higher than that in the IMN group

(1.9%). All infections in the two groups were treated with antibiotics, surgical debridement, removal of the implants or skin grafting.

Seventeen malalignments, including rotational and angular malalignment, were observed, 6 (5.5%) in the MIPO group and 11 (7.1%) in the IMN group. There was no significant difference between the groups in terms of rotational malalignment and angular malalignment. Rotational malalignment was seen in 2 (1.8%) patients treated with MIPO and 4 (2.6%) with IMN, without showing significance (p=0.14). Angular malalignment occurred in 4 (3.6%) patients treated with MIPO and 7 (4.9%) patients treated with IMN (p=1.0).

Discussion

Plates seem to be the obvious choice for distal tibia fracture more than a decade ago. However, with the development of IMN technology, more patients with distal tibia fractures are treated with intramedullary nails. Some studies have compared MIPO techniques with IMN techniques [29–35]. These study results are inconsistent and sometimes show conflicting views. To date, the optimal surgical treatment for extra-articular distal tibia fractures remains controversial. From the retrospective study, we found that all patients treated with IMN or MIPO for distal tibia fractures had satisfactory clinical results and limb function. Our results show that there was no significant difference in the primary operation union rate, AOFAS score, deep SSI or malalignment between the MIPO group and the IMN group. However, our study's results also show that there is a longer operation time, more perspective times, more intraoperative blood loss and more frequent anterior knee pain in the IMN groups than in the MIPO group. However, there was a significantly shorter time to union and fewer superficial SSI in the IMN group than in the MIPO group.

Our study results show that intraoperative blood loss in the IMN group was significantly greater than that in the MIPO group (222.8 ± 70.6 ml vs. 91.3 ± 25.7 ml). Intraoperative blood loss is rarely used as a comparative index, perhaps because the IMN and MIPO techniques are minimally invasive surgeries. This difference was confirmed because tibial reaming increased intramedullary bleeding. The operation time and intraoperative fluoroscopy times in the IMN group were significantly longer than those in the MIPO group, which is also different from those reported in the literature [1. 36], in which MIPO was associated with a longer operative time due to complicated indirect reduction techniques of MIPO. In our study, IMN was associated with a longer operative time and intraoperative fluoroscopy times due to poller blocking screw techniques helping fracture reduction and enhancing fracture stability under fluoroscopic guidance. We found that increasing the number of poller screws used during the operation generally increased the operation time by more than 8 minutes and the number of intraoperative fluoroscopy procedures by more than 10 times. More than 80% of patients in the IMN group need poller screws to help fracture reduction or enhance fracture stability.

The rate of union or nonunion is a main factor in evaluating final clinical outcomes. Our study results show that there was no statistically significant difference in the primary operation union rate between the

two groups. Our result was also consistent with results in other reports [4. 37]. However, some reports have shown that distal extra-articular fractures of the tibia treated with IMN have a significantly lower primary operation union rate in comparison to MIPO [32–33. 38–40]. Although nonunion is associated with many factors, surgical technique is one of the most important determinants of union. We think that the higher union rate in our study could be attributed to these two factors. One factor is that both surgical techniques are minimally invasive; they do not disrupt the fracture hematoma or impair the healing process. Another main factor is that the pollor blocking screws in the IMN group helped the fracture anatomical reduction and enhanced the fracture stability, which could increase the fracture healing ability. Time to union is another main factor in evaluating final clinical outcomes. Our study results show that time to union in the IMN group (138.8 ± 11.0 days) was significantly shorter than that in the MIPO group (153.5 ± 17.1 days). The results were also consistent with most research results[1. 4. 7. 34]. We think that the shorter time to union in the IMN group could be attributed to the reasonable biomechanics and micromotion of the fracture, which could accelerate the fracture healing process[41–42].

The higher rates of malalignment in IMN to MIPO were reported in most previous studies [2–6]. Some reports showed that the rates of malalignment after IMN were up to 35%. However, our results show that there was no significant difference between the groups in terms of rotational malalignment and angular malalignment. Rotational malalignment was seen in 2 (1.8%) patients treated with MIPO and 4 (2.6%) with IMN, without showing significance ($p = 0.14$). Angular malalignment occurred in 4 (3.6%) patients treated with MIPO and 7 (4.9%) patients treated with IMN ($p = 1.0$). The lower rates of malalignment in the IMN group can possibly be attributed to the use of poller blocking screws to help fracture anatomical reduction and adjust the alignment of the tibia. Bleeker NJ et al. also reported that adjusting the alignment by bilateral draping might be effective in reducing malalignment after definitive treatment of distal extra-articular tibia fractures. [32]

The main complications in our study showed that there was no significant difference in deep SSI between the two groups; however, the superficial SSI rate in the MIPO group (6.4%) was higher than that in the IMN group (1.9%). A higher rate of SSI after MIPO has also been extensively reported [1. 4. 43] and can be explained by the poor soft tissue envelope on the medial side of the distal tibia, the less soft tissue compromise during IMN and the probably less direct reduction techniques [44]. Therefore, we suggest IMN treatment for patients with poor local soft tissue conditions, such as blisters, blood blisters and obvious redness and swelling, to reduce the incidence of infection.

Conclusion

Based on our study results, we found that extra-articular distal tibia fractures can be treated satisfactorily with IMN or MIPO. Both surgeries have similar results for the primary operation union rate, AOFAS, deep SSI and malalignment, although there were significant differences in operation time, perspective times by C-arm, intraoperative blood loss, time to union, occurrence of anterior knee pain and superficial SSI rate. Pollor blocking screws have a main role in improving the efficacy of IMN. Regardless of the operation

time, intraoperative blood loss and occurrence of anterior knee pain, IMN was recommended as the choice to treat extra-articular distal tibia fractures.

Declarations

Data availability statement The datasets generated during and/or analysed during the current study are available from the corresponding author on reasonable request.

Acknowledgements The authors gratefully acknowledge the contribution of Medical record management department and Imaging department.

Author contributions Wang Chaofeng, Huang Qiang, Li Zhong and Zhang Kun have made substantial contributions to the conception. Lu Dongsheng and Wang Chaofeng have collected the data. Wang Chaofeng and Huang Qiang has performed the data analysis. Wang Chaofeng wrote the main manuscript text. Zhang Congming Ma Teng Wang Qian and Duan Ning have substantively revised the manuscript. All authors read and approved the final manuscript.

Additional information Ethical Approval The Honghui Hospital Research Ethics Committee has confirmed that no ethical approval is required

Competing interests The authors declare that there is no conflict of interest.

Funding This study was supported by by Natural Science Basic Research Program of Shaanxi (Program No. 2022JM-529)

Consent to Participate

Informed consent was obtained from all individual participants included in the study.

Consent to Publish

The authors affirm that human research participants provided informed consent for publication of the images in Figure 1, and 2.

References

1. Daolagupu AK, Mudgal A, Agarwala V. A comparative study of intramedullary interlocking nailing and minimally invasive plate osteosynthesis in extra articular distal tibial fractures. Indian J Orthop. 51, 292–298 (2017).
2. Maufrey C, McGuinness K, Parsons N, Achten J, Costa ML. A randomised pilot trial of “locking plate” fixation versus intramedullary nailing for extra-articular fractures of the distal tibia. J Bone Joint Surg Br. 94(5), 704–8. https://doi.org/10.1302/0301- 620X.94B5.28498 (2012).

3. Vallier HA, Cureton BA, Patterson BM. Randomized, prospective comparison of plate versus intramedullary nail fixation for distal tibia shaft fractures. J Orthop Trauma. 25(12), 736–41. https://doi.org/10.1097/BOT.0b013e318213f709 (2011).
4. Guo JJ, Tang N, Yang HL, Tang TS. A prospective, randomised trial comparing closed intramedullary nailing with percutaneous plating in the treatment of distal metaphyseal fractures of the tibia. J Bone Joint Surg Br. 92(7), 984–8. https://doi.org/10.1302/ 0301-620X.92B7.22959 (2010).
5. Vallier HA. Current evidence: plate versus intramedullary nail for fixation of distal tibia fractures in 2016. J Orthop Trauma. 30(Suppl 4), S2–6. https://doi.org/10.1097/BOT.0000000000 000692 (2016).
6. Avilucea FR, Triantafillou K, Whiting PS, Perez EA, Mir HR. Suprapatellar intramedullary nail technique lowers rate of malalignment of distal tibia fractures. J Orthop Trauma. 30(10), 557–60. https://doi.org/10.1097/BOT.0000000000 000631(2016).
7. Prasad P, Nemade A, Anjum R, Joshi N. Extra-articular distal tibial fractures, is interlocking nailing an option? A prospective study of 147 cases. Chin J Traumatol. 22(2), 103–107 (2019).
8. Ronga M, Longo UG, Maffulli N. Minimally invasive locked plating of distal tibia fractures is safe and effective. Clin Orthop Relat Res. 468, 975–982. https:// doi.org/10.1007/s11999-009-0991-7 (2010).
9. Shrestha D, Acharya BM, Shrestha PM. Minimally invasive plate osteosynthesis with locking compression plate for distal diametaphyseal tibia fracture. Kathmandu Univ Med J. 9, 62–68. https://doi.org/10.3126/kumj.v9i2.6291(2011).
10. Mushtaq A, Shahid R, Asif M, et al. Distal tibial fracture fixation with locking compression plate (LCP) using the minimally invasive percutaneous osteosynthesis (MIPO) technique. Eur J Trauma Emerg Surg. 35, 159–164. https://doi.org/10.1007/s00068-008-8049-1 (2009).
11. Chan DS, Serrano-Riera R, Grifng R, Steverson B, Infante A, Watson D, Sagi HC, Sanders RW. Suprapatellar versus infrapatellar tibial nail insertion: a prospective randomized control pilot study. J Orthop Trauma. 30(3), 130–4. https://doi.org/10. 1097/BOT.0000000000000499 (2016).
12. Jones M, Parry M, Whitehouse M, Mitchell S. Radiologic outcome and patient-reported function after intramedullary nailing: a comparison of the retropatellar and infrapatellar approach. J Orthop Trauma. 28(5), 256–62. https://doi.org/10.1097/BOT. 0000000000000070 (2014).
13. Leliveld MS, Verhofstad MH. Injury to the infrapatellar branch of the saphenous nerve, a possible cause for anterior knee pain after tibial nailing? Injury. 43(6), 779–83. https://doi.org/10. 1016/j.injury.2011.09.002 (2012).
14. Ozcan C, Turkmen I, Sokucu S. Comparison of three diferent approaches for anterior knee pain after tibia intramedullary nailing. Eur J Trauma Emerg Surg. 46(1), 99–105. https://doi. org/10.1007/s00068-018-0988-6 (2020).
15. Vaienti E, Schiavi P, Ceccarelli F, Pogliacomi F. Treatment of distal tibial fractures: prospective comparative study evaluating two surgical procedures with investigation for predictive factors of unfavourable outcome. Int Orthop. 43(1), 201–7. https:// doi.org/10.1007/s00264-018-4121-6 (2019).

16. Seyhan M, Unay K, Sener N. Intramedullary nailing versus percutaneous locked plating of distal extra-articular tibial fractures: a retrospective study. Eur J Orthop Surg Traumatol. 23(5), 595–601. https://doi.org/10.1007/s00590-012-1016-x (2013).
17. Nork SE, Schwartz AK, Agel J, Holt SK, Schrick JL, Winquist RA: Intramedullary nailing of distal metaphyseal tibial fractures. J Bone Joint Surg Am. 87, 1213–1221 (2005).
18. Kruppa CG, Hoffmann MF, Sietsema DL, Mulder MB, Jones CB: Outcomes after intramedullary nailing of distal tibial fractures. J Orthop Trauma. 29, e309-e315 (2015).
19. Litrenta, J., Tornetta, P., 3rd, Mehta, S., Jones, C., O'Toole, R. V., Bhandari, M., et al. Determination of radiographic healing: An assessment of consistency using RUST and modifed RUST in Metadiaphyseal fractures. Journal of Orthopaedic Trauma. 29(11), 516–520 (2015).
20. Misir A, Uzun E, Kizkapan TB, Yildiz KI, Onder M, Ozcamdalli M Reliability of RUST and Modified RUST Scores for the Evaluation of Union in Humeral Shaft Fractures Treated with Different Techniques. Indian J Orthop. 54(Suppl 1), 121–126 (2020).
21. Wenger R, Oehme F, Winkler J, Perren SM, Babst R, Beeres FJP. Absolute or relative stability in minimal invasive plate osteosynthesis of simple distal meta or diaphyseal tibia fractures? Injury. 48(6), 1217–23 (2017).
22. Kitaoka HB, Alexander IJ, Adelaar RS, et al. Clinical rating systems for the ankle hindfoot, midfoot, hallux, and lesser toes. Foot Ankle Int. 15, 349–53 (1994).
23. Bleeker NJ, Cain M, Rego M, Saarig A, Chan A, Sierevelt I, Doornberg JN, Jaarsma RL. Bilateral low-dose computed tomography assessment for post-operative rotational malalignment after intramedullary nailing for tibial shaft fractures: reliability of a practical imaging technique. Injury. 49(10), 1895–900. https://doi.org/10.1016/j.injury.2018.07.031 (2018).
24. Cain ME, Hendrickx LAM, Bleeker NJ, Lambers KTA, Doornberg JN, Jaarsma RL. Prevalence of rotational malalignment after intramedullary nailing of tibial shaft fractures: can we reliably use the contralateral uninjured side as the reference standard? J Bone Joint Surg Am. 102(7), 582–91. https://doi.org/10.2106/ JBJS.19.00731 (2020).
25. Milner SA. A more accurate method of measurement of angulation after fractures of the tibia. J Bone Joint Surg Br. 79(6), 972–4. https://doi.org/10.1302/0301-620x.79b6.7458 (1997).
26. Vallier HA, Cureton BA, Patterson BM. Randomized, prospective comparison of plate versus intramedullary nail fxation for distal tibia shaft fractures. J Orthop Trauma. 25(12), 736–41. https://doi.org/10.1097/BOT.0b013e318213f709 (2011).
27. Avilucea FR, Triantafillou K, Whiting PS, Perez EA, Mir HR. Suprapatellar intramedullary nail technique lowers rate of malalignment of distal tibia fractures. J Orthop Trauma. 30(10), 557–60. https://doi.org/10.1097/BOT.0000000000 000631 (2016).
28. Mangram AJ, Horan TC, Pearson ML, Silver LC, Jarvis WR. Guideline for prevention of surgical site infection, 1999. Centers for Disease Control and Prevention (CDC) Hospital Infection Control Practices Advisory Committee. Am J Infect Control. 27(2), 97–132 (1999).

29. Kc KM, Pangeni BR, Marahatta SB, Sigdel A, Kc A. Comparative study between intramedullary interlocking nailing and minimally invasive percutaneous plate osteosynthesis for distal tibia extra-articular fractures. Chin J Traumatol. 25(2), 90–94 (2022).
30. Barcak E, Collinge CA. Metaphyseal Distal Tibia Fractures: A Cohort, Single-Surgeon Study Comparing Outcomes of Patients Treated With Minimally Invasive Plating Versus Intramedullary Nailing. J Orthop Trauma. 30(5), e169-e174 (2016).
31. Mioc ML, Prejbeanu R, Deleanu B, Anglitoiu B, Haragus H, Niculescu M. Extra-articular distal tibia fractures-controversies regarding treatment options. A single-centre prospective comparative study. Int Orthop. 42(4), 915–919. doi:10.1007/s00264-018-3775-4 (2018).
32. Bleeker NJ, van Veelen NM, van de Wall BJM, et al. MIPO vs. intra-medullary nailing for extra-articular distal tibia fractures and the efficacy of intra-operative alignment control: a retrospective cohort of 135 patients. Eur J Trauma Emerg Surg. 10 (2022).
33. Liu XK, Xu WN, Xue QY, Liang QW. Intramedullary Nailing Versus Minimally Invasive Plate Osteosynthesis for Distal Tibial Fractures: A Systematic Review and Meta-Analysis. Orthop Surg. 11(6), 954–965. doi:10.1111/os.12575 (2019).
34. Polat A, Kose O, Canbora K, Yanık S, Guler F. Intramedullary nailing versus minimally invasive plate osteosynthesis for distal extra-articular tibial fractures: a prospective randomized clinical trial. J Orthop Sci. 20(4), 695–701. doi:10.1007/s00776-015-0713-9 (2015).
35. Tahir MM, Khan DN, Chaudhry MEA, et al. A Multicentre Randomized Controlled Trial Comparing Plating with Intramedullary Nailing for Extra-articular Distal Tibial Fractures. Injury. 52(1), 19–25. doi:10.1016/j.injury.2020.11.046 (2021).
36. Wang B, Zhao Y, Wang Q, et al. Minimally invasive percutaneous plate osteosynthesis versus intramedullary nail fixation for distal tibial fractures: a systematic review and meta-analysis. J Orthop Surg Res. 14(1), 456 (2019).
37. Li Y, Jiang X, Guo Q, Zhu L, Ye T, Chen A. Treatment of distal tibial shaft fractures by three different surgical methods: a randomized, prospective study. Int Orthop. 38(6), 1261–7 (2014).
38. Yu J, Li L, Wang T, Sheng L, Huo Y, Yin Z, Gu G, He W. Intramedullary nail versus plate treatments for distal tibial fractures: a meta-analysis. Int J Surg. 16(Pt A), 60–8. https://doi.org/10.1016/j.ijsu.2015.02.004 (2015).
39. Kwok CS, Crossman PT, Loizou CL. Plate versus nail for distal tibial fractures: a systematic review and meta-analysis. J Orthop Trauma. 28(9), 542–8. https://doi.org/10.1097/BOT.0000000000000068 (2014).
40. Goh EL, Chidambaram S, Eigenmann D, Ma S, Jones GG. Minimally invasive percutaneous plate osteosynthesis versus intramedullary nail fixation for closed distal tibial fractures: a meta-analysis of the clinical outcomes. SICOT J. 4, 58 (2018).
41. Dailey HL, Daly CJ, Galbraith JG, Cronin M, Harty JA. A novel intramedullary nail for micromotion stimulation of tibial fractures. Clin Biomech (Bristol, Avon). 27(2), 182–188. doi:10.1016/j.clinbiomech.2011.08.009 (2012).

42. Dailey HL, Schwarzenberg P, Webb Iii EB, Boran SAM, Guerin S, Harty JA. Pilot study of micromotion nailing for mechanical stimulation of tibial fracture healing. Bone Jt Open. 2(10), 825–833. doi:10.1302/2633-1462.210.BJO-2021-0121.R1 (2021).
43. Costa ML, Achten J, Griffin J, et al. Effect of Locking Plate Fixation vs Intramedullary Nail Fixation on 6-Month Disability Among Adults With Displaced Fracture of the Distal Tibia: The UK FixDT Randomized Clinical Trial. JAMA. 318(18), 1767–1776. doi:10.1001/jama.2017.16429 (2017).
44. Santolini E, West R, Giannoudis PV. Risk factors for long bone fracture non-union: a stratification approach based on the level of the existing scientific evidence. Injury. 46 Suppl 8, S8-S19. doi:10.1016/S0020-1383(15)30049-8 (2015)

Tables

Table 1 Main characteristics of the patients in the two groups

Characteristics	IMN (156)	MIPO (110)	p Value
Age	46.6±6.8	43.3±7.5	
Sex (male)	93	72	
Blister or blood blister	68	47	

Table 2 Comparison of operation time, perspective times by C-arm and intraoperative blood loss between the two groups

Surgical data	IMN (156)	MIPO (110)	p Value
Operation time (min)	116±16	85±12	
Perspective times by C-arm	45±5	22±4	
Intraoperative blood loss (ml)	214±38	80±22	

Table 3 Comparison of the clinical outcomes and main complications between MIPO and IMIL nailing groups

Clinical outcomes and main complications	IMN (156)	MIPO (110)	p Value
Time to union (day)	134.54±15.36	151.06±18.18	
Primary operation union rate	144	105	
AOFAS scores	86.24±8.74	84.76±10.74	
Anterior knee pain	22	0	
Malalignments	11	6	
Deep SSI	1	1	
Superficial SSI	3	9	

Figures

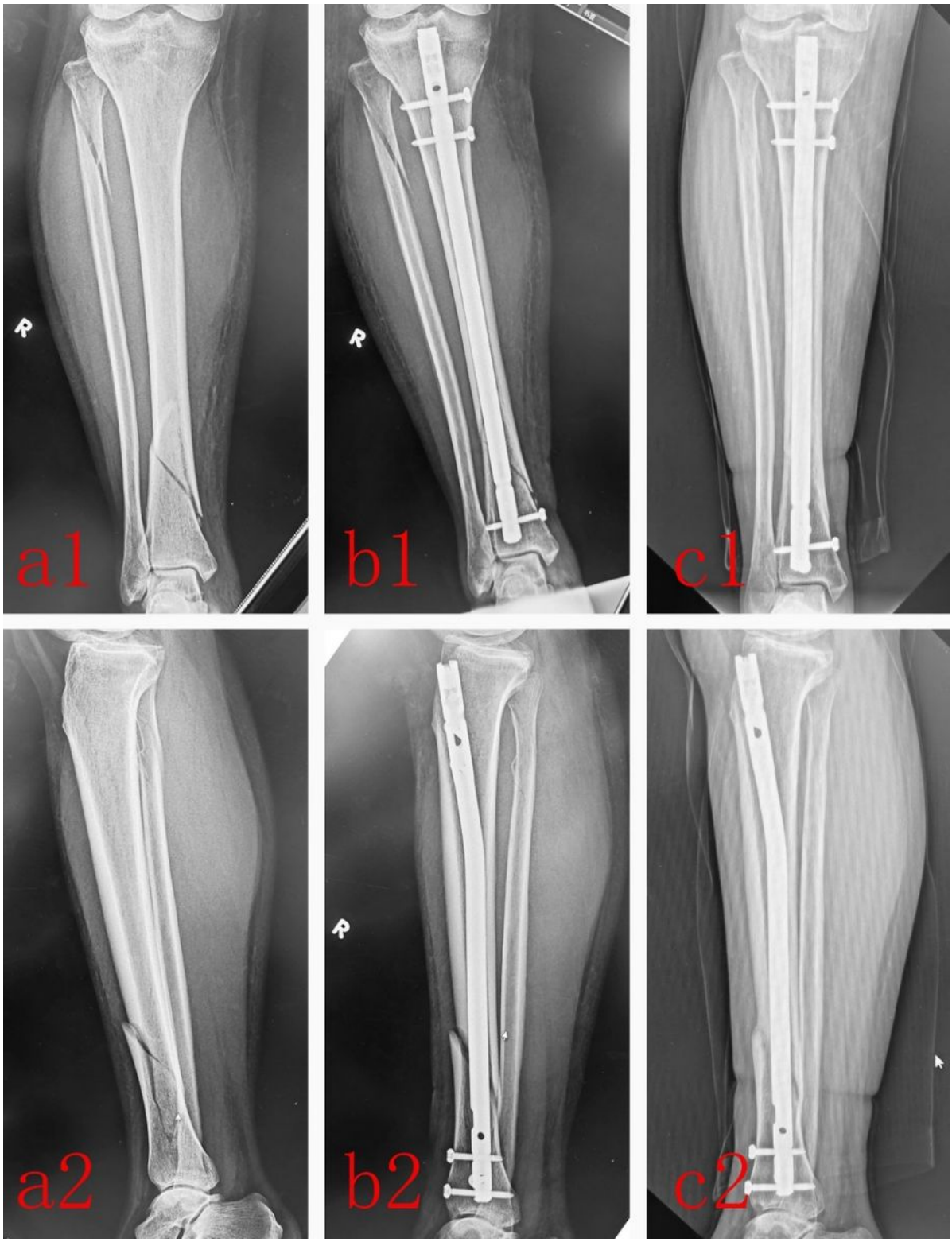

Figure 1

Radiological image of a typical patient treated by IMN. The preoperative anteroposterior X-ray (a1) and the preoperative lateral X-ray (a2) showed that the fracture had not healed and the plate had been broken. An anteroposterior X-ray (b1) and lateral X-ray (b2) at 1 month after the operation showed that the fracture lines were clear. An anteroposterior X-ray (c1) and lateral X-ray (c2) at 5 months after the operation showed that the fracture lines were blurred and had healed well.

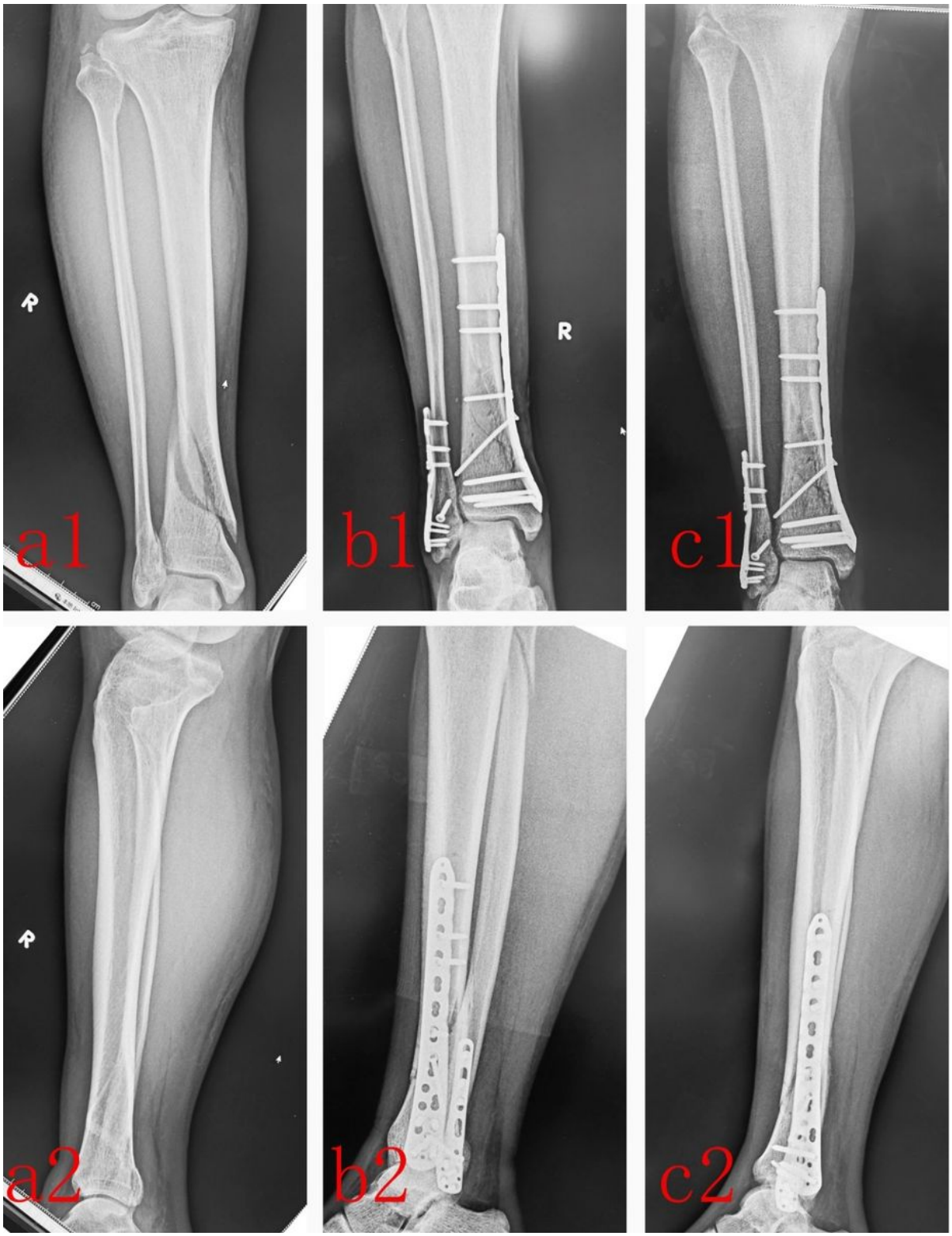

Figure 2

Radiological image of a typical patient treated by MIPO. The preoperative anteroposterior X-ray (A1) and the preoperative lateral X-ray (A2) showed that nonunion of the femur shaft was clear. An anteroposterior X-ray (B1) and lateral X-ray (B2) at 1 month after the operation showed that the fracture lines were still clear. An anteroposterior X-ray (C1) and lateral X-ray (C2) at 6 months after the operation showed that the fracture lines were blurred and had healed well.