Simultaneous opening-wedge distal tubercle osteotomy and double-bundle anterior cruciate ligament reconstruction for anterior cruciate ligament-deficient knees with medial compartment osteoarthritis: technical tip

Ryosuke Kawai (jobryohoo_k@yahoo.co.jp)
Asahi University Hospital
Itaru Kawashima
Asahi University Hospital
Takashi Tsukahara
Asahi University Hospital
Yoshiaki Kusaka
Asahi University Hospital

Research Article

Keywords: high tibial osteotomy, opening-wedge distal tubercle osteotomy, double-bundle anterior cruciate ligament reconstruction, simultaneous, combined surgery

Posted Date: May 23rd, 2022

DOI: https://doi.org/10.21203/rs.3.rs-1675484/v1

Abstract

The surgical outcomes of simultaneous anterior cruciate ligament reconstruction (ACLR) and high tibial osteotomy (HTO) are good in ACL-deficient knees with medial compartment osteoarthritis (OA). However, this procedure has issues to be solved, such as mild knee instability and progression of OA after surgery. Herein, we introduce our surgical procedure and technical tip of opening-wedge distal tubercle osteotomy (OWDTO) performed simultaneously with anatomical double-bundle ACLR (DBACLR). This procedure aims to achieve long-term knee stability by anatomically reconstructing the ACL using the double-bundle technique even though ACLR and OWDTO are both performed for ACL-deficient knees with medial compartment OA.

1. Background

The surgical outcomes of simultaneous anterior cruciate ligament reconstruction (ACLR) and high tibial osteotomy (HTO) are good in ACL-deficient knees with medial compartment osteoarthritis (OA) [1–3]. However, this procedure has some issues to solve, such as mild knee instability and OA progression after surgery [2), 4–6]. Schneider et al. [2] have reported that combined ACLR (bone–patella tendon–bone graft) and opening-wedge high tibial osteotomy (OWHTO) can facilitate sustainable knee stabilization based on a 10-year follow-up. Moreover, return to sport at the same level was possible just for one-third of patients with femorotibial OA progression in 39% of cases. Shuster et al. [6] performed OWHTO combined with ACLR and chondral resurfacing on 23 patients, and all patients had Kellgren–Lawrence (KL) grade 3–4 knees. Four ACL grafts (18.1%) were insufficient, and two (9.1%) were stable but had signs of degeneration. However, most reports about combined OWHTO and ACLR performed single-bundle ACLR (SBACLR), not double-bundle ACLR (DBACLR).

Also, the increasing incidence of patellofemoral (PF) joint compression after OWHTO has been a cause of concern [7,8]. To address this problem, several studies have assessed opening-wedge distal tubercle osteotomy (OWDTO) [9–12].

2. Purposes

The current report aimed to present our surgical procedure and technical tip of OWDTO performed simultaneously with anatomical DBACLR.

3. Indications

The indications for the procedure are ACL-deficient knees with medial compartment OA, particularly acute ACL rupture and relatively early OA (KL grades 2–3), are good indications (Table 1).

Table 1
Indication of simultaneous DBACLR with OWDTO

	Active indication	Negative indication
1)	Primary medial compartment OA is better	K-L grade 4 Extensive ICRS grade 4 cartilage damage A lot of osteophytes Joint subluxation
2)	Normal posterior tibial slope	Posterior tibial slope angle > 12°
3)	Acute ACL rupture is better	Chronic ACL rupture with severe anterior tibial translation

4. Surgical Techniques

Patients were placed in supine position under general anesthesia.

1) Routine arthroscopy

Standard anteromedial and anterolateral portals were created. The condition of the cartilage, particularly that of the PF joint, was evaluated, and lateral release was performed as needed.

2) Skin incision

A longitudinal 8-cm incision was made between the tibial tubercle and posteromedial tibial cortex.

3) Graft preparation

The gracilis (GC) and semitendinosus (ST) were harvested with an open-ended tendon stripper. In general, grafts for the anteromedial bundle (AMB) and the posterolateral bundle (PLB) were created with a four- or double-fold ST and four- or double-fold GC, respectively. EndoButton (Smith & Nephew Endoscopy, Andover MA) was used for fixation on the femoral side. The other end of the grafts was stitched with a 2.5-mm Telos artificial ligament (Aimedic MMT, Tokyo, Japan) for fixation on the tibial side.

4) Creation of the femoral and tibial tunnels

In addition, the distal anteromedial portal was created 2 cm medial from the anteromedial portal, and the femur tunnels were established independently using the transportal technique. The tibial tunnels for the AMB and PLB, with an angle of 50° and 55°, respectively, were created in the anatomical ACL footprint using the ACUFEX Anatomic ACL Guide (Smith & Nephew Endoscopy, Andover MA). Then, dilators were used to smoothen the tunnels (Figs. 1A, B).

5) Osteotomy

OWDTO was performed according to the procedure of Gaasbeek [13]. The superficial medial collateral ligament (sMCL) was released completely at the distal attachment to the tibial cortex, and a retractor was inserted behind the proximal tibia to protect the neurovascular structures.

The initial oblique osteotomy was initiated at the medial cortex 4 cm distal from the medial tibia plateau and was terminated at the lateral hinge point (5 mm medial from the lateral cortex and at the level of the proximal tibiofibular joint) using a bone saw. The second descending osteotomy of the tibial tubercle was performed distally, leaving the tuberosity in the proximal fragment. The angle between the descending and oblique planes was 90°, and the thickness and length of the distally osteotomized tibial tubercle were 7–10 and 40 mm, respectively. The distal end was cut to form a tapered shape (Fig. 1C).

The oblique osteotomy site was gradually opened using a bone spreader while the knees were extended, and the lower extremity alignment was confirmed. The postoperative weight-bearing line was targeted to pass 57–67% from the medial edge of the medial plateau (based on the severity of cartilage damage). Next, the OSferion ® (β-tri-calcium phosphate; Olympus Terumo Biomaterials, Tokyo, Japan) blocks, which were cut to size, were placed in the opened space [14]. The released sMCL was sutured using 0-Vicril, and the OSferion ® blocks were covered.

To fix the distal part of the tibial tubercle to the distal fragment of the tibia, a 5.0–6.0-mm cannulated cancellous screw (Meira, Nagoya, Japan) was inserted in an anterior–posterior direction using a flat washer.

6) Plate fixation

The Tris plate® (Olympus Terumo Biomaterials, Tokyo, Japan) was set at the optimum position in the medial cortex of the tibia, and the dilators were inserted again into the tibial tunnels. The locking screws for plate fixations were sequentially inserted. When the screw was drilled in the proximal front-hole of the plate, interference was confirmed with a dilator in the PLB. Therefore, a short screw was inserted (Figs. 1D, E, and F).

7) Graft passage and fixation

Graft passage and EndoButton flipping in the lateral femoral cortex were performed in the PLB and then the AMB. The latter was fixed with a force of 30 N and the former with a force of 20 N using three M4 staples ® (Meira, Nagoya, Japan) in the anterior tibial cortex with a knee flexion angle of 20° while axial pressure was applied (Figs. 1G). To fix the grafts, three staples were inserted into the distal fragment of the tibia while preventing interference with the plate screws (Figs. 2A, B).

8) Postoperatively

Knee range-of-motion and exercises were started 1 day after surgery. Patients could walk with full weight-bearing 2–3 weeks after surgery. Then, the protocol for normal ACLR alone was followed; patients could jog 4 months after surgery, and they resumed sports activities after 8–9 months. Gap filling at the

osteotomy site was almost achieved 3–4 months after surgery. Second-look arthroscopy and implant removal were performed 1 year after surgery (Fig. 3).

5. Discussion

OWDTO performed simultaneously with anatomical DBACLR aims to achieve long-term knee stability by anatomically reconstructing the ACL with the double-bundle technique even though ACLR and HTO are performed simultaneously for ACL-deficient knees with medial compartment OA. Surgical indications and patient selection are important, and acute ACL rupture and relatively early OA (KL grades 2–3) are good surgical indicators.

By contrast, in cases of severe OA such as those with KL grade 4 or in cases with extensive cartilage damage (grade 4) based on the International Cartilage Research Society (ICRS) system, abundance of osteophytes and joint subluxation are not good indications; thus, a two-stage surgery should be considered. In this case, alignment correction via HTO should be prioritized over ACL reconstruction. Mehl et al. [15)] have investigated the use of HTO alone or in combination with ACLR for ACL deficiency and varus osteoarthritis. Results showed that HTO alone can improve pain and even subjective knee stability. Then, correction osteotomy was initially performed. ACL should be reconstructed during plate removal if required.

An excessive posterior tibial slope increases the axial load on the ACL. Thus, in cases in which the posterior tibial slope angle was > 12° [16, 17)], we corrected not only varus deformity but also excessive tibial slope by initially performing closing-wedge HTO (CWHTO) or hybrid CWHTO [18)].

In our surgical procedure, the plate was fixed after creating tibial tunnels for DBACLR. The tunnel position was prioritized over the plate position because its accuracy is important for the clinical outcome of anatomical DBACLR. When drilling the proximal screws of the plate, the dilators were inserted again into the tibial tunnels to validate if there is interference between the drill and dilators. In most cases, the proximal-front screw of the plate interferes with the tibial tunnels in the PLB if they are created in the anatomical ACL footprint. The use of a short screw can solve the problem (Table 2).

Table 2
Technical tips of simultaneous DBACLR with OWDTO

	Technical Tip	Rationale
1)	Perform tunnels drilling for grafts before DTO.	Tunnels should be created in the anatomical ACL footprint.
2)	When drilling proximal screws of plate, dilators were inserted again into tibial tunnels.	Avoid interference between tibial tunnels and proximal screws of plate.
3)	Use of a short screw for proximal-front hole of the plate.	When creating bone tunnels in an anatomical position, the anterior screw can interfere with the PL tunnel.

The current study had several limitations. Only the concept and indications of the procedure were presented. Moreover, the representative cases were few in number. To validate the significance of the procedure, long-term outcomes should be assessed, and randomized controlled trials must be performed.

6. Conclusion

Simultaneous OWDTO and DBACLR is not technically complex. The procedure may be an option for ACL-deficient knees with medial compartment OA if the indications are appropriate.

Abbreviations

ACLR anterior cruciate ligament reconstruction

DBACLR double-bundle ACL reconstruction

SBACLR single-bundle ACL reconstruction

HTO high tibial osteotomy

OWHTO opening-wedge HTO

OWDTO opening-wedge distal tubercle osteotomy

CWHTO closing-wedge HTO

OA osteoarthritis

PF patellofemoral

WBL weight-bearing line

AMB anteromedial bundle

PLB posterolateral bundle

KL Kellgren–Lawrence

ICRS International Cartilage Research Society

ATT anterior tibial translation

GC gracilis

ST semitendinosus

sMCL superficial medial collateral ligament

Declarations

Ethics approval and consent to participate

Informed written consent was obtained from the participant in the study and the ethical board of Asahi University approved the study. All methods were carried out in accordance with relevant guidelines and regulations. This study was carried out in accordance with relevant guidelines and regulations. Informed consent was obtained from all individual participants included in the study.

Consent for publication

The patients provided permission for this study to be published, and their identity has been protected. A copy of the written consent is available for review by the Editor of this journal.

Availability of data and materials

All data concerning the case are presented in the manuscript.

Competing interests

The authors declare that they have no competing interests.

Funding

No funding was provided. The authors declare no conflict of interest associated with this manuscript.

Authors' Contributions

RK and IK performed the surgery.

RK and IK designed the study and drafted the manuscript.

TT and YK assisted with drafting of the manuscript and prepared the figures.

All authors have read and approved the final manuscript.

Acknowledgements

Not applicable.

References

1. Malahias MA, Shahpari O, Kaseta MK. The clinical Outcome of One-stage High Tibial Osteotomy and Anterior Cruciate Ligament Reconstruction. A Current Concept Systematic and Comprehensive Review; Arch Bone Jt Surg. 2018 May;6(3):161-168
2. Schneider A, Gaillard R, Gunst S, Batailler C, Neyret P, Lustig S, Servien E. Combined ACL reconstruction and opening wedge high tibial osteotomy at 10-year follow-up: excellent laxity control but uncertain return to high level sport; Knee Surg Sports Traumatol Arthrosc. 2020 Mar;28(3):960-968.
3. Li Y, Zhang H, Zhang J, Li X, Song G, Feng H. Clinical outcome of simultaneous high tibial osteotomy and anterior cruciate ligament reconstruction for medial compartment osteoarthritis in young patients with anterior cruciate ligament-deficient knees: a systematic review. Arthroscopy 2015; 31(3):507-519.
4. Stride D, Wang J, Horner NS, Alolabi B, Khanna V, Khan M. Indications and outcomes of simultaneous high tibial osteotomy and ACL reconstruction; Knee Surg Sports Traumatol Arthrosc. 2019 Apr;27(4):1320-1331.
5. Jin C, Song EK, Jin QH, Lee NH, Seon JK. Outcomes of simultaneous high tibial osteotomy and anterior cruciate ligament reconstruction in anterior cruciate ligament deficient knee with osteoarthritis; BMC Musculoskelet Disord. 2018 Jul 18;19(1):228.
6. Shuster P, Schulz M, Richter J. Combined biplanar high tibial osteotomy, anterior cruciate ligament reconstruction, and abrasion/microfracture in severe medial osteoarthritis of unstable varus knees. Arthroscopy2016;32(2):283-92.
7. Stoffel K, Willers C, Korshid O, Kuster M. Patellofemoral contact pressure following high tibial osteotomy: a cadaveric study; Knee Surg Sports Traumatol Arthrosc. 2007 Sep;15(9):1094-1100.
8. Tanaka T, Matsushita T, Miyaji N, Ibaraki K, Nishida K, Oka S, Araki D, Kanzaki N, Hoshino Y, Matsumoto T, Kuroda R. Deterioration of patellofemoral cartilage status after medial open-wedge high tibial osteotomy. Knee Surg Sports Traumatol Arthrosc. 2019 Apr;27(4):1347-1354.
9. Horikawa T, Kubota K, Hara S, Akasaki Y. Distal tuberosity osteotomy in open-wedge high tibial osteotomy does not exacerbate patellofemoral osteoarthritis on arthroscopic evaluation; Knee Surg Sports Traumatol Arthrosc. 2019 Jun 28(6):1750-1756.
10. Gaasbeek RD, Sonneveld H, van Heerwaarden RJ, Jacobs WC, Wymenga AB Distal tuberosity osteotomy in open wedge high tibial osteotomy can prevent patella infera: a new technique. Knee. 2004 11(6):457–461

11. Ogawa H, Matsumoto K, Yoshioka H, Sengoku M, Akiyama H. Distal tibial tubercle osteotomy is superior to the proximal one for progression of patellofemoral osteoarthritis in medial opening wedge high tibial osteotomy. Knee Surg Sports Traumatol Arthrosc. 2020 Oct;28(10):3270-3278.
12. Akiyama T, Osano K, Mizu-Uchi H, Nakamura N, Okazaki K, Nakayama H, Takeuchi R. Distal Tibial Tuberosity Arc Osteotomy in Open-Wedge Proximal Tibial Osteotomy to Prevent Patella Infra. Arthrosc Tech. 2019 Jun 2;8(6):e655-e662.
13. Gaasbeek RD, Sonneveld H, van Heerwaarden RJ, Jacobs WC, Wymenga AB Distal tuberosity osteotomy in open wedge high tibial osteotomy can prevent patella infera: a new technique. Knee. 2004 11(6):457–461
14. Takeuchi R, Ishikawa H, Aratake M, Bito H, Saito I, Kumagai K, Akamatsu Y, Saito T. Medial opening wedge high tibial osteotomy with early full weight bearing. Arthroscopy.2009 Jan;25(1):46-53.
15. Mehl J Paul J, Feucht MJ, Bode G, Imhoff AB, Südkamp NP, Hinterwimmer S. ACL deficiency and varus osteoarthritis: high tibial osteotomy alone or combined with ACL reconstruction? Arch Orthop Trauma Surg. 2017 Feb;137(2):233-240.
16. Schuster P, Geßlein M, Schlumberger M, Mayer P, Richter J. The influence of tibial slope on the graft in combined high tibial osteotomy and anterior cruciate ligament reconstruction. Knee. 2018 Aug;25(4):682-691.
17. Dickschas J, Strobel MJ, Weiler A, Lobenhoffer P, Simon MZ. Tibial slope correction as an infratuberosity closing-wedge extension osteotomy in ACL-deficient knees. Orthop Unfall. 2020 Oct;158(5):532-533.
18. Takeuchi R, Ishikawa H, Miyasaka Y, Sasaki Y, Kuniya T, Tsukahara S. A novel closed-wedge high tibial osteotomy procedure to treat osteoarthritis of the knee: Hybrid technique and rehabilitation measures. Arthrosc Tech. 2014 Jul 7;3(4):e431-e437.

Figures

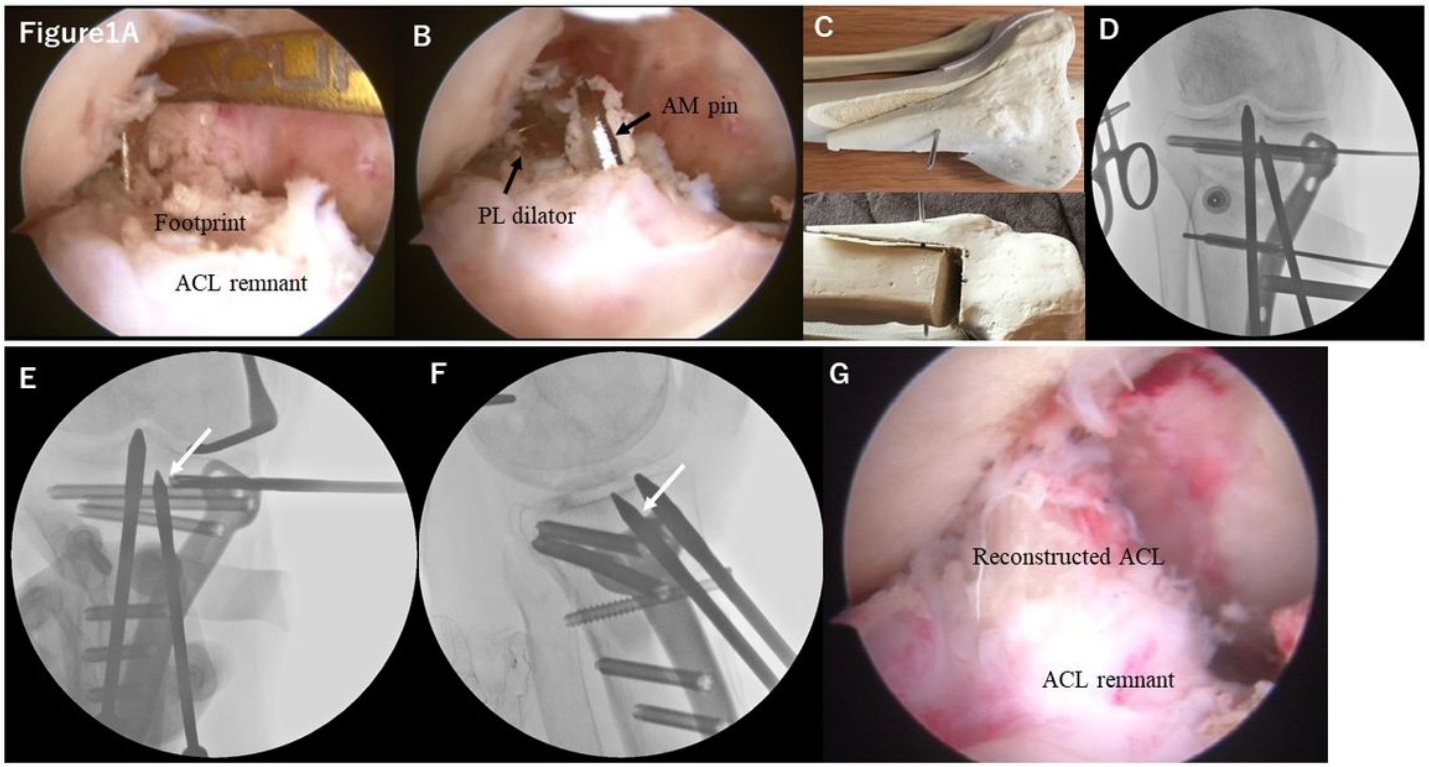

Figure 1

Case of simultaneous 6° correction by performing OWDTO and DBACLR (case 1, right knee of a 49-year-old woman).

(A) (B) The tibial tunnels were created in the footprint. (C) Bone model of OWDTO. Based on the bone model, biplane osteotomy was performed, leaving the tibial tuberosity in the distal fragment. (D) (E) (F) Intraoperative fluoroscopy findings. While drilling for the proximal front-screw of the plate, the drill was found to interfere with the dilator in the tibial PL tunnel, and a short screw was inserted (white arrows). (G) ACL was reconstructed using the double-bundle technique.

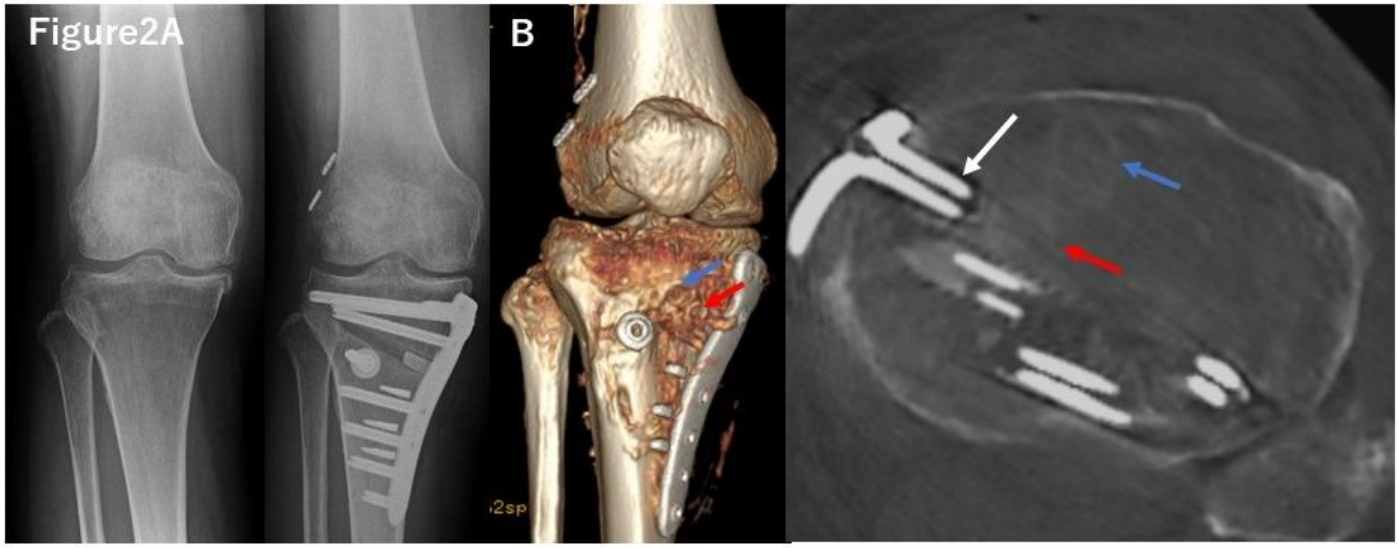

Figure 2

(A) Pre- and postoperative plane radiography and (B) postoperative 3-dimensional computed tomography (CT) and axial slice CT scan in case 1.

A short fixation screw was required for the proximal front-hole of the plate (white arrow) to prevent interference with the tibial PL tunnel (key: blue arrow, tibial tunnel for the AMB; red arrow, tibial tunnel for the PLB).

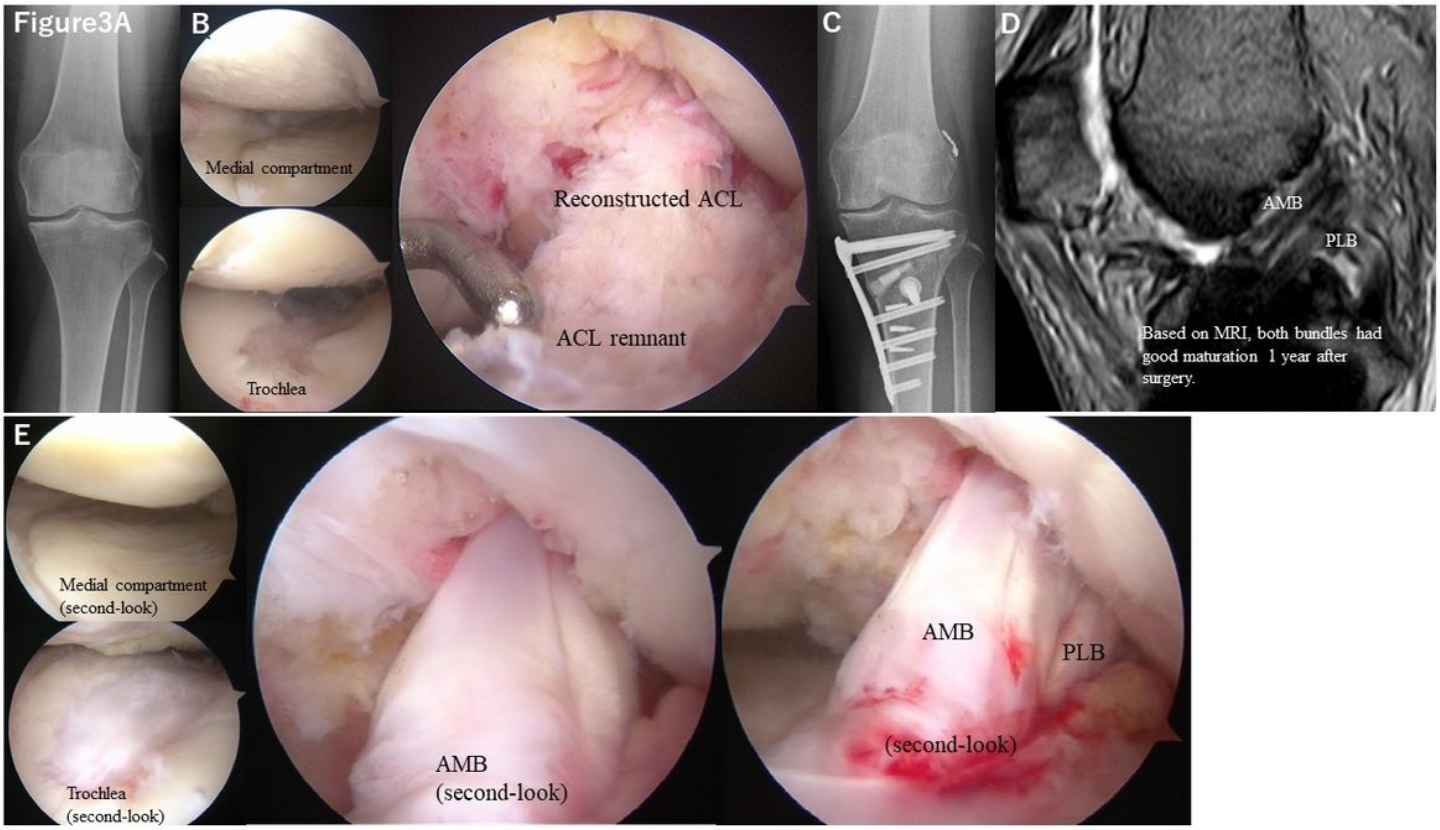

Figure 3

Postoperative course of simultaneous 7° correction OWDTO and DBACLR (case 2, left knee of a 50-year-old woman).

Preoperative plane radiography. (B) Intraoperative arthroscopic findings. ICRS grade 2 cartilage damage was observed in the medial femoral condyle and grade 4 in the posterior part of the medial tibial plateau and the femoral trochlea. (C) Plane radiography performed 5 months after surgery. Gap filling was almost completed. (D) T2-weighted sagittal imaging performed 1 year after surgery. Maturated two bundles were identified. (E) Second-look arthroscopic findings. One year after surgery, second-look arthroscopy was performed. The damaged cartilage in the medial compartment and the femoral trochlea was also repaired. Maturation and tension of both the bundles were excellent. Final follow-up was performed 2 years postoperatively; Lachman test and the pivot shift test became negative. The anterior drawer, which was evaluated using a measuring device at maximal manual force, improved from 12 to 7 mm. The WBL was transferred from 34% to 64% from the edge of the medial plateau. Scores on the Knee Injury and Osteoarthritis Outcome Score scale assessed preoperatively (Symptom57.1, Pain38.9, ADL64.7, Sports35, QOL18.8) were improved in all parameters (Symptom92.9, Pain72.2, ADL94.1, Sports80, QOL75) at the final follow-up.