Reliability study of measuring leg length discrepancy in patients with total hip arthroplasty using the tip of the greater trochanter

Yufeng Lu
Honghui Hospital,Xi'an Jiaotong University https://orcid.org/0000-0003-4527-0760

Xuechao Yuan
Shaanxi University of Chinese Medicine

Peng Xu
Honghui Hospital,Xi'an Jiaotong University

Yangquan Hao (haoyq2008@yahoo.com)

Research article

Keywords: total hip arthroplasty, leg length discrepancy, greater trochanter, inter-teardrop line

Posted Date: March 13th, 2020

DOI: https://doi.org/10.21203/rs.3.rs-17056/v1

Abstract

Background

Although the tip of the greater trochanter is widely used in THA to adjust leg length discrepancy (LLD), its accuracy and reliability are still unknown. The aim of this study was to investigate the reliability of measuring LLD in patients with total hip arthroplasty using the distance from the tip of the greater trochanter to the inter-teardrop line

Methods

128 patients who underwent THA in our department with preoperative and postoperative bilateral hips anteroposterior(AP) radiographs were reviewed. The distance between the bilateral anterior superior iliac spine and the medial malleolus (ASIS-MM) was measured before and after the operation. The distances from the vertex of the lesser trochanter to the bi-ischial line(LT-BI), the distance from the vertex of the lesser trochanter to the inter-teardrop line(LT-IT) and the distance from the tip of greater trochanter to the inter-teardrop line(GT-IT) were measured on the bilateral hips AP radiograph preoperatively and postoperatively. Taking X-ray magnification into account when measuring data. Use one-way ANOVA and paired t test to compare the differences between the four methods. The agreements between the four methods was evaluated using Bland-Altman analysis.

Results

There was no statistical difference between the four methods. Comparing GT-IT with MM-ASIS, ,LT-IT and LT-BI, the preoperative P values were 0.369, 0.581, and 0.402, and the postoperative P values were 0.755, 0.502 and 0.233. Comparing LT-BI with MM-ASIS and LT-IT, the P values were 0.151 and 0.372 preoperatively, and 0.179 and 0.917 postoperatively. Comparing LT-IT with MM-ASIS, the P value was 0.924 before surgery and 0.291 after surgery. Bland-Altman indicated that there were good agreements between GT-IT and LT-IT.

Conclusion

It is highly reliable to evaluate the LLD of patients with THA by using the difference in the distance between the tip of the greater trochanter and the inter-teardrop line.

Background

Leg length discrepancy (LLD) caused by total hip arthroplasty can produce a variety of complications, such as sciatic nerve paralysis [1], gait abnormality [1, 2], hip -spine syndrome [1], and recurrent hip dislocations [3]. Therefore, the difference in the length of the lower limbs should be fully evaluated before surgery in order to properly balance the length of the lower limbs during surgery. There are currently many methods to evaluate the difference in the length of the lower limbs, such as physical measurement of the length of the lower limbs, X-ray measurement, length balance of the lower limbs with the heel pad, etc. At

present, the most commonly used method in clinical practice is to measure the distance from the vertex of the lesser trochanter to the bi-ischial line or the distance from the vertex of the lesser trochanter to the inter-teardrop line on anteroposterior pelvic or bilateral hip joints radiograph. The difference in bilateral distance is considered to be LLD of both lower limbs [4]. This study evaluated the LLD by measuring the distance between the tip of the greater trochanter and the inter-teardrop line on the anteroposterior radiograph of both hips, and compared this method with the methods commonly used in the literature to evaluate its reliability.

Materials And Methods

As per Altman nomogram, using a standardized difference of 0.5 with a power of 80% and a P-value of 0.05 the sample size required for this study was 128. We measured the patients who needed to undergo total hip replacement in the osteonecrosis and joint reconstruction ward of Xi'an Honghui Hospital from August 2015 to March 2016.

AP radiographic views of the pelvis were obtained in the same radiology unit based on a routine protocol at a standard distance of 1 m and centered 2 cm above the pubic symphysis. The patients were placed in supine position with their feet rotated internally 15° to maintain neutral hip position. The sizes of the lesser trochanters were similar and the anterior and posterior borders of the greater trochanters were superimposed on both sides [5]. The coccyx was in line with the pubic symphysis to prevent pelvic rotation in the transverse plane[6]. The distance between the sacrococcygeal joint and the pubic symphysis was 1–4 cm in men and 4–6 cm in women to exclude abnormal pelvic tilting in the sagittal plane[6, 7]. Exclusion criteria: 1. Unclear teardrops; 2. Pelvic rotation or tilt; 3. Hip flexion contracture before or after surgery, cannot be straightened; 4. Other diseases of the lower limbs lead to shortening of the limbs or knee disease resulting in knee joints varus, valgus or flexion contracture deformity.

The following measures are given to eligible patients after admission:

Use a medical tape to measure the distance from the left and right anterior superior iliac spine(ASIS) to the ipsilateral medial malleolus(MM).

Use the marker on AP radiograph of the bilateral hip joint to mark the following (Figs. 1 and 2).1. Bilateral tip of the greater trochanter(GT); 2. Teardrop inferior edge line (inter-teardrop line, IT); 3. Ischia tuberosity line (bi-ischial line, BI); 4. Vertex of the lesser trochanter(LT).

Made perpendicular lines from GT to IT, and draw lines from LT to IT and BI, and measured the length of each vertical segment. Calculated the difference between the left and right sides, and the data were divided into 4 groups, the difference between GT to IT formed GT-IT group, the difference between ASIS to MM formed ASIS-MM group, the difference between LT to IT formed LT-IT group, and the difference between LT to BI formed LT-BI group. The postoperative radiograph measurement ÷ magnification1 was the actual value, and the preoperative radiograph measurement ÷ magnification 2 was the actual value. The difference in the length of the bilateral vertical line segments can be considered as LLD.

$$\text{Magnification1} = \frac{\text{Measured mediolateral dimension of the acetabular component on radiograph}}{\text{True mediolateral dimension of the acetabular component}}$$

$$\text{Magnification2} = \frac{\text{Preoperative distance between teardrops}}{\text{Postoperative distance between teardrops}} \times \text{Magnification1}$$

Thus, 128 patients were involved in the study, including 69 females and 59 males. The mean age at the time of index arthroplasty was 56.1 ± 11 years (range 26–77 years). All operations were performed by four senior authors through a posterolateral approach.

Institutional review board approval was obtained. The preoperative diagnoses in these patients included femoral neck fractures (15 cases), osteonecrosis of the femoral head (64 cases), developmental hip dysplasia (16 cases), THA revision due to aseptic loosening (five cases), primary osteoarthritis (23 cases), rheumatoid arthritis (four cases), and ankylosing spondylitis (one cases). All implants were cementless: 68 Trilogy IT (Zimmer, USA), 52 Reflection SP3 (Smith & Nephew, USA), six CombiCup PF (LINK, Germany), and two Zuanshi(IRENE, China). A total of 41 cases had ceramic-on-ceramic bearing surfaces, 39 had ceramicon-polyethylene bearing surfaces, 29Oxinium-polyethylene bearing surfaces, and 19 had metal-on-polyethylene bearing surfaces.

To determine intra- and interobserver variability, 20 randomly selected patients were measured initially by Observer I(Lu) and Observer II(Yuan). After 3 weeks the radiographs were measured again by the same authors except physical measurements. An intraclass correlation coeffcient (ICC) > 0.8 was considered excellent agreement, ICC 0.6–0.8 was fair to good agreement, and ICC < 0.6 was poor agreement.

Statistical analysis

Quantitative data are expressed as means ± standard deviation (SD). Statistical analyses were performed using PASW statistics 18 (SPSS Inc., Chicago, IL, USA). The normality assumption of our data was checked using the Kolmogorov-Smirnov test. The One-way ANOVA test and paired t test were used to detect the measurements of LLD of the lower limbs between GT-IT group and the other three groups. The Bland-Altman diagram was used to check the agreement of the four measurements. $P < 0.05$ was considered statistically significant.

Results

All measurements were normally distributed. The ICC values of the four groups were all greater than 0.80, which showed excellent agreement in the measurements (Table 1).

Table 1 Intraobserver and interobserver agreement in radiographic measurements

Error	Intraobserver I reliability	Intra-observer II reliability	Inter-observer reliability
GT-IT	0.96	0.94	0.92
LT-IT	0.94	0.93	0.91
LT-BI	0.91	0.93	0.89
ASIS-MM	—	—	0.82

The results of the four pre- and post-operative measurements are shown in Table 2.

Table 2 LLD measurements of four methods

		Mean ± SD（mm）	95% confidence interval
GT-IT	Preoperative	0.40±12.7	-1.7-2.6
	Postoperative	-0.4±9.0	-2.0～1.0
ASIS-MM	Preoperative	-0.8±12.0	-2.7-1.2
	Postoperative	-0.7±8.9	-2.3～0.6
LT-IT	Preoperative	-0.6±12.2	-2.8-1.4
	Postoperative	0.4±7.7	-0.8-1.6
LT-BI	Preoperative	1.0±11.4	-0.9-3.0
	Postoperative	0.5±8.0	-0.8-1.9

One-way ANOVA analysis showed, there were no statistically significant difference between the LLDs of the four groups preoperatively and postoperatively ($F = 0.748, 0.768$，both $P > 0.05$). There were no significant difference in preoperative LLD in comparing group GT-IT with group ASIS-MM, LT-IT and LT-BI ($t = -0.902, 0.554, -0.84$，all $P > 0.05$). And there were also no significant difference in postoperative LLD in comparing group GT-IT with group ASIS-MM, LT-IT and LT-BI ($t = -0.312, -0.674, -1.198$，all $P > 0.05$). Moreover, no significant difference was found in LLD between group LT-BI, ASIS-MM and LT-IT both preoperatively and postoperatively ($t = -1.446$～-0.897～$-1.350, -0.104$, all $P > 0.05$). And there was no significant difference in LLD between group LT-IT and ASIS-MM preoperatively and postoperatively($t = -0.096$～-1.059，both $P > 0.05$).

Bland-Altman analysis indicated that the means bias close to 0 mm between GT-IT and the other measurements(Fig. 3A-F), SD between GT-IT and LT-IT was significantly smaller than the standard deviation between GT-IT and other groups, and it has the smallest limits of agreement(LoA) which were

preoperative – 13.04 and 12.59(Fig. 3B), and postoperative – 15 and 14.84(Fig. 3E). We set the clinical LoA of -10 mm to 10 mm. It was suggested that 87.5% and 83.5% of the measurements are within clinical LoA before and after surgery. The measurements between GT-IT and the other two methods within LoA are less than 80%.

Discussion

Many studies believe that the complications increases significantly when the LLD was greater than 1 cm after THA, so it is recommended that LLD should be less than 1cm[8]. In order to prevent LLD, it is important to correctly measure the length of the lower limbs before surgery. Measurement on radiograph of the pelvis or bilateral hip joints is one of the most commonly used methods for assessing the length of the lower limbs. Standardized AP radiograph of the pelvis or bilateral hip joints were mainly used, the pelvic side use the ischia tuberosity line or the inter-teardrop line as references[9, 10], and the femoral side use the lesser trochanter[9, 10]. The difference between the distance from the vertex of the lesser trochanter to the inter-teardrop line or the vertex of the lesser trochanter to the bi-ischial line can be defined as LLD. It was also reported using the center and the higher point [11] of the femoral head as a reference to the femoral side. However, the reliability of these methods were not yet consistent. At present, the distance from the vertex of the lesser trochanter to the inter-teardrop line is considered to be more accurate than the distance from the vertex of the lesser trochanter to the ischial tuberosity line [4, 10, 12], because the inter-teardrop line is more stable on the AP pelvic X-ray than the ischial tuberosity line, and was less affected by body position, and it is even better than the physical measurement of the distance from the anterior superior iliac spine to the medial malleolus. Meermans et al. [4] found that using the distance from the center of the femoral head to the vertex of the lesser trochanter to evaluate LLD was also a reliable method.

There are few studies in the literature that use the tip of the greater trochanter to measure LLD. This study used the tip of the greater trochanter as a marker of femur to measure lower limb length in 128 patients with total hip arthroplasty. Comparison of the method with two X-ray measurement methods and physical measurement method commonly used in the literature, Paired t test showed no statistically significant difference. However, paired t test is mainly to compare the difference of the mean, sensitive to systematic errors and less sensitive to random errors. The Bland-Altman method combines quantitative analysis and qualitative analysis. When evaluating agreement, it takes into account both random errors and the impact of systematic errors on agreement. At the same time, it can be judged based on clinical significance. Therefore, we used Bland-Altman analysis to check consistency between GT-IT and the other 3 methods, and it was founded that they have high consistency, especially between GT-IT and IT-LT.

There are some advantages to measuring LLD with the tip of the greater trochanter. First, the tip of the greater trochanter is an important anatomical landmark for total hip replacement, and it is easy to identify during surgery. Many authors use the method that the tip of the greater trochanter is flush with the center of the femoral head to adjust the LLD during THA. Therefore, it has an important role in adjusting the length of the lower limbs during the operation. Second, the lower edge of the teardrop is an

important anatomical marker for positioning the acetabular component. Studies have shown that flushing the lower edge of the acetabular component with the lower edge of the teardrop can largely restore the anatomical center of rotation of the acetabulum [13]. Therefore, using this method to measure LLD can not only be used to evaluate the difference in the length of the lower limbs before and after surgery, and to guide the preoperative template, but also to directly adjust the length of the limbs using this marker during the operation.

The shortcomings of this study are: 1. The sample size is small and only 128 patients are selected; 2. Due to the limitations of the hospital, the measurement method is manual measurement, X-ray measurement was accurate to millimeters, and physical measurement was only accurate to 5 mm; 3. This study was not a typical prospective study, and no blind method was used. The researchers participated in the design and research. Therefore, it is still necessary to further use large samples, digital measurement, and strict use of blind research to further improve the accuracy and reliability of the research.

In conclusion, this study calculated the LLD of patients by measuring the difference in distance between the tip of the bilateral trochanter and the inter-teardrop line on a standard AP radiograph of bilateral hip radiograph. The results showed high reliability and accuracy for preoperative and postoperative LLD evaluation of patients with total hip arthroplasty.

Abbreviations

AP: anteroposterior; ASIS: anterior superior iliac spine; BI: bi-ischial line; GT: tip of greater trochanter; IT: inter-teardrop line; LLD: leg length discrepancy; LoA: limits of agreement; LT: vertex of lesser trochanter; MM: medial malleolus; THA: total hip arthroplasty.

Declarations

Ethics approval and consent to participate

The ethical approval was obtained from the Institutional Review Board (IRB) (IRB-2015-043) at Honghui Hospital, Xi’an Jiaotong University. The participants provided their written informed consent to undergo the study and to have their data used in the study.

Consent to publish

The participants in this study provided their written informed consent to undergo the study and to have their data used in the study.

Availability of data and materials

The datasets used and/or analyzed during the current study are available from the corresponding authors on reasonable request.

Competing interests

The authors declare that they have no competing interests.

Funding

This study was supported by a grant from Shaanxi Provincial Key Research and Development Project (CN) (grant no. 2019SF-214) and Xi'an Health Scientific Research Talent Project(CN) (grant no. J201903058). The authors have no conflicts of interest to declare.

Author Contribution

Yufeng Lu: Data management, analysis and manuscript writing

Xuechao Yuan: Data collection

Peng Xu: Protocol development

Yangquan Hao Protocol and project development

All authors have read and approved the manuscript.

References

1. Clark CR, Huddleston HD, Schoch EP 3rd, Thomas BJ. Leg-length discrepancy after total hip arthroplasty. J Am Acad Orthop Surg. 2006;14(1):38–45.
2. Goodman SB, Adler SJ, Fyhrie DP, Schurman DJ. The acetabular teardrop and its relevance to acetabular migration. Clin Orthop Relat Res. 1988;(236):199–204.
3. Kayani B, Pietrzak J, Donaldson MJ, Konan S, Haddad FS. Treatment of limb length discrepancy following total hip arthroplasty. Br J Hosp Med (Lond). 2017;78(11):633–637.
4. Krishnan SP, Carrington RW, Mohiyaddin S, Garlick N. Common misconceptions of normal hip joint relations on pelvic radiographs. J Arthroplasty. 2006;21(3):409–412.
5. Li J, McWilliams AB, Jin Z, et al. Unilateral total hip replacement patients with symptomatic leg length inequality have abnormal hip biomechanics during walking. Clin Biomech (Bristol, Avon). 2015;30(5):513–519.
6. Lu Y, Cheng L, Guo W, et al. Ability of lower teardrop edge to restore anatomical hip center height in total hip arthroplasty. Chin Med J (Engl). 2014;127(22):3915–3920.
7. Mast NH, Impellizzeri F, Keller S, Leunig M. Reliability and agreement of measures used in radiographic evaluation of the adult hip. Clin Orthop Relat Res. 2011;469(1):188–199.
8. McWilliams AB, Grainger AJ, O'Connor PJ, Redmond AC, Stewart TD, Stone MH. A review of symptomatic leg length inequality following total hip arthroplasty. Hip Int. 2013;23(1):6–14.

9. Meermans G, Malik A, Witt J, Haddad F. Preoperative radiographic assessment of limb-length discrepancy in total hip arthroplasty. Clin Orthop Relat Res. 2011;469(6):1677–1682.
10. Reina-Bueno M, Lafuente-Sotillos G, Castillo-Lopez JM, Gomez-Aguilar E, Munuera-Martinez PV. Radiographic Assessment of Lower-Limb Discrepancy. J Am Podiatr Med Assoc. 2017;107(5):393–398.
11. Sculco PK, Austin MS, Lavernia CJ, Rosenberg AG, Sierra RJ. Preventing Leg Length Discrepancy and Instability After Total Hip Arthroplasty. Instr Course Lect. 2016;65:225–241.
12. Siebenrock KA, Kalbermatten DF, Ganz R. Effect of pelvic tilt on acetabular retroversion: a study of pelves from cadavers. Clin Orthop Relat Res. 2003;(407):241–248.
13. Tannast M, Zheng G, Anderegg C, et al. Tilt and rotation correction of acetabular version on pelvic radiographs. Clin Orthop Relat Res. 2005;438:182–190.
14. Woolson ST, Hartford JM, Sawyer A. Results of a method of leg-length equalization for patients undergoing primary total hip replacement. J Arthroplasty. 1999;14(2):159–164.

Figures

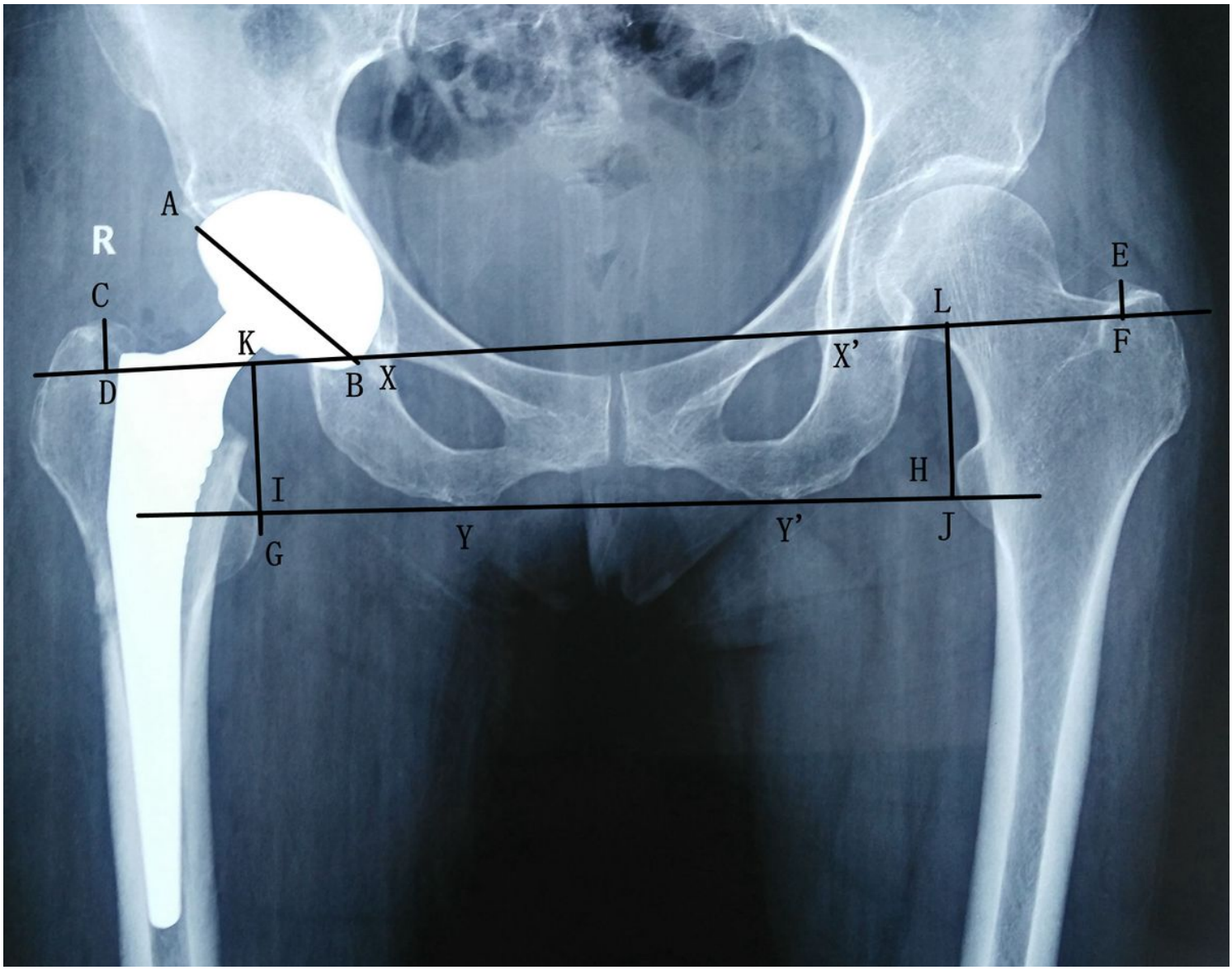

Figure 1

Postoperative AP radiograph of bilateral hip joint. AB is the outer diameter of the acetabular component, line XX'is the inter-teardrop line, line YY' is the ischial tuberosity line, and C and E are the tips of the right and left greater trochanter, respectively. G, H are the vertexes of the right and left lesser trochanter, respectively. CD and EF are the perpendicular to the line XX' and represents the distance from the tips of the right and left greater trochanter to the inter-teardrop line(GT-IT). GK and HL are the perpendicular to the line XX' and represents the distance from the vertexes of the right and left lesser trochanter to the inter-teardrop line(LT-IT). And IG and JH are the perpendicular to the line YY' and represents the distance from the vertexes of the right and left lesser trochanter to the bi-ischial line(LT-BI). The measured value of LT-BI is positive when the vertex of the lesser trochanter is above the ischial tuberosity line, otherwise it is negative. All other measurements are positive.

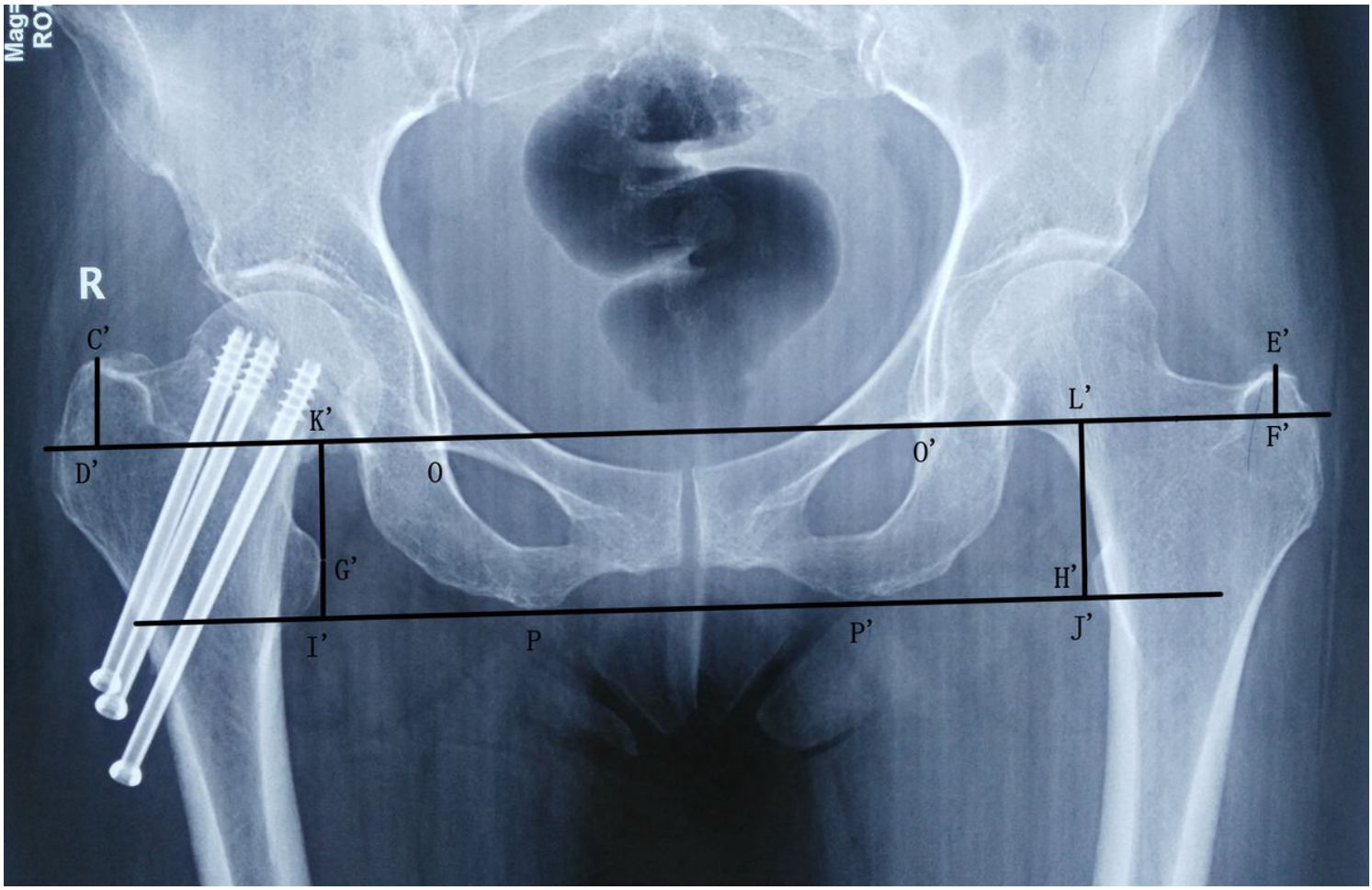

Figure 3

Preoperative AP radiograph of bilateral hip joint. line OO'is the inter-teardrop line, line PP' is the ischial tuberosity line, and C' and E' are the tips of the right and left greater trochanter, respectively. G', H' are the vertexes of the right and left lesser trochanter, respectively. C'D' and E'F' are the perpendicular to the line OO' and represents GT-IT. G'K' and H'L'are the perpendicular to the line OO' and represents LT-IT. And G'I' and H'J' are the perpendicular to the line YY' and represents LT-BI.

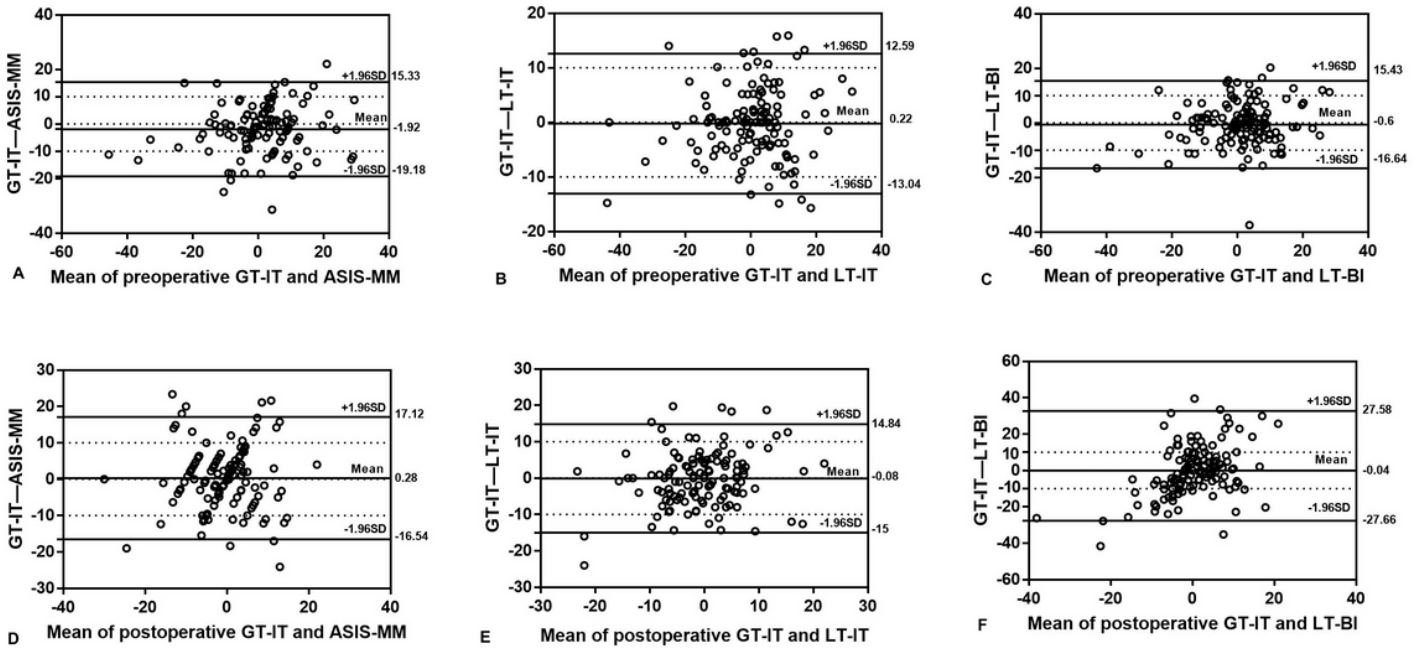

Figure 5

Bland-Altman plots illustrating the agreements A) between preoperative GT-IT and ASIS-MM , B) between preoperative GT-IT and LT-IT, C) between preoperative GT-IT and LT-BI, and D) between postoperative GT-IT and ASIS-MM, E) between postoperative GT-IT and LT-IT, F) between postoperative GT-IT and LT-BI, in mm.