Influence of ILM peeling on macular blood flow in patients with diabetic epiretinal membrane

Bo Li
Suining Central Hospital
Wenjun Gou
Suining Central Hospital
Hui You
Suining Central Hospital
Mengtian Bai
Suining Central Hospital
Chen Xie
Suining Central Hospital
Heng Li (liheng1_10@163.com)
Suining Central Hospital

Research Article

Keywords: Diabetes, Epiretinal membrane, Inner limiting membrane, vessel density , vessel length density

Posted Date: June 22nd, 2022

DOI: https://doi.org/10.21203/rs.3.rs-1718865/v1

Abstract

Background

To study the effect of intraoperative internal limiting membrane(ILM)peeling on the macular vascular structure in patients with diabetic epiretinal membrane (ERM).

Methods

Patients with diabetic ERM were divided into an ERM + ILM peeling group (18 eyes) and an ERM peeling group (19 eyes), all of whom underwent standard vitrectomy and were followed up until 6 months postoperatively. Best-corrected visual acuity(BCVA), Central macular thickness (CMT), Vessel density (VD) and vessel length density (VLD) of the superficial as well as deep retinal capillary plexus were compared between the two groups.

Results

There was no significant difference in BCVA ($P > 0.05$) and CMT ($P > 0.05$) between the two groups. In the superficial capillary plexus (SCP), the change in VD ($p = 0.106$) and VLD ($p = 0.438$) was not affected by peeling the ILM, and there was no significant difference in VD ($p = 0.162$) and VLD ($p = 0.391$) between the two groups at month 6. For the deep capillary plexus (DCP), there was an effect of ILM peeling on the changes in VD ($p = 0.024$) and VLD ($p = 0.012$); peeling of the ILM delayed the recovery time of the VD and VLD, and the VD ($p = 0.003$) and VLD ($p = 0.000$)in the ERM + ILM peeling group at postoperative month 6 were lower than those in the ERM peeling group.

Conclusion

Intraoperative peeling of the ILM in patients with diabetic ERM delayed the improvement of blood flow signal in the DCP but did not affect the recovery of postoperative BCVA and CMT.

Background

Epiretinal membrane (ERM) is a nonvascularized fibrous cell tissue formed by the chemotaxis and proliferation of cells at the vitreous-retinal junction, with a prevalence of approximately 7–11.8%; patients are mostly over 50 years of age [1–2]. ERMs can cause structural disorders of the retina, vascular leakage, retinal fissures and even retinal detachment, causing clinical symptoms such as loss of visual acuity and visual distortion in patients, and in severe cases, visual function cannot be restored [3]. According to the different pathogeneses, ERMs are divided into idiopathic and secondary types. For idiopathic ERM, posterior vitreous detachment and rupture of the internal limiting membrane(ILM)are the main pathogenic causes [4]. In contrast, secondary ERM is more often associated with intraocular

inflammation and/or retinal ischaemia, resulting in a large number of inflammatory factors in the vitreous cavity, such as nestin, nuclear protein Ki-67, and highly glycosylated type I transmembrane glycoproteins; in addition, the expression of cytokines such as interleukin-6 and 8 and monocyte chemotactic protein-1 is increased in the ERM compared to the idiopathic ERM [5–6]. Diabetic retinopathy is an important cause of secondary ERM [7].

The treatment of both idiopathic and secondary ERM is based on surgery, but whether to combine the peeling of the ILM intraoperatively has been controversial. Some scholars believe that the combination of ILM elimination during ERM peeling can ensure complete removal of the anterior membrane and thus reduce the recurrence rate [8]. However, some studies have found that in diabetic ERM, ILM peeling does not reduce the recurrence rate, and even if the ERM recurs, it does not affect the patient's visual acuity [9]. Intraoperative ILM peeling in diabetic ERM leads to increased glial fibrillary acidic protein (GFAP) secretion, which aggravates the intraoperative and postoperative inflammatory response; at the same time, ILM peeling causes mechanical damage to the retina, which may cause deep structural changes and retinal cystoid oedema, in turn affecting the long-term visual quality of patients [10–12]. Compared with idiopathic ERM, the deep avascular area of the macula is enlarged after ILM peeling in diabetic ERM [13].However, there are few studies on the changes of blood flow signals.

Optical coherence tomography angiography (OCT-A) allows detailed observation of the retinal vascular plexus, permitting us to compare changes in the blood flow signal before and after diabetic ERM surgery [14–15]. In our study, we used OCT-A to observe the effect of the ILM peeling on the retinal blood flow signal in the macula in diabetic ERM patients at the vascular level to provide a clinical reference for the treatment of diabetic ERM.

Methods

Patients

Medical records of a total of 37 eyes of 36 patients who visited our hospital and received surgical treatment by the same surgeon from November 2020 to September 2021 were analysed. Systemic medical histories, such as hypertension, cerebral infarction, and heart disease, were excluded, as well as ocular medical histories, such as retinal vascular obstruction, macular fissure, history of previous vitreous surgery, and history of previous vitreous cavity anti-VEGF drug injections. Patients were 47–68 years old, of either sex, with usually good glycaemic control and a degree of lens clouding that did not affect the surgery. All patients were diagnosed with non-proliferative diabetic ERM after fundus angiography and macular OCT. The ectopic inner foveal layer was below stage 2 with an intact ellipsoidal band, and the indications for surgery were LogMAR BCVA greater than 0.3 and/or visual distortion.

Surgery

Patients were randomized to the ERM + ILM peeling group (18 eyes) and the ERM peeling group (19 eyes), and the procedures were performed by the same surgeon, who had more than 10 years of experience in vitrectomy surgery. Using a 25G vitrectomy device (Alcon Co., Ltd. Huremberg, Switzerland), a standard 3-channel procedure was performed. For the ERM + ILM peeling group, a 27-gauge blunt needle was used to administer a drop of the configured (20% dextrose injection 4 ml + sterilized water for injection 6 ml + indocyanine green for injection 25 mg) indocyanine green stain for injection (Dandongyichuang Co., Ltd. Donggang, China) above the posterior pole so that the stain completely covered the macular area and then was slowly peeled off the ERM and the ILM with forceps. The peeling range was as follows: nasal side near the optic papilla, temporal side to 2DD-3DD outside the central macular recess, and upper and lower to the vascular arch (Fig. 1A). In the ERM peeling group, a drop of triamcinolone acetonide injection (Jida Co., Ltd. Kunming, China) was dropped above the posterior pole using a 27-gauge blunt needle, and the ERM was peeled in the same way (Fig. 1B). Some patients had intraoperative local retinal traction due to tight adhesion of the ERM, the vitreous cavity was filled with filtered sterile air after surgery, and the patients were instructed to rest in the prone position for 3–5 days after surgery. No iatrogenic retinal tears were produced intraoperatively, and intraoperative retinal haemorrhage did not affect the surgical operation.

Data collection

The ectopic intraocular layer grade and the integrity of the ellipsoidal band were identified using optical coherence tomography [16]. BCVA was determined using the Snellen visual acuity chart, and the Snellen visual acuity was converted to the logarithm of the angle of minimum resolution (logMAR). The presence or absence of dysmorphopsia was first determined by the patient's subjective perception and then verified using the M-CHARTS table. OCT-A (Carl Zeiss Co., Ltd. Oberkochen, Germany) was used to acquire the retinal blood flow in a 6*6 mm area centred on the fovea of the patient, and FastTrac image tracking software was used to reduce the signal noise generated by eye movements. The target images were opened in ImageJ v1.8 software (National Institutes of Health, USA), the Vessel J plug-in was imported into the software, and the images acquired by OCT-A were imported and converted to 8-bit format for analysis of vascular density (VD) [17].The target images were opened in AngioTool software, and the vessel length density (VLD) was analysed [18] (Fig. 2).

Statistical analysis

Statistical software SPSS 22.0 (IBM SPSS Inc., Chicago, IL, USA) was used. Data are expressed as the mean ± standard deviation (—x±s). The effect of peeling or non-peeling of the ILM on VD and VLD was analysed using two-factor repeated-measures ANOVA. Two-way comparisons of VD, VLD, BCVA, and MCT thickness were performed using the Mann–Whitney U test for data that did not satisfy a normal distribution and the t test for two independent samples for data that satisfied a normal distribution. GraphPad Prism 8 (GraphPad Software Inc., San Diego, USA) was used for data plotting.

Results

A total of 37 eyes of 36 patients were treated with vitrectomy, and there was no significant difference between the two groups in terms of baseline information (Table 1). (Relevant data is available at https://figshare.com/s/aa22c3d20a9ce3cda341)

Table 1
Clinical characteristics of the two groups of patients ± s

	Total	**ERM + ILM peeling**	**ERM peeling**	***p* between**
	(n = 37)	(n = 18)	(n = 19)	two groups
Male/Female	14/22	8/10	6/12	1.000
Age(years)	58.77 ± 6.00	59.64 ± 5.93	57.90 ± 6.11	0.394
BCVA(logMAR)	0.83 ± 0.20	0.80 ± 0.21	0.84 ± 0.18	0.292
SCP				
VD	0.55 ± 0.09	0.52 ± 0.11	0.57 ± 0.07	0.153
VLD	0.15 ± 0.03	0.15 ± 0.03	0.16 ± 0.03	0.759
DCP				
VD	0.58 ± 0.06	0.58 ± 0.06	0.58 ± 0.06	0.902
VLD	0.19 ± 0.03	0.19 ± 0.03	0.19 ± 0.02	0.847

BCVA gradually increased in both groups after surgery, with a statistically significant difference between the ERM + ILM peeling group (P = 0.001) and the ERM peeling group (P = 0.000) at 1 month postoperatively compared with preoperatively, there was no difference in BCVA between the two groups at 6 months postoperatively (P = 0.916). CMT gradually decreased in both groups after surgery, with a statistically significant difference between the ERM + ILM peeling group (P = 0.001) and the ERM peeling group (P = 0.000) at 1 month postoperatively compared with preoperatively, there was no difference in CMT between the two groups at 6 months postoperatively (P = 0.118) (Table 2). (Relevant data is available at https://figshare.com/s/aa22c3d20a9ce3cda341)

Table 2
BCVA and CMT before and after surgery in the two groups ± s

	Pre-operatin	Week 1	Month 1	Month 3	Month 6	*F*	*p*
BCVA							
ERM + ILM peeling group	0.80 ± 0.21	0.65 ± 0.24	0.55 ± 0.20	0.51 ± 0.20	0.50 ± 0.19	0.431	0.516
ERM peeling group	0.87 ± 0.18	0.75 ± 0.18	0.60 ± 0.18	0.50 ± 0.17	0.49 ± 0.16		
CMT							
ERM + ILM peeling group	420.83 ± 48.38	404.22 ± 47.13	379.11 ± 43.98	353.33 ± 36.83	322.06 ± 33.47	2.517	0.122
ERM peeling group	402.16 ± 36.09	384.63 ± 36.26	358.16 ± 37.58	334.05 ± 34.62	304.32 ± 31.34		
Peeling the inner limiting membrane had no effect on the changes of BCVA (p = 0.516) and CMT (p = 0.122) in the two groups							

For the superficial capillary plexus (SCP), ILM peeling did not make a difference in VD changes between the two groups (P = 0.106) (Table 3) (Relevant data is available at https://figshare.com/s/aa22c3d20a9ce3cda341); VD in both groups decreased after surgery and gradually rebounded with time (Fig. 3A). ILM peeling did not make a difference in VLD changes between the two groups (P = 0.438) (Table 3) (Relevant data is available at https://figshare.com/s/aa22c3d20a9ce3cda341); VLD in both groups decreased after surgery and gradually rebounded with time (Fig. 3B).

Table 3
VD and VLD before and after surgery in the two groups ± s

	Pre-operatin	Week 1	Month 1	Month 3	Month 6	*F*	*p*
VD of SCP							
ERM + ILM peeling group	0.52 ± 0.11	0.46 ± 0.10	0.47 ± 0.09	0.53 ± 0.08	0.59 ± 0.09	2.754	0.106
ERM peeling group	0.57 ± 0.07	0.50 ± 0.08	0.52 ± 0.07	0.57 ± 0.06	0.63 ± 0.05		
VLD of SCP							
ERM + ILM peeling group	0.15 ± 0.03	0.14 ± 0.03	0.14 ± 0.03	0.15 ± 0.03	0.16 ± 0.03	0.616	0.438
ERM peeling group	0.16 ± 0.03	0.15 ± 0.03	0.15 ± 0.03	0.16 ± 0.03	0.17 ± 0.03		
VD of DCP							
ERM + ILM peeling group	0.58 ± 0.06	0.54 ± 0.05	0.53 ± 0.05	0.52 ± 0.05	0.57 ± 0.05	5.595	0.024
ERM peeling group	0.58 ± 0.06	0.57 ± 0.06	0.57 ± 0.06	0.59 ± 0.05	0.62 ± 0.05		
VLD of DCP							
ERM + ILM peeling group	0.19 ± 0.03	0.17 ± 0.03	0.16 ± 0.03	0.16 ± 0.03	0.18 ± 0.03	6.995	0.012
ERM peeling group	0.19 ± 0.02	0.18 ± 0.02	0.18 ± 0.02	0.20 ± 0.02	0.21 ± 0.02		
In SCP, the peeling of the ILM has no effect on the changes of VD (p = 0.106) and VLD (p = 0.438).In DCP, the peeling of the ILM has an effect on the changes of VD (p = 0.024) and VLD (p = 0.012)							

In the deep capillary plexus (DCP), peeling of the ILM had an effect on the changes of VD in the two groups (P = 0.024), VD of the ERM + ILM peeling group was lower than that of the ERM peeling group at month 6 after surgery (Table 3). (Relevant data is available at https://figshare.com/s/aa22c3d20a9ce3cda341); VD in both groups decreased after operation, and then gradually rebounded, but the rebound time in the ERM + ILM peeling group was delayed compared with the ERM peeling group (P = 0.000) (Fig. 4A). The peeling of the ILM had an effect on the changes of VLD in the two groups (P = 0.012), VLD of the ERM + ILM peeling group was lower than that of the ERM peeling group at month 6(Table 3) (Relevant data is available at https://figshare.com/s/aa22c3d20a9ce3cda341); VLD decreased in both groups after surgery, and then gradually recovered, but the rebound in the ERM + ILM peeling group was delayed compared with the ERM peeling group (Fig. 4B).

Discussion

Transciliary pars plana vitrectomy combined with double membrane (ERM + ILM) peeling is currently the most common surgical procedure for the treatment of idiopathic ERM [19], but the necessity of peeling the ILM during secondary ERM surgery remains widely debated due to the different pathogeneses. Most current studies suggest that peeling the ILM causes partial microscopic effects on macular function but does not affect the recovery of final visual acuity. As OCT-A has been widely used in recent years to investigate retinal blood flow signals, we used OCT-A to observe the effect of diabetic ERM intraoperative peeling or non-peeling of the ILM on the VD and VLD of the SCP and DCP. In this study, data analysis of the acquired images was performed with the help of ImageJ and Anjio Toll software. After 6 months of follow-up, we found no difference in VD and VLD in terms of SCP between the two groups, which decreased in both groups in the first postoperative week and then gradually increased and exceeded the preoperative level. The two groups showed different trends in DCP, the ERM + ILM peeling group showing delayed recovery of VD and VLD compared to the ERM peeling group. The levels at postoperative month 6 were still lower than those preoperatively, while the ERM peeling group at postoperative month 6 had levels above those preoperatively. The BCVA in both groups gradually improved after surgery, and the difference was not statistically significant at month 6. The CMT gradually decreased after surgery in both groups, and the difference was not statistically significant at month 6.

The formation of the ERM exposes the macula to anterior-posterior forces and tangential forces, the anterior-posterior forces can lead to macular thickening, while tangential forces can cause vascular dislocation in macular area. Although ILM peeling ensures complete removal of the cortical vitreous and ERM, it has been shown that ILM peeling and intraoperative staining with indocyanine green decreases retinal sensitivity [20]. We found by OCT-A, like idiopathic ERM, the blood flow signals of the SCP and DCP are also altered after surgery in the diabetic ERM [21]. Levels of VD and VLD reflect the supply of the retinal blood supply, so their changes cause subsequent changes in retinal function and structure. In both the SCP and DCP, the VD and VLD decreased in both groups in the short-term postoperative period, probably because the vessels that were crinkled in the OCT-A analysis area retreated to their original position after the ERM peeling, and some vessels left the analysis area, resulting in a temporary decrease in vessel density and length density. However, this was only for a short period of time, and then the VD and VLD gradually increased in both groups, which we believe is due to the reopening of the occluded microcapillaries caused by the ERM peeling [22]. Traction of the ERM increases the resistance to blood flow in the retinal veins, and peeling the ERM significantly improves the retinal blood circulation [23]. However, in the DCP, the ERM + ILM peeling group took longer to recover their VD and VLD than did the ERM peeling group and still did not recover to the preoperative levels by the final follow-up time. In contrast, the ERM peeling group was shown to have exceeded the preoperative levels at the final follow-up, which demonstrates that peeling of the ILM hindered the recovery of deep blood flow signals after surgery. We believe that Müller cells play a crucial role in this phenomenon, these cells secreting GFAP as a bridge to the ILM, when ILM peeling, Müller cells secreting large amounts of GFAP, GFAP will reduce the

blood flow rate and oxygen permeability of the microcirculation, which is manifested as abnormal blood flow information in the deep retina [24–25]. Moreover, in a high-glucose environment, Müller cells secrete increased GFAP, the peeling of the ILM can lead to anatomical changes in the deep retina [26–27]. Additionally, the deep retina, being the location of the 3 main oxygen-consuming sectors of the retina (photoreceptor segment, outer plexiform layer, deep inner plexiform layer), has a much higher sensitivity of the microcirculation to ILM peeling than the superficial retina [28]. In the superficial retina, the VD and VLD did not differ between the ERM + ILM peeling group and the ERM peeling group, we speculate that the reason for this may be that the superficial retinal vessels are not directly affected by Müller cells, and the superficial retina has a higher perfusion pressure and oxygen supply, allowing for better vascular tolerance [29–30].

Our study has some limitations. First, the presence of artefacts in OCT-A, an emerging tool for vascular analysis, can interfere with the analysis of deep retinal blood flow information, especially with a disturbed macular structure. Furthermore, because the severity of diabetic retinopathy and the structure of other parts of the macula can affect postoperative recovery [31], so we chose diabetic ERM cases with an ectopic inner foveal layer grade less than or equal to grade II and an intact ellipsoidal band and in the non-proliferative phase, which may have introduced selection bias.

Conclusions

Through this study, we found that although there was no difference in BCVA and MCT recovery after surgery between the two groups, intraoperative peeling of the ILM in patients with diabetic ERM can have a short-term inhibitory effect on deep retinal vascular recovery, which has clinical-reference implications for the choice of surgical approach. Next, we will continue to analyze the mechanism of Müller cells regulating microcirculation changes after ILM peeling.

Abbreviations

ILM: internal limiting membrane; ERM: epiretinal membrane; BCVA: best-corrected visual acuity; CMT: central macular thickness; VD: vessel density; VLD: vessel length density; SCP: superficial capillary plexus; DCP: deep capillary plexus; GFAP: glial fibrillary acidic protein; OCT-A: Optical coherence tomography angiography

Declarations

Acknowledgements

Not applicable.

Authors’ contributions

Heng Li was responsible for study design and patient surgery, Bo Li was responsible for data collection and manuscript writing, Wenjun Gou was responsible for patient follow-up and data statistics, Hui You and Mengtian Bai were responsible for patient follow-up and data collection, and Chen Xie was responsible for data compilation and doctor-patient communication

Funding

This research received no specific grant from any funding agency in the public, commercial, or not-for-profit sectors.

Availability of data and materials

The datasets used and analysed during the current study are available from the corresponding author on reasonable request. Or all relevant datasets related to the study can be found in the specified database (https://figshare.com/s/aa22c3d20a9ce3cda341)

Ethics approval and consent to participate

Informed consent was obtained from all the patients. The study program was reviewed and approved by the Research Ethics Committee of Suining Central Hospital(LLSLH20200007). In the following study, all methods were performed in accordance with the relevant guidelines and regulations.

Consent for publication

Not applicable.

Competing interests

The authors declare that they have no competing interests.

Author details

Department of Ophthalmology, Suining Central Hospital, Suining, 629000, Sichuan, People's Republic of China.

References

1. Adrian T Fung, Justin Galvin, Tuan Tran. Epiretinal membrane: A review. Clin Exp Ophthalmol.2021;49(3):289-308.
2. Khin Z Aung, Galina Makeyeva, Madeleine K Adams, Elaine W-T Chong, Lucy Busija, Graham G Giles, et al. The prevalence and risk factors of epiretinal membranes: the Melbourne Collaborative Cohort Study. Retina. 2013;33(5):1026-34.
3. Andreas Bringmann, Peter Wiedemann. Involvement of Müller glial cells in epiretinal membrane formation. Graefes Arch Clin Exp Ophthalmol. 2009;247(7):865-83.

4. Malav Joshi, Shivi Agrawal, John Byron Christoforidis. Inflammatory mechanisms of idiopathic epiretinal membrane formation. Mediators Inflamm . 2013;2013:192582.
5. Mari Ueki, Seita Morishita, Ryohsuke Kohmoto, Masanori Fukumoto, Hiroyuki Suzuki, Takaki S, et al. Comparison of histopathological findings between idiopathic and secondary epiretinal membranes. Int Ophthalmol. 2016;36(5):713-8.
6. Takeru Yoshimura, Koh-hei Sonoda, Mika Sugahara, Yasutaka Mochizuki, Hiroshi Enaida, Yuji Oshima, et al. Comprehensive analysis of inflammatory immune mediators in vitreoretinal diseases. PLoS One. 2009;4(12):e8158.
7. Eleni Tsotridou, Eleftherios Loukovitis, Konstantinos Zapsalis, Iro Pentara, Solon Asteriadis, Paris Tranos, et al. A Review of Last Decade Developments on Epiretinal Membrane Pathogenesis . Med Hypothesis Discov Innov Ophthalmol.2020;9(2):91-110.
8. Paris Tranos, Stavrenia Koukoula, Davic G Charteris, Georgia Perganda, Athanasios Vakalis, Solon Asteriadis, et al. The role of internal limiting membrane peeling in epiretinal membrane surgery: a randomised controlled trial. Br J Ophthalmol . 2017;101(6):719-24.
9. Mine Ozturk, Dilek Guven, Hakan Kacar, Murat Karapapak, Mehmet Demir. Functional and Morphological Results of Epiretinal Membrane Surgery in Idiopathic versus Diabetic Epiretinal Membranes. Semin Ophthalmol . 2021;36(5-6):366-72.
10. Mario R Romano, Gennaro Ilardi, Mariantonia Ferrara, Gilda Cennamo, Davide Allegrini, Pia Clara Pafundi, et al. Intraretinal changes in idiopathic versus diabetic epiretinal membranes after macular peeling. PLoS One. 2018;13(5):e0197065.
11. Richard F Spaide. "Dissociated optic nerve fiber layer appearance" after internal limiting membrane removal is inner retinal dimpling. Retina . 2012;32(9):1719-26.
12. P Grimbert, O Lebreton, M Weber. Optical coherence tomography and microperimetry after internal limiting membrane peeling for epiretinal membrane. J Fr Ophtalmol. 2014;37(6):434-41.
13. Akinori Uemura, Shigeru Kanda, Yushi Sakamoto, Hazuki Kita. Visual field defects after uneventful vitrectomy for epiretinal membrane with indocyanine green-assisted internal limiting membrane peeling. Am J Ophthalmol. 2003;136(2):252-7.
14. Lisa Toto, Enrico Borrelli, Rodolfo Mastropasqua, Luca Di Antonio, Emanuele Doronzo, Paolo Carpineto, et al. Association between outer retinal alterations and microvascular changes in intermediate stage age-related macular degeneration: an optical coherence tomography angiography study. Br J Ophthalmol . 2017;101(6):774-9.
15. Yufei Teng, Marco Yu, Yi Wang, Xinxin Liu, Qisheng You, Wu Liu. OCT angiography quantifying choriocapillary circulation in idiopathic macular hole before and after surgery. Graefes Arch Clin Exp Ophthalmol. 2017 ;255(5):893-902.
16. Gerardo González-Saldivar, Alan Berger, David Wong, Verena Juncal, David R Chow. ECTOPIC INNER FOVEAL LAYER CLASSIFICATION SCHEME PREDICTS VISUAL OUTCOMES AFTER EPIRETINAL MEMBRANE SURGERY. Retina.2020;40(4):710-7.

17. Alessandro Rabiolo, Fabio Bignami, Paolo Rama, Giulio Ferrari. VesselJ: A New Tool for Semiautomatic Measurement of Corneal Neovascularization. Invest Ophthalmol Vis Sci.2015;56(13):8199-206.
18. Enrique Zudaire, Laure Gambardella, Christopher Kurcz, Sonja Vermeren. A computational tool for quantitative analysis of vascular networks. PLoS One.2011;6(11):e27385.
19. Kunihiro Azuma, Takashi Ueta, Shuichiro Eguchi, Makoto Aihara. EFFECTS OF INTERNAL LIMITING MEMBRANE PEELING COMBINED WITH REMOVAL OF IDIOPATHIC EPIRETINAL MEMBRANE: A Systematic Review of Literature and Meta-Analysis. Retina. 2017;37(10):1813-9.
20. Miin Roh, Dean Eliott. Internal Limiting Membrane Peeling During Idiopathic Epiretinal Membrane Removal: Literature Review. Int Ophthalmol Clin.2015;55(4):91-101.
21. Jianbo Mao, Jimeng Lao, Chenyi Liu, Caiyun Zhang, Yiqi Chen, Jiwei Tao, et al. A study analyzing macular microvasculature features after vitrectomy using OCT angiography in patients with idiopathic macular epiretinal membrane. BMC Ophthalmol. 2020; 20(1):165.
22. Rodolfo Mastropasqua, Rossella D'Aloisio, Pasquale Viggiano, Enrico Borrelli, Carla Iafigliola, Marta Di Nicola, et al. Early retinal flow changes after vitreoretinal surgery in idiopathic epiretinal membrane using swept source optical coherence tomography angiography. J Clin Med. 2019; 8(12):2067.
23. Tomoko Yagi, Kumi Sakata, Hideharu Funatsu, Sadao Hori. Evaluation of perifoveal capillary blood flow velocity before and after vitreous surgery for epiretinal membrane. Graefes Arch Clin Exp Ophthalmol.2012;250(3):459-60.
24. Mario R Romano, Gilda Cennamo, Stefano Schiemer, Claudia Rossi, Federica Sparnelli, Giovanni Cennamo, Deep and superficial OCT angiography changes after macular peeling: idiopathic vs diabetic epiretinal membranes. Graefes Arch Clin Exp Ophthalmol. 2017;255(4):681-9.
25. Guido Ripandelli, Fabio Scarinci, Paolo Piaggi, Gianluca Guidi, Marco Pileri, Gaetano Cupo, et al. Macular pucker: to peel or not to peel the internal limiting membrane? A microperimetric response. Retina. 2015;35(3):498-507.
26. Nihal Kenawy, David Wong, Theodore Stappler, Mario R Romano, Ronald A Das, Gillian Hebbar, et al. Does the presence of an epiretinal membrane alter the cleavage plane during internal limiting membrane peeling? Ophthalmology. 2010;117(2):320-3.
27. H Terasaki, Y Miyake, R Nomura, C H Piao, K Hori, T Niwa, et al. Focal macular ERGs in eyes after removal of macular ILM during macular hole surgery. Invest Ophthalmol Vis Sci. 2001;42(1):229-34.
28. Kwan Hyuk Cho, Sang Jun Park, Joon Hee Cho, Se Joon Woo, Kyu Hyung Park. Inner-Retinal Irregularity Index Predicts Postoperative Visual Prognosis in Idiopathic Epiretinal Membrane. Am J Ophthalmol.2016; 168:139-149.
29. Florence Coscas, Agnes Glacet-Bernard, Alexandra Miere, Violaine Caillaux, Joel Uzzan, Marco Lupidi, et al. Optical Coherence Tomography Angiography in Retinal Vein Occlusion: Evaluation of Superficial and Deep Capillary Plexa. Am J Ophthalmol.2016;161:160-71.
30. Hui Chen, Wei Chi, Xiaojuan Cai, Yang Deng, Xintong Jiang, Yantao Wei, et al. Macular microvasculature features before and after vitrectomy in idiopathic macular epiretinal membrane: an

OCT angiography analysis. Eye (Lond). 2019;33(4):619-28.

31. Lorenzo Iuliano, Giovanni Fogliato, Francesca Gorgoni, Eleonora Corbelli, Francesco Bandello, Marco Codenotti. Idiopathic epiretinal membrane surgery: safety, efficacy and patient related outcomes. Clin Ophthalmol.2019;13:1253-65.

Figures

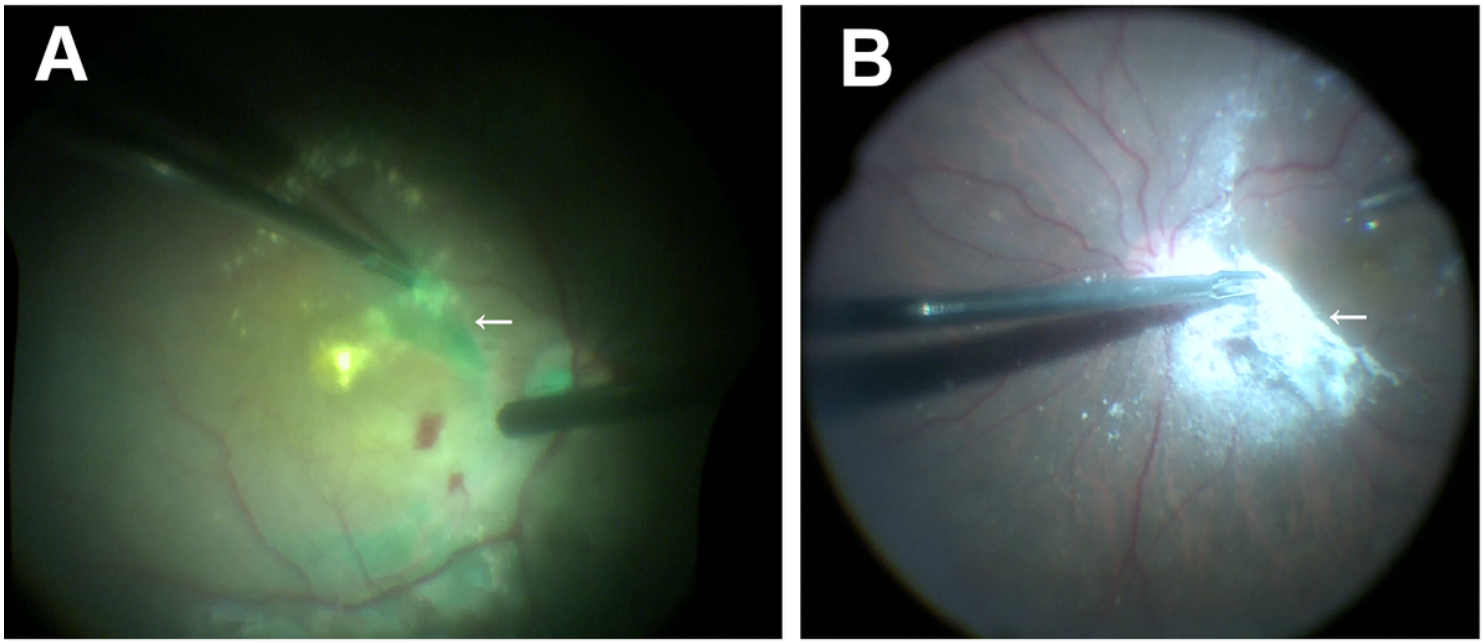

Figure 1

Intraoperative peeling of the proliferating membrane using membrane forceps. A After indocyanine green staining, peel off ERM+ILM (arrows). B After triamcinolone acetonide staining, the ERM (arrows) was stripped

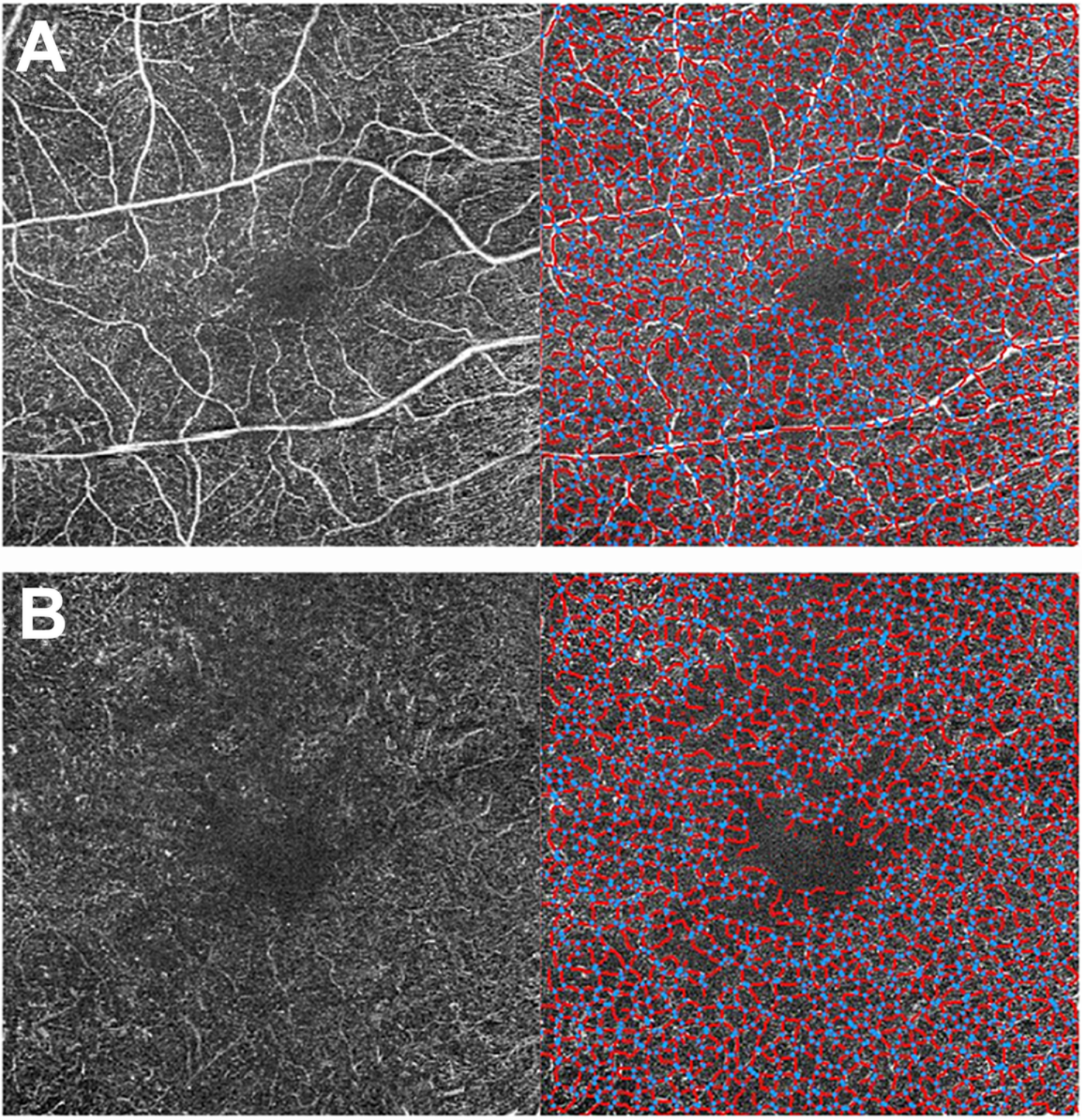

Figure 2

SCP and DCP within 6*6mm centered on fovea. A In SCP, the red lines represent the vascular network, and the blue dots represent the intersections between the vessels. B In DCP, the red lines represent the vascular network, and the blue dots represent the intersections between the vessels

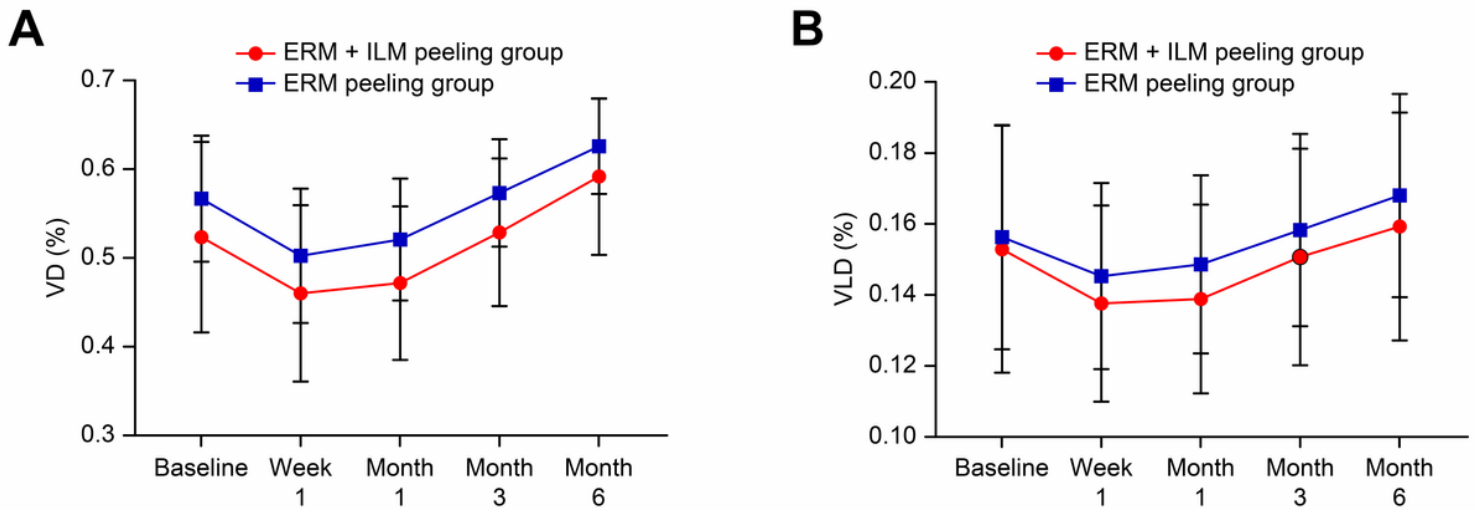

Figure 3

In SCP, the change trend of VD and VLD in two groups of patients. A The change trend of VD in the two groups of patients after surgery. B The change trend of VLD in the two groups of patients after surgery

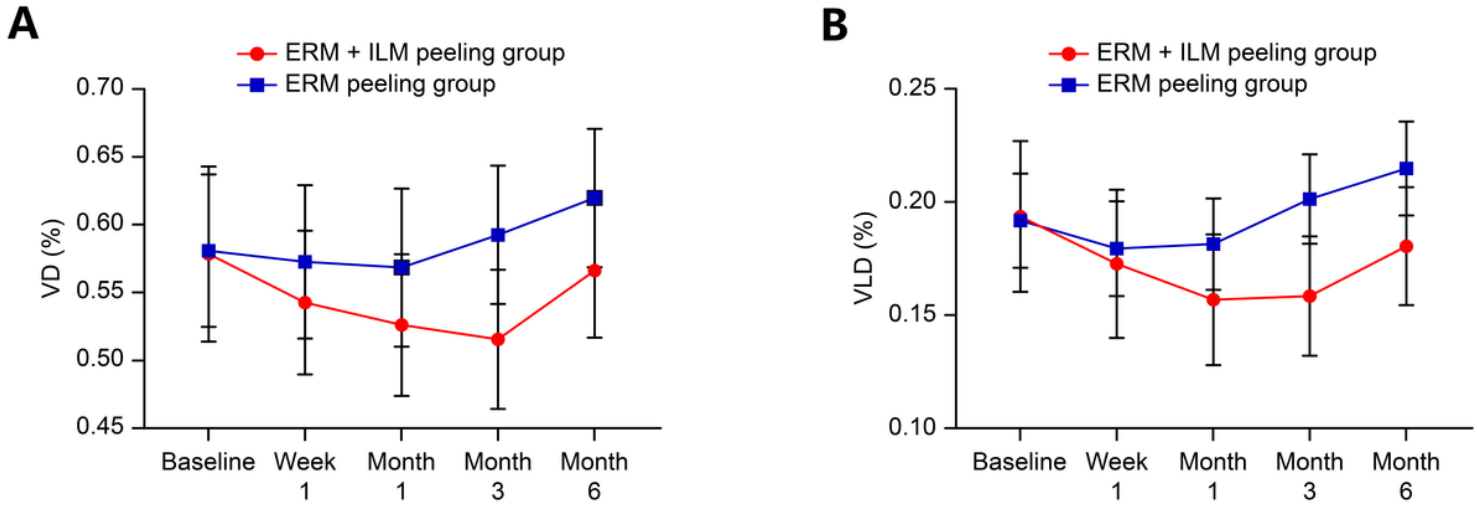

Figure 4

In DCP the change trend of VD and VLD in two groups of patients. A The change trend of VD in the two groups of patients after surgery. B The change trend of VLD in the two groups of patients after surgery