A giant hepatic cavernous hemangioma with an abdominal wall hemangioma: a case report

Yan Liu
Chengdu Fifth People's Hospital
Xue Gu
Chengdu Fifth People's Hospital
Zhang Zhou
Chengdu Fifth People's Hospital
Na Yang
Chengdu Fifth People's Hospital
Cheng-jun Luo
Chengdu Fifth People's Hospital
Li Li (lddlily@163.com)
Chengdu Fifth People's Hospital

Case report

Keywords: hepatic hemangioma, cavernous hemangioma, abdominal wall hemangioma

Posted Date: March 16th, 2020

DOI: https://doi.org/10.21203/rs.3.rs-17273/v1

Abstract

Introdoction: Hepatic cavernous hemangioma is the most common benign tumor of the liver without special treatment which is very common in clinical work.But some larger cavernous hemangioma has the risk of bleeding, clinical diagnosis and treatment of large hepatic cavernous hemangioma is of great significance.

Case presentation: The patient was a 45-year-old middle-aged woman who was admitted to the hospital due to a large lesion of the abdominal wall. At first, she was considered as having a melanoma of the abdominal wall. After imaging and pathological examinations, she was diagnosed as having a giant cavernous hemangioma of the liver. Percutaneous hepatic artery superselective angiography and embolization significantly reduced the lesions.

Conclusion: Hepatic cavernous hemangioma is relatively more common clinically, but there are few reports of multiple and huge hemangioma, as reported here, our patient had a large abdominal wall hemangioma. It is speculated that the coexistence of the two is related. In fact,during embryonic development,the fetus and mother are connected by two umbilical arteries and one umbilical vein. An aneurysm-like deformity caused by excessive development or abnormal differentiation of blood vessels during the developmental process may be the cause of the patient's massive abdominal wall and liver hemangiomas.

Background

A hepatic hemangioma is the most common benign tumor of the liver. It is clinically divided into four types: cavernous hemangioma, sclerosing hemangioma, hemangioendothelioma and capillary hemangioma. The most common type is hepatic cavernous hemangioma. The hepatic cavernous hemangioma is a benign tumor formed by interstitial tissue, its structure is irregular, and interstitial tissues separate the vascular space of various shapes and sizes[1], we report a rare case of a massive diffuse giant hemangioma with massive, progressive, and spontaneous hemorrhage with a massive abdominal wall hemangioma.

Case Presentation

The female patient, 45 years old, was born with a 1×1 cm melanotic nevus on the left abdominal wall of the navel. More than 20 years ago, the patient's abdominal wall melanotic nevus gradually grew, ruptured and hemorrhaged during pregnancy. One year ago, the melanotic nevus grew up to 2×4 cm. There was bleeding but no pain; the patient was admitted to the hospital for 1 week due to bloating, nausea and vomiting, without abdominal pain or diarrhea. The physical examination revealed no abnormality. Routine blood, hepatic function, coagulation function, and alpha-fetoprotein tests were not significantly abnormal.

Abdominal color Doppler ultrasound showed solid nodules in the abdominal wall and multiple solid nodules in the liver, and contrast-enhanced ultrasound revealed the uneven enhancement of intrahepatic lesions (see Figure 1). Abdominal computed tomography (CT) showed a "cauliflower-like" protrusion in the anterior abdominal wall, which enhanced the uneven enhancement of the posterior abdominal wall; diffuse nodules and masses in the hepatic parenchyma, uneven density, partial fusion, approximately 19.5 × 16.9 × 7.9 cm at most (see Figure 2); and discontinuous nodular enhancement in the arterial phase. The range of strengthening was expanded in the portal phase and delay phase (see Figure 3). Magnetic resonance enhancement suggested that the size of the abdominal wall uneven enhancement lesion was approximately 4.2×1.6×1.4 cm (see Figures 4 and 5). Hepatic lesion T1-weighted imaging (T1WI) showed diffuse low-signal nodules and a mass and interspecific hypersignal hemorrhage (see Figure 6). T2WI showed a high signal mixed with a low signal (indicating acute hemorrhage) and a high signal (indicating subacute hemorrhage) (see Figure 7). A dynamic contrast-enhanced scan showed multiple nodular and reticular masses around and in the center of the tumor early enhanced. With the delay of the scan time, the enhancement range was gradually expanded (see Figure 8).

Hepatic and abdominal wall biopsy was consistent with a cavernous hemangioma (see Figure 9). Later, "percutaneous superselective hepatic artery angiography and embolization" was performed under local anesthesia (see Figure 10). After interventional treatment, the hemangioma of the patient was significantly smaller than before(see Figure 11).

Discussion

In the past, a rare case of a giant cavernous hemangioma with a diameter of approximately 17 cm was reported[2][3]. In this case, the hemangioma was diffuse, and the maximum diameter was approximately 19.5 cm. The Medline database, which was active for more than one hundred years (1898–2010), contains 97 reported cases of hepatic hemangioma rupture, including 46 cases of spontaneous rupture, suggesting that a hepatic hemangioma with spontaneous hemorrhage is a rare phenomenon[4]. In this case, acute and subacute hemorrhage was reported in the hepatic hemangioma, and a large hemangioma with progressive growth and repeated hemorrhage in the periumbilical skin was also reported, although it is rare.

The pathogenesis of cavernous hemangioma is not fully understood. It is related to congenital dysplasia, chromosomal variation during the formation of the three germ layers, and stimulating changes in acquired hormones. It is speculated from molecular biology mechanisms that it may be caused by abnormal angiogenesis[5]. Specifically, it may be characterized by the upregulation of proangiogenic factors, such as fibroblast growth factor, vascular endothelial growth factor, and matrix metalloproteinase, and the downregulation of certain angiogenesis inhibitors, such as tissue inhibitor of matrix metalloproteinase 1.

Why is there a giant hemangioma in the liver and navel skin in this case? We suspect that the cause may be an aneurysm-like malformation caused by excessive blood vessel development or abnormal

differentiation during embryonic development. The fetus and the mother are connected by two umbilical arteries and one umbilical vein. When the fetus is born, its own blood circulation is established, the physiological function of the umbilical cord is stopped, the umbilical vein is occluded into the round hepatic ligament, and the umbilical artery is occluded into the umbilical lateral ligament. The umbilical cord is cut and healed to leave scar tissue to form the navel[6]. It was confirmed that the navel and liver were connected during the embryonic period.

Conclusion

When we first analyzed this case, we easily misdiagnosed it as abdominal wall with liver metastasis of melanoma tumors. Abdominal wall and liver pathological histology of cavernous blood vessels showed the characteristics of liver and abdominal wall hemangioma. The primary diagnosis and final treatment for patients differ completely with regard to direction and acceptance. Through this case, we explored the possible causes of hemangioma malformations, which allowed us to attach importance to the significance of the pathological basis of our clinical diagnosis.

Many liver hemangiomas will be encountered in clinical work, but most are small and do not require special treatment. However, if we find a large, multiple hemangioma in the clinic with bleeding, we must pay enough attention. Hemangiomas can be treated by interventional embolization to avoid serious complications such as major bleeding.

Declarations

Data and materials: Not application

Ethics approval and consent:

As this case report is not a prospective study, Ethics approval cannot be provided for the time being

Informed Consent:

Written informed consent was obtained from the patient for the publication of this case report and accompanying images. A copy of the written consent is available for review by the editor-in-chief of this journal.

Competing interests

The authors declare that they have no competing interests.

Authors’contributions

Xue Gu was involved in drafting the manuscript. Yan Liu was involved in acquisition of case and preparing the figures. Li Li and Chengjun Luo designed and revised the manuscript. Zhang Zhou and Na

Yang were involved in drafting the manuscript.Zhang Zhou and Na Yang were involved in acquisition of case and preparing the figures. All authors have read and approved the final manuscript.

Acknowledgements

We greatly appreciate the assistance of the staff of the Department of Radiology and pathology, Chengdu Fifth People's Hospital, and thank them for their efforts.

Author details

[1]Gastroenterology department, Chengdu Fifth People's Hospital, Chengdu wenjiang 611130

[2]Radiology department,Chengdu Fifth People's Hospital, Chengdu wenjiang 611130

Corresponding author: Li Li Ma shi street wenjiang district chengdu city sichuan province

E-mail:Lddlily@163.com. Cheng-jun Luo,Ma shi street wenjiang district chengdu city sichuan province E-mail:4620943@qq.com

Yan Liu and Xue Gu contributed equally to this work.

References

1. Hinganu MV, Hinganu D, Francu LL. Microanatomic aspects of arterial blood supply in rectal carcinomas predictive models. Rom J Morphol Embryol 2013, 54(3):561–565.
2. Ketchum WA, Lin-Hurtubise KM, Ochmanek E,et al.Management of Symptomatic Hepatic "Mega" Hemangioma.Hawaii J Med Public Health. 2019,78(4):128-131.
3. Renzulli M,Ricciardi D,Clemente A,et al.Unexpected newborns in the liver : hemangiomatosis onset after hepatic resection of a giant cavernous hemangioma. Acta gastro-enterologica Belgica 2019,18(3):454-455.
4. Professional Committee of Hepatic Hemangioma of ihpba China Branch,Multidisciplinary expert consensus on the diagnosis and treatment of hepatic hemangioma(2019 version)[J].Chinese journal of practical surgery,2019,39(8):761-765.
5. Yu Y,Varughese J,Brown LF,et al.Increased tie2 expression,enhanced response to angiopoietin-1,and dysregulated angiopoietin-2 expression in hemangioma-derived endothelial cells,Am J 2001,159:2271-2280.
6. Anna Finnemore,Alan Groves,Physiology of the fetal and transitional circulation.Seminars in Fetal & Neonatal Medicine 20 (2015)

Figures

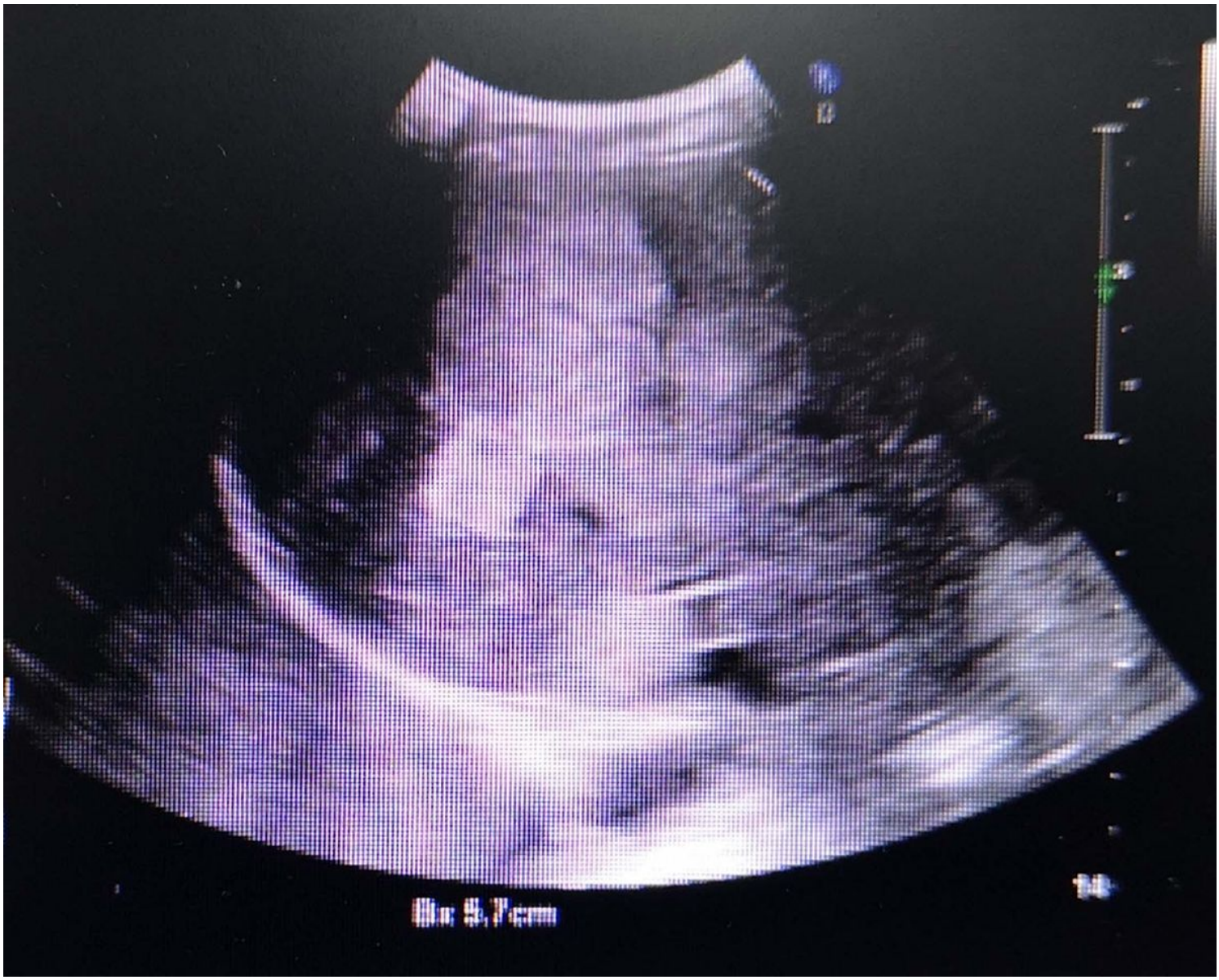

Figure 1

Abdominal color Doppler ultrasound showed the multiple solid nodules in the liver.

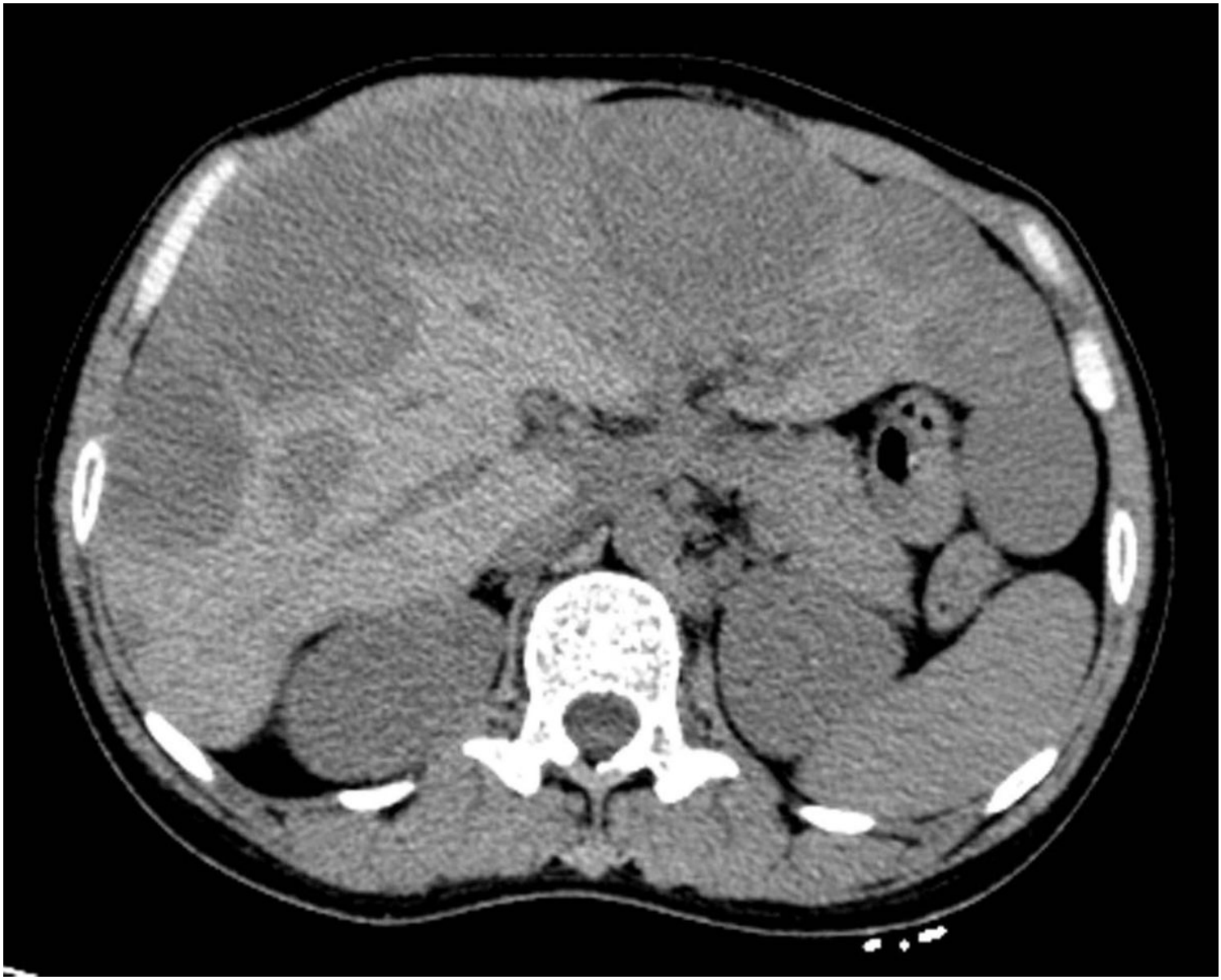

Figure 2

CT plain scan of multiple liver lesions.

Figure 3

CT enhancement is progressive and obvious(green arrow).

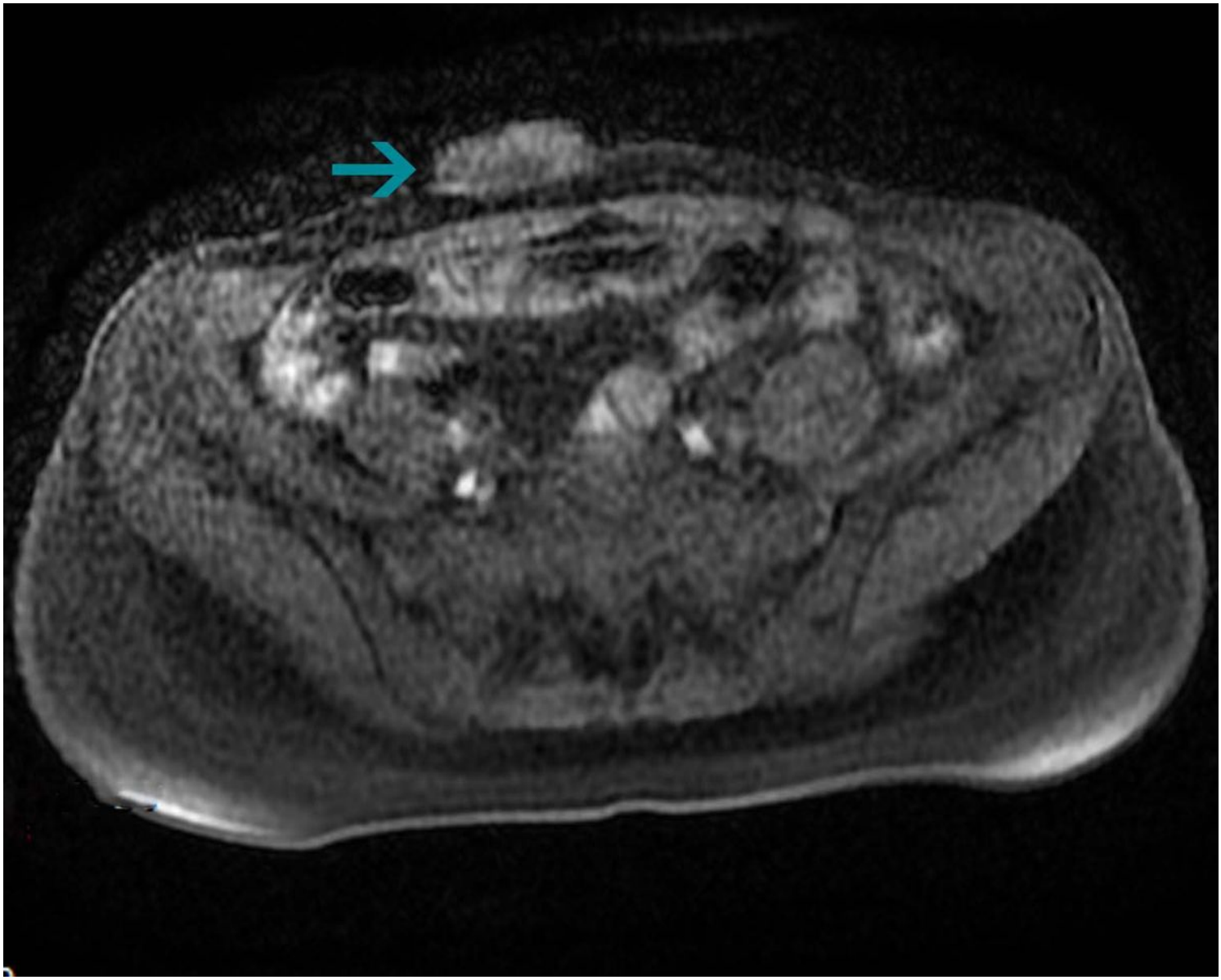

Figure 4

The T1-weighted images of the abdominal wall showed a slightly lower inter - heterohedral signal.

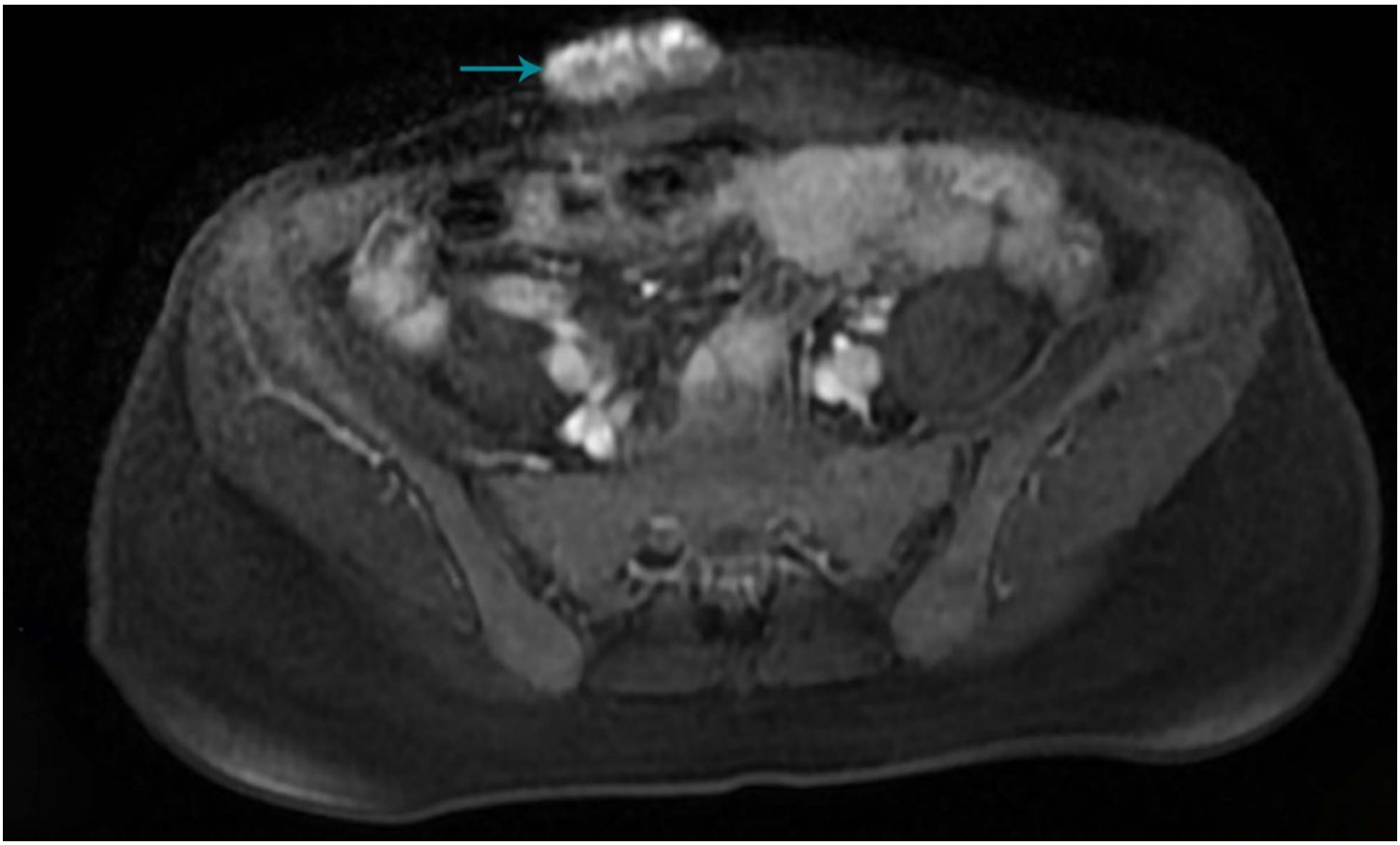

Figure 5

Enhanced scan showed uneven enhancement of abdominal wall lesions.

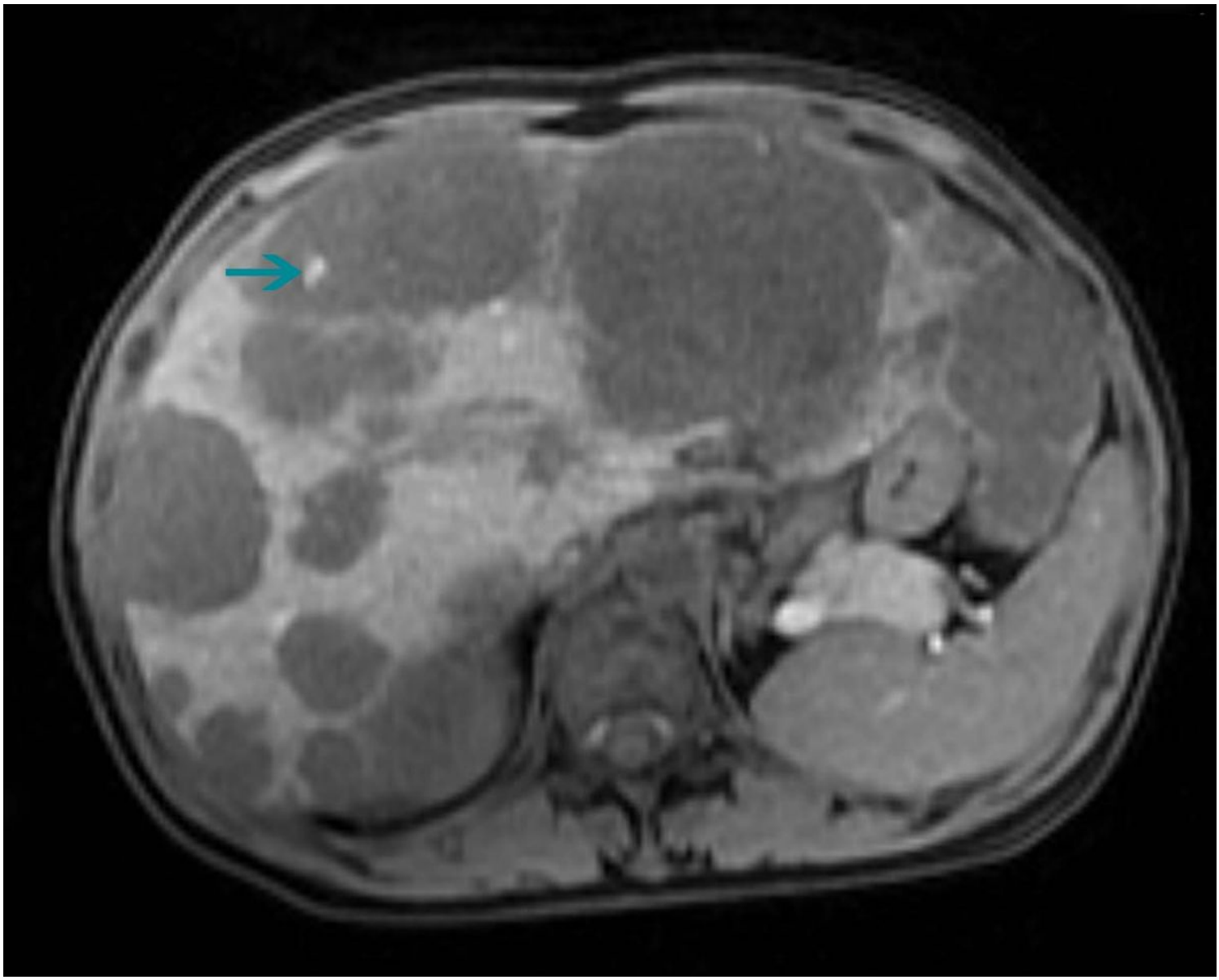

Figure 6

T1-weighted imaging suggested that multiple liver lesions presented uneven low signal and mixed high signal shadows,which indicates bleeding（green arrow ）.

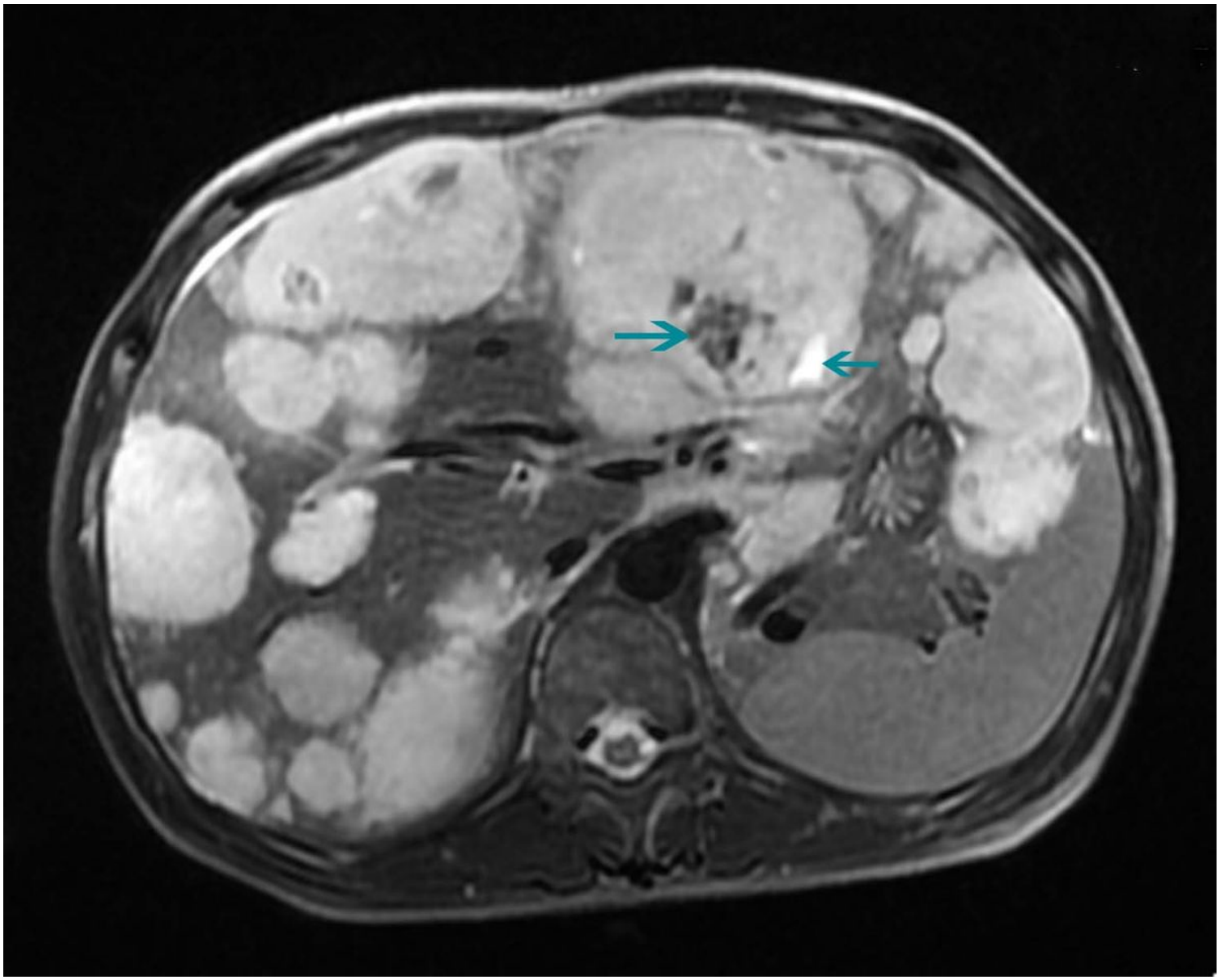

Figure 7

T2-weighted imaging suggested that multiple liver lesions presented uneven high signal and mixed low signal shadows，which indicates bleeding，green arrow ↖.

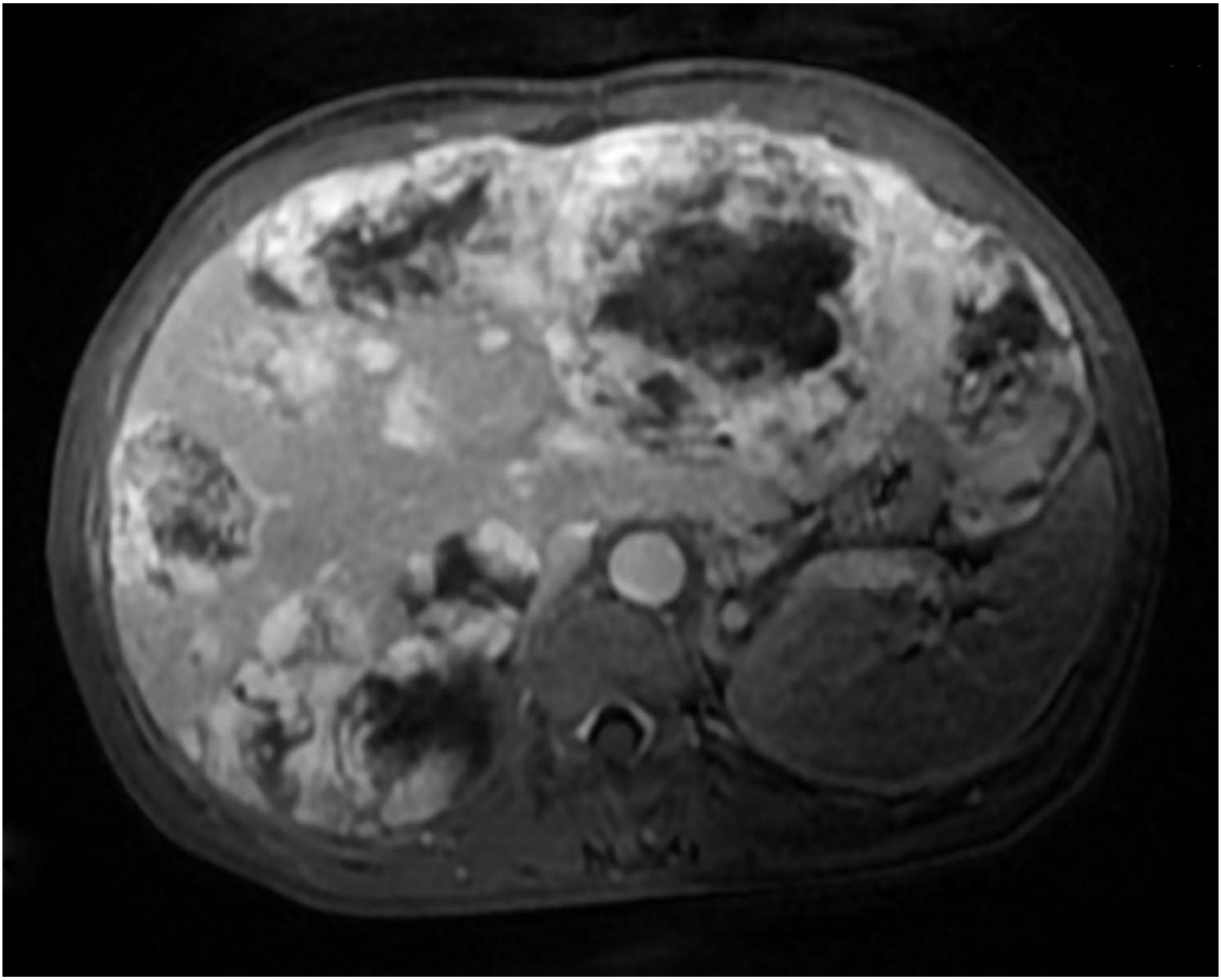

Figure 8

Multiple liver lesions showed progressive enhancement on MRI.

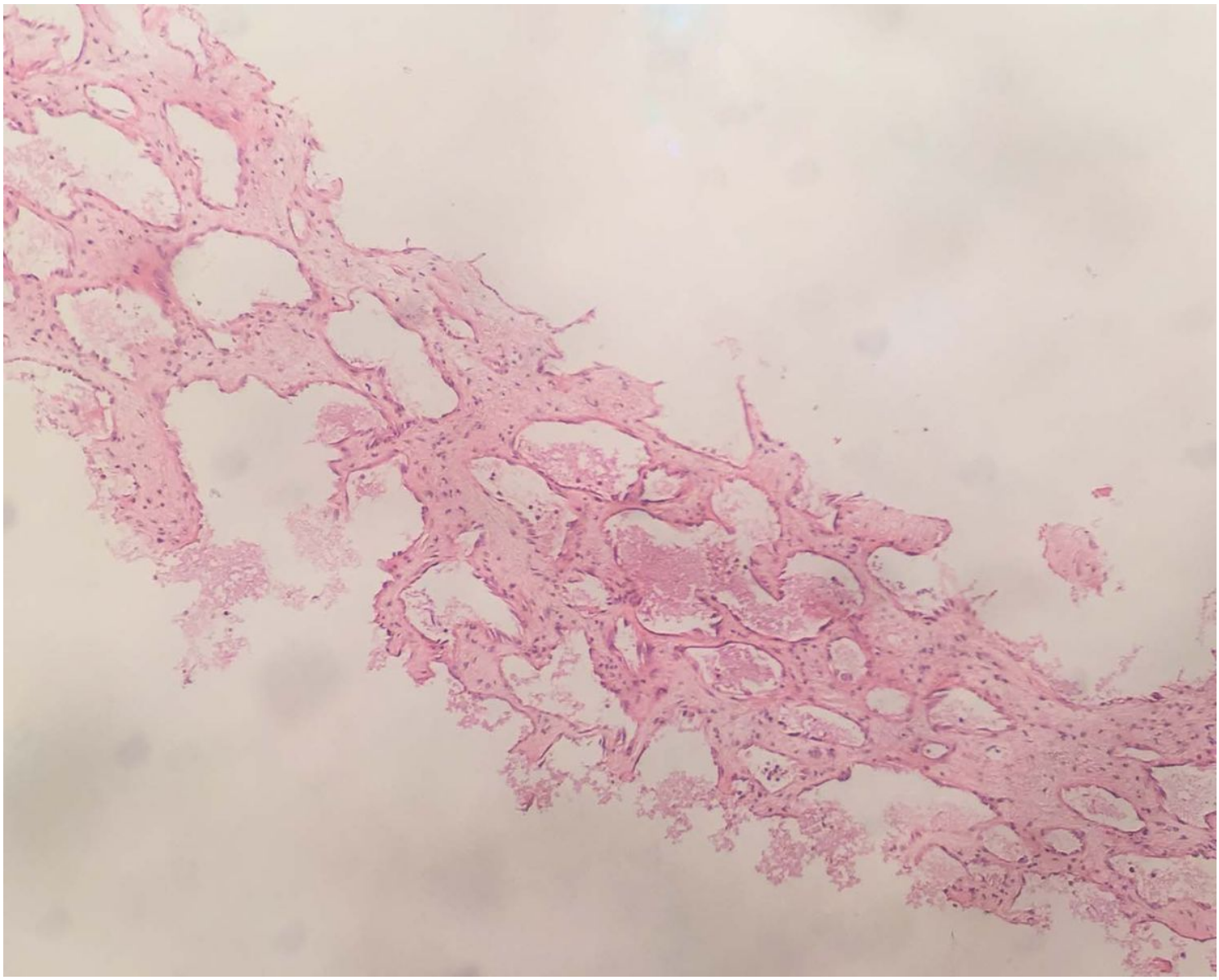

Figure 9

Liver biopsy revealed cavernous hemangioma in the liver.

Figure 10

Percutaneous hepatic arteriography and embolization.

Figure 11

After interventional treatment, the hemangioma of the patient was significantly smaller than before