MR imaging characteristics of slow- and rapid-growing meningiomas: a cohort study of 165 cases

Lei He
Capital Medical University
Yuchao Liang
Capital Medical University
Ziwen Fan
Capital Medical University
Yukun Liu
Capital Medical University
Chunyao Zhou
Capital Medical University
Qiang Zhu
Capital Medical University
Hong Zhang
Capital Medical University
Tianshi Li
Capital Medical University
Jianing Yang
Capital Medical University
Yanpeng Zhou
Capital Medical University
Jiaxiang Wang
Capital Medical University
Lei Wang (wanglei_tiantan@163.com)
Capital Medical University

Research Article

Keywords: Meningioma, Tumor growth, MRI, Risk assessment

Posted Date: June 14th, 2022

DOI: https://doi.org/10.21203/rs.3.rs-1734865/v1

Abstract

Introduction: The growth rate of meningiomas varies greatly (0.01 to 2.58 cm^3/year).

An inappropriate 'wait and see' treatment strategy, such as a follow-up interval of MRI longer than 2 years, for rapid growing meningioma (RGM) may seriously increase the risk of subsequent surgery and may eliminate the opportunity for operation. Our purpose was to compare the MR imaging features of slow-growing meningiomas (SGMs) and RGMs and identify the factors that could predict RGM.

Methods: We retrospectively collected SGM and RGM data between 2016 and 2021 in Beijing Tiantan Hospital and then used IBM SPSS software to analyze the clinical and MR imaging features between the two groups.

Results: Eighty-seven SGM and 78 RGM were collected in our study. Male sex had a 2.896-fold risk of predicting RGM in multivariate analysis (P = 0.048). Patient age, tumor shape and location showed no significant difference between the two groups (P = 0.562, P = 0.514, P = 0.094, respectively). Meningiomas with diameters > 2.5 cm had a higher risk of growing rapidly (multivariate analysis, HR: 3.484, P = 0.006). The presence of peritumoral edema and absence of hypointensity on T2W-MRI were significantly associated with RGM (multivariate analysis; HR: 6.990, P < 0.001; HR: 3.753, P = 0.008;, respectively).

Conclusions: Male sex, peritumoral edema, tumor size > 2.5 cm and absence of hypointensity on T2W-MRI may indicate the potential for rapid growth of meningiomas.

Introduction

Meningioma is the most common primary intracranial tumor (37.6%), with an annual incidence rate of 8.58 per 100 000 population [1]. The incidence rate increases with age; the prevalence is 0.5% in subjects aged 45–59 years and 1.6% after 75 years [2]. The treatment plan (operation, dynamic observation or radiotherapy) is mainly based on the tumor size, location and presence of symptoms. Dynamic observation is one preferred treatment for some meningiomas with a maximum diameter below 2.5 cm and without neurological symptoms or patients with high surgical risk [2]. However, the annual growth rate of meningiomas is very different (0.01–2.58 cm^3/year) [3]. Inappropriate dynamic observation may seriously increase the risk of subsequent surgical treatment and even miss the opportunity for operation. Therefore, the growth rate potential of meningiomas should also be considered seriously when making treatment decisions. The purpose of this study was to analyze the imaging features of slow-growing meningioma (SGM) and rapid-growing meningioma (RGM) to identify factors that can effectively predict the tumor growth rate.

Methods

Definition of SGM and RGM

A unified definition of RGM has not yet been established, but some previous studies provide a reliable reference. Lee et al. defined RGM based on an absolute growth rate of ≥ 2 cm3/year [4], while Islim et al. added an absolute growth rate of ≥ 1 cm^3/year + a relative growth rate ≥ 30%/year as an additional standard in their report [3]. Considering that initial volume differs among observed meningiomas, defining RGM only on absolute growth rate seems insufficient. In addition, meningiomas may grow exponentially [5], and nonsignificant growth in the short term (1 to 2 years) may not mean SGM correctly. Hence, we consider an absolute growth rate of ≥ 2 cm3/year or an absolute growth rate ≥ 1 cm3/year + a relative growth rate ≥ 30%/year as the criterion defining RGM, while SGM should not meet the above standards for four years or longer.

Patient Selection

We retrospectively collected all the patients diagnosed with meningioma based on MR imaging between 2016 and 2021 in Beijing Tiantan Hospital and then checked MR imaging patient-by-patient by two independent observers using the following steps:

1) Selecting patients who had at least two MR imaging records before operation in the hospital system.

2) Observers independently determine whether the tumor belongs to the SGM or RGM according to visual inspection. Tumors that visually meet the definition criteria of rapid growth meningioma are tentatively designated as RGM, while those that do not meet the criteria within four years or longer (if MR imaging records can be traced back before 2016, and the maximum interval longer than 4 years between two MR images is also acceptable) are designated as SGM.

3) Using open source software, 3D Slicer calculates tumor volume to redefine tumor grouping by two observers independently. If one sample was not redefined in the same group by both observers, then it was excluded.

4) Patients with radiotherapy experience in medical records were excluded.

MRI characteristics

Tumor size, shape, location, hypointensity on T2W-MRI and peritumoral edema were collected, along with the patient's age at the first diagnosis and sex. The specific definitions are as follows:

1) Tumor size is defined as maximum diameter considering that it is more likely to be measured, while original image data are not always available.

2) Tumor shape was defined as regular (globular shape) or irregular (mushroom shape). or lobulated).

3) Tumor location was defined as supratentorial, infratentorial (including tentorium cerebellum, posterior cranial fossa and clival region) and triangular region.

4) The percentage of hypointensity on T2W-MRI was defined as 0%, 0–33%, 34–67%, 68 – 100% (Fig. 1e-h).

Statistical Analysis

Analysis was performed using IBM SPSS, version 25.0 (IBM Corp., Armonk, New York, USA), for Windows. We used independent samples t tests or Mann–Whitney U tests for continuous variables. The chi-square test or Fisher's precision probability test was used for categorical variables. A Cox proportional hazards model was used for multivariate analysis. Statistical significance was considered present at $P < 0.05$.

Results

Patient characteristics

As shown in Table 1. One hundred and sixty-five patients were enrolled in our analysis. Eighty-seven subjects were defined as SGM (mean growth rate, 0.22 cm3/year), while 78 subjects were defined as RGM (mean growth rate, 5.80 cm3/year). The mean follow-up durations (Fig. 2) were 81.53 months (range 48.40-164.13 months) and 42.81 months (range 8.93–116.00 months) in the SGM and RGM groups, respectively ($P = 0.000$). The age distribution is shown in Fig. 1. Between the SGM group and RGM group, no statistical significance was found in age (mean age in years: 55.66 ± 8.20 vs. 56.60 ± 12.52, $P = 0.562$; patients with age below 60 years: 70.11% vs. 56.41%, $P = 0.068$). There were eight (9.20%) male patients in the SGM group and 23 (29.46%) males in the RGM group ($P < 0.001$).

Table 1
Characteristics of patient and MR imaging

	SGM-group	RGM- group	P
Characteristics	N (%)	N (%)	value
Patients	87	78	-
Mean follow-up duration in month (range) [b]	81.53 (48.40-164.13)	42.81 (8.93–116.00)	< 0.001
Mean age in years (± SD) [a]	55.66 ± 8.20	56.60 ± 12.52	0.562
Age<60years[c]	61 (70.11)	44 (56.41)	0.068
Male sex [c]	8 (9.20)	23 (29.49)	0.001
Growth rate in cm3/year (range) [a]	0.22 (0.01–1.44)	5.80 (0.65–22.50)	< 0.001
Mean volume in cm3 (range) [a]	6.11 (0.41–23.64)	10.34 (0.71–43.66)	0.015
Mean maximum diameter (± SD) [a]	2.00 ± 0.98	2.70 ± 0.98	< 0.001
Size (maximum diameter) [d]			< 0.001
≤ 2.5 cm	69 (79.31)	38 (48.72)	-
> 2.5 to ≤ 4.0 cm	13 (14.94)	30 (38.46)	-
> 4.0 cm	5 (5.75)	10 (12.82)	-
Edema in the first MRI [c]	4 (4.60)	13 (16.67)	0.011
Edema in MRI within follow-up duration [c]	4 (4.60)	33 (42.31)	< 0.001
Irregular shape [c]	11 (12.64)	19 (24.36)	0.514
Tumor location [d]			0.094
Supratentorial	69 (79.31)	53 (67.95)	-
Infratentorial	14 (16.09)	23 (29.49)	-
Triangular	4 (4.60)	2 (2.56)	-
Hypointense in T2W-MRI [d]			0.008
0%	44 (50.57)	58 (74.36)	-
0–33%	32 (36.78)	14 (17.95)	-

a t-test, b Mann-Whitney U test, c chi-square test, d fisher's precision probability test

	SGM-group	RGM- group	P
34–67%	6 (6.90)	5 (6.41)	-
68–100%	5 (5.75)	1 (1.28)	-
a t-test, b Mann-Whitney U test, c chi-square test, d fisher's precision probability test			

MRI characteristics

Compared with the SGM group, tumors in the RGM group had a wider maximum diameter (mean maximum diameter, 2.00 ± 0.98 vs. 2.70 ± 0.98 cm, P < 0.001), and 79.31% SGM and 48.72% RGM were smaller than 2.5 cm (P < 0.001). Peritumoral edema was present in 4 (4.60%) SGMs and 13 (16.67%) RGMs in the first MRI (P = 0.011). In the follow-up duration, we observed that 20 tumors (without peritumoral edema in the first MRI) presented peritumoral edema in the RGM group (Fig. 3), while none were found in the SGM group (P < 0.001). Regarding tumor shape and location, no significant difference was found between the two groups (P = 0.514 and P = 0.094, respectively). Tumors in the RGM group were more likely to be without hypointensity on T2W-MRI than those in the SGM group (50.57% vs. 74.36%, P = 0.008). Details are listed in Table 1.

We performed a subgroup analysis based on tumor size, and the results are shown in Table 2. In the subgroup of tumor size < 2.5 cm, 4 RGM (10.53%) presented edema, while no SGM presented (P = 0.014). However, between the SGM group and the RGM group, no significant difference in edema presentation was found in the > 2.5 to ≤ 4.0 cm subgroup and the > 4.0 cm subgroup (P = 1.000, P = 1.000, respectively). Between SGM and RGM, hypointensity on T2W-MRI was significantly different in the ≤ 2.5 cm subgroup and the > 2.5 to ≤ 4.0 cm subgroup (P = 0.007, P = 0.006, respectively) but not in the > 4.0 cm subgroup (P = 0.126). (Table 2).

Table 2
Subgroup analysis based on tumor size

	SGM-group	RGM- group	P
Characteristics	N (%)	N (%)	Value
≤ 2.5 cm			
Edema in first MRI			0.014
No	69 (100.00)	34 (89.47)	-
Yes	0 (0.00)	4 (10.53)	-
Hypointense in T2			0.007
0%	39 (56.52)	33 (86.84)	-
0–33%	22 (31.88)	4 (10.53)	-
34–67%	5 (7.25)	0 (0.00)	-
68–100%	3 (4.35)	1 (2.63)	-
> 2.5 to ≤ 4.0 cm			
Edema in first MRI			1.000
No	12 (92.31)	26 (86.67)	-
Yes	1 (7.69)	4 (13.33)	-
Hypointense in T2			0.006
0%	4 (30.77)	23 (76.67)	-
0–33%	6 (46.15)	7 (23.33)	-
34–67%	1 (7.70)	0 (0.00)	-
68–100%	2 (15.38)	0 (0.00)	-
> 4.0 cm			
Edema in first MRI			1.000
No	2 (40.00)	5 (50.00)	-
Yes	3 (60.00)	5 (50.00)	-
Hypointense in T2			0.126
0%	1 (20.00)	2 (20.00)	-

All dates are analysed by fisher's precision probability test

	SGM-group	RGM- group	P
0–33%	4 (80.00)	3 (30.00)	-
34–67%	0 (0.00)	5 (50.00)	-
68–100%	0 (0.00)	0 (0.00)	-
All dates are analysed by fisher's precision probability test			

Multivariate analysis indicated that male sex (HR: 2.896, P = 0.048), peritumoral edema (HR: 6.990, P = 0.001), absence of hypointensity on T2W-MRI (HR: 3.753, P = 0.002) and maximum diameter > 2.5 cm (HR: 3.484, P = 0.006) predicted RGM. (Table 3).

Table 3
Multivariate analysis of characteristics

	Univariable			Multivariable		
Characteristics	HR	95% CI	P value	HR	95% CI	P value
Sex (male)	2.285	1.331–4.362	0.001	2.896	1.008–8.326	0.048
Age (<60yrs)	0.746	0.525–1.020	0.068	0.859	0.398–1.853	0.698
Edema in MRI within follow-up duration (present)	5.998	2.594–15.240	0.000	6.990	2.140–22.840	0.001
Size (maximum diameter)						
> 2.5 cm vs<2.5 cm	2.079	1.422–3.194	0.000	3.484	1.437–8.475	0.006
<2.5 cm vs > 2.5 to ≤ 4.0 cm	0.469	0.283–0.721	0.000			
<2.5 cm vs > 4.0 cm	0.517	0.233–0.927	0.021			
<2.5 cm vs > 4.0 cm	1.103	0.454–2.374	0.823			
Hypointense in T2W-MRI						
0 vs others	1.582	1.194–2.099	0.002	3.753	1.611–8.742	0.002
0 vs 0–33%	1.613	1.188–2.157	0.003			
0 vs 34–67%	1.264	0.630-2.000	0.469			
0 vs 68–100%	1.932	0.984–2.644	0.090			
0–33% vs 34–67%	0.784	0.369–1.225	0.343			
0–33% vs 68–100%	1.198	0.615–1.620	0.659			
34–67% vs 68–100%	1.528	0.711–3.122	0.333			
Cox proportional hazards model was used in multivariate analysis						

Discussion

A uniform definition of SGM and RGM should be established

The growth pattern of meningioma varies, and previous studies have indicated that meningioma can stop growing in a long time or follow exponential or linear growth patterns [5, 6]. Hence, meningioma remaining 'stable' for one or two years may not actually be stable. We found that almost all meningiomas that remained stable for 4 years did not grow evidently during subsequent observation, so we defined SGM as tumors that did not meet the rapid growth standard for at least 4 years in this research. In addition, because the initial volume of meningioma could be large or small, defining the tumor growth rate only by absolute volume growth may mistakenly classify some tumors with small initial volumes as slow-growing meningioma. In this study, we defined the absolute growth rate of ≥ 2 cm^3/year or absolute growth rate ≥ 1 cm^3/year + relative growth rate $\geq 30\%$/year as the criterion defining RGM. Considering that the definition of SGM and RGM could seriously affect the analysis results, a uniform and widely accepted definition should be considered in the future.

Meningioma of males may grow faster

Several previous studies reported that RGM was more common in male patients [3, 4, 7]. In our results, meningioma was associated with a 2.285-fold higher risk and a 2.896-fold higher risk of RGM in male patients than in female patients in univariate and multivariable analyses ($P = 0.001$, $P = 0.048$, respectively). However, a significant difference was not found in a meta-analysis (volumetric analysis, $P = 0.107$; maximum diameter analysis, $P = 0.662$) [8].

Larger meningiomas tend to grow rapidly

Some reports have observed that large meningiomas seem to grow faster than small ones [3, 4, 9, 10]. Meningiomas with diameters of > 2.5 to ≤ 4.0 cm had an 8.18-fold increased risk compared with smaller ones, while those larger than 4 cm had a 50.31-fold increased risk [4]. In the current study, we found that tumors larger than 2.5 cm had a higher risk of growing rapidly (HR: 3.484, $P = 0.006$).

Peritumoral edema is a high-frequency event when meningioma grows rapidly

Peritumoral edema strongly correlated with rapid growth meningioma has been reported in previous studies [3, 4, 6, 7]. Lee et al. reported that 42.4% of all 59 rapidly growing meningiomas (volume ≥ 2 cm^3/year) presented edema, while only 12.1% of 173 slowly growing meningiomas (volume < 2 cm^3/year) presented edema (HR: 1.96, $P < 0.001$) [4]. Another report observed that meningioma with peritumoral edema has a 6.27 times higher risk of predicting progression (volume ≥ 2 cm^3/year or volume ≥ 1 cm^3/year + growth rate $\geq 30\%$/year) than meningioma without ($P < 0.001$). Similarly, in the current study, we also found that peritumoral edema was significantly associated with rapidly growing meningioma (Fig. 1a-d) in univariable and multivariable analyses (HR: 5.998, $P = 0.000$; HR: 6.990, $P = 0.001$, respectively). In the subgroup analysis based on tumor size, among tumors with a maximum

diameter ≤ 2.5 cm, 4 (10.53%) RGMs presented peritumoral edema, while no SGMs were present (P = 0.014). However, no significant difference was found among the other subgroups (> 2.5 to ≤ 4.0 cm subgroup, P = 1.000; >4.0 cm subgroup, P = 1.000). For meningioma, peritumoral edema not only correlated with a rapid growth rate but was also associated with a high ki-67 level, malignant meningioma, hemangioma meningioma, brain invasion, mutational burden and symptom progression [11–14]. Considering the importance of peritumoral edema in meningioma, it should be taken into account when making treatment decisions, especially in small meningiomas.

Without hypointensity in T2W-MRI associated with RGM

Our study indicated that meningiomas without hypointensity on T2W-MRI tend to grow rapidly, which is similar to several other articles [3, 4, 8, 15, 16]. A meta-analysis indicated that meningioma without hypointensity on T2W-MRI has a 2.75-fold risk of being RGM (P < 0.001) [8]; similarly, a 3.753-fold risk was found in our study in the multivariable analysis (P = 0.002). However, we did not find a significant difference between various degrees of hypointensity on T2W-MRI (Table 3). The subgroup analysis showed that the prediction ability of hypointensity in T2W-MRI was suitable for meningiomas of different sizes (Table 2). Different internal characteristics of tumors will cause different MRI information. In contrast, MRI information can also reflect the internal characteristics of tumors to a certain extent. Texture features could help to distinguish the grade and brain invasion of meningioma [17–20]. Here, the hypointensity in T2W-MRI seems to reflect the growth potential of the tumor to some extent. Perhaps, using radiomics could provide more accurate information on the growth potential of meningiomas.

Limitations Of This Study

This is a retrospective analysis in a single institute. The strict definition of slow-growing meningioma avoids erroneously dividing RGM into RGM, but some slow-growing meningioma was inevitably omitted. On the other hand, many of the larger meningiomas were surgically removed without follow-up when they were first discovered, so our study collected a very limited number of larger meningiomas in both groups. Most importantly, many patients did not receive surgical treatment, so we did not collect the pathological results of the tumor.

Conclusions

Male sex, peritumoral edema, larger size and absence of hypointensity on T2W-MRI may indicate the potential for rapid growth of meningiomas. However, the results of different studies are quite different. Larger prospective studies are necessary based on a uniform and widely accepted definition of the growth speed of meningioma in the future.

Declarations

Funding

No funds, grants, or other support were received during the preparation of this manuscript.

Conflict of interest

The authors declares that they have no conflict of interest to disclose.

Author contributions

Lei He made research design. Jianing Yang, Yanpeng Zhou and Jiaxiang Wang did the data collection. Lei He, Chunyao Zhou and Qiang Zhu did the data analysis. Lei He, Ziwen Fan and Yukun Liu did the data interpretation. Lei He wrote the report. Yuchao Liang and Lei Wang reviewed and approved the paper.

Data availability

The dataset is available upon reasonable request.

Ethical approval

This clinical study was approved by the ethics committee at Beijing Tiantan Hospital, Capital Medical University.

References

1. Goldbrunner R, Stavrinou P, Jenkinson MD et al (2021) EANO guideline on the diagnosis and management of meningiomas. Neuro-Oncology 23: 1821-34. https://doi.org/10.1093/neuonc/noab150
2. Apra C, Peyre M, Kalamarides M (2018) Current treatment options for meningioma. Expert Rev Neurother 18: 241-9. https://doi.org/10.1080/14737175.2018.1429920
3. Islim AI, Kolamunnage-Dona R, Mohan M et al (2020) A prognostic model to personalize monitoring regimes for patients with incidental asymptomatic meningiomas. Neuro-Oncology 22: 278-89. https://doi.org/10.1093/neuonc/noz160
4. Lee EJ, Kim JH, Park ES et al (2017) A novel weighted scoring system for estimating the risk of rapid growth in untreated intracranial meningiomas. Journal of Neurosurgery 127: 971-80. https://doi.org/10.3171/2016.9.Jns161669
5. Nakasu S, Fukami T, Nakajima M, Watanabe K, Ichikawa M, Matsuda M (2005) Growth pattern changes of meningiomas: Long-term analysis. Neurosurgery 56: 946-54. https://doi.org/10.1227/01.Neu.0000157958.20215.7f
6. Hashiba T, Hashimoto N, Izumoto S et al (2009) Serial volumetric assessment of the natural history and growth pattern of incidentally discovered meningiomas Clinical article. Journal of Neurosurgery 110: 675-84. https://doi.org/10.3171/2008.8.Jns08481
7. Kasuya H, Kubo O, Tanaka M, Amano K, Kato K, Hori T (2006) Clinical and radiological features related to the growth potential of meningioma. Neurosurgical Review 29: 293-6.

https://doi.org/10.1007/s10143-006-0039-3

8. Zeng L, Liang P, Jiao J, Chen J, Lei T (2015) Will an Asymptomatic Meningioma Grow or Not Grow? A Meta-analysis. Journal of Neurological Surgery Part a-Central European Neurosurgery 76: 341-7. https://doi.org/10.1055/s-0034-1543959
9. Deguchi S, Nakashima K, Nakasu Y et al (2020) A practical predictor of the growth potential of benign meningiomas: Hypointensity of surface layer in T2-weighted magnetic resonance imaging. Clinical Imaging 62: 10-6. https://doi.org/10.1016/j.clinimag.2020.01.009
10. Nakasu S, Nakasu Y (2020) Natural History of Meningiomas: Review with Meta-analyses. Neurologia Medico-Chirurgica 60: 109-20. https://doi.org/10.2176/nmc.ra.2019-0213
11. Gill CM, Loewenstern J, Rutland JW et al (2021) Peritumoral edema correlates with mutational burden in meningiomas. Neuroradiology 63: 73-80. https://doi.org/10.1007/s00234-020-02515-8
12. Ibe M, Jimbo M, Yamamoto M, Umebara Y, Hagiwara S, Kubo O (1996) MIB-1 staining index and peritumoral brain edema of meningiomas. Cancer 78: 133-43. https://doi.org/10.1002/(sici)1097-0142(19960701)78:1<133::Aid-cncr19>3.0.Co;2-0
13. Mattei TA, Mattei JA, Ramina R, Aguiar PH, Plese JP, Marino R, Jr. (2005) Edema and malignancy in meningiomas. Clinics (Sao Paulo, Brazil) 60: 201-6. https://doi.org/10.1590/s1807-59322005000300004
14. Osawa T, Tosaka M, Nagaishi M, Yoshimoto Y (2013) Factors affecting peritumoral brain edema in meningioma: special histological subtypes with prominently extensive edema. Journal of Neuro-Oncology 111: 49-57. https://doi.org/10.1007/s11060-012-0989-y
15. Hunter JB, Yawn RJ, Wang R et al (2017) The Natural History of Petroclival Meningiomas: A Volumetric Study. Otology & Neurotology 38: 123-8. https://doi.org/10.1097/mao.0000000000001260
16. Zeidman LA, Ankenbrandt WJ, Du H, Paleologos N, Vick NA (2008) Growth rate of non-operated meningiomas. Journal of Neurology 255: 891-5. https://doi.org/10.1007/s00415-008-0801-2
17. Ke C, Chen H, Lv X et al (2020) Differentiation Between Benign and Nonbenign Meningiomas by Using Texture Analysis From Multiparametric MRI. Journal of Magnetic Resonance Imaging 51: 1810-20. https://doi.org/10.1002/jmri.26976
18. Kandemirli SG, Chopra S, Priya S et al (2020) Presurgical detection of brain invasion status in meningiomas based on first-order histogram based texture analysis of contrast enhanced imaging. Clinical Neurology and Neurosurgery 198. https://doi.org/10.1016/j.clineuro.2020.106205
19. Lu Y, Liu L, Luan S, Xiong J, Geng D, Yin B (2019) The diagnostic value of texture analysis in predicting WHO grades of meningiomas based on ADC maps: an attempt using decision tree and decision forest. European Radiology 29: 1318-28. https://doi.org/10.1007/s00330-018-5632-7
20. Al-Kadi OS (2010) Texture measures combination for improved meningioma classification of histopathological images. Pattern Recognition 43: 2043-53. https://doi.org/10.1016/j.patcog.2010.01.005

Figures

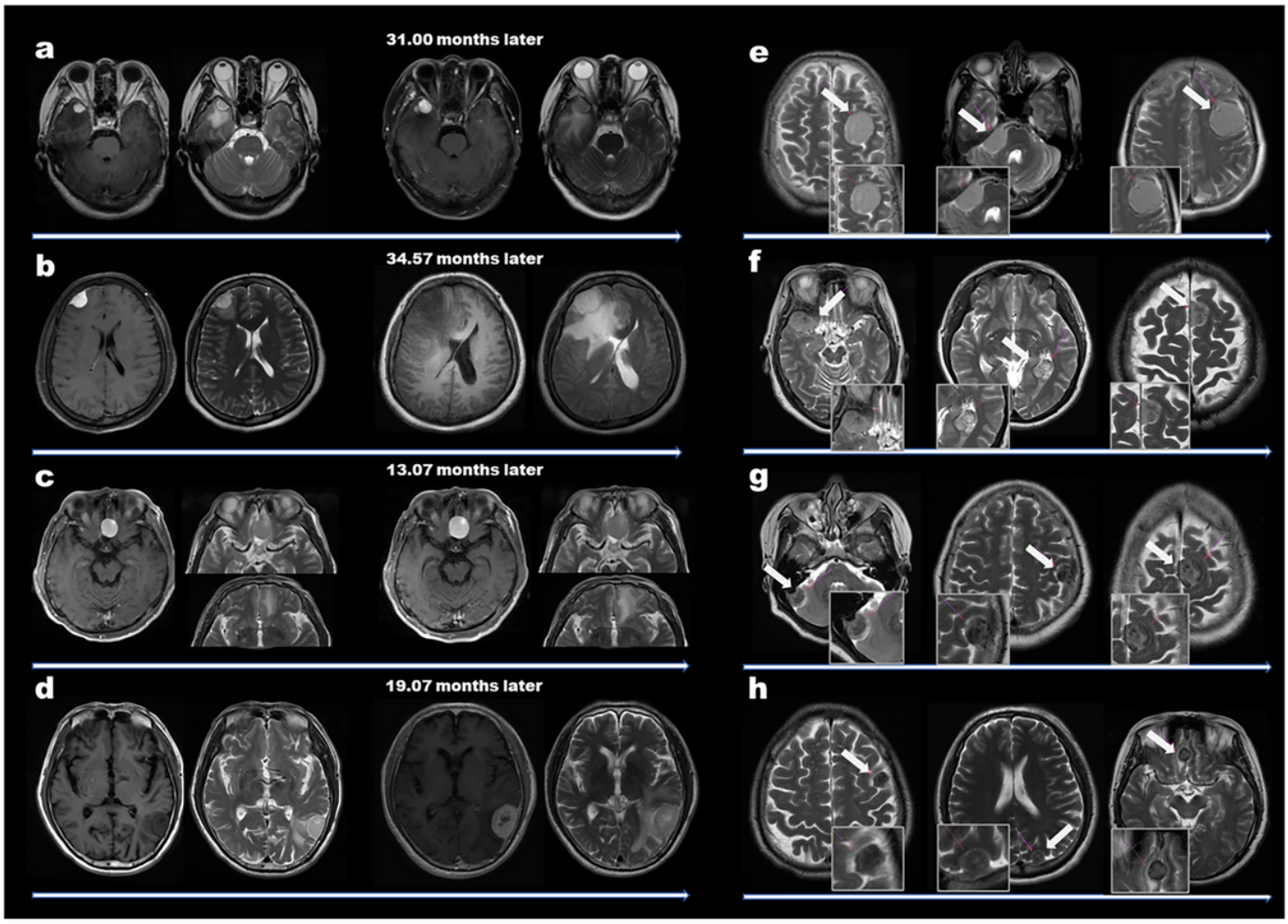

Figure 1

a-d, Tumors, with peritumoral edema and absence of hypointensity on T2W-MRI, significantly increased within a short term. **e-h**, The percentage of hypointensity on T2W-MRI. **e** 0%, **f** 0–33%, **g** 34–67%, **h** 68 – 100%.

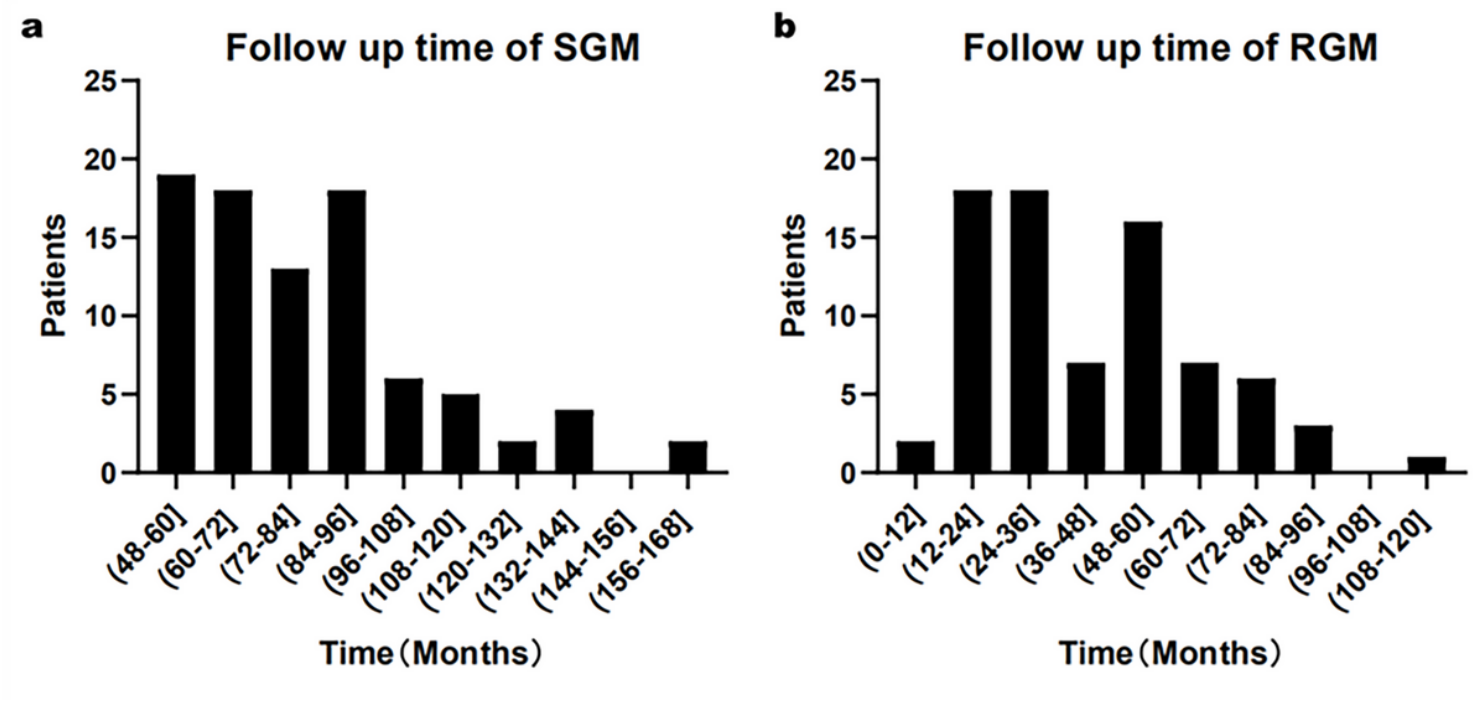

Figure 2

The follow up time of SGM (**a**) and RGM (**b**).

Figure 3

Peritumoral edema presented when tumors rapidly grow.