Long-term radiographic and clinical outcomes in patients undergoing transforaminal endoscopic lumbar discectomy: a propensity score matching study

Guanzhang Mu
Peking University First Hospital

Lei Yue
Peking University First Hospital

Haolin Sun (sunhaolin@vip.163.com)
Peking University First Hospital

Research Article

Keywords: Endoscopic discectomy, Spinal surgery, Minimally invasive, Lumbar disc herniation

Posted Date: June 15th, 2022

DOI: https://doi.org/10.21203/rs.3.rs-1740115/v1

Abstract

Background

Percutaneous Endoscopic Transforaminal Discectomy (PETD) is an evolving technique for spinal disorders. But what comes along with the widespread use of PETD are treatment related side-effects. The evidence regarding the long-term effects of PETD is needed. Our study aimed to fill the knowledge gap of long-term clinical and radiographic effects of PETD on lumbar disc herniation.

Methods

Radiographic and clinical data of patients undergoing TELD in our institution from January 2015 to January 2019 were retrospectively collected. LDH outpatients who had not received surgical treatment during the same period were 1:1 matched by propensity score matching as the conservative group. The radiographic parameters of the two groups at baseline and at the last follow-up (≥ 24 months) were analyzed. For the TELD group, patient-reported clinical outcomes and the incidence of reoperation were analyzed.

Results

A total of 47 patients in the TELD group were included in this study, and 47 patients in the conservative group were matched by propensity score matching. The disc height of the TELD group at the last follow-up was lower than that at the baseline ($P < 0.001$), and lower than that of the conservative group at the last follow-up ($P < 0.05$). The disc degeneration grade of the TELD group at the last follow-up was greater than that at the baseline, and greater than that of the conservative group at the last follow-up. There was no significant difference in the facet joint degeneration in the TELD group between the baseline and the last follow-up, and between the TELD group and the conservative group at the last follow-up ($P > 0.05$). The pain intensity and disability score in the TELD group at 3-month follow-up and at the last follow-up were significantly lower than those at the baseline ($P < 0.001$). Six patients in the TELD group required additional surgery during the follow-up period.

Conclusion

The disc height of the operated level was significantly reduced and the disc degeneration was significantly aggravated in TELD-treated patients at the long-term follow-up; in contrast, the facet joint degeneration did not show significant aggravation. Despite the satisfying therapeutic results, patients undergoing TELD should still be informed of the risk of reoperation.

Introduction

Over the past several decades, full-endoscopic discectomy (FED) has undergone significant technological maturity, and its indications have expanded from lumbar disc herniation (LDH) to thoracic and cervical disc herniation [1, 2]. Compared with open spine surgery, FED has the advantages of less invasiveness, less trauma, faster recovery, and less impact on adjacent intervertebral discs [3, 4]. However, the widespread use of FED is associated with certain complications, and previous studies have shown that FED procedure per se could result in biomechanical deterioration [5–7]. The long-term follow-up for FED is anticipated to examine clinical efficacy, explore postoperative morphological changes, and timely detect complications. Currently, most of the long-term FED follow-up results are limited to patient-reported clinical outcomes, while few studies have investigated the long-term postoperative radiographic changes. Therefore, a long-term follow-up involving both radiographic and clinical analysis is needed to better understand its cost-effectiveness.

The basic unit of lumbar spine movement includes two adjacent vertebral bodies and the connecting structure between them. The connecting structure refers to the three-joint complex (TJC), composed of the intervertebral disc and the facet joints on both sides [8]. Transforaminal endoscopic lumbar discectomy (TELD)—a common full-endoscopic lumbar discectomy technique, which is characterized by partial removal of the intervertebral disc and preservation of the facet joint—may be optimal for observing postoperative morphological changes in the TJC. The purpose of this study was to investigate the postoperative radiographic changes in the TJC and the clinical outcomes after at least 2-year follow-up after TELD.

Materials And Methods

This retrospective study was approved by the Ethics Committee of Peking University First Hospital (2021 – 473), and the subjects in this study were exempted from informed consent. This study was conducted and reported in accordance with the STROBE statement [9].

Patients

We included patients with a single-level LDH, who had been treated at our institution from January 2015 to January 2019, with a minimum of 2-year follow-up. The patients were divided into two groups based on whether they received TELD (the TELD group) or conservative treatment (the conservative group). Patients with spinal stenosis, spondylolisthesis, spine trauma, ankylosing spondylitis, spinal infection, spinal tumor, or history of a previous spine surgery were excluded. The diagnosis of LDH was consistently made by the same group of surgeons based on clinical manifestations, physical examination, and magnetic resonance imaging (MRI) findings.

Radiographic parameters

Radiographic parameters were evaluated on MRI (3T GE Discovery MR750, Waukesha, WI, USA), and all of the images were acquired in a supine position in CTL-spine coil, field of view (FOV) of 310 mm, and 16-

sagittal slices with 3 mm thickness. The radiographic parameters included disc height [10], disc protrusion size, disc protrusion location [11], disc degeneration grade [12], and facet joint degeneration grade [13]. The measurement methods are shown in Fig. 1.

Clinical outcomes

Clinical outcomes were collected and analyzed only for the patients in the TELD group, considering that the conservative group was not clinically comparable because it included asymptomatic patients. Clinical outcomes were Oswestry Disability Index (ODI) and visual analogue scale (VAS) before surgery, 3 months after surgery, and at the last follow-up and reoperation.

The TELD procedure

The TELD procedure was performed under spinal anesthesia with 6 mL of hypobaric ropivacaine (0.125%). Then, with patients in a prone position, surgical draping was performed on a routine basis. A puncture needle was introduced from the entry point, 8–13 cm from the midline, and placed into the disc space through Kambin's triangle. Then, a guide wire was inserted through the puncture needle under fluoroscopic guidance, and an 8-mm incision was made at the entry site. A cannulated obturator was inserted along the guide wire; after touching the ventral edge of the superior articular process, a working cannula was inserted along the obturator and the position of the cannula was ascertained by fluoroscopy. Next, endoscope equipment (TESSYS system; Joimax, Germany) was inserted through the cannula. The herniated disc and fibrotic scar tissues were removed using an endoscopic forceps and ablation device (Trigger-Flex, Elliquence, USA). Annulus modulation was performed after the herniated fragment was completely removed, and then the endoscope was removed and a sterile dressing was applied with a single stich suture. Figure 2 shows the schematic and key steps of the TELD procedure.

Statistical analysis

All of the data were anonymized and entered into an Excel spreadsheet (Microsoft, Redmond, WA). Continuous variables were described as the mean and standard deviations (SDs) if normally distributed, or median and interquartile range if not normally distributed. For continuous variables with a normal distribution, independent-sample *t*-test was used for intergroup comparisons, while paired-sample *t*-test was used for intragroup comparison. For continuous variables not complying with a normal distribution, the Mann–Whitney *U* test was used for intergroup comparisons, and Wilcoxon test was used for intragroup comparison. Categorical variables were described as frequencies and percentages, and were analyzed with Fisher's exact test or the chi-square test. All of the statistical analyses were done using SPSS 27.0 (IBM, Armonk, NY). $P < 0.05$ was considered to be statistically significant.

The propensity score was determined by multivariate logistic regression, and the finally included variables were age, gender, herniation level, facet joint degeneration grade, and disc degeneration grade. After calculating the propensity score of each subject, the conservative group was matched in a 1:1 ratio to the TELD group using nearest neighbor matching with a 0.12 caliper width. Weighted Kappa analysis was used to determine the interobserver agreement on radiographic measurements. The Kappa

coefficient was interpreted as almost perfect (0.81–1.00), substantial (0.61–0.80), moderate (0.41–0.60), fair (0.21–0.4), and none to slight (0.00–0.20) [14].

Results

Baseline demographic characteristics and radiographic parameters

From January 2015 to January 2019, 256 patients who had received single-level TELD surgery were screened, and 47 eligible patients were finally enrolled. A total of 47 eligible outpatients who had not received surgery were matched as the conservative group. Demographic characteristics and radiographic parameters were similar in the two groups at baseline, except for the distribution of disc protrusion size (P = 0.001) (Table 1).

Table 1. Baseline demographic characteristics and radiographic parameters.

		TELD group (n = 47)	Conservative group (n = 47)	P
Age		43.49±14.79	48.38±12.56	0.087
BMI, kg/m^2		23.80±3.77	23.44±2.56	0.585
Gender	Female	22 (46.81%)	29 (61.70%)	0.147
	Male	25 (53.19%)	18 (38.30%)	
Herniation level	L2/3	1 (2.12%)	3 (6.38%)	0.097
	L3/4	3 (6.38%)	1 (2.12%)	
	L4/5	17 (36.17%)	26 (55.32%)	
	L5/S1	26 (55.32%)	17 (36.17%)	
Disc protrusion location	a	20 (42.55%)	27 (57.45%)	0.201
	b	20 (42.55%)	14 (29.79%)	
	c	7 (14.90%)	6 (12.77%)	
Disc protrusion size	1	1	0	0.001
	2	27	43	
	3	19	4	
Disc height, mm		10.08±1.86	9.62±1.80	0.223

Abbreviations: BMI, body mass index.

Radiographic outcomes

Intragroup comparisons showed that the disc height in the TELD group at the last follow-up was significantly lower than that at the baseline (8.64±1.88 vs. 10.08±1.86, P = 0.000), while the disc height in the conservative group was similar between the baseline and the last follow-up (9.49±1.87 vs. 9.62±1.80, P=0.164). Intergroup comparison showed that the disc height at the last follow-up was smaller in the TELD group than in the conservative group (8.64±1.88 vs. 9.49±1.87, P = 0.031). Intragroup comparison showed that disc protrusion size in the TELD group at the last follow-up was significantly smaller than that at the baseline (P = 0.000), while disc protrusion size in the conservative group was similar between the baseline and the last follow-up (P = 0.655).

The disc degeneration grade at the last follow-up was greater than that at the baseline in the TELD group (P = 0.000), while disc degeneration grade in the conservative group was similar between the baseline and the last follow-up (P = 0.713). Intergroup comparison at the last follow-up showed that the disc degeneration grade in the TELD group was larger than that in the conservative group (P = 0.033). As for facet joint degeneration grade in both groups, no differences were observed between the last follow-up and the baseline, and the facet joint degeneration grade was similar in both groups at the last follow-up (Table 2).

Table 2. Degeneration grade of disc and facet joint in the two groups

	TELD group (n = 47)			**Conservative group (n = 47)**			
Grade	Baseline	Last FU	P1	Baseline	Last FU	P2	P3
Disc degeneration							
1	0	0	0.000	1	1	0.713	0.033
2	4	0		0	1		
3	26	14		23	18		
4	15	26		22	27		
5	2	7		1	0		
FJ degeneration							
0	6	3	0.117	3	1	0.207	0.451
1	12	13		18	14		
2	20	17		19	26		
3	9	14		7	6		

Notes: P1 represents the intragroup comparison of the TELD group; P2 represents the intragroup comparison of the conservative group; P3 represents the intergroup comparison between the TELD group and the conservative group at the last follow-up.

Abbreviations: FJ, facet joint; FU, follow-up; TELD, transforaminal endoscopic lumbar discectomy.

Clinical outcomes

In the TELD group, the VAS score and ODI score at 3 months after surgery and at the last follow-up significantly decreased compared with the baseline ($P < 0.001$) (Figure 3). In addition, four patients in the TELD group underwent additional surgery for re-herniation at the operated level, and two patients underwent additional surgery for adjacent segment disease during the follow-up period.

Figure 3. The follow-up results of clinical outcomes in the TELD group: (A) VAS score of pain decreased significantly at 3 months after surgery and at the last follow-up, compared with the baseline; (B) ODI score at 3 months after surgery and at the last follow-up also significantly decreased compared with the baseline; ****: $P < 0.001$.

Abbreviations: FU, follow-up; TELD, transforaminal endoscopic lumbar discectomy.

Interobserver agreement assessment

The interobserver agreement on radiographic measurements was “almost perfect” for disc protrusion size, and “substantial” for disc degeneration, facet joint degeneration, and disc protrusion location (Table 3).

Table 3. Interobserver agreement of radiographic parameters.

	Proportion of same opinion	Weighted kappa value	Consistency
Disc degeneration	79.26%	0.698	Substantial
FJ degeneration	74.47%	0.705	Substantial
Disc protrusion size	90.43%	0.821	Almost perfect
Disc protrusion location	85.11%	0.792	Substantial

Abbreviations: FJ, facet joint.

Discussion

The current study investigated the long-term impact of TELD on patients with LDH, in terms of both radiographic and clinical outcomes. Our results showed that after at least 2 years of follow-up, patients undergoing TELD achieved satisfying clinical outcomes; however, they experienced significant loss of disc height and aggravation of disc degeneration at the operated disc level. Our results also showed that the TELD procedure did not cause aggravation of facet joint degeneration at the long-term follow-up. Moreover, 12.77% of TELD-treated patients required additional surgery during the follow-up period.

Only few case series have reported long-term follow-up radiographic outcomes after FED, and the disc height change was the most studied parameter. The studies by Lin et al. and Sharma et al. unanimously found that the disc height remained unchanged at 1-year follow-up compared with baseline[15, 16]. However, the results from studies with a larger sample size and longer follow-up showed different findings: Mahatthanatrakul et al. reported a 67.7% reduction in disc size and 8.4% reduction in disc height at 12 months after TELD (31 patients) [17]; the 11.22-year follow-up results by Eun et al. (38 patients) suggested that the disc height ratio was 81.54% of the original disc height [18]; and the seven-year follow-up outcomes by Li et al. (42 patients) showed that the postoperative disc height was 84.52%±5.66% of the preoperative disc height [19]. However, these results are still not convincing due to the lack of a nonoperated comparator. We designed the control group by propensity score matching LDH outpatients, and further ascertained the disc height loss effect of FED. However, though the disc height was reduced after FED, the reduction was still not as great as that of traditional surgery at long-term follow-up [20, 21].

Our results also suggested that the disc protrusion size was reduced after FED, which was the basis of the therapeutic efficacy; however, such anticipated efficacy came at a cost of disc degeneration and risk of re-herniation. Similarly, Lin et al. showed significant disc degeneration at 1-year follow-up after FED. The results from percutaneous endoscopic cervical discectomy also showed progression of degeneration at the corresponding level at long-term follow-up [22]. A major limitation of previous results of degeneration grading is that it was based on subjective grading methods. To solve this problem, we used Pfirrmann grading for evaluation of disc degeneration and Weishaupt grading for evaluation of facet joint degeneration according to suggestions from Kettler et al. [23], and we applied interobserver agreement to increase the reliability of the results. We showed that disc size grade was significantly reduced compared with the baseline in 70.21% of TELD-treated patients, which is in line with previous studies [15, 22]. Moreover, re-herniation of the index level occurred in 8.51% of TELD-treated patients, which is similar to the results of a previous meta-analysis (7.92%) [24].

TELD often requires foraminal reamer or drill to remove a part of superior articular process (SAP) to enlarge the foramen [25]. Therefore, the procedure poses damage to the intervertebral disc and the SAP, which may cause mechanical deterioration of the spine. This is because both discectomy and foraminotomy cause the spinal instability, and the degree of such an effect is related to the amount of the removed disc [6, 26, 27]. Moreover, previous studies have shown that disc removal may also affect the stability of the TJC of the adjacent levels [28]. However, the studies on the effect of discectomy on spinal biomechanics are mostly finite element analyses. In contrast, our study investigated the long-term morphological changes in the TJC, and the results indicated aggravated disc degeneration, reduced disc height, and preserved the facet joints. Additionally, adjacent segment disease occurred in two TELD-treated patients, which from the clinical angle verified the impact of discectomy on the adjacent levels.

The advantages of this study are as follows: the propensity score method was used to match patients who did not undergo surgery as a control group to increase the reliability of radiographic results, and we adopted interobserver agreement to increase the internal consistency of imaging measurements. However, several limitations in our study should be noted. First, the retrospective nature and the small

sample size compromised the reliability of the results. Then, the clinical outcomes of the conservative group were not collected or analyzed due to a considerable proportion of asymptomatic patients in the conservative group, which may have affected the credibility of clinical outcomes. Finally, the amount of disc removal is another factor affecting the radiographic changes after FED, but this information was not available in the current study [29].

Conclusion

The long-term follow-up results showed that TELD was associated with the disc height loss, disc degeneration aggravation, and facet joint integrity. In addition, although patients after TELD can achieve good long-term clinical symptom relief, clinicians should be alert to re-herniation at the operated level and adjacent segment disease caused by changes in the local biomechanical environment. Our results may provide a certain reference value for future clinical practice and research.

Abbreviations

TELD:Transforaminal endoscopic lumbar discectomy;LDH:Lumbar disc herniation; FED: Full-endoscopic disectomy ; LDH:lumbar disc herniation ; TJC:Three-joint complex ; MRI : magnetic resonance imaging;FOV:field of view;ODI : Oswestry Disability Index ; VAS:visual analogue scale ; SDs : standard deviations;SAP:superior articular process

Declarations

1、Ethics approval and consent to participate

This work is granted by Interdisciplinary clinical research project of Peking University First Hospital (Grant number: 2021CR31). Informed consent was obtained from all patients

2、Consent for publication

Not applicable

3、Availability of data and materials

All the datasets used during the study are not publicly available due to the data are confidential patient data but are available from the corresponding author upon reasonable request.

4、Competing interests

The authors declare that they have no competing interests

5、Funding

Not applicable

6 Authors' contributions

YL and MGZ conceived and designed the study,YL and MGZ collected the data. YL and MGZ analyzed and interpreted the patient data. YL wrote the paper.SHL are responsible for this article.All authors have read the journal policies and have no issues related to journal policies. All authors read and approved the final manuscript.

7 Acknowledgements

We thank LetPub (www.letpub.com) for its linguistic assistance during the preparation of this manuscript.

References

[1] Mayer HM, Brock M. Percutaneous endoscopic lumbar discectomy (PELD). Neurosurg Rev. 1993;16:115-20. http://doi.org/10.1007/bf00258242

[2] Ahn Y. A Historical Review of Endoscopic Spinal Discectomy. World Neurosurg. 2021;145:591-6. http://doi.org/10.1016/j.wneu.2020.08.008

[3] Ruetten S, Komp M, Merk H, Godolias G. Full-Endoscopic Interlaminar and Transforaminal Lumbar Discectomy Versus Conventional Microsurgical Technique: A Prospective, Randomized, Controlled Study. Spine. 2008;33.

[4] Chen C, Yuchi CX, Gao Z, Ma X, Zhao D, Li JW, et al. Comparative analysis of the biomechanics of the adjacent segments after minimally invasive cervical surgeries versus anterior cervical discectomy and fusion: A finite element study. J Orthop Translat. 2020;23:107-12. http://doi.org/10.1016/j.jot.2020.03.006

[5] Pan M, Li Q, Li S, Mao H, Meng B, Zhou F, et al. Percutaneous Endoscopic Lumbar Discectomy: Indications and Complications. Pain Physician. 2020;23:49-56.

[6] Li J, Xu C, Zhang X, Xi Z, Liu M, Fang Z, et al. TELD with limited foraminoplasty has potential biomechanical advantages over TELD with large annuloplasty: an in-silico study. BMC Musculoskelet Disord. 2021;22:616. http://doi.org/10.1186/s12891-021-04504-1

[7] Qian J, Yu SS, Liu JJ, Chen L, Jing JH. [Biomechanics changes of lumbar spine caused by foraminotomy via percutaneous transforaminal endoscopic lumbar discectomy]. Zhonghua Yi Xue Za Zhi. 2018;98:1013-8. http://doi.org/10.3760/cma.j.issn.0376-2491.2018.13.012

[8] Kong MH, Hymanson HJ, Song KY, Chin DK, Cho YE, Yoon DH, et al. Kinetic magnetic resonance imaging analysis of abnormal segmental motion of the functional spine unit. J Neurosurg Spine. 2009;10:357-65. http://doi.org/10.3171/2008.12.Spine08321

[9] von Elm E, Altman DG, Egger M, Pocock SJ, Gøtzsche PC, Vandenbroucke JP. The Strengthening the Reporting of Observational Studies in Epidemiology (STROBE) statement: guidelines for reporting observational studies. PLoS Med. 2007;4:e296. http://doi.org/10.1371/journal.pmed.0040296

[10] Jarman JP, Arpinar VE, Baruah D, Klein AP, Maiman DJ, Muftuler LT. Intervertebral disc height loss demonstrates the threshold of major pathological changes during degeneration. Eur Spine J. 2015;24:1944-50. http://doi.org/10.1007/s00586-014-3564-8

[11] Mysliwiec LW, Cholewicki J, Winkelpleck MD, Eis GP. MSU classification for herniated lumbar discs on MRI: toward developing objective criteria for surgical selection. Eur Spine J. 2010;19:1087-93. http://doi.org/10.1007/s00586-009-1274-4

[12] Pfirrmann CW, Metzdorf A, Zanetti M, Hodler J, Boos N. Magnetic resonance classification of lumbar intervertebral disc degeneration. Spine (Phila Pa 1976). 2001;26:1873-8. http://doi.org/10.1097/00007632-200109010-00011

[13] Weishaupt D, Zanetti M, Boos N, Hodler J. MR imaging and CT in osteoarthritis of the lumbar facet joints. Skeletal Radiol. 1999;28:215-9. http://doi.org/10.1007/s002560050503

[14] McHugh ML. Interrater reliability: the kappa statistic. Biochem Med (Zagreb). 2012;22:276-82.

[15] Lin RH, Chen HC, Pan HC, Chen HT, Chang CC, Tzeng CY, et al. Efficacy of percutaneous endoscopic lumbar discectomy for pediatric lumbar disc herniation and degeneration on magnetic resonance imaging: case series and literature review. J Int Med Res. 2021;49:300060520986685. http://doi.org/10.1177/0300060520986685

[16] Sharma SB, Lin G-X, Jabri H, Sidappa ND, Song MS, Choi KC, et al. Radiographic and clinical outcomes of huge lumbar disc herniations treated by transforaminal endoscopic discectomy. Clinical Neurology and Neurosurgery. 2019;185:105485. http://doi.org/https://doi.org/10.1016/j.clineuro.2019.105485

[17] Mahatthanatrakul A, Kotheeranurak V, Lin GX, Hur JW, Chung HJ, Kim JS. Comparative analysis of the intervertebral disc signal and annulus changes between immediate and 1-year postoperative MRI after transforaminal endoscopic lumbar discectomy and annuloplasty. Neuroradiology. 2019;61:411-9. http://doi.org/10.1007/s00234-019-02174-4

[18] Eun SS, Lee SH, Sabal LA. Long-term Follow-up Results of Percutaneous Endoscopic Lumbar Discectomy. Pain Physician. 2016;19:E1161-e6.

[19] Li X, Bai J, Hong Y, Zhang J, Tang H, Lyu Z, et al. Minimum Seven-Year Follow-Up Outcomes of Percutaneous Endoscopic Lumbar Discectomy for Lumbar Degenerative Disease. Int J Gen Med. 2021;14:779-85. http://doi.org/10.2147/ijgm.S293400

[20] Lee SH, Chung SE, Ahn Y, Kim TH, Park JY, Shin SW. Comparative radiologic evaluation of percutaneous endoscopic lumbar discectomy and open microdiscectomy: a matched cohort analysis. Mt Sinai J Med. 2006;73:795-801.

[21] Ren C, Qin R, Li Y, Wang P. Microendoscopic discectomy combined with annular suture versus percutaneous transforaminal endoscopic discectomy for lumbar disc herniation: a prospective observational study. Pain Physician. 2020;23:E713-E21.

[22] Lee JH, Lee SH. Clinical and radiographic changes after percutaneous endoscopic cervical discectomy: a long-term follow-up. Photomed Laser Surg. 2014;32:663-8. http://doi.org/10.1089/pho.2014.3806

[23] Kettler A, Wilke HJ. Review of existing grading systems for cervical or lumbar disc and facet joint degeneration. Eur Spine J. 2006;15:705-18. http://doi.org/10.1007/s00586-005-0954-y

[24] Ruan W, Feng F, Liu Z, Xie J, Cai L, Ping A. Comparison of percutaneous endoscopic lumbar discectomy versus open lumbar microdiscectomy for lumbar disc herniation: a meta-analysis. International journal of surgery. 2016;31:86-92.

[25] Pan Z, Ha Y, Yi S, Cao K. Efficacy of Transforaminal Endoscopic Spine System (TESSYS) Technique in Treating Lumbar Disc Herniation. Med Sci Monit. 2016;22:530-9. http://doi.org/10.12659/msm.894870

[26] Zöllner J, Rosendahl T, Herbsthofer B, Humke T, Eysel P. [The effect of various nucleotomy techniques on biomechanical properties of the intervertebral disk]. Z Orthop Ihre Grenzgeb. 1999;137:206-10. http://doi.org/10.1055/s-2008-1037394

[27] Prado M, Mascoli C, Giambini H. Discectomy decreases facet joint distance and increases the instability of the spine: A finite element study. Comput Biol Med. 2022;143:105278. http://doi.org/10.1016/j.compbiomed.2022.105278

[28] Cao R, He Y, Qian C, Ma L, Li J, Xi Z, et al. Negative biomechanical effects of large grade nuclectomy in the transforaminal endoscopic discectomy increased the risk of adjacent segment diseases: A finite element study. J Clin Neurosci. 2021;93:141-6. http://doi.org/10.1016/j.jocn.2021.09.014

[29] Heo JH, Kim CH, Chung CK, Choi Y, Seo YG, Kim DH, et al. Quantity of Disc Removal and Radiological Outcomes of Percutaneous Endoscopic Lumbar Discectomy. Pain Physician. 2017;20:E737-e46.

Figures

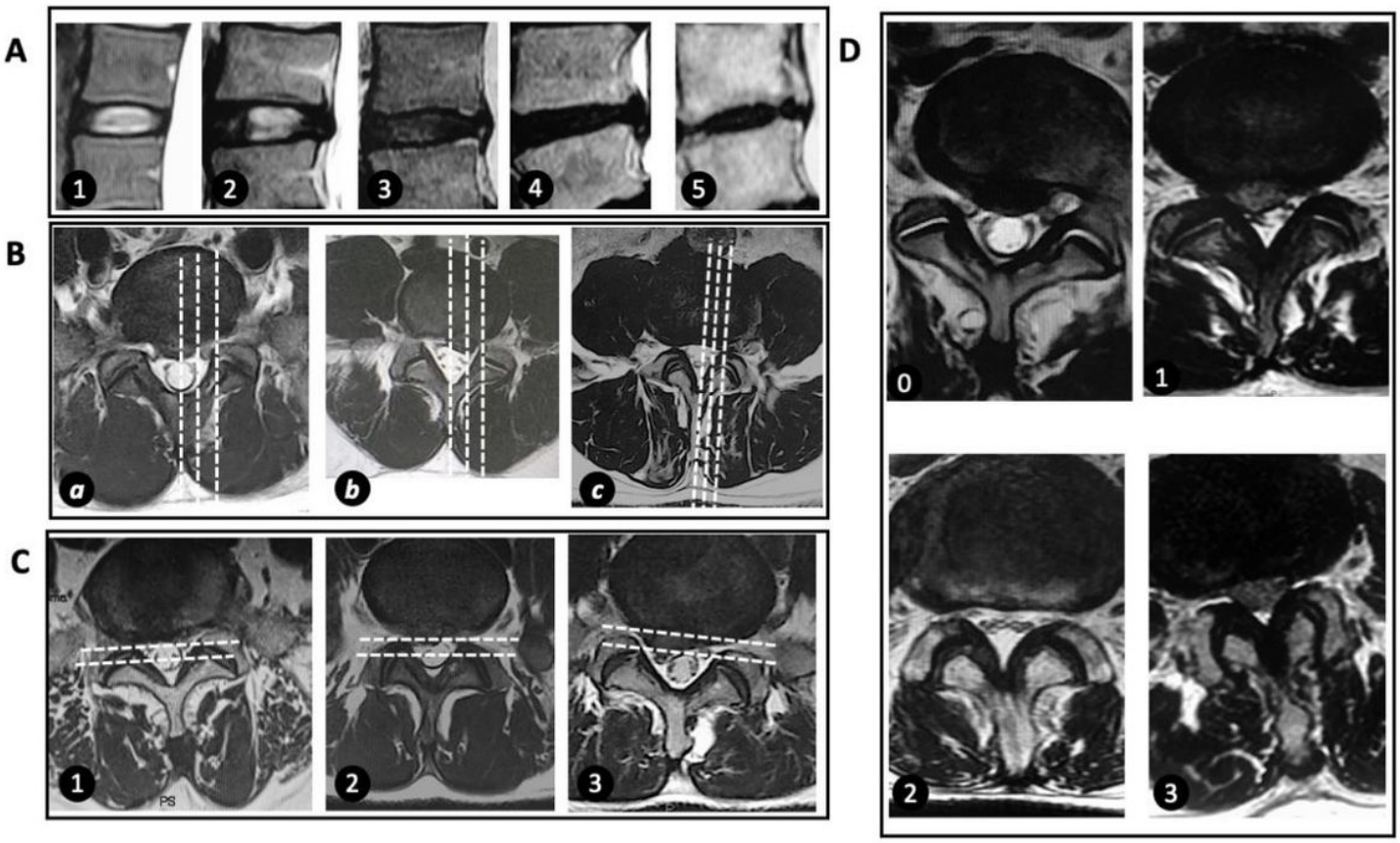

Figure 1

Schematic diagram of the imaging classification methods. (A) Disc degeneration grades 1, 2, 3, 4, and 5; (B) disc protrusion locations a, b, and c, and white dashed lines represents midline, 50% of the distance between midline and intra-facet line, and intra-facet line; (C) disc protrusion sizes 1, 2, and 3, and white dashed lines represents posterior edge of disc, 50% of the distance between posterior edge of disc and intra-facet line, and intra-facet line; (D) facet joint degeneration grades 0, 1, 2, and 3.

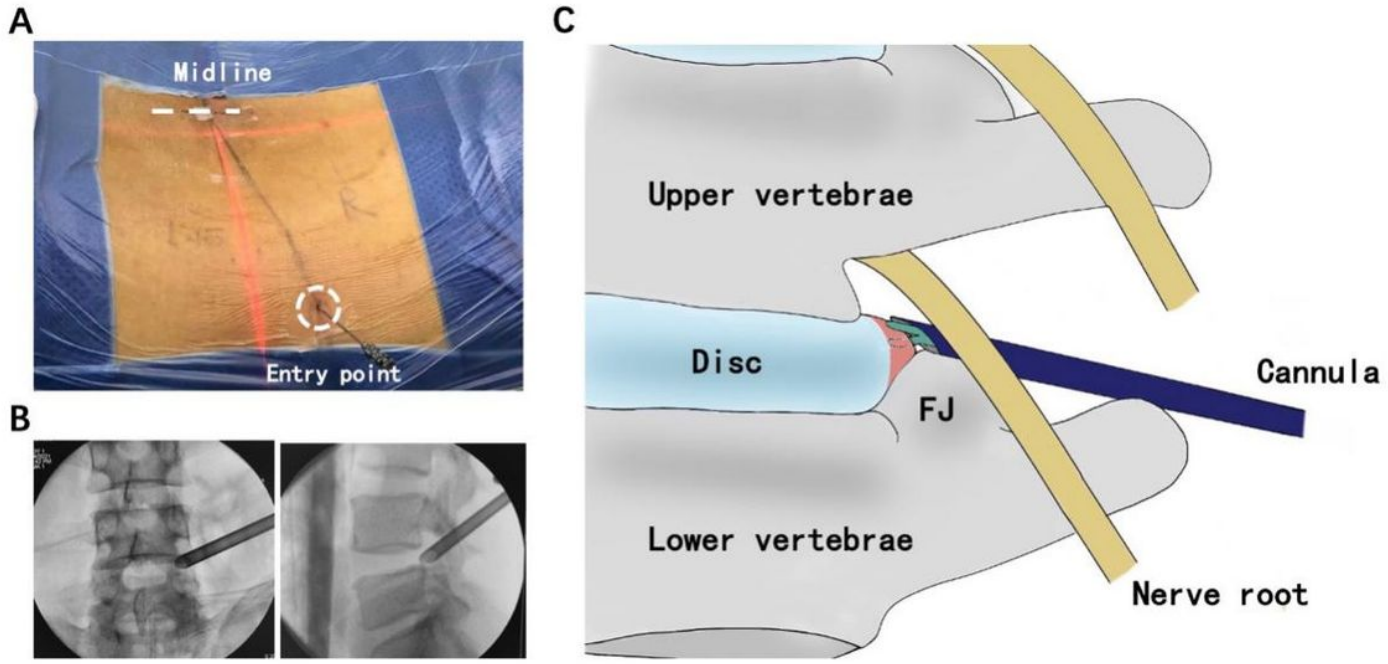

Figure 2

Illustration of the TELD procedure. (A) Surgical draping and entry point for an L4/5 TELD procedure; (B) working channel introduction under fluoroscopic guidance; (C) schematic diagram of the TELD procedure.

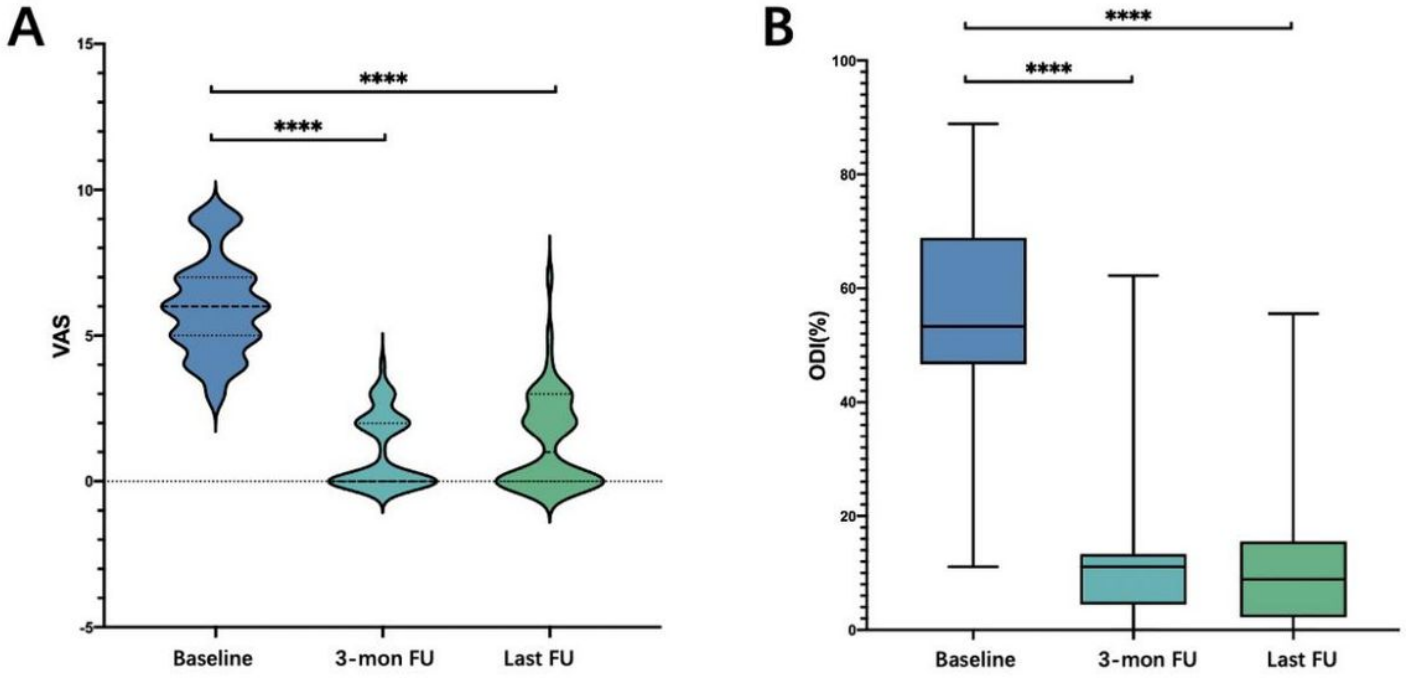

Figure 3

The follow-up results of clinical outcomes in the TELD group: (A) VAS score of pain decreased significantly at 3 months after surgery and at the last follow-up, compared with the baseline; (B) ODI score at 3 months after surgery and at the last follow-up also significantly decreased compared with the baseline; ****: $P < 0.001$.

Abbreviations: FU, follow-up; TELD, transforaminal endoscopic lumbar discectomy.