# The Eruption Patterns of The Teeth of Nigerian Local Pigs. Part 1: Profile of Deciduous Teeth

**Michael Efeturi Okandeji**
University of Ibadan Faculty of Veterinary Medicine
**Ayodeji David Lijoka**
University of Ibadan Faculty of Veterinary Medicine
**Folusho Ayobami Atiba**
University of Ibadan College of Medicine
**James Olukayode Olopade** ( jkayodeolopade@yahoo.com )
University of Ibadan https://orcid.org/0000-0002-3470-0801

**Research**

**Keywords:** Deciduous teeth, Dental Eruption, Local Pigs, Nigeria

**Posted Date:** February 4th, 2021

**DOI:** https://doi.org/10.21203/rs.3.rs-174623/v1

# Abstract

**Background:** The pigs, domesticated about 6000 years ago, are highly prolific omnivores belonging to the Family Suidae and Order artiodactyla along with their other hooved counterparts. They qualify as models for various translational research studies (including dental studies) because of their anatomical and physiological similarities to humans. There is however a dearth of information as regards the deciduous dental eruption profile (sequence and timing of eruption) of the Nigerian local pigs (NLP). This study was designed to determine the deciduous eruption profile in the NLP to assist in the management of the breed and in a bid to making the NLP more obvious as suitable animal models in dental research. A total of 51 healthy piglets (from postnatal day 1) were used for this. Their oral cavities were examined every other day for 29 weeks for signs of dental eruption. Looking at Mandibular (Md) and Maxillar (Mx) eruptions for Incisors (I), Canines(C), Premolars (P) and Molars (M), the modular sequence in the NIP was Md/ Mx I3(at birth), C (at birth) $\rightarrow$Md $I_1 \rightarrow$Md $P_3 \rightarrow$MxP$^3$ $\rightarrow$MxI$^1$ $\rightarrow$ Md $I_2$ $\rightarrow$Md$P_4$ $\rightarrow$MxP$^4$ $\rightarrow$MxP$^2$$\rightarrow$ Md $I_2$ $\rightarrow$MxI$^2$ .

**Result:** It was observed that variations in eruption timing exist amongst individuals and sexes while variation in eruption sequence exists between NLP and various breeds of pigs based on the literature.

**Conclusion:** The results of this study will be particularly important to farmers, and researchers into NLP especially those using pigs in Nigeria as a model for translation research.


# Background

The pig belongs to the Suidae family [6], and the order Artiodactyla, along with cattle, sheep, goats, camels, deer, giraffes, and hippopotamuses [11], with a worldwide distribution of about 500 breeds [22]. It displays enormous phenotypic diversity in terms of shape, color, size, production and reproduction abilities [19, 36, 37,]. Due to their anatomical and physiological similarities with humans, and the availability of disease models, pigs have been used as models in some biomedical and pharmacological studies [13, 25, 31, 32, 33,]. The pig's oral mucosa has been used to study the process of scar-free wound healing and drug permeability [5, 12, 14]. Pig models have also been used to study regenerative processes following periodontal stem cell application [24], dental implantations[18], bone renewal research [26], and regeneration of teeth and jaw bones [8, 38, 40].

The Nigerian local pigs (NLP) or the West African Dwarf pigs, are characterized by small body sizes with short foreheads, straight tails, elongated snouts and medium-sized, semi-erect ears. They have narrow body conformation with relatively long legs and slightly inclined rumps. They have predominantly black color coats, with others being brown, white and black or patchy and spotted [2, 3, 19]. NLPs are well adapted to local conditions and are commonly resistant to a variety of endemic parasitic and infectious diseases [20, 1].

Teeth are hard, whitish structures in the mouth of vertebrates, used for breaking down food. They are made up of tissues of varying density and hardness, such as enamel, dentine, and cementum [21].These structures surround a pulp cavity which consists of neurovascular bundles [34].

Mammalian dentition refers to the types;incisor, canine, premolar, and molar, shapes, number, and arrangement of teeth in the mouth of a given species, at a particular age[4].All pigs are diphyodonts with heterodont dentition[25].The deciduous dentition of the domestic pig is made up of 28 teeth (2×incisors (I)$^3/_3$, canine (C)$^1/_1$, premolars(P)$^3/_3$, molars(M)$^0/_0$), with the maxillary and mandibular third incisors and canines, being present at birth, as the needle teeth (Swindle, 2010). The deciduous teeth are thereafter replaced by a permanent set totalling 44 (2 × $I^3/_3$, $C^1/_1$, $P^4$ /4, M3/3)[30].

The eruption pattern of the deciduous teeth of several breeds of pigs have been reported, including Yorkshire pig[30],European wild pigs (*Sus scrofa*) [16],Large White pigs[29], and Miniature breeds of pigs[9, 28, 35].However, no information appears to be available on the dental eruption pattern of the deciduous teeth of the NLP. The aim of this work, therefore, was to study the pattern of eruption of the deciduous teeth of Nigerian local pigs (*Sus scrofa*), as part of our continuing effort to provide baseline information on dental eruption profiles and abnormalities amongst pigs in Nigeria.

## Materials And Method

# Animals and farm selection

A total of 5 NLPs were obtained from Gbogan, Ibarapa North West Local Government and Iseyin Local Government, Oyo state for this study. They were housed and adequately fed, with a combination of concentrate and brewery waste, in concrete pens at the piggery unit of the Teaching and Research farm, University of Ibadan. Water was also provided, *ad libitum.* An adult boar was used to mate the sows, naturally. A total of Fifty one (51) healthy piglets were used for thus study.

# Method

Observations were made thrice in a week, from birth until the eruption of the last deciduous tooth. Piglets were firmly held in dorsal or lateral recumbency and the mouth of the piglets were gently held open to visually examine all quadrants of the dental arches (right and left maxillary, right and left mandibular). Tooth eruption was considered to have occurred with the gingival penetration and emergence of any portion of the crown [27, 30].

# Statistical analysis

GraphPad Prism 5® was used for statistical analysis and data expressed as Mean ± S.E. Sequence of dental eruption was determined by calculating the mean values of eruption time of each tooth across all piglets and ordering the mean values in an increasing order.

## Results

The mean values and the age range of deciduous eruptions are as stated in Table 1 and pictural evidence of erupted teeth are seen in Figs. 1–9.

Female piglets (gilts) had lower mean values for eruption time, in comparison to the males (barrows). Results obtained showed that 50% (n = 5) of the teeth examined erupted earlier in the gilts when compared with the barrows. Similarly, the gilts completed their eruption in 60% (n = 6) of the teeth, ahead of the barrows. Only 10% (n = 1) of the teeth eruption was completed in the barrows, ahead of the gilts. These observations were, however, not statistically significant.

Staining of the needle teeth, from deep yellow to dark brown, was observed in some piglets, from every litter.

Bilateral polydonty of the third maxillary incisors (Fig. 9) was observed in two gilts while it was observed as a left unilateral occurrence in a barrow. These supernumerary teeth were located between the maxillary canine and the third incisor teeth in all affected piglets.

Table 1
Age of deciduous tooth eruption in the maxilla and mandible for male and female piglets in Nigeria (n = 51)

| | **MALES (n = 24)** | | **FEMALES (n = 27)** | |
|---|---|---|---|---|
| Tooth Eruption | Mean ± S.E | Range | Mean ± S.E | Range |
| Md $I_1$ (Days) | 12.95 ± 0.73 | 8–18 | 12.54 ± 0.74 | 7–23 |
| Mx $I^1$ (Weeks) | 3.75 ± 0.15 | 3–5 | 3.28 ± 0.22 | 2–5 |
| Md $I_2$ (Weeks) | 11.08 ± 0.40 | 6–14 | 10.67 ± 0.39 | 5–13 |
| Mx $I^2$ (Weeks) | 17.91 ± 0.58 | 12–24 | 16.91 ± 0.53 | 12–20 |
| Md $P_2$ (Weeks) | 5.73 ± 0.71 | 3–13 | 5.59 ± 0.68 | 3–13 |
| Mx $P^2$ (Weeks) | 7.65 ± 0.20 | 6–9 | 7.33 ± 0.16 | 6–9 |
| Md $P_3$ (Weeks) | 3.63 ± 0.23 | 2–6 | 3.26 ± 0.22 | 1–5 |
| Mx $P^3$ (Weeks) | 3.38 ± 0.25 | 2–7 | 3.19 ± 0.24 | 1–6 |
| Md $P_4$ (Weeks) | 6.25 ± 0.17 | 4–8 | 6.15 ± 0.17 | 4–7 |
| Mx $P^4$ (Weeks) | 6.33 ± 0.17 | 5–9 | 6.00 ± 0.19 | 5–8 |

***Note**: Md: **Mandibular**, Mx: **Maxillary**. The deciduous eruption sequence elucidated is as follows: **Md/ MxI3**(at birth), **C** (at birth) →**Md $I_1$**→**Md $P_3$**→**Mx$P^3$** →**Mx$I^1$** → **Md $I_2$** →**Md$P_4$** →**Mx$P^4$** →**Mx$P^2$**→ **Md $I_2$** →**Mx$I^2$**

# Discussion

The overall chronology of deciduous dental eruptions for NLPs was observed to be different from those observed in Yorkshire pigs [30], European wild pigs (*Sus scrofa*) [16], Large white pigs[29],and miniature breeds of pigs[9, 28, 33, 35].The observed difference in the timing of the eruptions may be due to genetic or environmental factors associated with the NLPs. Tucker and Widowski reported that husbandry practices and breed selection activities could have an influence on the onset of dental eruption [30].

Although the mean values showed no statistical differences in the eruption timing of individual tooth, the gilts had advanced eruptions for the first mandibular and maxillary incisors, the second mandibular incisor, and the mandibular and maxillary third premolar teeth, ahead of the barrows. This observation is similar to the findings of Tucker and Widowski, who reported that Yorkshire gilts had early eruptions ahead of the barrows [30]. This observation was however different from the findings reported in miniature pigs, where there was no sexual difference in dental eruption [17, 35]. Of the several factors thought to be responsible for delayed teeth eruption [27], systemic stress is considered to be the primary cause of teeth eruption delays in animals[30].

While Herring and Wineski showed that a relationship exists between dental development, specifically the premolars, and chewing behaviour in miniature breeds of pigs[19], Tucker and Widowski showed that premolar eruption had a direct relationship with the amount of time piglets spent at the creep feeder, post weaning[30].Therefore early dental development in the gilts could result in increased feed intake before and after weaning. Delumeau and Meunier-Salaün suggested that gilts may have greater abilities to adapt to learning novel behaviours, including feeding, when compared with barrows [7].

Deciduous teeth staining in post natal life could be intrinsic or extrinsic in origin. The fact that some piglets in this study were observed to have discoloured needle teeth a few days after birth could be due to some conditions *in-utero*. Intrinsic staining of dental tissues usually occurs during prenatal tooth development and several factors including several metabolic disorders, excess fluoride intake, tetracycline administration, vitamin D deficiency, or any disturbance affecting the normal development of dentine or enamel have been implicated[30]. Staining of teeth has been noted in the Sinclair miniature breed of pig, although age and time of onset was not provided [9].

Supernumerary teeth or Polydonty is thought to be of congenital origin and may result from development of excess dental lamina, an additional follicle, or an extension of the dental lamina after the deciduous, as well as the permanent follicles which may result in the formation of additional tooth germs[15, 39]. They can be found in any part of the dental arch in the oral cavity. Although the condition is thought to be uncommon in pigs, it has however been reported in wild boars[15].Congenital disorders such as polydonty may result in excessive wear of the teeth and predispose affected animals to dental diseases including caries and periodontitis[15].This may be due to reduction in interdental spaces and mechanical abrasion of fibres on the supporting gingivae.

The Nigerian local piglets in this study showed a different sequence of eruption, when compared to the Yorkshire piglets. In the piglets used in this study, the third mandibular premolar erupted before its maxillary counterpart. This is similar to what Weaver reported in the Pitman-Moore strain of miniature pigs [35], but the reverse was the case in the Yorkshire piglets. Similarly, the fourth mandibular premolar erupted immediately before its maxillary counterpart, in the Nigerian local pigs but in the Yorkshire piglets, eruption of the fourth maxillary premolar tooth occurred after the eruption of the third mandibular premolar and first maxillary incisor teeth [30]. A variation was also observed in the eruption of the first maxillary incisor teeth between piglets in this study and the Pitman-Moore strain of miniature swine. While the first maxillary incisors erupted after the third premolars in the Nigeria local pigs, similar to the result obtained in the Yorkshire piglets, those of the miniature pigs erupted before the premolars [30].Eruption sequence within species is thought to be an adaptive feature, hence changes in such sequence could be an indication of how breeds of such species have adapted to their environments over time (23).

## Conclusion

This is the first study to examine the pattern of deciduous tooth eruption in the Nigerian local pigs over a period of time. These results clearly indicate that considerable variation in eruption times exists among individuals and litters and in comparison to other breeds of pigs. In addition, observable differences in the timing of premolar eruption were found between the current study and earlier studies. This will be particularly important to researchers who will be using pigs in Nigeria as a model for translation research.

## Declarations

# Ethics approval and consent to participate:

The experiments were performed following the Guide of University of Ibadan -Animal Care and Use in Research Ethics Committee (UI-ACUREC).

# Consent for publication:

Not Applicable

# Availability of data and material:

The datasets during and/or analysed during the current study available from the corresponding author on reasonable request

# Competing interests:

"The authors declare that they have no competing interests"


# Funding:

The authors received no funding for this work


# Authors' contributions:

ME and AD raised the animals and monitored the eruption pattern daily and weekly. FA was involved in data interpretation. OJO was involved in research design. All authors were involved in data analysis, manuscript reading and correction


# Acknowledgements:

We appreciate Dr OA Adebiyi of Animal Science Department, University of Ibadan for guidance on animal management


## References


1. Abenga JN, Lawal IA. Implicating roles of animal reservoir hosts in the resurgence of Gambian trypanosomiasis (sleeping sickness). Afr J Biotechnol. 2005;4:134–7.
2. Adeola AC, Oseni SO, Omitogun OG. Morphological characterization of indigenous and crossbred pigs in rural and peri-urban areas of Southwestern Nigeria. Open J Anim Sci. 2013;3:230–5.
3. African Union-. Inter-african Bureau for Animal Resources, AU-IBAR. Local African Pig, 1–2, 2015.
4. Angus S. Dentition definition. In: Shorter Oxford English Dictionary. 6th ed. Oxford: Oxford University Press; 2007;p. 646. ISBN 978-0-19-920687-2.
5. Campisi G, Paderni C, Saccone R, et al. Carbamazepine transbuccal delivery: the histo-morphological features of reconstituted human oral epithelium and buccal porcine mucosae in the transmucosal permeation. Int J Immunopath Pharmacol. 2008;21:903–10.
6. Clutton-Brock J. A natural History of domesticated Mammals. Cambridge: Cambridge University Press; 1999. p. 91.
7. Delumeau O, Meunier-Salaün MC. Effect of early trough familiarity on the creep feeding behavior in suckling piglets and after weaning. Behav Processes. 1995;34:185–96.
8. Ding G, Liu Y, Wang W, et al. Allogeneic periodontal ligament stem cell therapy for periodontitis in swine. Stem Cells. 2010;28:1829–38.
9. Gier RE. Dentition and other oral conditions of the Sinclair strain of miniature swine. In: Swine in Biomedical Research. New York: Plenum Press; 1986. pp. 633–9.

10. Herring SW, Wineski LE. Development of the masseter muscle and oral behavior in the pig. J Exp Zool. 1986;237:191–207.
11. Huffman B. Pigs as ungulates. The ultimate ungulate website. 2006; Retrieved April 10, 2007.
12. Larjava H, Wiebe C, Gallant-Behm C, Hart DA, Heino J. & Hakkinen L. Exploring scarless healing of oral soft tissues. J Can Dent Assoc. 2011;77:b18.
13. Larsen MO, Rolin B. Use of the Gottingen minipig as a model of diabetes, with special focus on type 1 diabetes research. ILAR J. 2004;45:303–13.
14. Mak K, Manji A, Gallant-Behm C, et al. Scarless healing of oral mucosa is characterized by faster resolution of inflammation and control of myofibroblast action compared to skin wounds in the red Duroc pig model. J Dermatol Sci. 2009;56:168–80.
15. Malmsten A, Dalin AM, Pettersson A. Caries, periodontal disease, supernumerary teeth and other dental disorders in Swedish wild boar (Susscrofa). J Comp Path. 2015;153:50–7.
16. Matschke GH. Aging European wild hogs by dentition. JWildl Manag. 1967;1:109–13.
17. McKean CF, Jump EB, Weaver ME. The calcification pattern of deciduous teeth in miniature swine. Arch Oral Biol. 1971;16:639–48.
18. Nkenke E, Lehner B, Fenner M, et al. Immediate versus delayed loading of dental implants in the maxillae of minipigs: follow-up of implant stability and implant failures. Int J Oral Maxillofac Implants. 2005;20:39–47.
19. Osei-Amponsah R, Skinner BM, Adjei DO, Bauer J, Affara NA, Sargent CA. Origin and phylogenetic status of the local Ashanti Dwarf pig (ADP) of Ghana based on genetic analysis. BMC Genom. 2017;18:193.
20. Penrith ML, Thomson GR, Bastos AD, et al. An investigation into natural resistance to African swine fever in domestic pigs from an endemic area in southern Africa. Rev Sci Tech de l'Office International des Epizooties. 2004;23:965–77.
21. Romer AS, Parsons TS. The Vertebrate Body. Holt-Saunders International. 1977;300–310.
22. Rothschild MF. Porcine genomics delivers new tools and results: this little piggy did more than just go to market. Genet Res. 2004;83:1–6.
23. Smith BH. Sequence of emergence of the permanent teeth of Macaca, Pan, Homo, and Australopithecus: its evolutionary significance. Am J Hum Biol. 1994;6:61–76.
24. Sonoyama W, Liu Y, Fang D, et al. Mesenchymal stem cell-mediated functional tooth regeneration in swine. PLoS One. 2006;e79. doi:10.1371/journal.pone.0000079.
25. Stembirek J, Kyllar M, Putnova I, Stehlik L, Buchtova M. The pig as an experimental model for clinical craniofacial research. Lab Anim. 2012;46:269–79.
26. Sun D, Wang J, Wu R, et al. Development of a novel LAMP diagnostic method for visible detection of swine Pasteurella multocida. Vet Res Comm. 2010;34:649–57.
27. Suri L, Gagari E, Vastardis H. Delayed tooth eruption: pathogenesis, diagnosis, and treatment. A literature review. Am J of Orthod Dentofacial Orthop. 2003;126(4):432–45.

28. Swindle MM. Swine as models in dental and oral surgical research. Catheterization series. Sinclair bio resources LLC. 2010.
29. Tonge CH, McCance RA. Normal development of the jaws and teeth in pigs, and the delay and malocclusion produced by calorie deficiencies. J Anat. 1973;115:1–22.
30. Tucker AL, Widowski TM. Normal profiles for deciduous dental eruption in domestic piglets: Effect of sow, litter, and piglet characteristics. J Anim Sci. 2009;87:2274–81.
31. Tudor C, Bumiller L, Birkholz T, Stockmann P, Wiltfang J, Kessler P. Static and dynamic periosteal elevation: a pilot study in a pig model. Int J Oral MaxillofacSurg. 2010;39:897–903.
32. Van der Laan JW, Brightwell J, McAnulty P, Ratky J, Stark C. Regulatory acceptability of the minipig in the development of pharmaceuticals, chemicals and other products. J Pharmacol Toxicol. 2010;62:184–95.
33. Wang S, Liu L, Fang D, Shi S. The Miniature pig: a useful large animal model for dental and orofacial research. Oral Dis. 2007;13:530–7.
34. Warwick C, Williams PL. Gray's Anatomy. 35th ed. Philadelphia: Saunders WB Co; 1973.
35. Weaver ME, Jump EB, McKean CF. The eruption pattern of deciduous teeth in miniature swine. Anat Rec. 1969;154:81–6.
36. Wiener P, Wilkinson S. Deciphering the genetic basis of animal domestication. Proc. R. Soc. B. 2011;278:3161–3170.
37. Wilkinson S, Lu ZH, Megens HJ, et al. Signatures of diversifying selection in European pig breeds. PLoS Genet. 2013;9(4):e1003453. DOI:10.1371/journal.pgen.1003453.
38. Xu J, Zheng Z, Fang D. Early stage pathogenic sequence of jaw osteoradionecrosis in vivo. J Dent Res. 2012;91:702–8.
39. Yai-Tin L, Sung-Wen C, Yng-Tzer J, Lin. Delayed formation of multiple supernumerary teeth. J Dent Sci. 2009;4(3):159–64.
40. Zheng Y, Liu Y, Zhang CM, et al. Stem cells from deciduous tooth repair mandibular defect in swine. J Dent Res. 2009;88:249–54.

# Figures

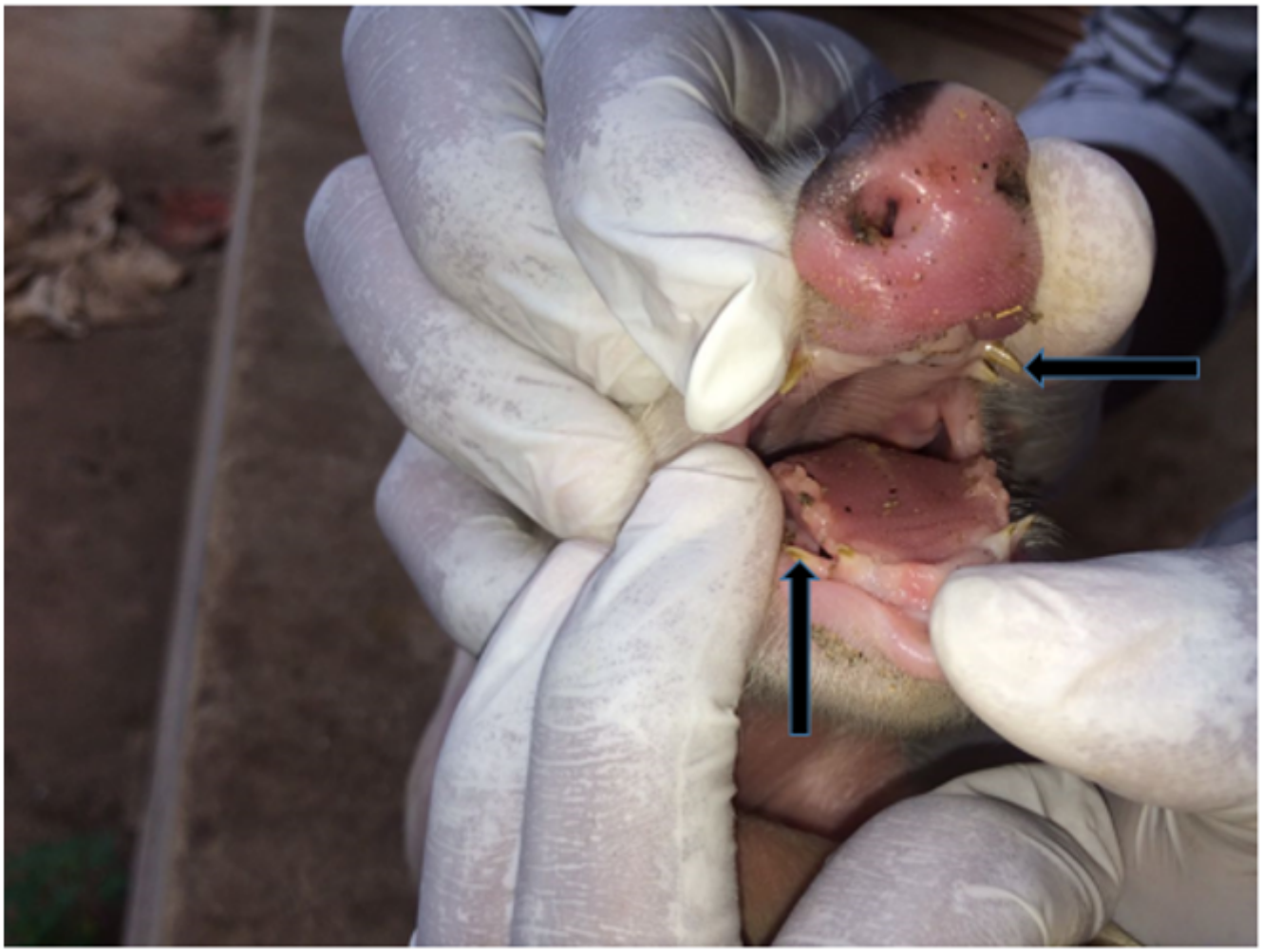

**Figure 1**

Arrows show the “Needle Teeth (Mandibular and Maxillary)

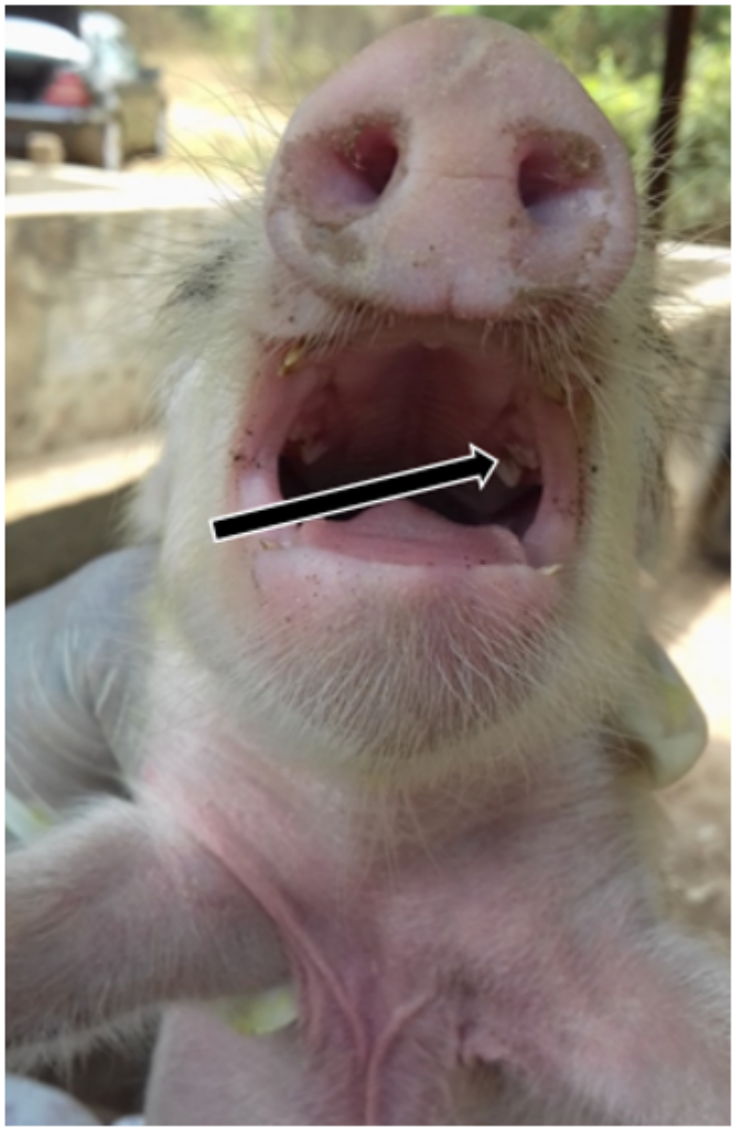

**Figure 2**

Arrow shows Erupted Mx p3

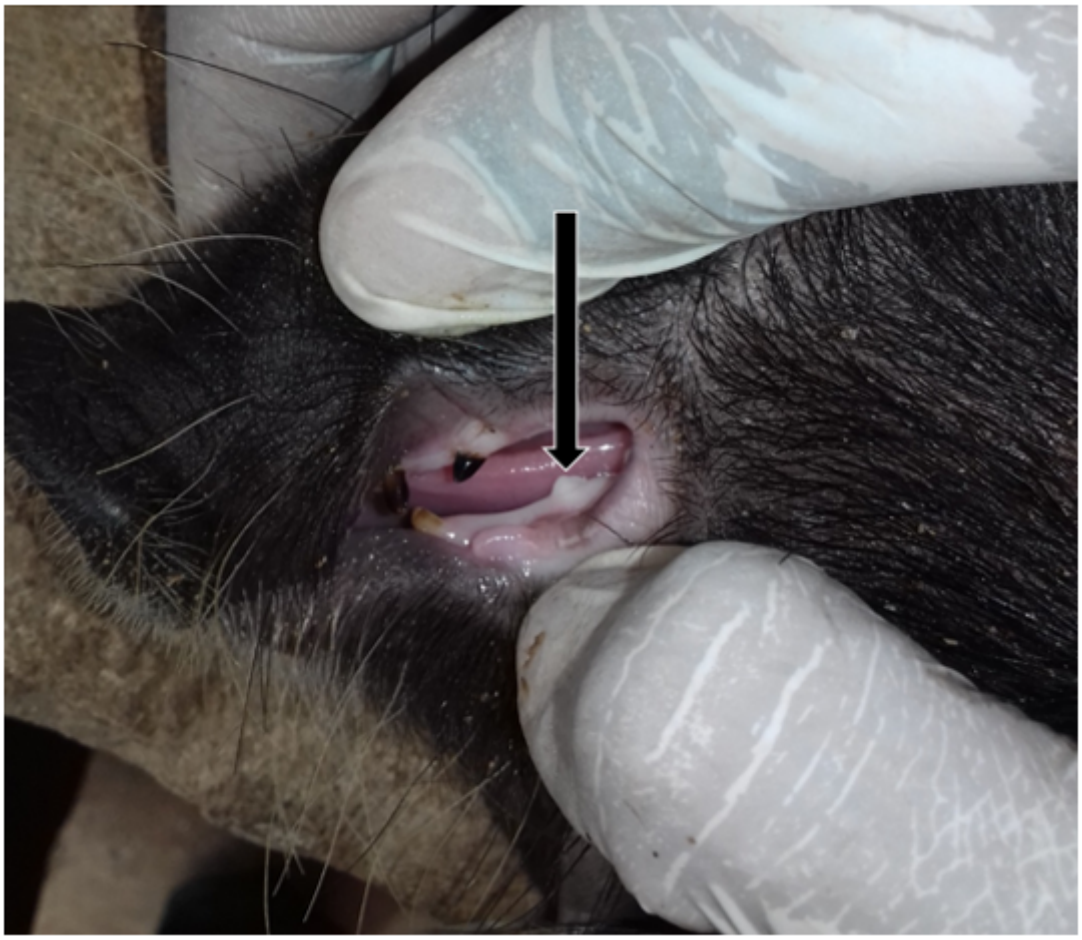

**Figure 3**

Arrow shows Erupted Md p2

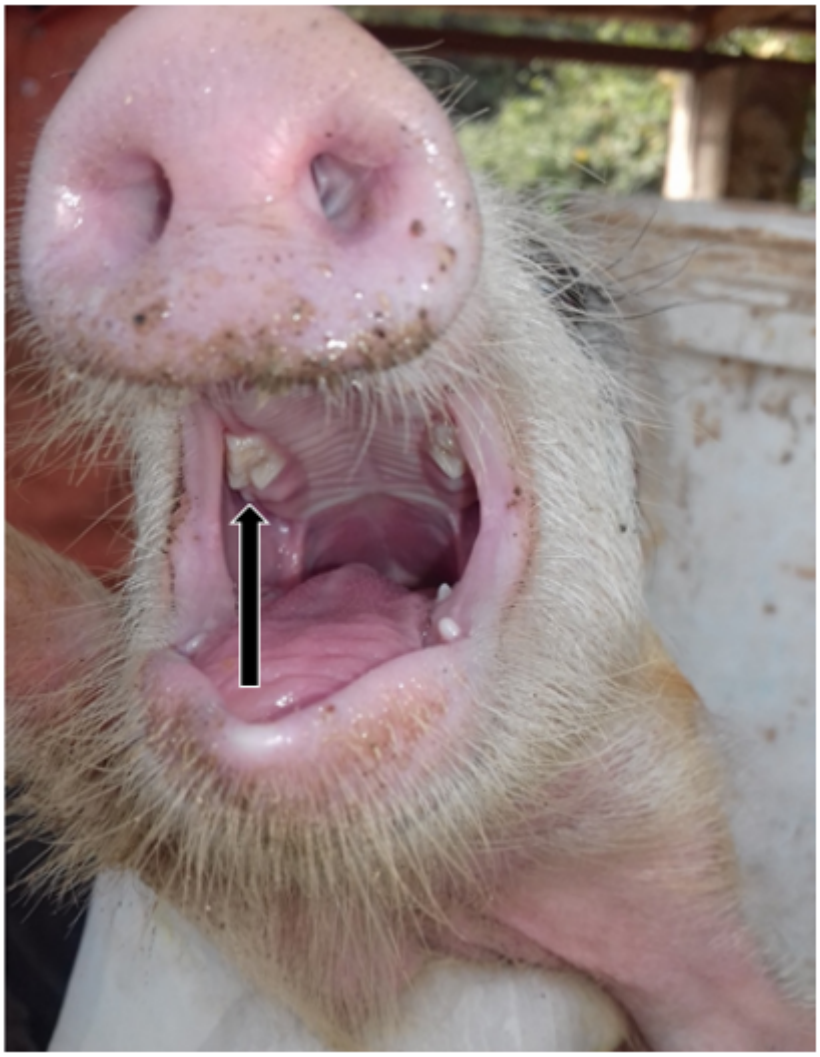

**Figure 4**

Arrow shows erupting Mxp4

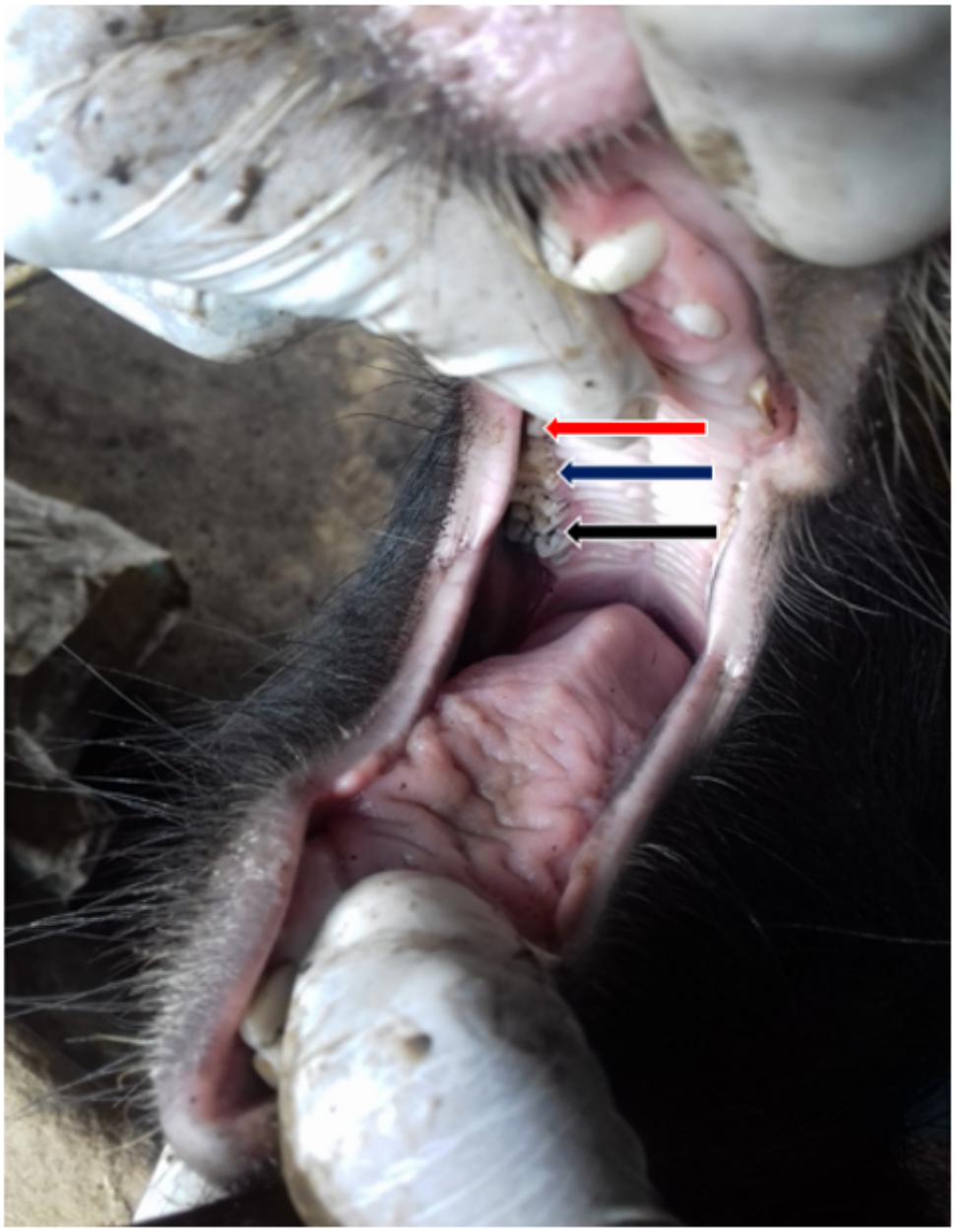

## Figure 5

Arrows Show Mx p2(Red Arrow), Mx p3 (Blue Arrow and Mx p4 (Black Arrow)

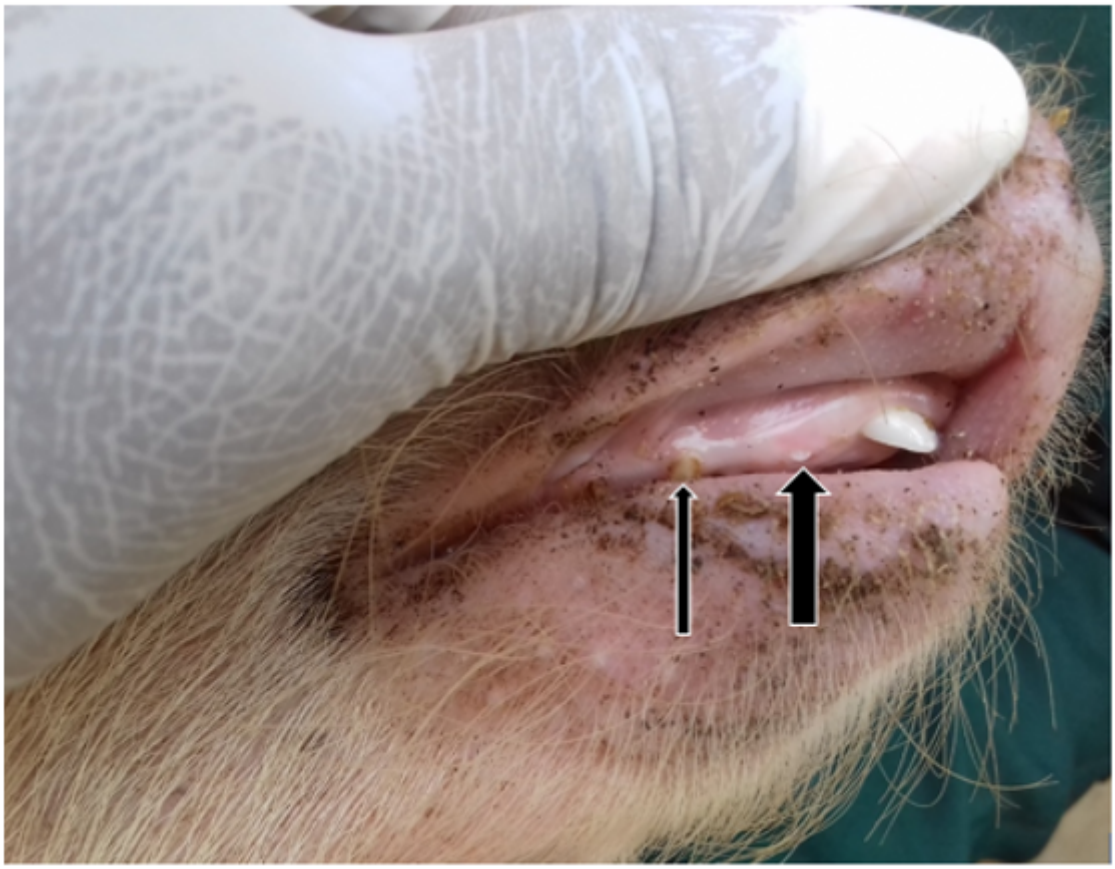

**Figure 6**

Arrows show Mx i3(Thin Arrow) and Mx i2(Thick Arrow)

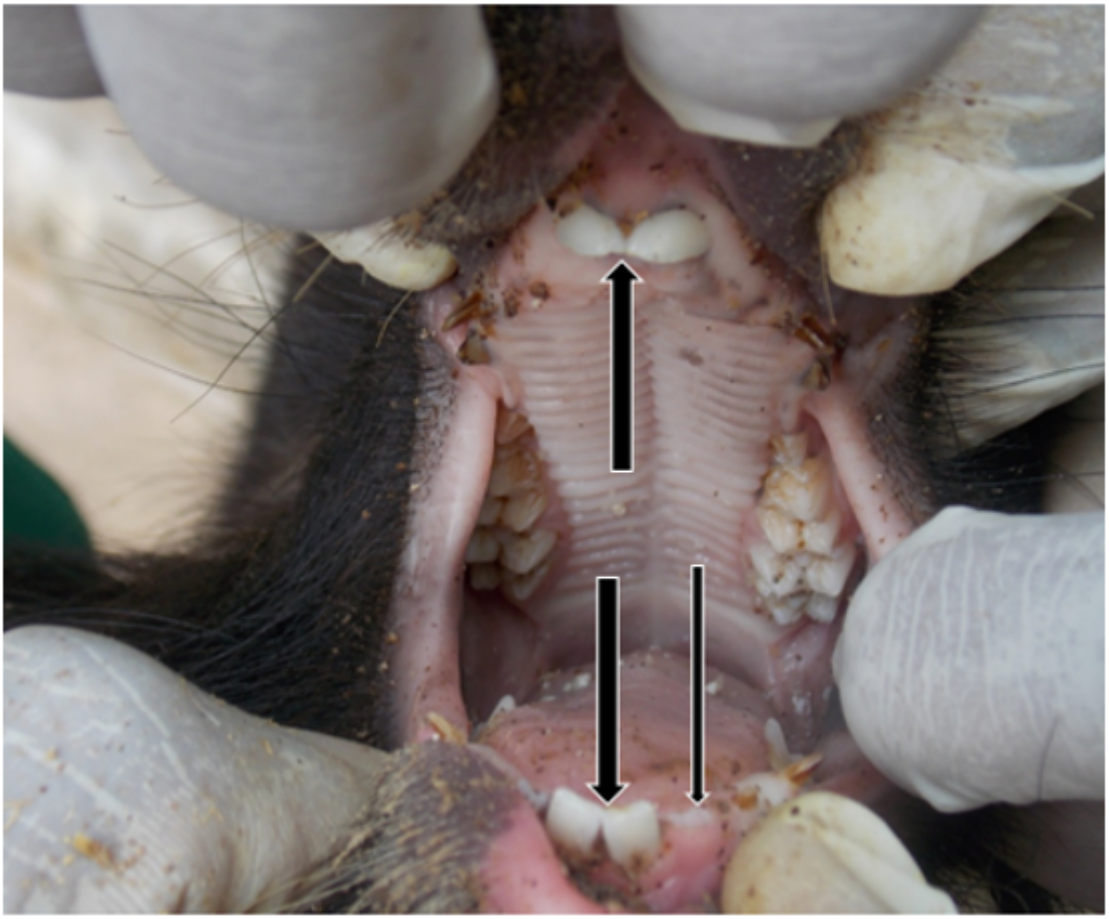

**Figure 7**

Thick Arrows show central incisors (Md i1and Mx i1), and Md i2(Thin Arrow)

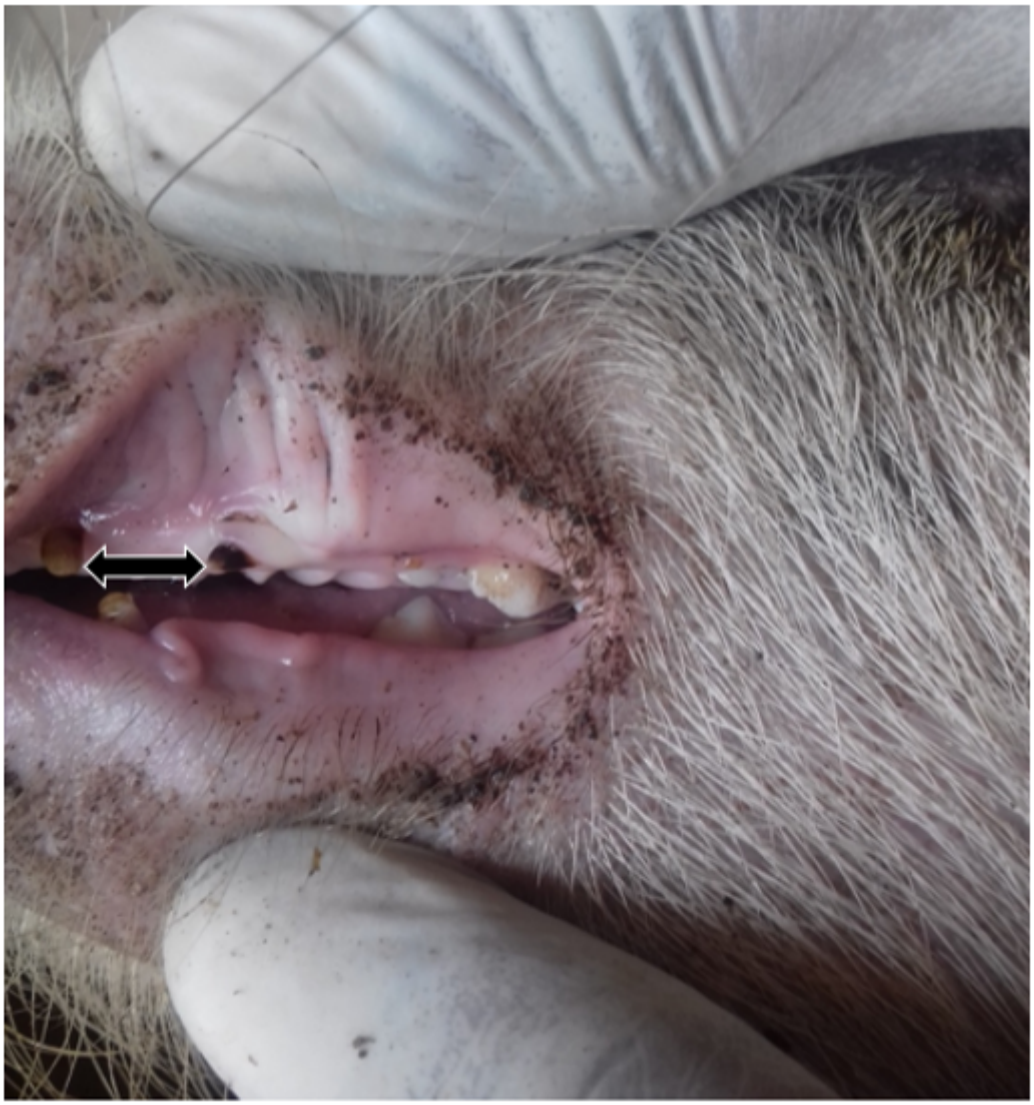

**Figure 8**

Left-Right Arrow showing stained incisor Mx i3 and canine teeth

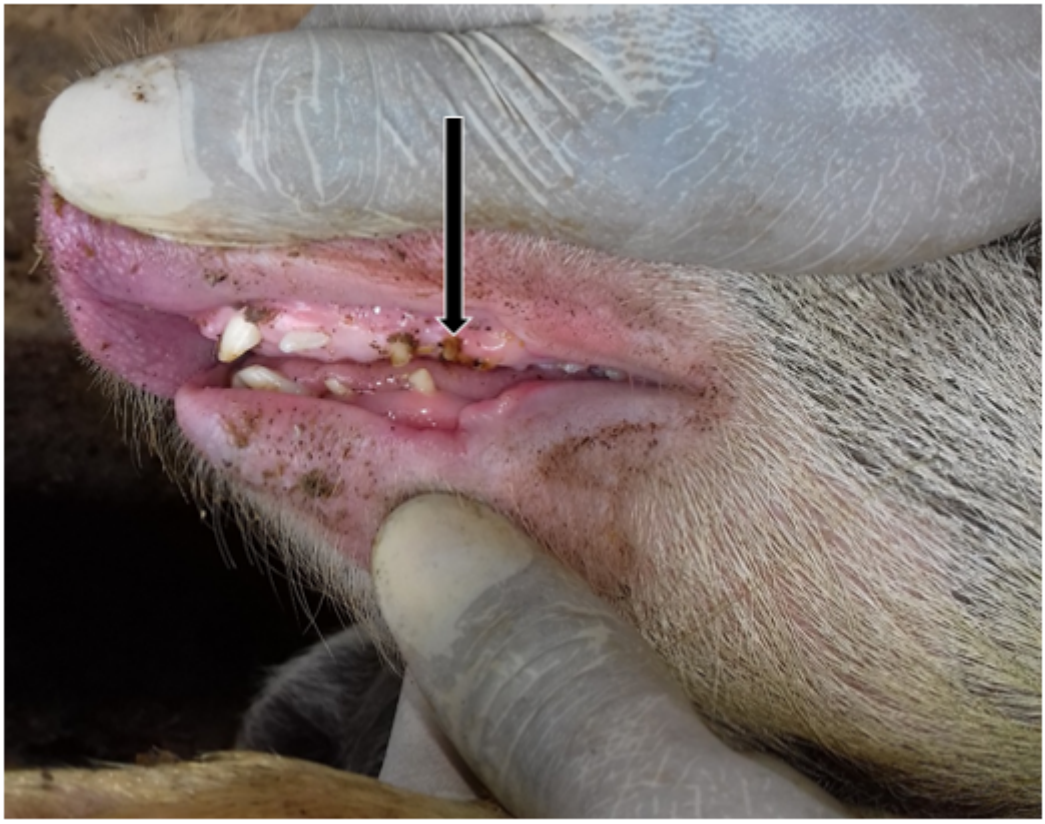

**Figure 9**

Arrow shows polydonty of Mx i3