Coronary stent-graft use to salvage a juxta-anastomotic arterial rupture complicating a case of radio-cephalic fistuloplasty

Zhiyuan Lin (zhiyuan.lin@nhs.net)
Royal Free London NHS Foundation Trust https://orcid.org/0000-0003-3728-3510

Neha Kallam
Royal Free London NHS Foundation Trust

Ruhaid Khurram
Royal Free London NHS Foundation Trust

Ammar Al Midani
Royal Free London NHS Foundation Trust

Mohamed Khalifa
Royal Free London NHS Foundation Trust

Research Article

Keywords: AVF stenosis, Fistuloplasty, Vessel rupture, Pseudoaneurysm, BeGraft coronary stent-graft

Posted Date: June 23rd, 2022

DOI: https://doi.org/10.21203/rs.3.rs-1753668/v1

Abstract

Background:

Stenosis is a common complication of haemodialysis arteriovenous accesses. Endovascular approaches with percutaneous transluminal fistuloplasty have largely replaced open surgical approaches as first line treatment. Vessel rupture is an uncommon complication of fistuloplasty and most reports describe venous rupture. Stent-graft deployment can salvage this however its use requires careful assessment of the distal vasculature. Arterial rupture with fistuloplasty has rarely been described in the literature. This is a novel case describing the use of a BeGraft coronary stent-graft to manage juxta-anastomotic arterial rupture and pseudoaneurysm complicating fistuloplasty.

Case presentation:

A 77 year old female with end stage renal failure secondary to systemic amyloid light chain type amyloidosis was referred for a suspected radio-cephalic arteriovenous fistula stenosis after difficulty cannulating with poor flow during dialysis and clinical reduction in the fistula thrill. Both doppler ultrasound and intravenous fistulography confirmed a venous stenosis 2cm distal to the anastomosis. The stenosis was treated by fistuloplasty, however, this was complicated by a rupture of the juxta-anastomotic arterial segment intraoperatively. Intermittent balloon tamponade was used to minimise extravasation although a pseudoaneurysm formed within the damaged arterial segment. The patient's distal neurovascular status was assessed using the Barbeau test and we sonographically confirmed adequate retrograde arterial flow via a complete palmar arch directing blood from the ulnar artery. After discussion with the renal transplant team, a 4mm BeGraft coronary stent-graft was deployed to control haemorrhage and bypass the pseudoaneurysm until adequate haemostasis and fistula flow was achieved. Follow-up 3 months post-procedure reported the patient continued with haemodialysis using the stented fistula with no further complications.

Conclusions:

To our knowledge, this is the first case report describing the application of BeGraft coronary stent-grafts to salvage fistuloplasty of a radio-cephalic arteriovenous fistula stenosis complicated by juxta-anastomotic arterial rupture and pseudoaneurysm formation. We demonstrate the safety and short-term efficacy of this technology.

Background

Stenosis is the most common complication after haemodialysis arteriovenous (AV) access creation [1]. A clinically significant stenotic lesion is one that shows > 50% narrowing relative to the normal adjacent vein diameter and has clinical signs or symptoms. These include ipsilateral limb oedema, abnormal thrills

and bruits. Stenosis can also cause difficulty in cannulation, aspiration of clots, and a decrease in access flow from the baseline [2]. Any clinical suspicion of arteriovenous fistula (AVF) stenosis requires further characterisation by duplex ultrasound or intravenous angiography (fistulography). If left untreated, stenosis can lead to AVF non-maturation and cause dysfunction in mature AVFs resulting in eventual abandonment.

Fistuloplasty (or percutaneous transluminal angioplasty) for AVF stenosis was first described in the early 1980s using a Grüntzig balloon catheter [3, 4]. It remains the first-line treatment of AVF stenosis with a technical success rate of 90% [5]. There is a small but significant complication rate for fistuloplasty of approximately 4%, with haematoma formation being the most common complication [5]. Vessel rupture occurs in 0.9%-3.8% of fistuloplasty in the management of AV access stenosis [6–8]. Most reports of iatrogenic vessel rupture are venous.

High pressure balloon fistuloplasty remains the standard as it improves the success rate compared to standard pressure balloons, however, this acknowledges a higher risk of vessel rupture [9]. Using balloon catheters > 2mm greater than the vessel diameter and cutting balloons both improve patency but further increase risk of vessel rupture [8, 10]. Vessel rupture, whilst uncommon, can be managed with balloon tamponade, stent-graft deployment or conservatively with external compression and intentional thrombosis. Several studies have demonstrated the technical success, long-term efficacy and safety of stent-grafts for failed or complicated fistuloplasty. Across these studies, the technical and clinical success rate was between 98%-100% [11–14].

We report the case of a 77 year old woman who underwent fistuloplasty for a radio-cephalic AVF with inflow stenosis which was complicated by rupture of the juxta-anastomotic arterial segment and pseudoaneurysm formation requiring stent-graft deployment.

Case Report

A 77 year old female with end stage renal failure secondary to systemic amyloid light chain (AL) type amyloidosis on long term haemodialysis was referred to the interventional radiology department following difficulty in cannulating her AVF and clinical reduction in the palpable fistula thrill. Her significant medical comorbidities include type 2 diabetes mellitus, hypertension, hypercholesterolaemia and a pacemaker for Mobitz type 2 second degree atrioventricular block.

Doppler ultrasound revealed a stenosis 2 cm distal to the anastomosis. With systemic heparinisation, we performed fistulography under intravenous sedation (2mg Midazolam, 50µg Fentanyl) and local anaesthetic (10ml 1% Lidocaine). Glyceryl trinitrate (800µg) and Amlodipine (10mg) were administered during the procedure due to a systolic blood pressure over 200mmHg on a background of known hypertension. This controlled the systolic pressure to 150mmHg.

Under ultrasound guidance, retrograde puncture of the fistula was performed. A 5F sheath was inserted and the catheter and wire were successfully passed across the stenotic lesion. The initial venogram

confirmed a juxta-anastomotic venous segment stenosis (Fig. 1).

This was initially dilated with a 4mm Sterling balloon (Boston Scientific) which resulted in suboptimal reduction of the stenosis after which a 5mm Sterling balloon was used to overcome the tight stenosis. To achieve optimal dilatation of the affected vessel, a short segment of the balloon was positioned and inflated within the arterial segment to attain adequate vessel patency and to prevent migration of the balloon proximally due to arterial-flow back pressure. This was complicated by rupture at the juxta-anastomotic radial artery segment which immediately presented as pain and swelling in the patient's forearm and was confirmed by fistulography (Fig. 2).

Intermittent balloon tamponade was maintained with a 3 mm balloon at the level of contrast extravasation. To ensure safety of the distal limb whilst the balloon was inflated, the neurovascular status of the patient was clinically assessed together with ultrasound of the radial artery distal to the fistula which demonstrated adequate retrograde blood flow from the complete palmar arch via the ulnar artery. This was further confirmed with a Barbeau test which showed no dampening of the pulse oximeter waveform on the ipsilateral thumb with balloon inflation. Confirmation of the above allowed for prolonged balloon tamponade for a total duration of 30 minutes without concern for neurovascular compromise to the distal limb.

Whilst intermittent balloon tamponade minimised extravasation, a small pseudoaneurysm subsequently formed within the short arterial segment (Fig. 3). After discussion with the renal transplant team, a joint decision was made to deploy a covered stent-graft within the arterial portion of the anastomosis. A 4mm BeGraft coronary stent-graft (Bentley InnoMed GmbH) was deployed in an adequate position within the arterial portion of the anastomosis (Fig. 4).

The completion fistulogram demonstrated excellent flow through the fistula with no evidence of active bleeding and complete exclusion of the pseudoaneurysm (Fig. 5). There was no clinical evidence of compartment syndrome.

The patient recovered well post-procedure and was admitted overnight for monitoring and neurovascular observations. Her post-operative haemoglobin levels were within normal limits (113 g/L; ref: 110-150g/L). The forearm swelling improved significantly, and no neurovascular complications were noted the following morning. The patient was reviewed in haemodialysis clinic 3 months later and successfully continued with haemodialysis through the stented fistula, reporting no further complications.

Conclusion

To the best of the authors' knowledge, this is the first case report describing the use of a BeGraft coronary stent-graft, a balloon-expandable encapsulated polytetrafluoroethylene (ePTFE) covered Cobalt-Chromium stent-graft, to manage juxta-anastomotic arterial rupture and pseudoaneurysm complicating fistuloplasty for AVF stenosis.

Thus far, stent-grafts have generally been confined to salvage therapy in AV accesses where fistuloplasty has failed due to high elastic recoil, > 30% residual stenosis, early restenosis within 3 months, and in-stent restenosis or where fistuloplasty is complicated by vessel rupture or aneurysm as in our case [2, 15]. The putative advantages of stent-grafts over balloon tamponade include the ability of stent-grafts to resist vessel elastic recoil and provide a complete physical barrier to prevent further haemorrhage and exclude pseudoaneurysm. One recent study of fistuloplasty induced rupture of haemodialysis AV accesses demonstrated that the Viabahn SG (W. L. Gore & Associates), a self-expanding ePTFE covered Nitinol stent-graft had a significantly greater 12 months target lesion primary patency rate compared to balloon tamponade even after multivariate adjustment analysis [16].

There are few specifically designed or licensed stents for use in AVFs and a wide variety of stent types have been tried off-label. Aside from the Viabahn SG, there is the Fluency® Plus stent-graft, another self-expanding ePTFE Nitinol stent, FDA approved for in-stent restenosis for haemodialysis access following the RESCUE trial [17].

BeGraft is commonly used in coronary intervention. From a literature search, a small number of studies reported application of a BeGraft coronary stent-graft within a comparable non-coronary context such as in traumatic or iatrogenic injury to the anterior tibial artery and other small vessels [18, 19]. Another case series described BeGraft use in critical limb ischaemia with AVF creation in the distal tibial artery [20]. Due to the small calibre of the radial artery and the short segment requiring exclusion, a low-profile covered stents was required to manage this. A covered BeGraft coronary stent-graft was most suited to this application. Stent-grafts traditionally used for peripheral interventions such as the Viabahn SG would not have met these requirements due to their larger profile.

Irrespective of whether balloon tamponade or stent-grafts are used to treat fistuloplasty-induced AVF arterial rupture or pseudoaneurysm, it is vital to assess for adequate retrograde blood flow via the palmar arch from the ulnar artery. This can be clinically proven by neurovascular assessment, the Barbeau test and sonographically by ultrasound of the distal vasculature. If necessary, prolonged tamponade in arterial rupture and stent-grafting across the anastomosis can be safe with confirmation of the above.

Despite the high technical success rate demonstrated by stent-grafts in both AVF vessel rupture and pseudoaneurysms, there are a few limitations. Covered stent-grafts are not designed for repeat cannulation which means once deployed, the area must be marked to avoid cannulation over that site as in our patient.

In conclusion, juxta-anastomotic arterial segment rupture is a rare complication of fistuloplasty that can be managed with endovascular stent-graft deployment. Clinical assessment of the neurovascular status and adequate retrograde palmar arch flow via the ulnar artery are key to ensuring safe balloon tamponade and stent-graft deployment. We demonstrate that the BeGraft coronary stent is safe and effective in the short-term. Its long-term success in salvaging failed or complicated fistuloplasty of AV accesses requires further investigation.

List Of Abbreviations

AV
Arteriovenous
AVF
Arteriovenous fistula
ePTFE
Encapsulated polytetrafluoroethylene

Declarations

Ethics approval & Consent to participate:

Not applicable

Consent for publication:

Written informed consent was obtained from the patient for publication of this case report and any accompanying images.

Availability of data and materials:

Not applicable

Competing interests:

The authors declare that they have no competing interests

Funding:

This case report was not supported by any funding

Author contributions:

ZL performed a literature review, created the initial draft and contributed to editing and submission of the revised manuscript. MK performed the procedure and edited the revised manuscript. RK obtained the images and edited the revised manuscript. NK and AAM provided edits and improvements to the revised manuscript. All authors read and approved the final manuscript

Acknowledgements:

Not applicable

References

1. Riella MC, Roy-Chaudhury P Vascular access in haemodialysis: strengthening the Achilles' heel. Nat Rev Nephrol 2013 96 [Internet]. 2013 Apr 16 [cited 2022 Mar 12];9(6):348–57. Available from: https://www.nature.com/articles/nrneph.2013.76
2. Lok CE, Huber TS, Lee T, Shenoy S, Yevzlin AS, Abreo K et al KDOQI Clinical Practice Guideline for Vascular Access: 2019 Update. Am J Kidney Dis [Internet]. 2020 Apr 1 [cited 2022 Mar 12];75(4):S1–164. Available from: http://www.ajkd.org/article/S0272638619311370/fulltext
3. Lawrence PF, Miller FJ, Mineau DE (1981) Balloon catheter dilatation in patients with failing arteriovenous fistulas. Surgery [Internet]. Apr 1 [cited 2022 Mar 12];89(4):439–42. Available from: https://europepmc.org/article/med/7209792
4. Noveline RA (1980) Percutaneous transluminal angioplasty: newer applications. AJR Am J Roentgenol [Internet]. [cited 2022 Apr 7];135(5):983–8. Available from: https://pubmed.ncbi.nlm.nih.gov/6778177/
5. Beathard GA, Litchfield T, operators forum of rms lifeline P. Effectiveness and safety of dialysis vascular access procedures performed by interventional nephrologists. Kidney Int [Internet]. 2004 Oct 1 [cited 2022 Mar 12];66(4):1622–32. Available from: http://www.kidney-international.org/article/S0085253815502330/fulltext
6. Raynaud AC, Angel CY, Sapoval MR, Beyssen B, Pagny JY, Auguste M Treatment of Hemodialysis Access Rupture during PTA with Wallstent Implantation. J Vasc Interv Radiol [Internet]. 1998 May 1 [cited 2022 Mar 12];9(3):437–42. Available from: http://www.jvir.org/article/S1051044398702957/fulltext
7. Kornfield ZN, Kwak A, Soulen MC, Patel AA, Kobrin SM, Cohen RM et al Incidence and Management of Percutaneous Transluminal Angioplasty–induced Venous Rupture in the "Fistula First" Era. J Vasc Interv Radiol [Internet]. 2009 Jun 1 [cited 2022 Mar 12];20(6):744–51. Available from: http://www.jvir.org/article/S1051044309002164/fulltext
8. Bittl JA Venous rupture during percutaneous treatment of hemodialysis fistulas and grafts. Catheter Cardiovasc Interv [Internet]. 2009 Dec 1 [cited 2022 Apr 5];74(7):1097–101. Available from: https://onlinelibrary.wiley.com/doi/full/10.1002/ccd.22143
9. Trerotola SO, Stavropoulos SW, Shlansky-Goldberg R, Tuite CM, Kobrin S, Rudnick MR (2004) Hemodialysis-related Venous Stenosis: Treatment with Ultrahigh-Pressure Angioplasty Balloons1. https://doi.org/101148/radiol2311030949 [Internet]. Apr 1 [cited 2022 Mar 12];231(1):259–62. Available from: https://pubs.rsna.org/doi/abs/10.1148/radiol.2311030949
10. Agarwal SK, Nadkarni GN, Yacoub R, Patel AA, Jenkins JS, Collins TJ et al Comparison of Cutting Balloon Angioplasty and Percutaneous Balloon Angioplasty of Arteriovenous Fistula Stenosis: A Meta-Analysis and Systematic Review of Randomized Clinical Trials. J Interv Cardiol [Internet]. 2015 Jun 1 [cited 2022 Mar 12];28(3):288–95. Available from: https://pubmed.ncbi.nlm.nih.gov/25989717/
11. Bent CL, Rajan DK, Tan K, Simons ME, Jaskolka J, Kachura J et al Effectiveness of Stent-graft Placement for Salvage of Dysfunctional Arteriovenous Hemodialysis Fistulas. J Vasc Interv Radiol

[Internet]. 2010 Apr 1 [cited 2022 Apr 7];21(4):496–502. Available from: http://www.jvir.org/article/S1051044309016728/fulltext

12. Dolmatch BL, Duch JM, Winder R, Butler GM, Kershen M, Patel R et al Salvage of Angioplasty Failures and Complications in Hemodialysis Arteriovenous Access Using the FLUENCY Plus Stent Graft: Technical and 180-Day Patency Results. J Vasc Interv Radiol [Internet]. 2012 Apr 1 [cited 2022 Mar 21];23(4):479–87. Available from: http://www.jvir.org/article/S1051044311016447/fulltext
13. Özkan B, Güngör D, Mahir Yildirim U, Harman A, Özen Ö, Aytekin C Endovascular Stent Placement of Juxtaanastomotic Stenosis in Native Arteriovenous Fistula After Unsuccessful Balloon Angioplasty. Iran J Radiol 2013 103 [Internet]. 2013 Sep [cited 2022 Mar 12];10(3):133–9. Available from: https://brief.land/iranjradiol/articles/17947.html
14. Schmelter C, Raab U, Lazarus F, Ruppert V, Vorwerk D Outcomes of AV Fistulas and AV Grafts after Interventional Stent-Graft Deployment in Haemodialysis Patients. Cardiovasc Interv Radiol 2014 384 [Internet]. 2014 Nov 7 [cited 2022 Apr 5];38(4):878–86. Available from: https://link.springer.com/article/10.1007/s00270-014-1018-7
15. MacRae JM, Dipchand C, Oliver M, Moist L, Lok C, Clark E et al Arteriovenous access failure, stenosis, and thrombosis. Can J Kidney Heal Dis [Internet]. 2016 Sep 27 [cited 2022 Mar 12];3(1). Available from: https://journals.sagepub.com/doi/10.1177/2054358116669126
16. Liao MT, Luo CM, Hsieh MC, Hsieh MY, Lin CC, Chie WC et al Stent grafts improved patency of ruptured hemodialysis vascular accesses. Sci Reports 2022 121 [Internet]. 2022 Jan 7 [cited 2022 Mar 21];12(1):1–10. Available from: https://www.nature.com/articles/s41598-021-03933-1
17. Falk A, Maya ID, Yevzlin ASA, Prospective Randomized Study of an Expanded Polytetrafluoroethylene Stent Graft versus Balloon Angioplasty for In-Stent Restenosis in Arteriovenous Grafts and Fistulae: Two-Year Results of the RESCUE Study. J Vasc Interv Radiol [Internet]. 2016 Oct 1 [cited 2022 Apr 7];27(10):1465–76. Available from: http://www.jvir.org/article/S1051044316302767/fulltext
18. Brunoro M, Baldassarre V, Sirignano P, Mansour W, Capoccia L, Speziale F Endovascular Treatment of an Anterior Tibial Artery Pseudoaneurysm Secondary to Penetrating Trauma in a Young Patient: Case Report and Literature Review. Ann Vasc Surg [Internet]. 2019 Oct 1 [cited 2022 Apr 5];60:479.e5-479.e9. Available from: https://pubmed.ncbi.nlm.nih.gov/31195105/
19. Ruffino MA, Fronda M, Varello S, Discalzi A, Mancini A, Muratore P et al Emergency management of iatrogenic arterial injuries with a low-profile balloon-expandable stent-graft: Preliminary results. Medicine (Baltimore) [Internet]. 2020 Apr 1 [cited 2022 Mar 21];99(15):e19655. Available from: https://journals.lww.com/md-journal/Fulltext/2020/04100/Emergency_management_of_iatrogenic_arterial.24.aspx
20. Migliara B, Cappellari TF A Novel Technique to Create an Arteriovenous Fistula During Total Percutaneous Deep Foot Venous Arterialisation Using an IVUS Guided Catheter. Eur J Vasc Endovasc Surg [Internet]. 2018 May 1 [cited 2022 Mar 21];55(5):735. Available from: http://www.ejves.com/article/S1078588418301291/fulltext

Figures



Figure 1

An initial fistulogram demonstrating venous puncture and successful passage of the catheter into the radial artery with a juxta-anastomotic venous segment stenosis (blue arrow)

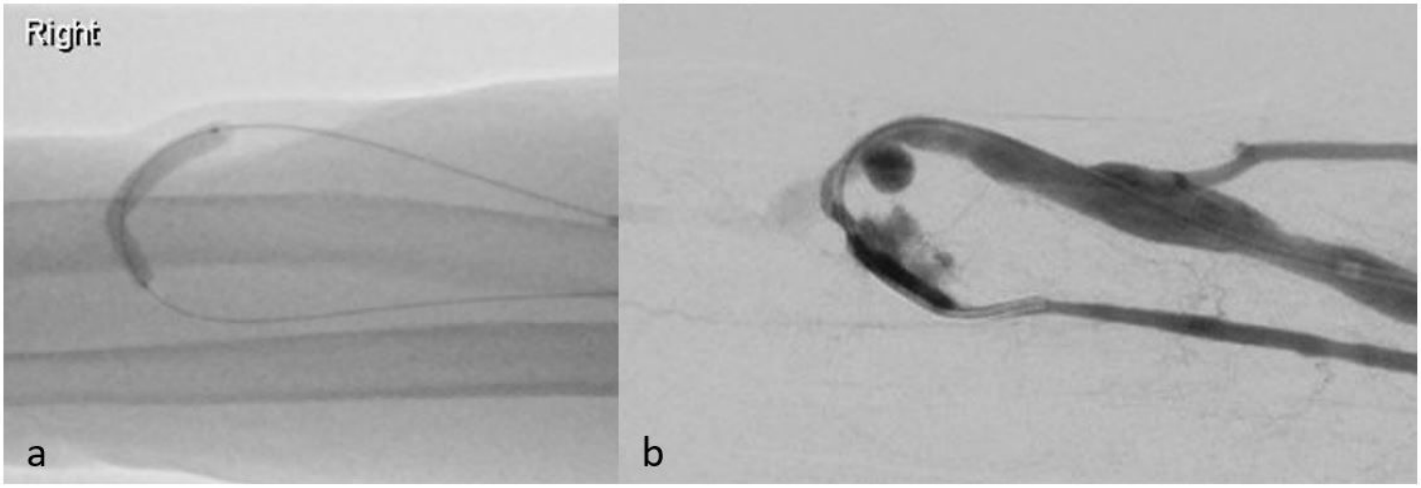

Figure 2

Short segment of the Sterling balloon inflated within the juxta-anastomotic arterial segment in an attempt to achieve optimal dilation (a). Active extravasation of contrast secondary to a rupture of the juxta-anastomotic arterial segment (b)

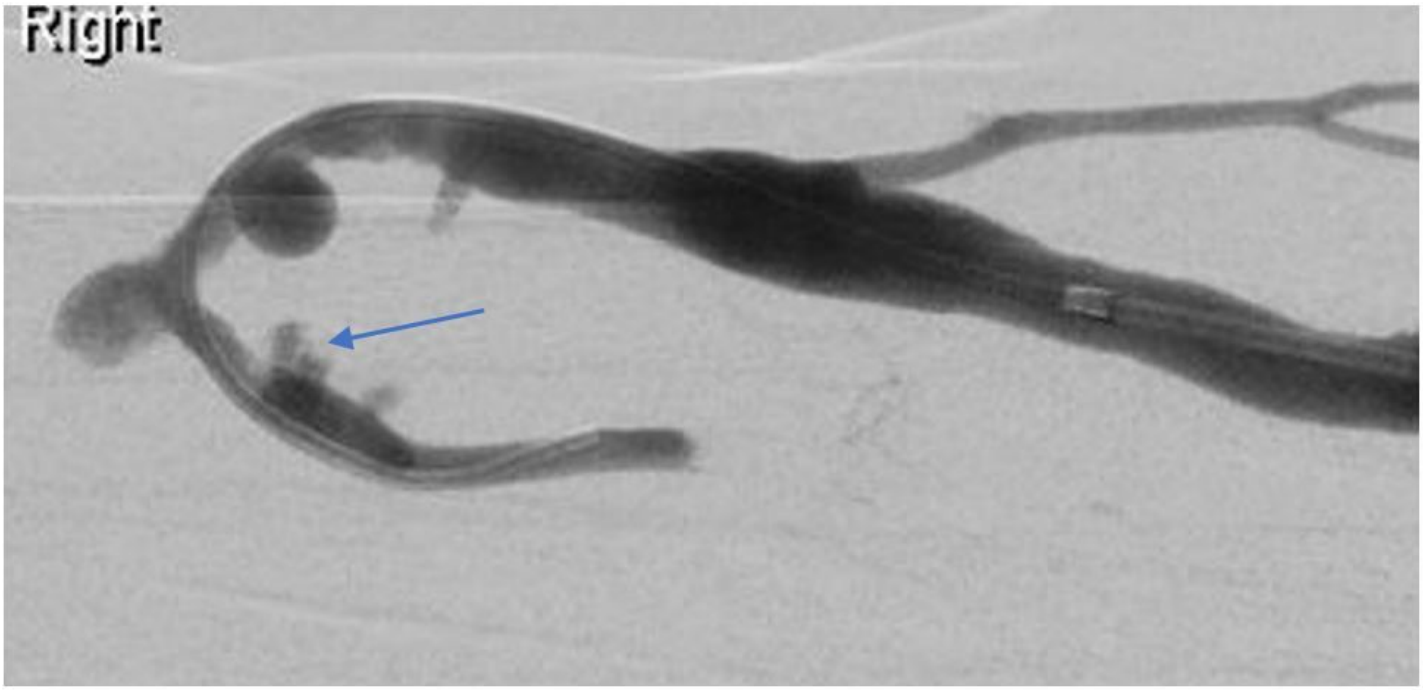

Figure 3

Formation of a pseudoaneurysm (blue arrow) within the short arterial segment



Figure 4

4mm BeGraft coronary stent-graft deployed within the arterial portion of the anastomosis to bypass the pseudoaneurysm

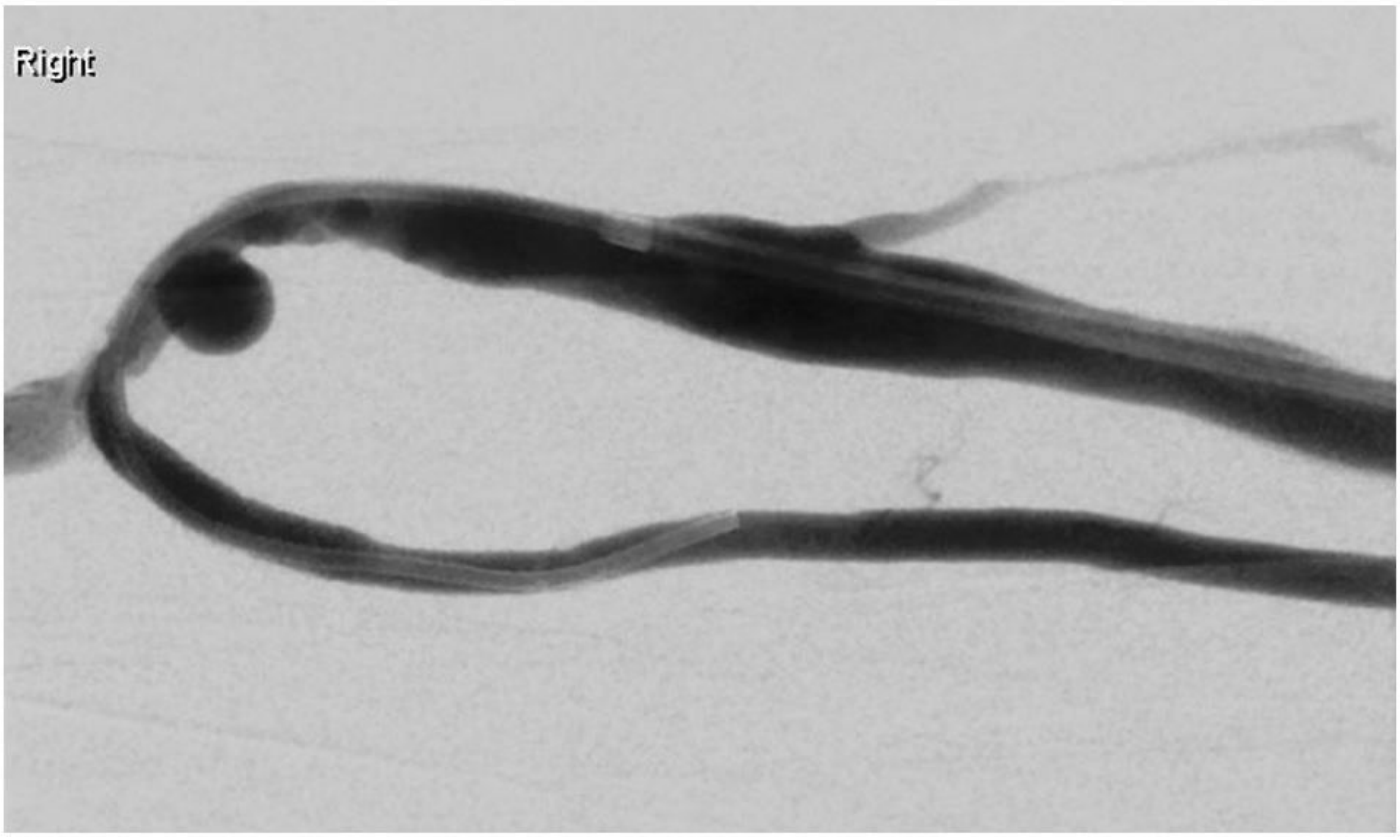

Figure 5

Completion fistulogram demonstrating no evidence of active contrast extravasation following successful stent-graft placement into the arterial segment