Retrospective comparative study of arthroscopy assisted loop-plate suture technique and a Hook plate for the treatment of distal clavicle fractures

Hui Wang (wanghui02@xinhuamed.com.cn)
Shanghai Jiaotong University School of Medicine Xinhua Hospital

Guiquan Cai
Shanghai Jiaotong University School of Medicine Xinhua Hospital

De Li
Shanghai Jiaotong University School of Medicine Xinhua Hospital

Chenglong Wang
Shanghai Jiaotong University School of Medicine Xinhua Hospital

Jiahong Zhang
Shanghai Jiaotong University School of Medicine Xinhua Hospital

Jiye He
Shanghai Jiaotong University School of Medicine Xinhua Hospital

Dongliang Wang
Shanghai Jiaotong University School of Medicine Xinhua Hospital

---

Technical advance

Keywords: Arthroscopy, Distal clavicle fracture, Hook plate, Coracoclavicular ligament

Posted Date: March 17th, 2020

DOI: https://doi.org/10.21203/rs.3.rs-17539/v1

Abstract

Abstract Purpose To compare the clinical effects of hook plate and AALS technique in the treatment of acute Neer II distal clavicular fracture. Methods 33 patients with Neer II distal clavicular fracture were included in this study. 15 patients were treated internal fixation with clavicular hook plate. 18 patients underwent fracture reduction with AALS technique. Constant-Murley and VAS scores were used to evaluate shoulder joint function and pain degree during follow-up. Karlsson score and shoulder joint X-ray was used to evaluate patients' satisfaction and the loss of reduction respectively. Results There were significant differences in amount of bleeding, Constant-Murley score and Karlsson score between these two groups (P<0.05). In the AALS group, we observed 3 cases with rotator cuff injury, 1 case with labrum injury during the operation. Two patients in AALS group had slight loss of reduction, but with no requirement of removal of internal fixation owing to discomfort. In hook plate group, 5 patients complained discomfort in shoulder movement and limited function after operation. At the last follow-up, 3 patients suffered from subacromial osteolysis accompanied by acromial impingement pain, and 2 patients with mild reduction loss. Conclusion For patients with Neer IIB distal clavicle fracture, AALS technique is superior to hook plate in shoulder joint function recovery and pain performance after operation, which is probably a novel reliable choice.

Introduction

Fractures of the distal clavicle are less common than midshaft fractures but they may lead to poorer functional outcome[1]. Approximately 21% to 28% of all clavicle fractures occur in the distal portion, and 10% to 52% of these are displaced[2]. Neer type I and type III fractures are usually treated conservatively because the proximal segment is stabilized by coracoclavicular ligament and the displacement of the fracture is small.In type II fractures, owing to the weight of the arm and the interaction of pectoral and latissimus dorsi muscles, as well as trapezius, fracture ends usually exhibits displacement and instability, especially in Neer type IIB styles. Owing to the fracture combined with rupture of coracoclavicular ligament in type IIB fractures, unstable and high rate of nonunion of fracture occur and always lead to poor shoulder joint function[3-4].

Several surgical treatments are available for distal clavicle fractures, including hook plates, anatomic locking plates as well as arthroscopic adjuvant therapy (flexible coracoclavicular fixation with mini-plate and suture). We performed a retrospective study of Neer IIB clavicular distal fracture treated with hook plate and a novel arthroscopy assisted Loop-plate suture(AALS) technology to compare their strength and weakness and recommend a suitable treatment.

Materials And Methods

45 patients with distal clavicle fracture admitted to our hospital orthopaedics department from 2016 to 2018 were analyzed. Inclusion criteria: 1) Neer type IIB distal clavicle fracture. 2) Patients with no abnormal in liver and kidney function and coagulation function. 3) Patients with no previous shoulder

pain. The exclusion criteria were as follows: 1) Neer type I and type IIa and typeIII-V of distal clavicle fracture.2) Injury combined with humerus proximal fracture. 3) Follow up period less than 2 years or midway lost.The clinical data of the two groups were analyzed and compared(Table 1).

Surgical treatment and rehibitiation guidence

All the surgical treatments were performed with patients in bench chair position under general anesthesia or brachial plexus anesthesia. In group A, we apply incision of the distal clavicle to expose the acromioclavicular joint**[Fig 1A]**. After temporary open reduction of fracture ends with Kirschner wire, the clavicle hook plate(AO Hook Plate; Synthes, Solothurn,Switzerland) was inserted under the acromion and the fracture ends were fixed by screws **[Fig 1B]**.

In group B, the posterior and lateral approach of shoulder arthroscopy was established**[Fig 1E]**. The glenohumeral joint was explored by arthroscopy for glenoid labrum, biceps tendon and rotator cuff. If combined injuries were explored, one-stage repair was performed immediately. Besides, the coracoid process was exposed to explore the laceration of coracoid ligament and to prepare for the assistant suture crossing under the arthroscopy. In the fracture area near acromioclavicular joint, a 5 cm longitudinal small incision was taken to expose the distal fracture ends **[Fig 1E].** Two clavicle bone marrow canals were constructed with 3.5mm drill bits at 2.0cm and 4.5cm to the distal clavicle respectively. Under the arthroscopic monitoring of lateral approach, the coracoid process basement was in the middle position**[Fig 2A]**. Hollow drilling holes with 2.5 mm diameter Kirschner wires were drilled. Two Fiber tape (Rigidloop Depuy Synthes, USA) threads were delivered through the coracoid process from top to bottom using lumbar puncture needle and PDS wire combined with arthroscopic thread passing technology**[Fig 2B]**, and then the four threads of the two wires were respectively pulled into two collarbone tunnels and pulled out of the body above the clavicle.

Two Fiber tapes under the coracoid process were linked throuth the Dog bone plate (Arthrex, USA)**[Fig 2C]**. Four threads above the clavicle were pulled vigorously and carefully to make the Dog bone plate cline to the underside of coracoid**[Fig 1H]**. We insert the tapes into the two loops of steel plates which cling to the clavicle surface, tightened the four ends of Fiber tape, and then knotted and fixed the Fiber tapes onto the plate surface**[Fig 1F].**Finally, we pulled out the temporary Kirschner wire, moved the shoulder joint, and ensured there is no reduction losing under C arm machine scanning, then we finally closed the wound layer by layer.

Postoperative rehabilitation

After the operation, the patients received routine anti-inflammatory, anti-swelling and analgesic supportive treatment. The patients wore an arm sling for 3 to 4 weeks to limit movement of the injured shoulder. Passive lifting and "pendulum-like" movement of affected limb were carried out on the third day after operation with the assistance of the healthy limb. Four weeks later, strength training was gradually strengthened to increase the range of motion of shoulder joint, and normal exercise and work were resumed three months after operation.

Clinical and radiological assessment

All patients were followed up and radiographs were taken to evaluate fracture healing. The differences of operation time, intraoperative bleeding, hospitalization period and medical cost between two groups were statistically analyzed. Constant-murley shoulder score and visual analog scale (VAS) score were applied at the first, third, sixth, 12th and 24th months after surgery to evaluate shoulder joint function and pain status. At the last follow-up (24th months), the efficacy of the surgery was evaluated using the Karlsson efficacy grading criteria. In the last follow-up, through x-ray, we defined the postoperative failure and loosening as the lower margin of the operative distal clavicle rising above the upper margin of the corresponding acromion.

Statistical analysis

SPSS16.0 software was used for data processing. Constant score and VAS score of measurement data were compared by Wilcoxon rank sum test. $P<0.05$ was considered statistically significant.The counting data were obtained by Fisher's exact probability method.$P < 0.05$ was considered statistically significant.

Ethics statements

The study protocol was approved by Shanghai jiaotong university school of medicine affilated Xinhua Hospital ethics committee（Approval No. XHEC-D-2019-036）. All patients participating in the study provided verbal informed consent.

Results

A total of 33 patients were final included in this study. Among this, the hook plate group(Group A) comprised 15 patients. The shoulder arthroscopic assisted loop plate-suture reconstruction group(Group B) comprised 18 patients. Patients' incision in both groups got stage Ⅰ healing, combined with no blood vessel and nerve injury and early complications such as infection. Patients in two groups were comparable in age, injured side, sex (Table 1). There was no significant difference in medical cost and hospitalization time between two groups (Table 2). The intraoperative blooding in Group A was significantly higher than Group B. The operation time in group A was significant shorter than Group B. During postoperative follow up, 5 patients in Group A seeked early removal of internal fixation owing to unacceptable discomfort with shoulder movement. Among these, 3 patients suffered from subacromial osteolysis accompanied by acromial impingement pain. 2 patients in Group A got hook plate loose displacement because of early weight-bearing activity such as driving and housework. In group B, patients have achieved good reduction and bone healing without osteolytic reaction adjacent to the clavicle during follow-up periods. 2 patients in group B got internal fixation loose at 2 and 3 months postoperative respectively, but with no complain of discomfort and limited shoulder function.

In Group B, during the operation, we observed a total of 3 patients suffered rotator cuff tear injuries of different degrees (3/18 incidence), including 2 cases of supraspinatus tear**[Fig 3A]** and 1 case of

subscapularis tear**[Fig 3C]**. There was another patient who suffered from labrum injury of shoulder joint (1/17). All of them received a one-stage patch**[Fig 3B,D]** during the operation.

The postoperative follow up were conducted to evaluate the function of shoulder joint. The constant-murley score in Group B showed significantly higher than Group A at 3, 6, 12 and 24months after surgery (Table 3) . The VAS score in Group B showed obvious decreased than Group A at3, 6 and 12 months after surgery($P<0.01$).

At the last follow-up, patient satisfaction score (Karlsson efficacy evaluation criteria) and x-ray assessed reduction failure/loose were evaluated: the overall performance of Group B was better than Group A. (Table 4).

Discussion

The distal end of the clavicle has a complex anatomical relationship due to the presence of the coracoclavicular ligament in addition to its bony structure. The fracture type of distal clavicle are usually short oblique or comminuted with coracoclavicular ligament especially conic ligament tears. Owing to the losing of press-down effect of coracoclavicular ligament, it is difficult to maintain the integrity and continuity of the distal clavicle through non-surgical treatment[5]. Besides, there is growing demand for early recovery and activity, surgical treatment become the mainstream. Therefore, the purpose of surgery is to restore the complete continuity of the clavicle and achieve the torque balance at the distal end of the clavicle.

Since the 1970s, clavicle hook steel plate, which utilize the lever principle to achieve the reduction of fracture has been widely used[6-7]. However, with the extension of follow-up, we observed there still existed many problems with the application of hook steel plate.1) hook plate design is not anatomic plate, which often requires intraoperative shaping. During the operation, hook plate is prone to excessive reduction of acrominoclavicular joint, resulting in postoperative pain in acromion. 2) the clavicle hook has been located in the subacromial area for a long time, which squeezes the space, and is prone to cause acromial impingement, acromial dropping bursitis, and even subacromial osteolysis. 3) Long-term placing of hook steel plate could cause complain of shoulder discomfort, which often requires surgical removal, and may lead to a certain degree of reduction loss of acromioclavicular joint after removal of the plate[8-10].

In recent years, scholars have attempt to apply loop plate and suture technique to get anatomic reconstruction of acromioclavicular joint through elastic compression fixation at clavicle and coracoid process[11-12]. Most of them performed single-bundle reconstruction of coracoclavicular ligament. In this study, we adopted an novel technology with arthroscopy assisted loop plate suture to repair the fracture end and reconstruct the coracoclavicular ligament. On the one hand, it increases the strength of acromioclavicular joint reduction through suture tightening. On the other hand, this technology is more in accordance with the acromioclavicular joint biomechanics under physiological conditions. In addition, we

apply arthroscopic technology during the operation, which helps comprehensively observe and evaluate the shoulder joint and assist suturing through the tunnel.

In addition in this study of Group B, we observed a total of 3 patients combined with rotator cuff injuries of different degrees (3/18 incidence), including supraspinatus or subscapularis tear. There was another patient who suffered from labrum injury. All of them received intraoperative one-stage repair**[Fig 3B,D]**, which effectively avoided the omission of shoulder disease and effectively guarantee the recovery of the shoulder joint after surgery. In addition, assisted by shoulder arthroscopy during the operation, the loop plate crossing process is effectively shortened, which is helpful to shorten the operation time, reduce soft tissue dissection.

In the pursuit of minimally invasive arthroscopic surgery, we should pay attention to the following points: 1. Be familiar with the anatomy and characteristics of shoulder joint and reduce nosocomial damage. 2. When exploring and separating the coracoid process base with arthroscopy, excessive exposure is not recommended to reduce the damage to blood vessels and nerves. In addition, when drilling the coracoid process side under the arthroscopy, the insertion point should be carefully considered and should not be excessively forward or backward to avoid the coracoid process exploding. We once blew the coracoid process out during drilling in 2 cases. If necessary, we need to make a small longitudinal incision in the coracoid process and drill a hole in the coracoid process under direct vision.The loop plate (Rigidloop Depuy Synthes, USA) we choose in this study has unique advantage comparing to some other elastic loop plates**[Fig 2 C]**.The suture in this loop is so tight that once be tighten it can barely slide even with no suture knot, which greatly reduce the risk of suture loose.

The limitations of this study were small sample size and the retrospective design. This was largely because such fractures are rare. However, the results were comparable to the main other research[12-14].The clinical significance of this study lies in the observation that the loop plate-suture technique can be adopted as a considerable choice for the treatment of Neer type IIB distal clavicle fracture. Besides, it also provides an inspiring functional outcome and allows arthroscopic treatment of associated lesions in the procedure without requiring later implant removal.

In conclusion, this study has demonstrated that, compared to the hook plate technique, the arthroscopy assisted loop-plate suture technology presents a satisfactory functional outcome and minimize the risk of complications and the odds of implant removel in patients with Neer type IIB distal clavicle fracture.

Declarations

Acknowledgements

The authors thank Mr Xiao-dong Chen for English revision and technical guidance of this manuscript.

Funding information

This research was funded by the National Natural Science Foundation of China (NSFC) (81601866) and Shanghai Health Commission Special Clinical Found(20184Y0124)

Conflict of Interest

The authors declare that they have no conflicts of interest.

References

1 Sautet P, Galland A, Airaudi S, Argenson JN, Gravier R (2018) Arthroscopy-assisted fixation of fracture of the distal part of the clavicle by subcoracoid suture and clavicle button.Orthop Traumatol Surg Res 104: 1237-1240.

9 Singh Anshuman,Schultzel Mark,Fleming John F (2019) Complications after surgical treatment of distal clavicle fractures.Orthop Traumatol Surg Res 105: 853-859.

3 Suter C, von Rohr M, Majewski M, Dürselen L, Warnecke D, Schild N. et al (2019) Biomech (Bristol, Avon) 67: 78-84.

4 Yagnik GP, Brady PC, Zimmerman JP, Jordan CJ, Porter DA (2019) A biomechanical comparison of new techniques for distal clavicular fracture repair versus locked plating.J Shoulder Elbow Surg 28: 982-988.

5 Asadollahi Saeed,Bucknill Andrew(2019) Hook Plate Fixation for Acute Unstable DistalClavicle Fracture: A Systematic Review and Meta-analysis.J Orthop Trauma 33: 417-422.

6 Hsu KH, Tzeng YH, Chang MC, Chang CC (2018) Comparing the coracoclavicular loop technique with a hook plate for the treatment of distal clavicle fractures.J Shoulder Elbow Surg 27: 224-230.

7 Lopiz Y, Checa P, García-Fernández C, Valle J, Vega ML, Marco F (2019) Complications with the clavicle hook plate after fixation of Neer type II clavicle fractures. Int Orthop 43: 1701-1708.

8 Erdle B, Izadpanah K, Jaeger M, Jensen P, Konstantinidis L, Zwingmann J (2017) Comparative analysis of locking plate versus hook plate osteosynthesis of Neer type IIB lateral clavicle fractures. Arch Orthop Trauma Surg 137: 651-662.

9 Zlein SM, Badman BL, Keating CJ, Devinney DS, Frankle MA, Mighell MA (2010) Results of surgical treatment for unstable distal clavicular fractures.J Shoulder Elbow Surg 19: 1049-55.

10 Dumont GD, Russell RD, Knight JR, Hotchkiss WR, Pierce WA, Wilson PL et al (2013) Impact of tunnels and tenodesis screws on clavicle fracture: a biomechanical study of varying coracoclavicular ligament reconstruction techniques. Arthroscopy 29:1604-7.

11 Loriaut P, Moreau PE, Dallaudière B, Pélissier A, Vu HD, Massin P, et al (2015) Outcome of arthroscopic treatment for displaced lateral clavicle fractures using a double button device. Knee Surg Sports

Traumatol Arthrosc 23: 1429-33.

12 Soliman O, Koptan W, Zarad A (2013) Under-coracoid-around-clavicle (UCAC) loop in type II distal clavicle fractures. Bone Joint J 95-B:983-7.

13 Zhang C, Huang J, Luo Y, Sun H (2014) Comparison of the efficacy of a distal clavicular locking plate versus a clavicular hook plate in the treatment of unstable distal clavicle fractures and a systematic literature review. Int Orthop 38:1461-8.

14 Struhl Steven,Wolfson Theodore S (2016) Closed-Loop Double Endobutton Technique for Repair of Unstable Distal Clavicle Fractures.Orthop J Sports Med 4: (7).

Figures

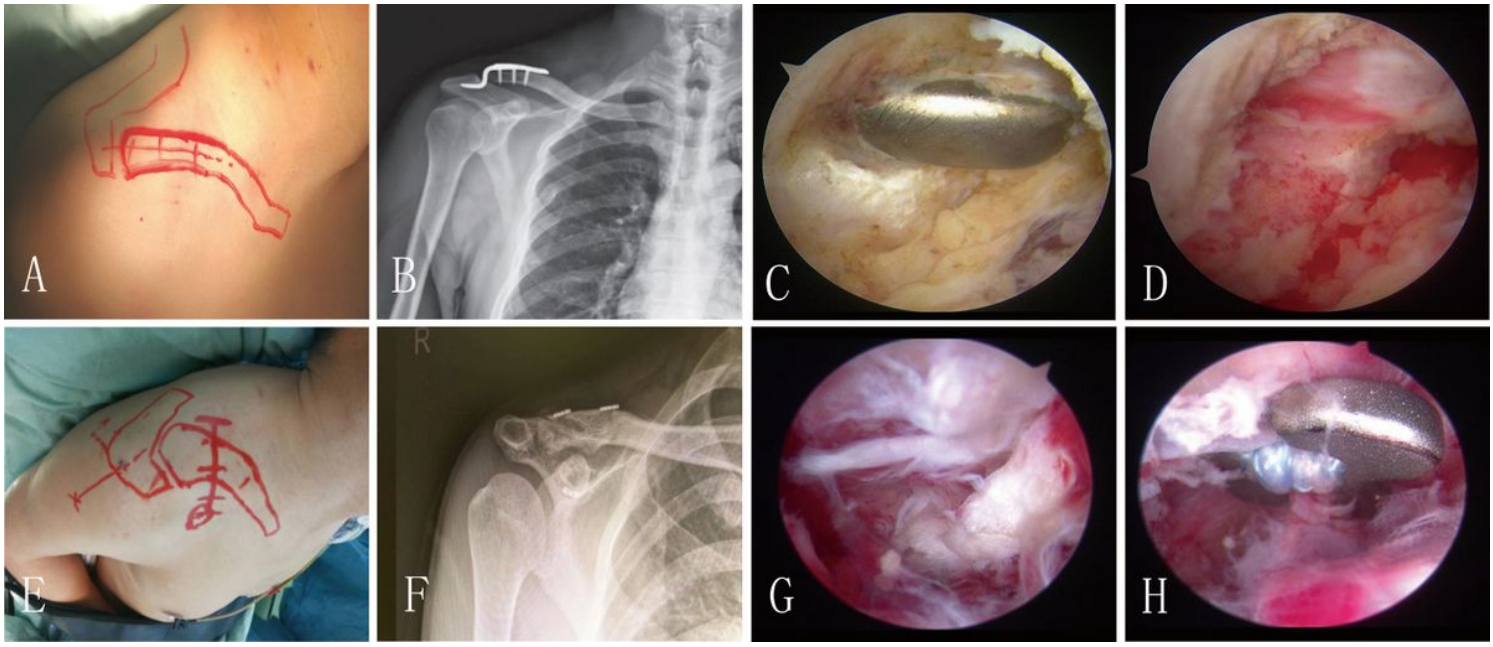

Figure 1

Illustructions of Hook plate and loop-plate technology for distal clavicle fracture. (A-B):Hook plate surgery preoperative positions and postoperative X-rays. (C-D): Subacromial presentation with arthroscopy when hook plate was taken out. (E-F): Arthroscopy assisted loop-plate suture technique(AALS) preoperative positions and postoperative X-rays.(G): The shoulder arthroscopy observed the coracoid ligament rupture during the operation. (H): The shoulder arthroscopy scanned the placing of dog bone plate under the coracoid during the operation.

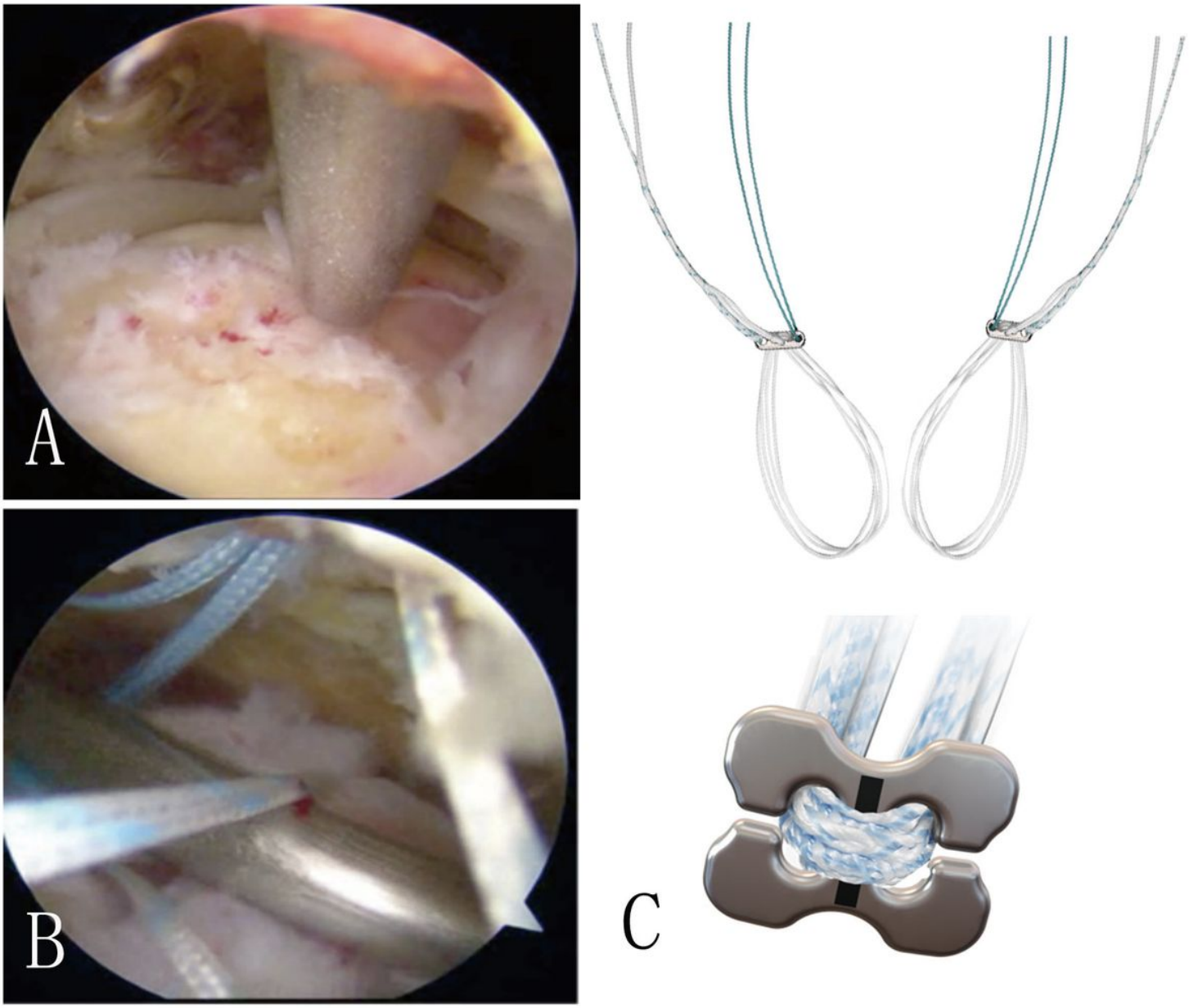

Figure 2

Intraoperative rotator cuff injury were observed and repaired under arthroscopy.(A-B):The shoulder arthroscopy scaned combined supraspinatus muscle tearing and one-stage repairing by anchor.(C-D): The shoulder arthroscopy scaned combined subscapular muscle tearing and one-stage repairing by anchor.

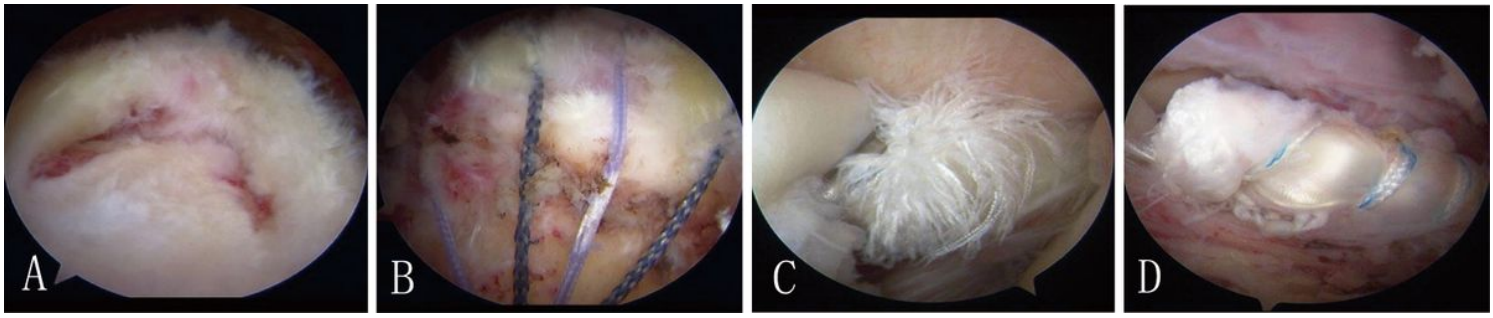

Figure 3

Illustractions of arthroscopy assisted surgery and loop-plate technology. (A-B): Arthroscopy assist coracoid process drilling and suture passing.(C):Loop-plate suture technology combined with dog bone plate applied for the surgery.

Supplementary Files

This is a list of supplementary files associated with this preprint. Click to download.

- Table.doc