Hemivertebra Resection Combined With Wedge Osteotomy for Treatment of Severe Rigid Congenital Kyphoscoliosis in Adolescence

Xinhua Yin
department of spine surgery, HongHui Hospital

Liang Yan
department of spine surgery,HongHui hospital

Baorong He
the department of spine surgery, HongHui Hoipital

Ding Jun Hao
the department of spine surgery, HongHui Hospital

Zhongkai Liu (spine2020@163.com)
department of spine surgery, HongHui Hospital

Research article

Keywords: Congenital, Severe Rigid Kyphoscoliosis, Adolescence, Hemivertebra Resection, Wedge Osteotomy

Posted Date: March 17th, 2020

DOI: https://doi.org/10.21203/rs.3.rs-17556/v1

Abstract

Background

There was a controversy about surgery approach of severe rigid congenital kyphoscoliosis in adolescence treatment. Aim of the study is to compare the clinical efficacy of surgical treatement by hemivertebra resection (HR) and hemivertebra resection combined with wedge osteotomy (HRWO) for severe rigid congenital kyphoscoliosis in adolescence.

Methods

Twenty-five patients with severe rigid congenital kyphoscoliosis between Jan 2006 and Dec 2011 were studied in our center. The patients were divided into hemivertebra resection group (group HR) or hemivertebra resection combined with wedge osteotomy group (group HRWO). The clinical and radiographic evaluation in terms of operation time, blood loss, correction rate, fusion time, hospital stay, complications and SRS-24 questionnaire score were compared between Group A and Group B.

Results

It is obvious that group HR achieved much better results in time of operation time, intra-operative blood loss, and hospital stay than group HRWO ($P < 0.05$). But meanwhile, group HRWO was significantly better than group HR in the times of coronal Cobb angle, kyphosis, the sagittal imbalance, coronal imbalance and SRS-24 questionnaire score ($P < 0.05$). There were no significant differences between the two groups in the age, mean flexibility, follow-up time, fusion time, and complications in the last follow-up ($P > 0.05$).

Conclusion

The outcomes of follow-up showed that the hemivertebra resection combined with wedge osteotomy approach obtained better clinical outcomes hemivertebra resection surgery. It might be a better surgical treatment for severe rigid congenital kyphoscoliosis in adolescence patients, but it needs longer operation time, more intra-operative blood loss, and extended hospital stay.

Introduction

Congenital scoliosis is generally secondary to a formation failure or a failure of segmentation that results in a wedgeshaped vertebra with only one pedicle on one side is named hemivertebra. It is estimated that 46% of congenital scoliosis patients are hemivertebral deformity [1]. The hemivertebra can be classified three types: fully segmented, partially segmented, or unisegmented [2]. Fully segmented hemivertebra is the most common type among them [3]. When the hemivertebra is fully segmented and unincarcerated the concavity of the congenital curve is unable to keep pace with the added growth of the hemivertebra on the convex side of the curve. Therefore, the fully segmented hemivertebra associated with severe progressive scoliosis. If the hemivertebra is located in the posterior part of the spine, it can be associated with kyphoscoliosis. Early treatment of progressive deformities helps in minimising the surgery risks and

allows better correction and prevents the development of structural and compensatory curves [4–6]. Various surgical hemivertebra excision treatments (for example, anterior, posterior, and combined and 2-stage approaches) have been performed on children with congenital kyphoscoliosis or kyphosis [7, 8]. However, the untreated nonincarcerated hemivertebra may result in large and stiff scoliosis or kyphoscoliosis, particularly during the adolescent growth spurt [9, 10], and occasionally can even lead to the compression of spinal cord. In other words, it is more challenging for the surgeons to treat severe rigid congenital kyphoscoliosis in adolescence. [11]. Even if removed of the hemivertebra and the upper and lower disc, it may be unable to get a good correction owing to the adjacent vertebra remain rigid. Till date, there was few studies of surgical treatment for adolescence patients with severe rigid congenital kyphoscoliosis. In our hsopital, we performed hemivertebra resection combined with wedge osteotomy (HRWO) for severe rigid congenital kyphoscoliosis in adolescence. This study compares the clinical outcomes of hemivertebra resection (HR) and hemivertebra resection combined with wedge osteotomy (HRWO) for for severe rigid congenital kyphoscoliosis in adolescence.

Materials And Methods

This study was approved by the ethics board committee of our hospital. We preformed retrospective study of 25 adolescence patients with severe rigid congenital kyphoscoliosis in our center from Jan 2006 to Dec 2011. Inclusion criteria: single hemivertebra, fully segmented nonincarcerated, adolesencet patients(range,12–20 years old), kyphoscoliosis with coronal or sagittal Cobb's angle greater than 60 °and curve flexibility less than 25%. There were 3 thoracic hemivertebrae (T1–T10), 17 in the thoracolumbar region (T11–L2) and 5 in the lumbar region (L3–L5). All patients were a Risser Stage 4 or 5 on presentation. The diagnosis of congenital kyphoscoliosis was based on clinical presentation, radiologic findings (plain radiograph, computed tomography and magnetic resonance imaging). The patients were divided into hemivertebra resection group (group A) or hemivertebra resection combined with wedge osteotomy group (group B). Group A had 5 males and 7 females, with an average age of 15.1 years old. Group B had 6 males and 7 females, with an average age of 16.5 years old. Standing full-length posteroanterior and lateral radiographs were taken. The main, segmental, cranial, and caudal compensatory curves were measured from the posteroanterior (PA)-radiographs and thoracic kyphosis, lumbar lordosis, and segmental kyphosis or lordosis were measured from the lateral radiographs by the Cobb angle. Lateral decompensation was determined as the horizontal distance of the spinous process of C7 from the center sacral line measured in millimeters. Sagittal balance was measured from the lateral projection with a similar method by dropping a vertical line from the middle of C7 vertebral body and measuring the horizontal distance of the uppermost portion of S1 vertebral body from this vertical line. The distance from the pedicle one segment above the hemivertebra to the pedicle one segment below was measured in millimeters in the concave and convex sides of the scoliosis from the PA radiograph. The shortening of the spinal column, which resulted from the hemivertebra resection, was regarded as the difference between the pre- and postoperative distances. Clinical outcome was evaluated preoperatively and at the final follow-up using the SRS-24 questionnaire. (Patients' general information is shown in Table 1).

Table 1
Preoperation and Surgical Data

	Group HR(n = 12)	Group HRWO (n = 13)	p value
Age (years)	15.1(12.6–17.3)	16.5(13.3–20.1)	0.05
Mean flexibility(%)	16(10–24)	14(8–20)	0.05
Blood loss (ml)	760(450 ~ 900)	980(600 ~ 1100)	<0.05
Operative time(mins)	4.3(2.5 ~ 5.8)	5.4(3.3 ~ 6.5)	<0.05
Hospital stay (days)	8(6–14)	11(8–17)	<0.05
Fusion time (mons)	7(5–9)	8(5–10)	0.05
Follow-up time(yr)	2.5(2–6)	1.8(1.5–2.5)	0.05
Complications	2	2	

Operative Technique

All patients were treated by posterior hemivertebra resection with pedicle screws. The patient was placed in the prone position. Spinal cord monitoring is used for all patients. The posterior elements on the convexity are carefully exposed, including the surplus rib head on the convex side of the thoracic spine. The transverse processes, rib heads, and approximately 5 cm of the proximal portion of the ribs were excised to expose the pedicle and the nerve roots above and below. The pleura was protected carefully. Then the lateral cortex of the hemivertebra was exposed by blunt dissection. For cases in which the apical vertebra was at the thoracic level, the intercostal nerve roots were severed, but if the apical vertebra was at the lumbar level, the lumbar nerve roots were spared. After exposure was completed, pedicle screws were inserted into the vertebrae, usually two above and two below the apical vertebra. Preflexed rods were connected using previously inserted pedicle screws to stabilize the spine..first, Osteotomies were used to remove the vertebra body along the cartilage endplate(Fig. 1)., then the upper and lower discs, including the cartilage endplate, were completely removed, Osteotomy of hemivertebra resection is completed.

A compression force was applied to shorten the spinal column, and the osteotomy site was closed gradually while the curvature of the rods was adjusted. During this procedure, we found that the operation fail to shorten the spine column in a lot of patients, because the adjacent spinal segments remain rigid. At this time, we decided to wedge osteotomy to removal of partly body of adjacent segments,that is, “V”shaped bone resection of the adjacent vertebral body to obtain more motivation. As this step proceeded, the spinal cord swelled up posteriorly, and for cases in which the spinal cord kinked at the edge of the laminectomy, the laminectomy was extended cranially and caudally. During this procedure, spinal cord function was monitored frequently. If changes in potentials were evident, further correction

was halted, and the spine was returned to its state immediately before the change. After correction and stabilization was completed by instrumentation, adequate bone grafts were implanted anteriorly and posteriorly. Sometimes the space can be placed titanium mesh cage, and the wound was closed in the standard fashion. Intraoperative radiographs are obtained before closure of the wound.

Post-operative Management

Antibiotics were given during the first 24 hours postoperatively. The drainage tube was removed when drainage volume was less than 20 ml/24 hours. Patients were braced in a Thorax Lumbar Sacrum Orthosis (TLSO) for 6–9 months postoperatively. X-ray examination was performed every three months.

Statistical Analysis

The statistical data was analyzed with using SPSS 19.0. The pre- and postoperative data in Intra-group were compared with Student's t test. Comparisons between groups using chisquared test and Student's t test. Differences were considered significant at $P < 0.05$. The measurement data are recorded as mean ± standard deviation.

Results

The average age at operation was 15.1 years (range,12.6–17.3 years) and 16.5 years (range, 13.3–20.1 years) in HR and HRWO groups, respectively. The mean follow-up time after surgery was 2.5 years (range, 2.0–6.0 years) in HR group and 1.8 years (range, 1.5–2.5 years) in HRWO group. More details are given in Table 1.

Operative Findings

The average bleeding were 760(450–900 mL) in HR group and 980 mL (range, 600–1100 mL) in HRWO group ($P<0.05$). The average operation times were 4.3 hours (range, 2.5–5.8 hours) and 5.4 hours (range, 3.3–6.5 hours), respectively ($P<0.05$). There were no neurological complications. There were no instances of infection or muscle necrosis.

Radiographic Outcomes

The mean coronal Cobb angle was measured as 50.9°before surgery,25°after surgery and 29°at the latest follow-up for HR group; 62°, 20°and 22°for HRWO group. The correction ratio was 51% in HR group and 68% in HRWO group ($P<0.05$). The loss of correction was 8% in HR group and 3% in HRWO group B ($P<0.05$). Preoperative kyphosis of 65 °in HR group was corrected to 26 °after surgery and 28°at the latest follow-up; 72°, 10°and 15°for HRWO group. The correction ratio was 60% in HR group A and 86% in HRWO group ($P<0.05$). The mean preoperative coronal imbalance of 3.5 cm was corrected to 1.5 cm

(57.1% correction) and the sagittal imbalance of 2.8 cm was corrected to 1.3 cm (53.6% correction)in HR group; 4.0 cm,0.5 cm(83.8% correction) and 2.9 cm,0.4 cm (90.3% correction) in HRWO group. (P<0.05) More details on radiographic outcomes can be seen in Table 2.

Table 2
Radiographic Outcomes

	Group HR(n = 12)	Group HRWO (n = 13)	p value
Main curve(°)			
Preoperatively	50.9(45–60)	62(56–80)	0.05
Postoperatively	25(20–39)	20(15–30)	<0.05
Correction %	50.9%	67.7%	<0.05
Final follow-up	29.0(20–39)	22(10–28)	<0.05
Loss of correction	8%	3%	<0.05
Kyphosis(°)			
Preoperatively	65(40–76)	72(63–95)	<0.05
Postoperatively	26(20–36)	10(5–15)	<0.01
Correction %	60%	86.1%	<0.05
Final follow-up	28(10–36)	13(10–20)	<0.01
Loss of correction	3%	4%	0.05
Coronal imbalance(mm)			
Preoperatively	35(25–42)	40(23–44)	<0.05
Final follow-up	15(10–23)	5(3–10)	<0.01
Sagittal imbalance(mm)			
Preoperatively	28(15–30)	29(19–35)	<0.05
Final follow-up	13(5–15)	4(0–9)	<0.01

SRS-24 Outcome Questionnaire

The mean total SRS-24 score for the whole group was immediately after surgery 83.8 (range, 56–99) and 100.3 (range, 85–109) at the FFU (P<0.01). The mean total scores tended to be better immediately after surgery in B (87.3 [range, 76–99]) than in A (79.2 [range, 56–94]) group (P0.05). And at the FFU the SRS-

24 total scores were on average 101 (range, 89–101) for HR group and 104 (range, 90–108) for HRWO group (P<0.05). The 7 main domains of the SRS-24-questionnaire are shown in Fig. 1.

Discussion

To our knowledge, most studies on congenital kyphoscoliosis or kyphosis concern pediatric patients, there is a minority of research referring to the surgical treatment of severe rigid congenital kyphoscoliosis in adolescence. Most of congenital kyphoscoliosis in adolescence fail to be cured by conservative treatment because of an unacceptable cosmetic appearance, progression of deformity or neurological dysfunction [12–14]. Surgical correction of congenital curves is generally more successful when high-risk curves of a smaller magnitude are treated early. Compare with younger patients, the skeletal of adolescence is the nearly maturity. The delayed treatment of adolescence congenial deformity result in the secondary structural curves and therefore requires long fusion segments. In other word, it is difficulty to correct the rigid curves and associated with a higher risk of neurologic impairment [15].

The ideal surgical approach for severe rigid congenital kyphoscoliosis in adolescence is controversial. In the past, most surgeons confirmed that one-stage posterior hemivertebra excision with short segmental fusion is a feasible procedure for congenital kyphoscoliosis in patients [16, 17]. Nevertheless, the majority of series were younger patients in whom deformity were mild. It is unknown whether the surgery approach effectively applied in adolescent congenital deformity with rigid and severe kyphoscoliosis. Ruf and Harms [18] reported that hemivertebra resection by the posterior-only procedure. They reported the good results of their study. However, in the series, most of the patients were children, the spinal deformity fail to become rigid and severe. In 2003, David et al [19] reported two cases of adults presenting with fully segmented thoracic hemivertebrae who underwent one-stage posterior hemivertebra excision with short segmental fusion. There were no neurological complications. However, the patients present with rigid and mild deformity. In 2011, Li et al [20] reported that twelve patients with adolescent congenital deformity who underwent posterior unilateral pedicle subtraction osteotomy and short-segment instrumentation. The mean age of the series was 17 years (range, 15–21 years). They considered that the approach could be easily and effectively applied in adolescent congenital deformity with mild and moderate scoliosis. In our series, 12 patients underwent hemivertebra excision and long instrumentation, the mean rates of correction of the major and segmental curves were worse to the reported results of hemivertebra excision in patients. Hence, for severe rigid kyphoscoliosis in adolescence, hemivertebra excision and long instrumentation often fail to effectively correction correct combined deformities. Therefore, the authors adopted a new method, combining hemivertebra resection with wedge osteotomy in only posterior procedure, and this new method is named “HRWO”

The posterior osteotomies approaches for the treatment of severe rigid spinal deformities have been performed in the last years. In 1979, Leatherman et al [21], reported that excellent correction of closing wedge osteotomy for rigid congenital deformity in pediatric patients. They reported a correction of 43% of scoliotic curves postoperatively. However, two patients having transient neurologic deficit. Gertzbein et al [22] reported “wedge osteotomy”; and Kawahara et al [23] reported “closing–opening wedge osteotomy.”

However, the majority of patients presented mild angular kyphosis. Mehment et al [24] reported that surgical treatment of congenital kyphoscoliosis in adolescent by posterior multiple chevron osteotomies, multiple concave rib osteotomies and all-pedicle screw instrumentation. Chevron osteotomies were performed at apical segments (three to seven levels) and concave rib osteotomies (five to eight levels). They considered that the approach can effectively correct kyphoscoliosis deformities in adolescent. However, as opposed to the current study, few patients with severe rigid kyphosis caused by congenital spinal deformity was included. Therefore, in this study, we selected kyphoscoliosis cases with coronal or sagittal Cobb's angle greater than 60° and curve flexibility less than 25%. All patients had a single nonincarcerated hemivertebra. During this procedure, we found that simply HR fail to completely removed of the disc materials located at the concave side, so the adjacent spinal segments remain rigid. We performed wedge osteotomy to removal of partly body of adjacent segments, that is, "V"shaped bone resection of the adjacent vertebral body,including the disc materials located at the concave side and both endplate of adjacent segments to obtain more motivation.

We performed posterior wedge osteotomy improve the flexibility of spine, and the spinal cord fail to be stretched because of shortening the posterior structure. Anterior column reconstruction was performed with titanium mesh in the series. We formed titanium mesh in accordance with anterior column interbody gap after wedge osteotomy and deformity correction. After that, the titanium was inserted in the anterior column interbody gap. It is no shorten the anterior column. The titanium mesh provided immediate anterior stability, and can tolerate compression forces well [25]. The rate of solid fusion was 100% in all series at the last follow-up. No crankshaft phenomenon occurred in the series, and because not only all patients with Risser 4 or 5 which the skeleton nearly mature, but also posterior pedicle screw system.

One major concern of HRWO is the risk for blood loss during the posterior osteotomy. The previous research confirmed that a large bleeding may lead to increase postoperative complications and morbidity rates in spinal osteotomy [26]. The following measures have been taken in order to reduce perioperative blood loss. The subperiosteal dissection was performed during the surgical exposure. The intravenous drip of tranexamic acid were routinely received and the wound are irrigated with tranexamic acid during the operation. In addition, it is critical to use Piezosurgery and bipolar electrocautery to control blood loss. Besides, the controlled hypertension is applied to decrease intraoperative blood loss during the operation. There is another issue to concern is neurological complications which may occur from spinal cord compression, dural strctching or buckling, and subluxation of the spinal column. It is critical to completely disclose nerve roots and dural tube before wedge osteotomy. In addition, the spinal cord monitoring is essential for osteotomy, especially when we performed closure of the wedge bone resection. There were 2 patients occurred MEP changes after closure of the wedge bone resection, but none was permanent. There were lower neurological complications in our cohorts. One possible reason is that anterior column reconstruction was performed with titanium mesh in the series, which have contributed to prevent overshortening of spinal column and dural buckling. Another reason may be that use of piezosurgery and spinal cord and nerve roots were under direct observation during the HRWO.

Conclusion

One-stage posterior hemivertebra resection combined with wedge osteotomy is an safe and effective procedure for adolescent patient with fixed kyphoscoliotic deformity. Compare with hemivertebra resection, it might be a better surgical treatment for severe rigid congenital kyphoscoliosis in adolescence patients, but it needs longer operation time, more intra-operative blood loss, and extended hospital stay.

Abbreviations

HR: hemivertebra resection, HRWO: hemivertebra resection combined with wedge osteotomy, SRS-24 score: Scoliosis Research Society-24 Questionnaire, TLSO: Thorax Lumbar Sacrum Orthosis, MRP: motor evoked potential monitoring, PA: posteroanterior

Declarations

Ethics approval and consent to participate

This study is a retrospective clinical study and has been approved by the HongHui Hospital Ethics Committee. All patients had signed the consent form.

Consent for publication

Not applicable.

Availability of data and material

The datasets used and/or analyzed during the current study are available from the corresponding author on reasonable request.

Declarations

The authors declare that they have no conflicts of interest.

Funding

This publication was funded by Natural Science Foundation of the Department of Science and Technology of ShanXi province (2019JM-200)

Authors' contributions

ZKL contributed to the study design. DJH performed the surgery, LY collected the data. BRH analyzed the data. XHY wrote the manuscript. All authors read and approved the final manuscript.

Acknowledgements

Not applicable.

References

1. Loughenbury PR, Gummerson NW, Tsirikos AI(2017). Congenital spinal deformity: assessment, natural history and treatment. Orthopaedics and Trauma, 31(6), 364-369.
2. Winter RB, Moe J, Lonstein J(1984) Posterior spinal arthrodesis for congenital scoliosis. An analysis of the cases of two hundred and ninety patients, five to nineteen years old. J Bone Joint Surg 66:1188–1197
3. Cheung, KM, Zhang JG, Lu DS, Luk KD, Leong JC(2002). Ten-year follow-up study of lower thoracic hemivertebrae treated by convex fusion and concave distraction. Spine, 27(7), 748-753.
4. McMaster MJ Singh H(1999). Natural history of congenital kyphosis and kyphoscoliosis. A study of one hundred and twelve patients. JBJS, 81(10), 1367-83.
5. Winter RB(1976). Congenital kyphoscoliosis with paralysis following hemivertebra excision. Clinical orthopaedics and related research, (119), 116-125.
6. Yaszay B, O'Brien M, Shufflebarger HL, Betz RR, Lonner B, Shah SA, Boachie-Adjei O, Crawford A, Letko L, Harms J (2011) Efficacy of hemivertebra resection for congenital scoliosis: a multicenter retrospective comparison of three surgical techniques. Spine 36:2052–2060
7. Jalanko T, Rintala R, Puisto V, Helenius I (2011) Hemivertebra resection for congenital scoliosis in young children: comparison of clinical, radiographic, and health-related quality of life outcomes between the anteroposterior and posterolateral approaches. Spine 36:41–49
8. McMaster MJ Ohtsuka K (1982). The natural history of congenital scoliosis. A study of two hundred and fifty-one patients. JBJS, 64(8), 1128-1147.
9. Winter RB Moe JH Eilers VE(1968). Congenital Scoliosis A Study of 234 Patients Treated and Untreated: PART I: NATURAL HISTORY. JBJS, 50(1), 1-15.
10. Nasca RJ Stilling FH Stell HH(1975). Progression of congenital scoliosis due to hemivertebrae and hemivertebrae with bars. The Journal of bone and joint surgery. American volume, 57(4), 456-466.
11. Danisa OA, Turner D, Richardson WJ (2000) Surgical correction of lumbar kyphotic deformity: posterior reduction “eggshell” osteotomy. J Neurosurg 92(suppl 1):50–56
12. McMaster MJ, Ohtsuka K (1982) The natural history of congenital scoliosis: a study of two hundred and fifty-one patients. J Bone Joint Surg Am 64:1128–1147
13. McMaster MJ, Singh H (1999) Natural history of congenital kyphosis and kyphoscoliosis: a study of one hundred and twelve patients. J Bone Joint Surg Am 81:1367–1383
14. alanko T, Rintala R, Puisto V, Helenius I (2010) Hemivertebra resection for congenital scoliosis in young children. Comparison of clinical, radiographic, and health related quality of life outcomes between the anteroposterior and posterolateral approaches. Spine 36(1):41–49
15. Chu G , Huang J , Zeng K , Guo Q, Zhang, H(2015). A modified surgical procedure for congenital kyphoscoliosis: selective partial hemivertebrectomy via posterior-only approach. Child's Nervous

System, 31(6), 923-929.

16. Shono Y, Abumi K, Kaneda K(2001). One-stage posterior hemivertebra resection and correction using segmental posterior instrumentation. Spine, 26(7), 752-757.
17. Ruf M, Harms J (2002) Hemivertebra resection by a posterior approach: innovative operative technique and first results. Spine 27:1116–1123
18. Polly DW, Rosner MK, Monacci W, Moquin, RR(2003). Thoracic hemivertebra excision in adults via a posterior-only approach: report of two cases. Neurosurgical focus, 14(2), 1-4.
19. Li XF, Liu ZD, Hu GY, Li XF, Liu ZD, Hu GY, Chen B, Zhong GB, Zang WP, Wang HT(2011). Posterior unilateral pedicle subtraction osteotomy of hemivertebra for correction of the adolescent congenital spinal deformity. The Spine Journal, 11(2), 111-118.
20. Leatherman KD, Dickson RA(1979). Two-stage corrective surgery for congenital deformities of the spine. The Journal of bone and joint surgery. British volume, 61(3), 324-328.
21. Gertzbein SD, Harris MB(1992). Wedge osteotomy for the correction of posttraumatic kyphosis. Spine, 17(3), 374-379
22. Kawahara N, Tomita K, Baba H, Kobayashi T, Fujita T, Murakami H(2001). Closing–opening wedge osteotomy to correct angular kyphotic deformity by a single posterior approach. Spine, 26(4), 391-402.
23. Ayvaz M, Olgun ZD, Demirkiran HG, Alanay A, Yazici, M(2014). Posterior all-pedicle screw instrumentation combined with multiple chevron and concave rib osteotomies in the treatment of adolescent congenital kyphoscoliosis. The Spine Journal, 14(1), 11-19.
24. Wang Y X, Zhang H Q, Liao W, Tang, MX, Guo CF, Deng A, Liu JY(2016). One-stage posterior focus debridement, interbody graft using titanium mesh cages, posterior instrumentation and fusion in the surgical treatment of lumbo-sacral spinal tuberculosis in the aged. International orthopaedics, 40(6), 1117-1124.
25. Chang D G, Yang J H, Lee J H, Kim, JH, Suh SW, Ha K Y, Suk, SI(2016). Congenital scoliosis treated with posterior vertebral column resection in patients younger than 18 years: longer than 10-year follow-up. Journal of Neurosurgery: Spine, 25(2), 225-233.

Figures

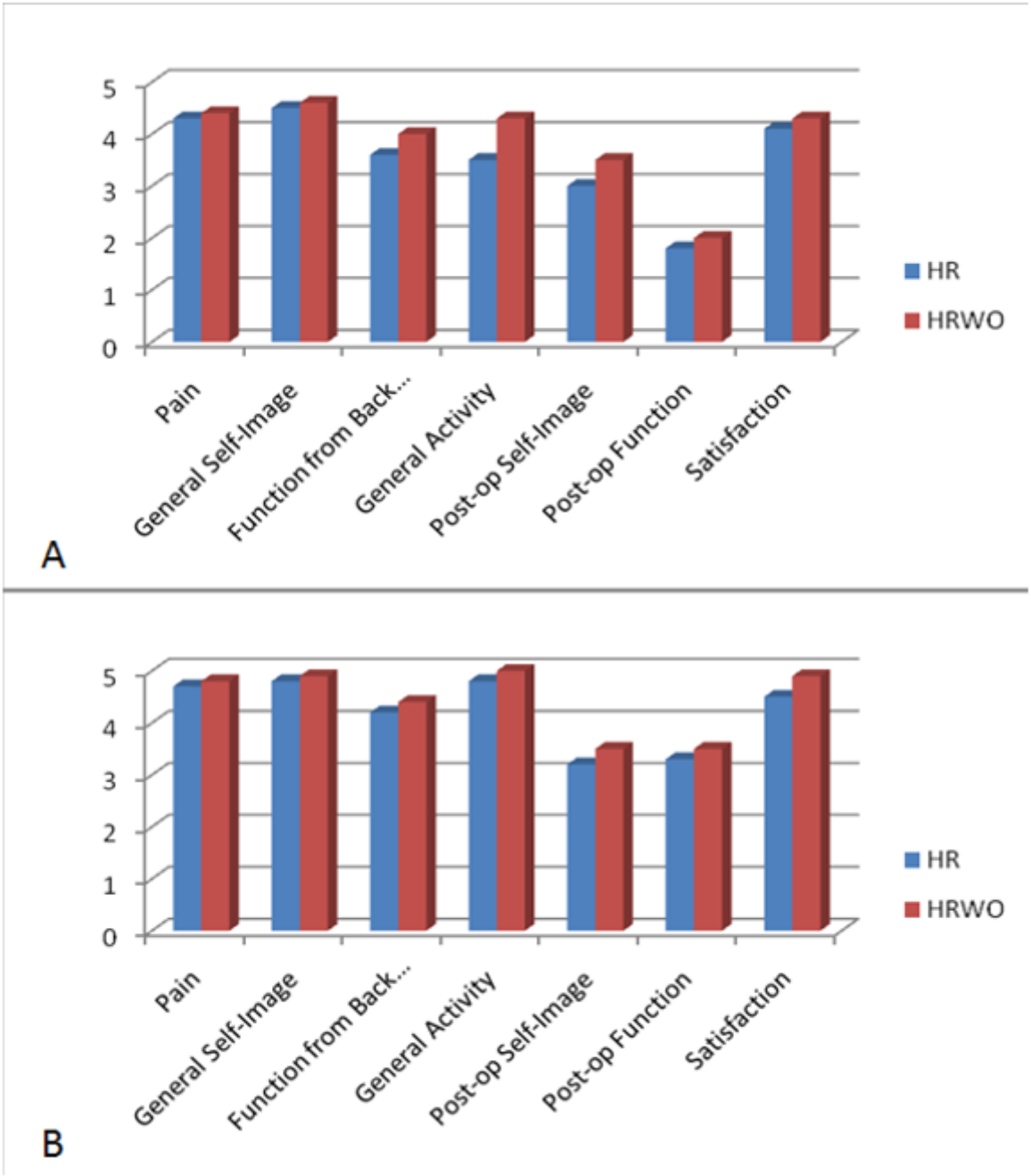

Figure 1

In comparison, the 7 domains of SRS-24 have gained similar results between HR and HRWO. The most significant change during the follow-up in both groups can be seen in the general activity and postoperative function. A, Postoperative. The difference in satisfaction between the groups ((P⩽0.05). B, FFU. The difference in General Activity between the groups (P⩽0.05).

Figure 2

HRWO is Hemivertebra Resection Combined With Wedge Osteotomy, that is,“V”shaped bone resection of the adjacent vertebral body, including the hemivertebral body, the upper and below disc, both endplate of adjacent segments a, the spinous process, bilamina, facet joint(b)

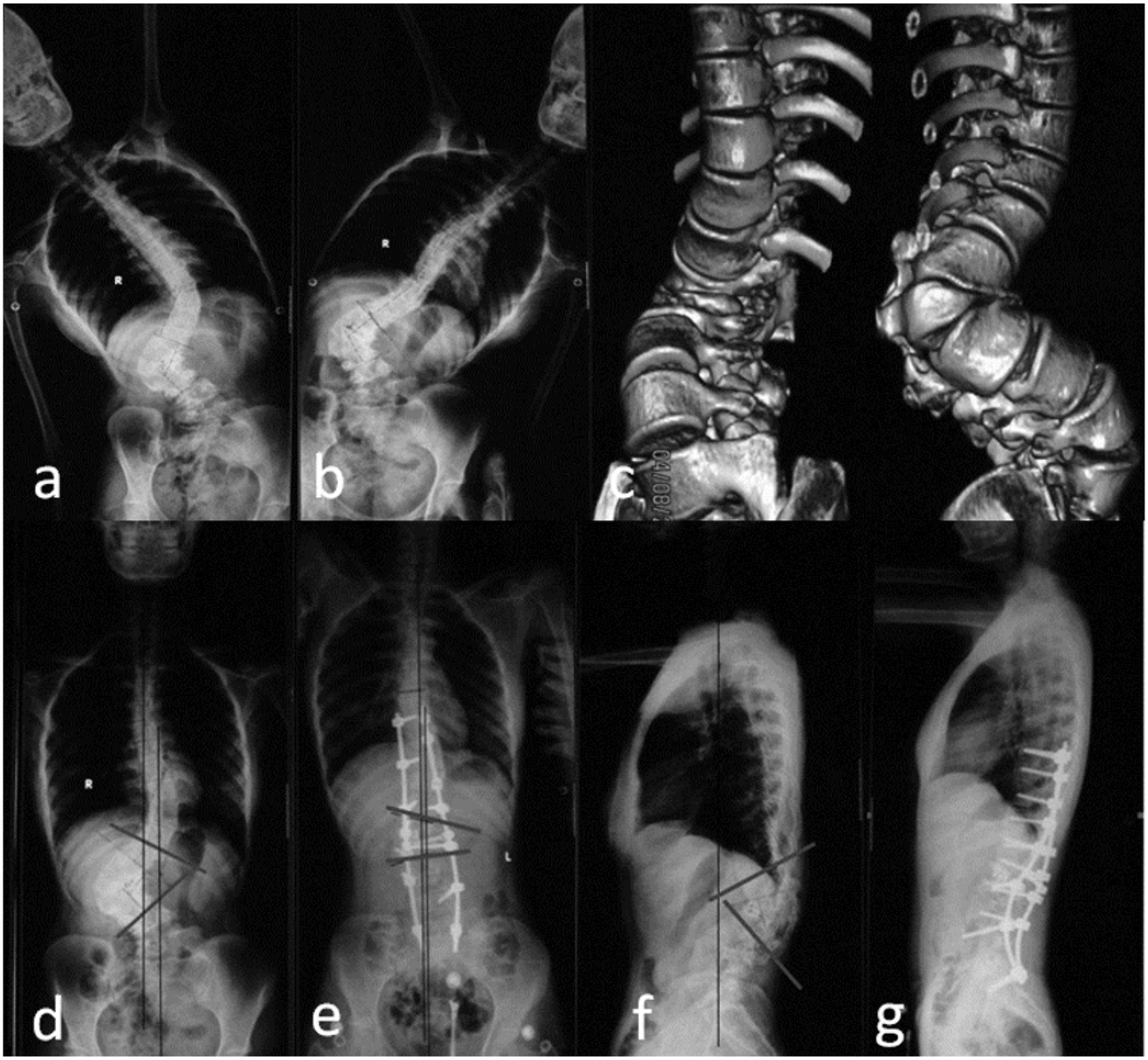

Figure 3

Radiographs of patient 18, a 16-year-old girl, who underwent hemivertebra excision combined with wedge osteotomy surgery for hemivertebrae L2. (a,b) Preoperative left- right bending radiograph found that the curve flexibility less than 25%. The patients present severe rigid angular kyphoscoliosis. (c)on the three-dimensionalcomputed tomography (d,e) Preoperative radiograph found that the apical hemivertebra of

kyphoscoliosis was L2.(e,f) There was no loss of correction at the final follow up, and fusion can be found