Risk factors of the suprasternal lymph node metastasis in papillary thyroid carcinoma with clinical lateral cervical lymph node metastasis

Hyun-Keun Kwon (kwon-h-g@hanmail.net)
Pusan National University School of Medicine https://orcid.org/0000-0003-4089-8639

Yong-Il Cheon
Pusan National University Hospital

Sung-Chan Shin
Pusan National University Hospital

Eui-Suk Sung
Pusan National University Yangsan Hospital

Jin-Choon Lee
Pusan National University Yangsan Hospital

In-Ju Kim
Pusan National University Hospital

Byung-Joo Lee
Pusan National University Hospital

Research

Keywords: Papillary thyroid carcinoma, suprasternal lymph node, cervical lymph node metastasis, neck dissection, risk factor

Posted Date: March 18th, 2020

DOI: https://doi.org/10.21203/rs.3.rs-17663/v1

Version of Record: A version of this preprint was published at Gland Surgery on February 1st, 2021. See the published version at https://doi.org/10.21037/gs-20-368.

Abstract

Background: Metastatic lymph nodes are occasionally found in the suprasternal lymph nodes in patients with papillary thyroid cancer (PTC), but there are few studies on these lymph nodes. Therefore, we investigated the frequency and risk factors of suprasternal lymph node metastasis in PTC patients with lateral cervical lymph node metastasis.

Methods: A total of 85 patients with cN1b PTC underwent total thyroidectomy with elective lateral neck dissection including the suprasternal lymph nodes. We analyzed the correlation between suprasternal lymph node metastasis and sex, age, tumor characteristics, and cervical lymph node metastasis status.

Results: Eleven patients (12.9%) had pathological suprasternal lymph node metastasis. Suprasternal lymph node metastasis was associated with tumors located in the inferior pole and level IV lymph node metastasis.

Conclusion: In cN1b PTC patients, especially those with inferior pole tumors and level IV nodal metastasis, the suprasternal lymph node should be routinely dissected.

Background

Thyroid cancer is a common endocrine tumor. Papillary thyroid carcinoma (PTC) is the most common malignancy that occurs in thyroid follicular cells. The majority of PTC patients have good prognosis with low mortality, but cervical lymph node metastasis is common.[1, 2] Most cervical lymph node metastasis of PTC occurs sequentially. The tumor cell spreads from the thyroid gland to the central and lateral lymph nodes on the ipsilateral side of the tumor, followed by metastasis to the opposite cervical lymph node.[3] However, PTC located in the upper pole of the thyroid gland may present with lateral lymph node metastasis without central lymph node metastasis, which is often referred to as “skip metastasis”.[4] According to previous studies, about 20-90% of PTC patients have cervical lymph node metastasis. The impact of cervical lymph node metastasis on overall survival is still controversial; however, it is known to increase the risk of locoregional recurrence.[5-10] Therefore, complete resection of metastatic cervical lymph nodes is important to reduce locoregional recurrence of PTC.

The central neck compartment is bounded superiorly by the hyoid bone, laterally by the carotid arteries, anteriorly by the superficial layer of the deep cervical fascia, and posteriorly by the deep layer of the deep cervical fascia,[11] not including the nodes anterior to the strap musculature. The anatomical boundary of the medial border of level III and IV lymph nodes is the lateral border of the sternohyoid muscle.[12] The space anterior to the sternohyoid muscle, posterior to the sternocleidomastoid muscle, medial to the lateral border of the sternohyoid muscle, and above the clavicle and sternum does not fall under the normal subdivisions of the central and lateral neck compartment (Fig. 1). This space is called the suprasternal space, and suprasternal lymph node metastasis is occasionally observed by preoperative ultrasonography or computed tomography (CT) in recurrent PTC patient (Fig. 2).

Metastatic suprasternal lymph nodes are occasionally found in patients with PTC, but there are few studies on this topic. Therefore, we investigated the frequency and risk factors of suprasternal lymph node metastasis in PTC patients with lateral cervical lymph node metastasis.

Methods

Patients

Data on a total of 85 cN1b PTC patients who underwent total thyroidectomy and elective lateral neck dissection including suprasternal lymph node dissection at the Pusan National University Hospital from January 1, 2012 to January 31, 2018 were reviewed. There were 29 men and 56 women, aged 17-83 years (mean 49.51 years). The inclusion criteria were: (1) PTC with lateral cervical lymph node metastasis; (2) no previous treatment with radioactive iodine, radiotherapy, or chemotherapy prior to surgery; and (3) underwent suprasternal lymph node dissection. Patients who had undergone previous thyroidectomy or revision neck dissection were excluded. This study was approved by the Institutional Review Board (IRB No. H-2002-003-087) and informed consent was waived.

Association of clinicopathological factors with suprasternal lymph node metastasis

Associations between suprasternal lymph node metastasis and clinicopathological factors, including age, sex, tumor size, primary tumor location, extrathyroidal extension (ETE), multifocality, vascular invasion, lateral cervical lymph node metastasis, central compartment lymph node metastasis were investigated. Lymph node ratio (LNR) was also investigated. LNR was defined as the number of positive lymph nodes divided by the total number of lymph nodes harvested.

Statistical analysis

Chi-square test and Fisher’s exact test were used as appropriate to identify risk factors for suprasternal lymph node metastasis. Receiver operating characteristic (ROC) curve analysis was performed to determine the predictability of suprasternal lymph node metastasis. The area under the ROC curve (AUC) with 95% confidence interval (CI) was reported. $P < 0.05$ was considered statistically significant. SPSS version 21 (SPSS Inc., Chicago, IL) software was used for all analyses.

Results

The rate of suprasternal lymph node metastasis was 12.9% (11/85), and the mean number of dissected suprasternal lymph nodes was 1.4 (range 0-4). More than one suprasternal lymph node was pathologically found in 76.5% (65/85) of patients.

Correlations between suprasternal lymph node metastasis and clinicopathologic factors were analyzed. Tumor location at the inferior pole was significantly associated with suprasternal lymph node metastasis ($p = 0.005$). All patients with suprasternal lymph node metastasis had ETE, but the relationship was not

statistically significant. Additionally, no significant association was found between suprasternal lymph node metastasis and age, sex, tumor size, multifocality, or vascular invasion (Table 1).

All patients had lateral lymph node metastasis, and 18.8% (16/85) of patients had lateral lymph node metastasis without central lymph node metastasis. These patients had no suprasternal lymph node metastasis. We analyzed the relationship between cervical lymph node metastasis and suprasternal lymph node metastasis. All patients with suprasternal lymph node metastasis had level IV and level VI nodal metastasis. However, only level IV nodal metastasis was significantly associated with suprasternal lymph node metastasis ($p = 0.014$). No significant association was found between suprasternal lymph node metastasis and level II, level III, or level VI nodal metastasis.

When examining the number of harvested and positive lymph nodes in patients with and without suprasternal lymph node metastasis, only the number of positive level IV lymph nodes was significantly different between the two groups ($p < 0.001$). LNR of level IV and VI was significantly different between the two groups ($p = 0.002, 0.009$) (Table 3). To determine the optimal cut-off for the number of positive level IV lymph nodes, a ROC curve was constructed. ROC curve analysis indicated that ≥ 2 positive lymph nodes had the best predictive value for suprasternal lymph node metastasis, with an AUC of 0.853 (95% CI 0.760-0.921, $p < 0.001$) (Fig. 3). Also, the optimal cut-off for the LNR of level IV and VI lymph node was analyzed. ROC curve analysis indicated that the optimal cut-off value for LNR of level IV and VI was 0.125 and 0.357, with an AUC of 0.830 (95% CI 0.734-0.903, $p < 0.001$) and 0.741 (95% CI 0.634-0.830, $p < 0.001$) (Fig. 3).

In all patients, suprasternal lymph node dissection took approximately 5 minutes, and there were no specific intraoperative or postoperative complications such as bleeding or pain.

Discussion

The suprasternal space, which is also known as the “Burns space,” is a narrow space between the superficial and deep layers of the investing layers of the deep cervical fascia above the manubrium of the sternum.[13] According to Gray’s Anatomy, it contains a small amount of areolar tissue, the lower parts of the anterior jugular veins, and the jugular venous arch, as well as the sternal heads of the sternocleidomastoid muscles and occasionally lymph nodes.[14] The result of this study showed the suprasternal lymph node metastasis is associated with tumors located in the inferior pole and level IV lymph node metastasis. The suprasternal lymph node metastasis can be predicted when there are two or more level IV lymph node metastasis. Level IV LNR > 0.125 and level VI LNR > 0.357 were also associated with suprasternal lymph node metastasis.

Sun et al. first defined the lymph node area between the sternocleidomastoid and sternohyoid muscle as follows: its anterior boundary as the sternocleidomastoid muscle, its posterior as the sternohyoid muscle, its superior as the intersection of sternocleidomastoid and sternohyoid muscle, and its inferiors as suprasternal fossa and clavicle, its external and internal boundary as the lateral and internal borders of the sternohyoid muscle, respectively.[13] They mentioned that this space is part of the suprasternal

space, and they found up to 5 (average, 3) lymph nodes pathologically. In this study, up to 4 (average, 1.4) lymph nodes were pathologically confirmed in the suprasternal space. Although the number of lymph nodes is small, it is certain that lymph nodes are present in the suprasternal space.

A prognostic significance of lymph node metastasis has been reported for low-risk as well as high-risk patient.[15-17] However, whether prophylactic central neck dissection is beneficial in patients with well-differentiated PTC is controversial because of a greater risk of postoperative complications, such as transient or permanent hypoparathyroidism and unintentional recurrent laryngeal nerve injury.[18] In contrast to central neck dissection, lateral neck dissection should be performed on patients who have PTC with clinically apparent cervical lymph node metastasis detected on palpation or imaging studies.[19-21] The extent of lateral neck dissection is still controversial, but a thorough lymph node dissection is required. Therefore, suprasternal lymph node metastasis is rare but should be routinely included in the lateral neck dissection because there are few complications during dissection.

The etiology of suprasternal lymph node metastasis is not clear. Sun et al. reported that, without exception, patients with suprasternal space metastasis also had lateral cervical lymph node metastasis, and level III and IV metastases were significantly correlated with suprasternal space metastasis.[13] They speculated that suprasternal space metastasis could be a result of the increasing tumor load after lateral cervical metastasis[13]. Homma et al. speculate that fibrofatty tissue, including the level III and IV metastatic lymph nodes, moves into the suprasternal space gradually due to the daily motion of the neck.[22] We present two theories through the anterior jugular node chain. First, level IV metastatic lymph nodes move into the suprasternal space laterally. Second, central lymph nodes, especially the pretracheal and paratracheal metastatic lymph nodes, move into the suprasternal space medially (Fig. 4). In this study, all patients with suprasternal lymph node metastasis had level IV and VI metastasis. However, only level IV metastasis was significantly correlated with suprasternal lymph node metastasis, and two or more level IV metastatic lymph nodes had the best predictive value. Therefore, it is important to dissect the suprasternal lymph node adjacent to the level IV lymph node, as the first theory is more convincing.

Suprasternal lymph node metastasis can be recognized by preoperative ultrasonography or CT; however, there is little clinical interest. Therefore, suprasternal lymph nodes are not routinely dissected because they are not included in the central and lateral neck compartment. Sun et al. reported that the positive rate for the suprasternal space was 22.6% among 115 patients with clinically node-positive PTC who underwent neck dissection that included the suprasternal space.[13] In this study, the positive rate for the suprasternal space was 12.9% among 85 patients.

The number of metastatic lymph nodes and LNR are risk factors for locoregional recurrence in PTC.[9, 10] Suprasternal lymph node metastasis was associated with level IV lymph node metastasis and can be predicted when there are two or more level IV lymph node metastasis. Level IV LNR > 0.125 and level VI LNR > 0.357 were also associated with suprasternal lymph node metastasis. Although the frequency of suprasternal lymph node metastasis is low, prophylactic suprasternal lymph node dissection is less invasive, easier to achieve, and less time consuming than central compartment dissection, which

increases the risk of recurrent laryngeal nerve palsy and hypocalcemia.[23] In this study, it did not take much longer to dissect the suprasternal lymph nodes, and there were no intraoperative or postoperative complications such as bleeding or pain.

PTC has an excellent prognosis, with a 10-year overall survival rate > 90%.[24] However, in rare cases, nodal recurrence may occur in the suprasternal lymph nodes. Because locoregional recurrence can affect quality of life,[25] it is important to reduce the risk of locoregional recurrence by complete resection of the lymph nodes during surgery.[26] Suprasternal lymph node metastasis is relatively rare, but dissection is safe and easy.

Conclusion

In cN1b PTC patients, especially those with tumors in the inferior pole or level IV lymph node metastasis, we propose suprasternal lymph node dissection should be routinely included in lateral neck dissection.

Declarations

Ethics approval and consent to participate

All procedures performed in studies involving human participants were in accordance with the ethical standards of the institutional and national research committee and with the 1964 Helsinki Declaration and its later amendments or comparable ethical standards. This study was approved by the Institutional Review Board (IRB No. H-2002-003-087) and informed consent was waived.

Consent for publication

Not applicable

Availability of data and materials

The datasets used and/or analyzed during the current study are available from the corresponding author on reasonable request.

Competing interests

The authors declare that they have no competing interests.

CONFLICT OF INTEREST

No potential conflict of interest relevant to this article was reported.

Funding

The authors have no funding to disclose.

Authors' contributions

Conceptualization: BJL. Data curation: YIC, SCS. Formal analysis: JCL, ESS. Methodology: HKK, YIC. Project administration: IJK. Visualization: HKK. Writing - original draft: HKK. Writing - review & editing: HKK, BJL.

Acknowledgements

We would like to thank Editage (www.editage.co.kr) for English language editing.

References

1. Ito Y, Kudo T, Kobayashi K, Miya A, Ichihara K, Miyauchi A: **Prognostic factors for recurrence of papillary thyroid carcinoma in the lymph nodes, lung, and bone: analysis of 5,768 patients with average 10-year follow-up.** *World J Surg* 2012, **36:**1274-1278.
2. Moo TA, McGill J, Allendorf J, Lee J, Fahey T, 3rd, Zarnegar R: **Impact of prophylactic central neck lymph node dissection on early recurrence in papillary thyroid carcinoma.** *World J Surg* 2010, **34:**1187-1191.
3. Machens A, Hinze R, Thomusch O, Dralle H: **Pattern of nodal metastasis for primary and reoperative thyroid cancer.** *World J Surg* 2002, **26:**22-28.
4. Lee YS, Shin SC, Lim YS, Lee JC, Wang SG, Son SM, Kim IJ, Lee BJ: **Tumor location-dependent skip lateral cervical lymph node metastasis in papillary thyroid cancer.** *Head Neck* 2014, **36:**887-891.
5. Cooper DS, Doherty GM, Haugen BR, Kloos RT, Lee SL, Mandel SJ, Mazzaferri EL, McIver B, Pacini F, Schlumberger M, et al: **Revised American Thyroid Association management guidelines for patients with thyroid nodules and differentiated thyroid cancer.** *Thyroid* 2009, **19:**1167-1214.
6. Park YM, Wang SG, Shin DH, Kim IJ, Son SM, Lee BJ: **Lymph node status of lateral neck compartment in patients with N1b papillary thyroid carcinoma.** *Acta Otolaryngol* 2016, **136:**319-324.
7. Hay ID, Hutchinson ME, Gonzalez-Losada T, McIver B, Reinalda ME, Grant CS, Thompson GB, Sebo TJ, Goellner JR: **Papillary thyroid microcarcinoma: a study of 900 cases observed in a 60-year period.** *Surgery* 2008, **144:**980-987; discussion 987-988.
8. Podnos YD, Smith D, Wagman LD, Ellenhorn JD: **The implication of lymph node metastasis on survival in patients with well-differentiated thyroid cancer.** *Am Surg* 2005, **71:**731-734.
9. Choi SY, Cho JK, Moon JH, Son YI: **Metastatic Lymph Node Ratio of Central Neck Compartment Has Predictive Values for Locoregional Recurrence in Papillary Thyroid Microcarcinoma.** *Clin Exp Otorhinolaryngol* 2016, **9:**75-79.
10. Zheng CM, Ji YB, Song CM, Ge MH, Tae K: **Number of Metastatic Lymph Nodes and Ratio of Metastatic Lymph Nodes to Total Number of Retrieved Lymph Nodes Are Risk Factors for Recurrence in Patients With Clinically Node Negative Papillary Thyroid Carcinoma.** *Clin Exp Otorhinolaryngol* 2018, **11:**58-64.

11. Carty SE, Cooper DS, Doherty GM, Duh QY, Kloos RT, Mandel SJ, Randolph GW, Stack BC, Jr., Steward DL, Terris DJ, et al: **Consensus statement on the terminology and classification of central neck dissection for thyroid cancer.** *Thyroid* 2009, **19:**1153-1158.
12. Robbins KT, Clayman G, Levine PA, Medina J, Sessions R, Shaha A, Som P, Wolf GT: **Neck dissection classification update: revisions proposed by the American Head and Neck Society and the American Academy of Otolaryngology-Head and Neck Surgery.** *Arch Otolaryngol Head Neck Surg* 2002, **128:**751-758.
13. Sun G, Wang Y, Zhu Y, Wang Y, Xu K, Wei W, Li H, Lu Z, Ji Q: **Lymph node metastasis between sternocleidomastoid and sternohyoid muscle in clinically node-positive papillary thyroid carcinoma.** *Head Neck* 2013, **35:**1168-1170.
14. Standring S: *Gray's anatomy: the anatomical basis of clinical practice, expert consult, 40th edn.* UK: Churchill Livingstone; 2008.
15. Zaydfudim V, Feurer ID, Griffin MR, Phay JE: **The impact of lymph node involvement on survival in patients with papillary and follicular thyroid carcinoma.** *Surgery* 2008, **144:**1070-1077; discussion 1077-1078.
16. Nixon IJ, Wang LY, Palmer FL, Tuttle RM, Shaha AR, Shah JP, Patel SG, Ganly I: **The impact of nodal status on outcome in older patients with papillary thyroid cancer.** *Surgery* 2014, **156:**137-146.
17. Adam MA, Pura J, Goffredo P, Dinan MA, Reed SD, Scheri RP, Hyslop T, Roman SA, Sosa JA: **Presence and Number of Lymph Node Metastases Are Associated With Compromised Survival for Patients Younger Than Age 45 Years With Papillary Thyroid Cancer.** *J Clin Oncol* 2015, **33:**2370-2375.
18. Shan CX, Zhang W, Jiang DZ, Zheng XM, Liu S, Qiu M: **Routine central neck dissection in differentiated thyroid carcinoma: a systematic review and meta-analysis.** *Laryngoscope* 2012, **122:**797-804.
19. Noguchi S, Murakami N: **The value of lymph-node dissection in patients with differentiated thyroid cancer.** *Surg Clin North Am* 1987, **67:**251-261.
20. Shaha AR: **Management of the neck in thyroid cancer.** *Otolaryngol Clin North Am* 1998, **31:**823-831.
21. Bhattacharyya N: **Surgical treatment of cervical nodal metastases in patients with papillary thyroid carcinoma.** *Arch Otolaryngol Head Neck Surg* 2003, **129:**1101-1104.
22. Homma A, Hatakeyama H, Mizumachi T, Furusawa J, Kano S, Sakashita T, Fukuda S: **Lymph node metastasis in the suprasternal space from thyroid papillary cancer.** *International Cancer Conference Journal* 2014, **4:**57-60.
23. Chen L, Wu YH, Lee CH, Chen HA, Loh EW, Tam KW: **Prophylactic Central Neck Dissection for Papillary Thyroid Carcinoma with Clinically Uninvolved Central Neck Lymph Nodes: A Systematic Review and Meta-analysis.** *World J Surg* 2018, **42:**2846-2857.
24. Lundgren CI, Hall P, Ekbom A, Frisell J, Zedenius J, Dickman PW: **Incidence and survival of Swedish patients with differentiated thyroid cancer.** *Int J Cancer* 2003, **106:**569-573.
25. Hughes CJ, Shaha AR, Shah JP, Loree TR: **Impact of lymph node metastasis in differentiated carcinoma of the thyroid: a matched-pair analysis.** *Head Neck* 1996, **18:**127-132.

26. Noguchi S, Murakami N, Yamashita H, Toda M, Kawamoto H: **Papillary thyroid carcinoma: modified radical neck dissection improves prognosis.** *Arch Surg* 1998, **133:**276-280.

Tables

Table 1. Factors related to suprasternal lymph node metastasis.

Parameter	Suprasternal lymph node		p value
	Positive	Negative	
Sex			
Male	4	25	1.000
Female	7	49	
Age, y			
<55	6	41	1.000
≥55	5	33	
Primary tumor size, cm			
<1	1	22	0.275
≥1	10	52	
Primary tumor location			
Noninferior pole	4	59	0.005*
Inferior pole	7	15	
Extrathyroidal extension			
Yes	11	60	0.198
No	0	14	
Multifocality			
Yes	6	23	0.174
No	5	51	
Vascular invasion			
Yes	3	25	1.000
No	8	49	

*Statistically significant ($p < 0.05$)

Table 2. Relationship between cervical lymph node metastasis and suprasternal lymph node metastasis.

Parameter	Suprasternal lymph node		p value
	Positive	Negative	
Level II metastasis			
Yes	9	39	0.103
No	2	35	
Level III metastasis			
Yes	10	56	0.442
No	1	18	
Level IV metastasis			
Yes	11	47	0.014*
No	0	27	
Level VI metastasis			
Yes	11	58	0.115
No	0	16	

*Statistically significant ($p < 0.05$)

Table 3. Relationship between cervical lymph node ratio (LNR) and suprasternal lymph node metastasis.

Parameter	Suprasternal lymph node		p value
	Positive	Negative	
Level II			
No. of harvested LN (mean ± SD)	14.45 ± 5.24	12.49 ± 5.38	0.260
No. of positive LN (mean ± SD)	1.18 ± 0.87	1.08 ± 1.55	0.834
LNR	0.10 ± 0.08	0.10 ± 0.16	0.929
Level III			
No. of harvested LN (mean ± SD)	8.45 ± 3.45	9.34 ± 4.95	0.570
No. of positive LN (mean ± SD)	2.82 ± 2.23	1.97 ± 1.75	0.153
LNR	0.31 ± 0.19	0.25 ± 0.25	0.471
Level IV			
No. of harvested LN (mean ± SD)	11.91 ± 6.43	10.51 ± 5.03	0.410
No. of positive LN (mean ± SD)	3.45 ± 1.51	1.26 ± 1.38	<0.001*
LNR	0.32 ± 0.15	0.14 ± 0.18	0.002*
Level VI			
No. of harvested LN (mean ± SD)	7.09 ± 4.28	8.91 ± 6.50	0.373
No. of positive LN (mean ± SD)	4.27 ± 2.33	3.70 ± 3.84	0.634
LNR	0.71 ± 0.24	0.44 ± 0.32	0.009*

*Statistically significant ($p < 0.05$)

Figures

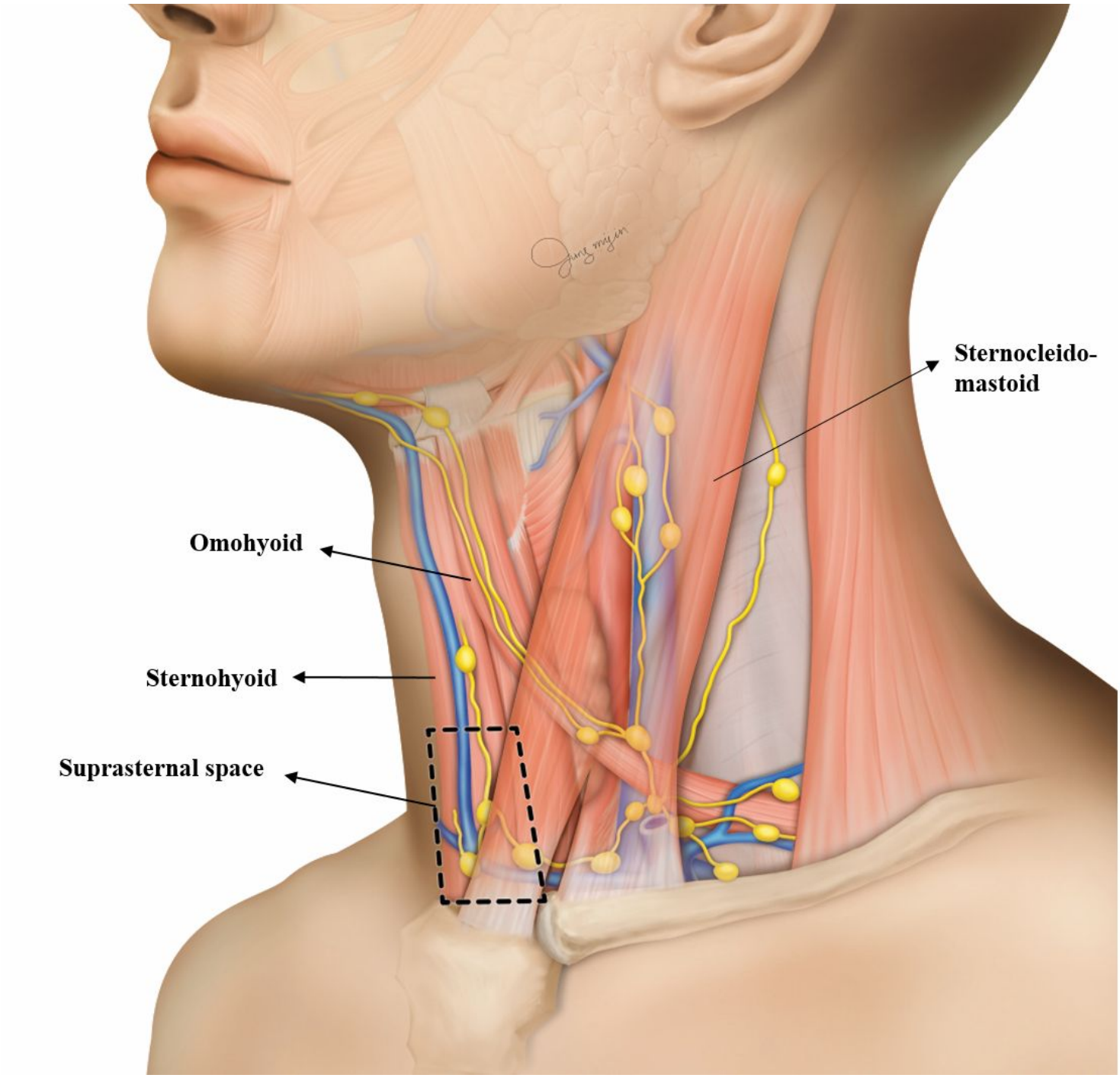

Figure 1

Schematic illustration of the suprasternal space. The suprasternal space is anterior to the sternohyoid muscle, posterior to the sternocleidomastoid muscle, medial to the lateral border of the sternohyoid muscle, and above the clavicle and sternum which is not fall under the normal subdivisions of the central and lateral neck compartment.

Figure 3

Preoperative CT scan of suprasternal lymph node metastasis. Enhanced lymph node (white arrow) can be found between sternocleidomastoid and sternohyoid muscle.

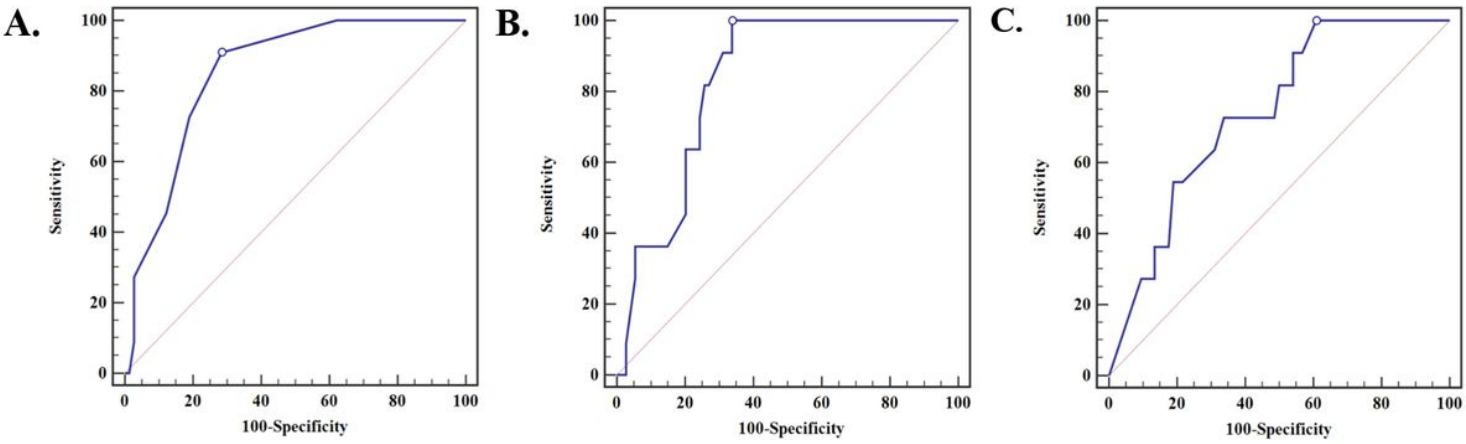

Figure 5

ROC curves of the association between cervical lymph node and suprasternal lymph node metastasis. (A) Level IV lymph node metastasis ≥ 2 had the best predictive value for suprasternal lymph node metastasis, with an AUC of 0.853 (95% CI 0.760-0.921, $p < 0.001$) (B) LNR of level IV > 0.125 had predictive value for suprasternal lymph node metastasis, with an AUC of 0.830 (95% CI 0.734-0.903, $p < 0.001$) (C) LNR of level VI > 0.357 had predictive value for suprasternal lymph node metastasis, with an AUC of 0.741 (95% CI 0.634-0.830, $p < 0.001$)

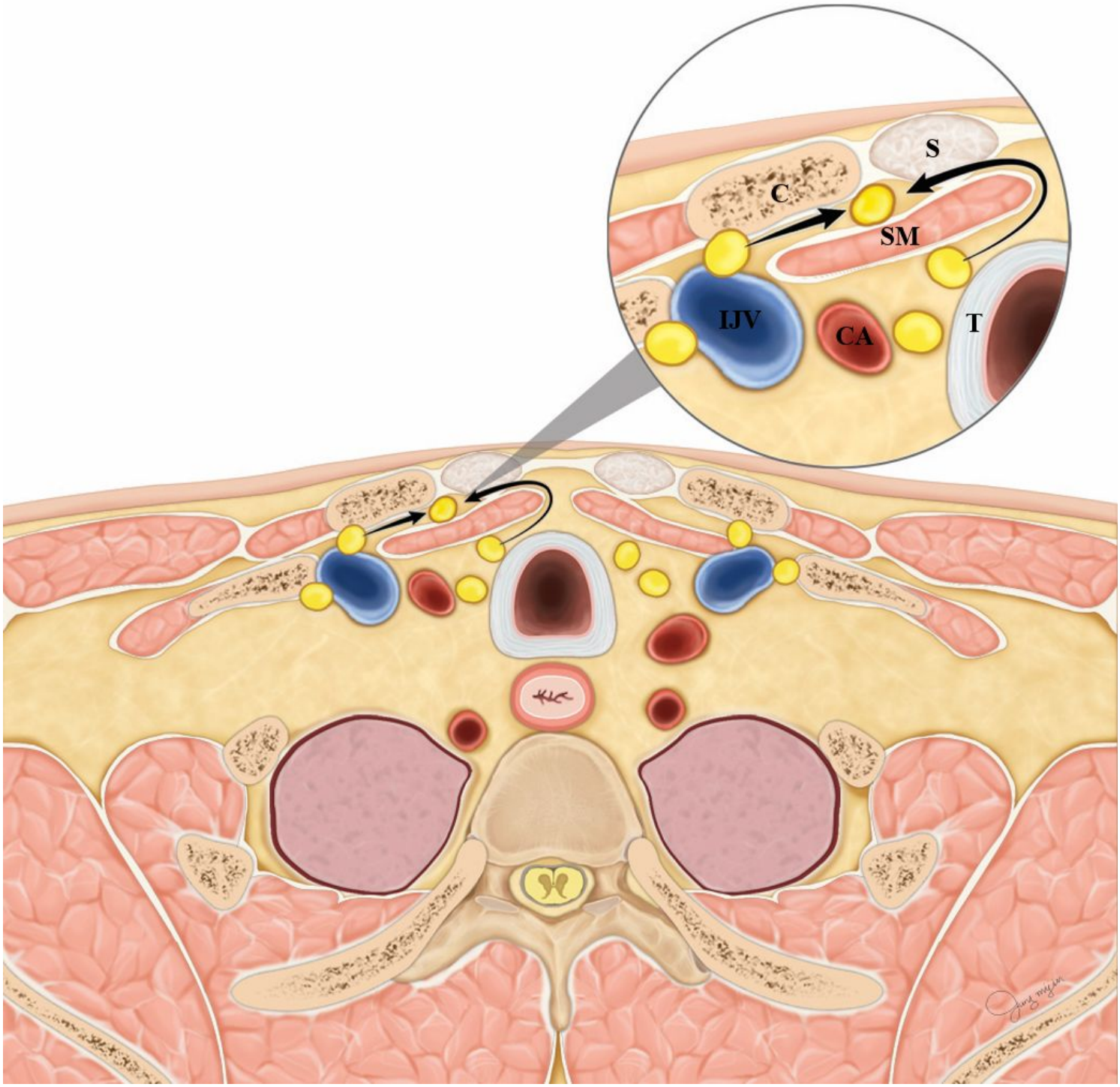

Figure 7

Schematic illustration of two pathway of suprasternal lymph node metastasis. First, level IV metastatic lymph nodes move into the suprasternal space laterally. Second, central lymph nodes, especially the pretracheal and paratracheal metastatic lymph nodes, move into the suprasternal space medially. S : sternum, C : clavicle, T : trachea, SM : strap muscle, CA : carotid artery, IJV : internal jugular vein