Coexistence of lung squamous cell carcinoma and pulmonary tuberculosis within a single lesion: a case report

Guoliang Xiao (DoctorXiaoGL@163.com)
Jiangsu University https://orcid.org/0000-0001-5047-8705

Shengjie Chen
Affiliated Hospital of Jiangsu Univesity

Case report

Keywords: lung cancer, lung squamous cell carcinoma, pulmonary tuberculosis, computed tomography, diagnosis

Posted Date: March 18th, 2020

DOI: https://doi.org/10.21203/rs.3.rs-17664/v1

Abstract

Background: Tuberculosis and lung cancer are common high-mortality lung diseases, but it is rare that lung cancer and tuberculosis exist in the same lesion. In addition, lung cancer with pulmonary tuberculosis is similar in morphology to lung cancer without tuberculosis. For these reasons, lung cancer patients with tuberculosis are often misdiagnosed and mistreated, so these patients have a poorer prognosis than lung cancer patients without tuberculosis. Therefore, a full understanding of such cases can help early diagnosis, so that appropriate treatments can be performed timely.

Case presentations: A 52-year-old male. The physical examination revealed a cavity-like nodule in the upper left lung and the first diagnosis was tuberculosis. There was no significant change in lung nodules after anti-tuberculosis treatment. So the patient was admitted to the hospital for surgical treatment of lung cancer. Postoperative pathological showed that the lesion was lung squamous cell carcinoma with tuberculosis.

Conclusion: the survival rate of patients with active pulmonary tuberculosis and lung cancer is lower than those with lung cancer or tuberculosis alone. Which is mainly due to incomplete diagnosis. if we find hollow shadows in the lungs on CT, we should think about the possibility of coexistence of lung cancer and tuberculosis, and then the appropriate treatment and management strategies should be developed.

1. Background

Globally, tuberculosis is one of the major infectious diseases that lead to death of patients, which is one of the threats to human health. The most susceptible organ for tuberculosis infection is the lungs, and the mortality rate of tuberculosis patients is as high as 7% to 35%. [1] At the same time, lung cancer lead to the highest mortality rate among male patients, and the mortality rate of which among female patients is second only to breast cancer, with a overall mortality rate of approximately 29%. [2] The prevalence of tuberculosis and lung cancer is both very high, and the patients with tuberculosis are at higher risk of lung cancer. Who have a double risk of developing lung cancer than normal people [3]. Nevertheless, the two diseases rarely occur simultaneously in the same lesion. Now, we share a case that a patient with lung squamous cell carcinoma and tuberculosis within a single lesion in the upper left lung.

2. Case Presentation

2.1 Medical history

Patient: 52 years old, male

Chief Complaint: Physical examination revealed a nodule in upper left pulmonary more than 2 months(Figure 1).

Family history: Denial of related familial genetic medical history.

Past history: The patient had diabetes for 11 years for more than 5 years, irregularly taking reglinide and metformin for treatment; the patient was diagnosed as syphilis positive in other hospital one year ago without formal treatment. Denial of surgery.

Current medical history: The patient was found a nodule in the upper left pulmonary by physical examinations about 2 months ago, without hemoptysis, chills and fever. Who was also no chest tightness or shortness of breath. When he was admitted to our hospital, CT showed that: 1. the nodule was cavity with thick wall in the upper left lobe, considering that the MT might be large; 2. the left hilar lymph node was enlarged; 3. there was a small nodule in the upper right pulmonary. And he didn't receive any treatment in our hospital. Then he went to the other hospital for treatment. CT showed that there was a hollow-like lesion in the posterior segment of the upper left lobe, considering the possibility of tuberculosis. After 2 weeks of treatment in the infectious disease hospital, the PDD test was strongly positive during the course of the disease, and then he was treated with isoniazid, rifampicin, bisazinamide, ethambutol for anti-tuberculosis, however, after treatments for a month, CT showed that the size of nodule in the upper left lobe was 2.1cm * 1.8cm cavity-like lesions; so lung cancer cannot be completely ruled out. Now the patient was coming to our clinic for further treatment again. Who had no headache, vomiting, coma, convulsions and fever.

2.2 Hematology examination

Blood routine examination: normal

2.3 Image examinations

CT scanning: The lung window showed that the two lung fields are clear, the light transmission is good, and the lung texture is natural. The left lung has a thick-walled hollow shadow in the upper lobe, about 2.1 * 1.7 cm, lobulated, rough edges, and the inner wall was still smooth, and no obvious calcification and liquid level were seen. In the posterior segment of the upper right lung, irregular small nodules are seen, and the border is clear. The nodule in the upper left lobe was cavity with thick wall, considering that the nodule was more likely MT. (Fig. 1)

PET-CT: Cavity-like nodules with a thickness of about 2.3cm * 2.1cm in the posterior segment of the upper lobe of the left lung are shallowly divided, with rough edges, and the inner wall is smooth. There are no obvious calcifications and fluid levels. Increased radioactive uptake, SUVmax 5.13. Thick wall hollow nodules in the posterior segment of the upper left lobe with enlarged left hilar lymph nodes, increased metabolic activity, considering the possibility of granulomatous lesions (tuberculosis? Other chronic infections?), MT to be scheduled, please combine clinical, Mycobacterium tuberculosis and PPD tests Etc. Histological examination if necessary.

2.4 Operation findings

The mass was located in the posterior segment of the left upper lung near the fissure, with a diameter of about 2.5 cm. The pleural cavity was visible. No obvious metastases and effusions were seen. The

wedge resection has been performed and the biopsy has been made in the operations, suggesting: (left upper lung) epithelial malignant tumors, tend to squamous cell carcinoma. Intraoperative diagnosis: upper left lung cancer. Then we decided to perform radical operation of left upper lung cancer.

2.5 Postoperative pathology

Pathological examination: (left upper lung) differentiated squamous cell carcinoma, cancer tissue did not invade the lung membrane, no obvious nerve and vascular invasion. Epithelial granulomas with coagulative necrosis were seen around the cancerous tissue, and combined tuberculosis was considered. (Fig. 2A,B)

Immunohistochemistry: P53 (+) Ki-67 (75% +) TOPO (+) NSE (-) CDX-2 (-) EGFR (+) VEGF (-) ERCC-1 (+) RRM-1 (-) AE1 / AE3 (+) P40 (+) CD68 (histological cells +) combined with HE sections were considered as (upper left lung) squamous cell carcinoma with tuberculosis. (Fig. 2C)

2.6 Postoperative follow-up

Sputum culture and sputum smear examination were performed according to postoperative pathological results. No tuberculosis bacilli were found. It is recommended that the patient should go to the infectious disease hospital for further treatment and be also followed up regularly in our hospital. The general condition of the patient was acceptable, and he was discharged one week after the operation. Until now, it has been more than one year after the operation. The patient has no complaints of discomfort and the relevant examinations were normal one year after the operation.

3. Discussion

The majority of lung cancer patients coexisting with tuberculosis are similar to those without pulmonary tuberculosis in the morphological characteristics, whose CT shows that the nodules was lobulated. And there are also a few patients with hollow lesions, so it is easy to be misdiagnosed and mistreated[4]. Coexistence of tuberculosis and lung squamous cell carcinoma is rare, so the pathogenesis of which is still unclear[4]. Previous researchers have tried to explain pathogenesis. The first hypothesis suggests that the tumor may be secondary to previous tuberculosis, which causes pulmonary fibrosis, scar formation and the proliferation of bronchial mucosa easily leading to the development of lung cancer. The general process is that tuberculosis causes persistent inflammation and even lung tissue damage. Which will increase the accumulation of carcinogens in this lesion[2,3,5]. In addition, on the one hand, lung tissue scars formed after repeated tuberculosis infections and self-healing provide a favorable environment for tumor formation. On the other hand, the lung parenchyma growed into the cavity left by the tuberculosis lesion. Which led to atypical epithelial cell proliferation and metaplasia, and then the lesions were prone to canceration[2,5]. The second hypothesis holds that the components of the cell wall of mycobacterium tuberculosis can induce the production of nitric oxide and reactive oxygen species, both of which are related to canceration[2]. Especially chronic TB infection caused the phage cells to secrete reactive oxygen species and nitrogenous substances that destroy DNA, in addition, the phage

cells also secreted the carcinogenic chemicals of the epidermal growth factor family. which played a carcinogenic role as paracrine growth factors in the early stages of cancer formation[3]. The third hypothesis suggests that cancer cells may in turn reactivate mycobacterium tuberculosis in the body. The production of lung cancer cells in non-active tuberculosis lesions stimulated mycobacterium tuberculosis and restored its activity. Primary lung cancer may increase the risk of opportunistic infections within the tumor, which made the cancer patients more vulnerable to tuberculosis.

The prognosis of patients with both lung cancer and tuberculosis has been controversial[6]. However, a recent study showed that patients with both lung cancer and tuberculosis had a significantly higher mortality rate than patients with lung cancer alone. At present, many studies showed that when the doctor cannot completely rule out the possibility of lung cancer, as long as the patient meets the surgical indication, the surgery is the best treatment strategy for the lung cancer patients with tuberculosis, in addition, the anti-tuberculosis treatment and adjuvant chemotherapy should be performed after operation[6,7,8,9,10].

In this case, a 2.3cm * 2.1cm thick-walled cavity-like nodule was found in the left upper lobe of our patient. After a preliminary examination was carried out at the hospital, he was diagnosed with tuberculosis and recommended to receive formal anti-tuberculosis treatment. After admission, the PPD test was strongly positive, and standardized anti-tuberculosis treatment was performed immediately. After a month of treatment, a CT scanning revealed that the nodules were not changed obviously, so the patient was considered to have lung cancer and tuberculosis. And then he went to our hospital for surgical treatment and definitive diagnosis. Before the operation, we did not consider the possibility of the two diseases merging into one lesion. Everyone still thought that the possibility of lung cancer is high.

4. Conclusion

In summary, we provide a rare case of coexistence of lung squamous cell carcinoma and tuberculosis within a single lesion. At present, the survival rate of patients with active pulmonary tuberculosis and lung cancer is lower than those with lung cancer or tuberculosis alone. Which is mainly due to incomplete diagnosis. Especially for patients with two diseases in the same lesion, the timely diagnosis is even more difficult. I provide this case hoping that in our clinical work, if we find hollow shadows in the lungs on CT, we should think about the possibility of coexistence of lung cancer and tuberculosis, and then the appropriate treatment and management strategies should be developed.

Declarations

Acknowledgements

Not applicable

Authors’ contributions

SJC designed the report, GLX performed the pathological analysis, GLX collected the patient's clinical data and information. GLX wrote the paper. All authors read and approved the final manuscript.

Funding

None

Availability of data and materials

As a case report, all data generated or analyzed are included in this published article.

Ethics approval and consent to participate

Not applicable

Consent for publication

Consent for publication was obtained from the patient described in this article.

Competing interests

The authors declare that they have no competing interests.

Author details

[1]Jiangsu University, Zhenjiang, Jiangsu 212000, China; [2]Department of thoracic surgery, Affiliated Hospital of Jiangsu University, Zhenjiang, Jiangsu 212000, China

Correspondence to: Dr Shengjie Chen, Department of thoracic surgery, Affiliated Hospital of Jiangsu University, No.438 North Section of Jiefang Road, Jingkou District, Zhenjiang, Jiangsu 212000, China.

References

[1] Lin CH, Lin CJ, Kuo YW, et al. Tuberculosis mortality: patient characteristics and causes. BMC Infect Dis 2014;14:5.

[2] Luo YH, Wu CH, Wu WS, et al. Association between tumor epidermal growth factor receptor mutation and pulmonary tuberculosis in patients with adenocarcinoma of the lungs. J Thorac Oncol 2012;7:299–305.

[3] Rihawi A, Huang G, Al-Hajj A, et al. A case of tuberculosis andadenocarcinoma coexisting in the same lung lobe. Int J Mycobacteriol2016;5:80–2.

[4] Kim YI, Goo JM, Kim HY, et al. Coexisting bronchogenic carcinoma andpulmonary tuberculosis in the same lobe: radiologic findings and clinicalsignificance. Korean J Radiol 2001;2:138–44.

[5] Sakuraba M, Hirama M, Hebisawa A, et al. Coexistent lung carcinomaand active pulmonary tuberculosis in the same lobe. Ann ThoracCardiovasc Surg 2006;12:53–5.

[6] Dagaonkar RS, Choong CV, Asmat AB, et al. Significance of coexistentgranulomatous inflammation and lung cancer. J Clin Pathol2017;70:337–41.

[7]Niyonkuru Alexandre,Chen Xiaomin,Bakari Khamis Hassan et al. Evaluation of the diagnostic efficacy of F-Fluorine-2-Deoxy-D-Glucose PET/CT for lung cancer and pulmonary tuberculosis in a Tuberculosis-endemic Country.[J] .Cancer Med, 2020, 9: 931-942.

[8] Jian ZH, Huang JY, Ko PC, et al. Impact of coexisting pulmonarydiseases on survival of patients with lung adenocarcinoma. Medicine(Baltimore) 2015;94:e443.

[9]Lan Chou-Chin,Wu Chih-Wei,Wu Yao-Kuang,Systemic Tuberculosis Mimicking Lung Cancer With Multiple Metastases.[J] .Am. J. Med. Sci., 2020, 359: 186-187.

[10] Pisters KM, Evans WK, Azzoli CG, et al. Cancer Care Ontario andAmerican Society of Clinical Oncology adjuvant chemotherapy andadjuvant radiation therapy for stages I-IIIA resectable non–Small-celllung cancer guideline. J Oncol Pract 2007;3:332–5.

[11] Subotic D, Yablonskiy P, Sulis G, et al. Surgery and pleuro-pulmonarytuberculosis: a scientific literature review. J Thorac Dis 2016;8:E474–485.

[12] Xia Z, Qiao K, He J. Recent advances in the management of pulmonarytuberculoma with focus on the use of tubeless video-assisted thoracoscopicsurgery. J Thorac Dis 2017;9:3307–12.

[13] Sahoo Srinibas,Sahoo Satyajeet,TB or not TB: an uncanny radiology.[J] .Postgrad Med J, 2019, undefined: undefined.

[14]van Eeden Ronwyn,Rapoport Bernardo L,Smit Teresa et al. Tuberculosis Infection in a Patient Treated With Nivolumab for Non-small Cell Lung Cancer: Case Report and Literature Review.[J] .Front Oncol, 2019, 9: 659.

Figures

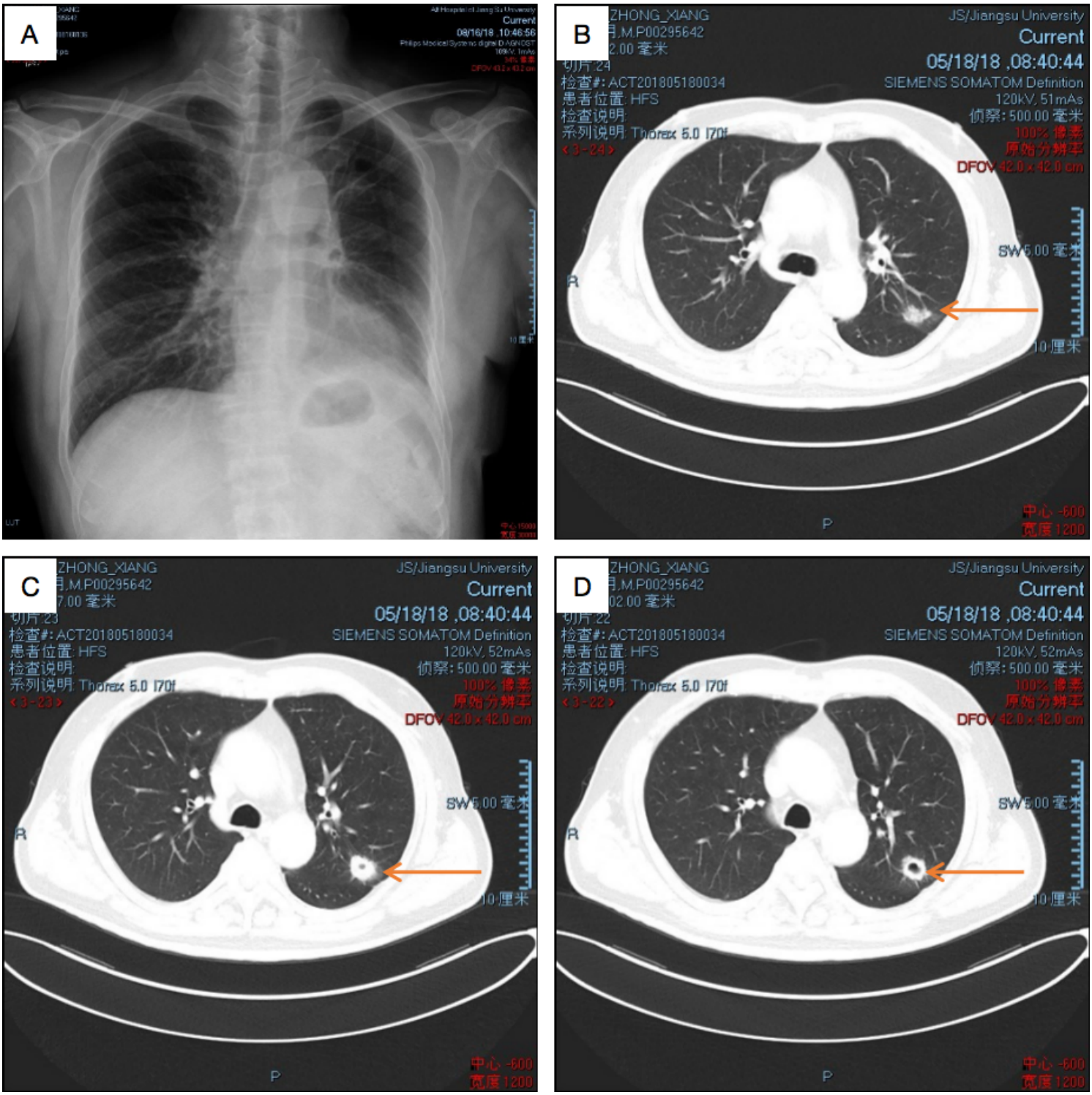

Figure 1

Chest CT showed a thick-walled hollow shadow in the upper left lobe(A); Chest CT showed that a very obvious nodule in the upper left lobe was cavity with thick wall at different planes of CT(B,C,D).

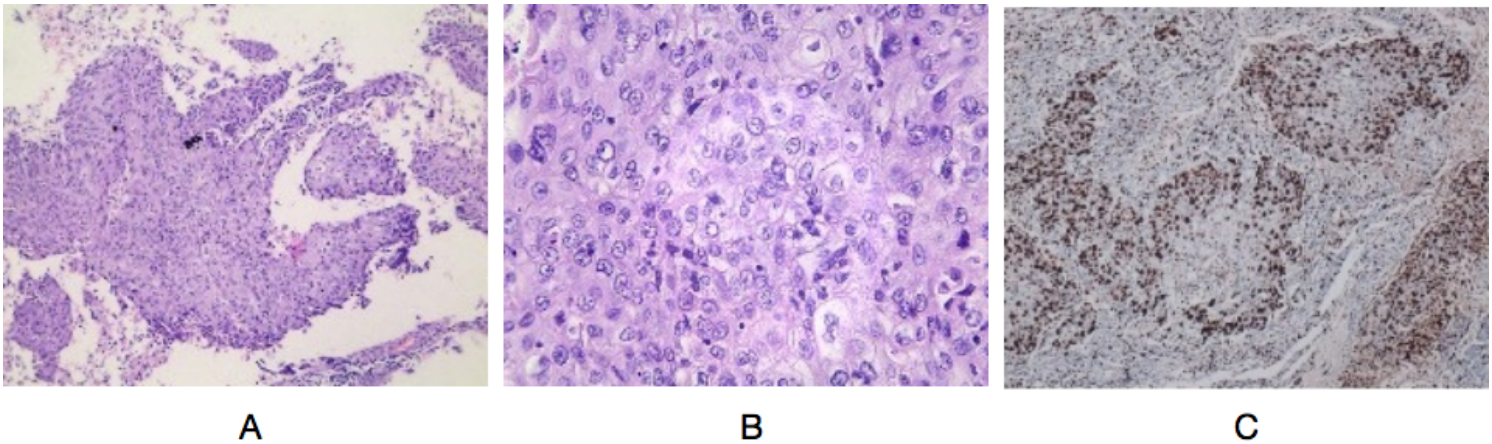

Figure 2

Postoperative pathology picture(100x) showed obvious lesions(A); Postoperative pathology picture(400x) was enlarged to observe the lesion(B); Immunohistochemistry(Ki67)(C).