Self-made fenestrated modified endograft for urgent an Aortic Arch Aneurysm: Case Report

Vito Gallicchio
Hospital of National Importance San Giuseppe Moscati

Danilo Barbarisi
Hospital of National Importance San Giuseppe Moscati

Flavia Condò
Hospital of National Importance San Giuseppe Moscati

Rosaria Sciarrillo (sciarrillo@unisannio.it)
University of Sannio

Loris Flora
Hospital of National Importance San Giuseppe Moscati

Case Report

Keywords: aortic arch, arch aneurysm, carotid-carotid-succlavium bypass, self-made endograft, fenestrated endograft, endovascular repair

Posted Date: June 30th, 2022

DOI: https://doi.org/10.21203/rs.3.rs-1780518/v1

Additional Declarations: No competing interests reported.

Version of Record: A version of this preprint was published at Journal of Cardiothoracic Surgery on January 7th, 2023. See the published version at https://doi.org/10.1186/s13019-023-02102-x.

Abstract

We report the case of an endovascular repair of an aortic arch aneurysm by a self-made endograft with a single fenestration in a high-risk patient unfit for open surgery.

A patient of 81 years, chronic ischemic cardiopathic, suffering from prostate K in chemotherapy treatment, came to our hospital for post-traumatic fracture of the right femur, associated with dysphonia and respiratory disorders for several days. During the hospitalization, the patient performed angio-CT that found the presence of voluminous aneurysm of the aortic arch with a maximum diameter of about 70mm.

The patient was treated in the first instance with a carotid-carotid-succlavium bypass to preserve the cerebral and upper limb vascularization. The *self-made* endograft was created by modifying a standard endograft by a single fenestration following the three-dimensional reconstructions of the CT images. The procedure was completed by implanting this endograft with stent delivery to the patient with a fenestration on the anonymous trunk.

The procedure was successfully completed and postoperative course was uneventful. Computed tomography angiography demonstrated the exclusion of the aneurysm, patency of the implanted endograft modules, and absence of signs of endoleaks and / or cerebral or medullary ischemic complications.

Background

Aortic arch aneurysm repair remains a major surgical challenge. Various strategies have been developed in order to limit the morbidity and mortality associated with open surgical repair, the major concern being neurologic morbidity with a reported rate of perioperative stroke ranging from 5% to 12% [1-4].

To further minimize the perioperative risks and the potential negative impact of these complex procedures on long-term outcomes of patients with aortic arch aneurysms, a concept of total endovascular repair for aortic arch disease has recently emerged.

The mortality and morbidity rates were reduced with the endovascular therapies with *custom-made* stent grafts (CSGs) in patients unfit for surgery [5, 6].

We present the case of a patient with a large saccular aneurysm of the aortic arch successfully treated with a self-made endograft with a single fenestration by a carotid-carotid-succlavium bypass.

Aortic arch endografts with a single fenestration are useful for treating distal arch pathology where the proximal landing zone commences at the distal margin of the left common carotid artery origin and blood flow into the left subclavian artery needs to be preserved; however, such endografts could also be used to preserve flow into the left common carotid artery or the innominate artery if the more distal arch branches are revascularized by other means, such as bypass surgery.

Case Report

An 81-year-old patient, chronic ischemic heart disease, suffering from prostatic K undergoing chemotherapy, came to the emergency room of our hospital for post-traumatic fracture of the right femur, associated with dysphonia and respiratory disorders for several days (**Table 1**).

Table 1

Characteristics of the Patient.

Patient Characteristics	
Age, y	**84**
Hypertensiona	**1**
Diabetes	**0**
Dyslipidemia	**1**
Smoking	**0**
COPD	**1**
CAD	**1**
LV ejection fraction <40%	**0**
Prior aortic surgery	**0**
Renal insufficiency	**0**
eGFR, mL/min/1.73 m2	**103**
ASA score	**2**

Abbreviations: ASA, American Society of Anesthesiologists; CAD, coronary artery disease; COPD, chronic obstructive pulmonary disease; DAP, dose area product; eGFR, estimated glomerular filtration rate; LV, left ventricular; [a]Systolic pressure >140 mm Hg or treatment.

During the hospital stay, the patient underwent Computed Tomography Angiography that revealed the presence of a voluminous aneurysm of the aortic arch with a maximum diameter of about 70mm (**Figure 1A**). The saccular aneurysm involved the origin of the Left Subclavian Artery (LSA) and Left Common Carotid Artery (LCCA) and Right Common Carotid Artery (RCCA) in the absence of a sufficient proximal aortic collar downstream of the TB (**Figure 1B, 1C, 1D, 1E**).

The aorto-iliac and trunk anatomical details supra-aortics with the respective feasibility criteria for endovascular treatment are summarized in **Table 2**.

Table 2

Anatomical criteria for eligibility for endovascular treatment of the aortic arch and anatomical characteristics of the clinical case.

Anatomical criteria	Characteristics of the clinical case
Aneurysm of the aortic arch	Saccular aneurysm 70 mm in diameter
Iliac accesses navigable	Yes
Ascending aorta length	89mm between the sino-tubular junction and the anonymous trunk
Diameter of the ascending aorta	Ascending aorta with a maximum diameter of 41 mm
Anonymous trunk with diameter ≤20 mm and sealing area ≥20 mm	Yes

Due to the absence of a healthy collar and the anatomy of the epiaortic trunks, it was not possible to plan an endovascular intervention with standard endografts and, given the patient's condition; it would not have been prudent to wait 30 days for the production of a custom-made endograft. Therefore, a *self-made* endograft was created by modifying the standard endograft (Zenith Alpha ™ Thoracic Endovascular Graft Proximal Component Cook Medical[9] (**Figure 2A**).

The procedure was carried out in the hybrid room by a team of vascular surgeons, assisted by interventional cardiologists following the three-dimensional reconstructions of CT images. A single fenestration (dm 1cm) for the Brachio-Cephalic Trunk (BCT) of appropriate size and location is made in between the endograft stent struts, in line with the radiopaque mid-marker, using a thermal cautery instrument (**Figure 2B**). Thereafter, a radiopaque nitinol wire is sewn onto the edge of the fenestration (**Figure 2C**). In the arch endograft system described above, the fenestration is circular and is of comparable size to the target vessel; these features allow sealing in the ascending aorta (**Figure 2D**).

The procedure was performed in the operating room by a team of vascular surgeons, assisted by interventional cardiologists who placed a temporary cardiac pacing to produce bradycardia in the patient at the time of the endograft release. To ensure access and navigability of the endograft, a bilateral percutaneous access to the common femoral and a surgical access from the right brachial artery were performed. The first surgery was a carotid-carotid-subclavian bypass, in order to preserve the cerebral and upper limb vascularity. The endograft sealing in the ascending aorta.

Intraoperative angiogram and completion angiogram showing successful exclusion of the aneurysm, and preservation of all supra-aortic branches with the patency of the carotid-carotid-subclavian bypass and normal cerebral and upper limb vascularization (**Figure 3**).

Discussion

The recent guidelines for aneurysmal pathology of the aortic arch of the European Societies of Vascular Surgery and Cardio-Thoracic Surgery[12] recommend treatment endovascular through fenestrated endografts in specialized centers with high volume, for patients not suitable for traditional surgery, in the presence of specific anatomical features.

The development of endovascular technology has spurred another revolution in the management of aortic arch aneurysms[13].

However, CSGs have long manufacturing times and are therefore inappropriate for symptomatic and ruptured aortic arch aneurysm. In 2012, the first "*off-the-shelf*" multibranched endograft for endovascular aneurysm repair was approved in Europe. The initial clinical experiences showed interesting early results in both elective and urgent settings, but larger cohorts and longer follow-up are needed to verify this device. In fact, branched aortic endografts have been developed for this purpose and are currently undergoing clinical investigation [7-10]. The development of a device with a single internal branch allows complete endovascular treatment of the aneurysm of the aortic arch, reducing the time or the need of further anesthesia and the risks of damage to structures lymphatics, nerve perioperative hematomas. Precise deployment of these fenestrated arch endografts is important to correctly orient the fenestrations toward the branches for which they are intended. It is therefore desirable to have a system that allows full deployment of a fenestrated arch endograft immediately after introduction, facilitates correct orientation of the fenestrations, and minimizes subsequent manipulations to cannulate these openings[11].

Recent experiences of the literature have reported satisfactory technical results e clinical in the endovascular treatment of arch aneurysms aortic artery by branched endograft, with a mortality rate and perioperative cerebrovascular events ranging from 0.5% and 0.7%, respectively [8, 14-17]. The endograft most commonly implanted for this treatment is the one that uses two antegrade branches for the trunk anonymous and the left common carotid artery (CCS) with associated surgical revascularization of the left subclavian artery (ASS) by carotid-subclavian bypass or transposition of the subclavian artery.

Recently, however, Gallitto et al.[8] underwent the endovascular treatment of an arch aneurysm aortic by means of custom made endograft with three internal branches for the supraortic trunks, in a patient at high risk for the conventional surgical treatment.

In this report, instead, we describe the effective treatment of a voluminous aneurysm of the aortic arch via a totally endovascular route, in a high-risk patient aged over eighty considered unsuitable for traditional surgery. This procedure was performed using a *self-made* endograft with a single fenestration that ensured the revascularization of the supra-aortic trunks. These data can be evaluated for a greater diffusion of the totally endovascular treatment of aneurysms of the aortic arch and in the eventual creating an off-the-shelf device available for cases urgent or for bulky aneurysms where the risk of rupture during the customization times it is not negligible.

Conclusion

A *self-made* endovascular device with a single fenestration is a safe and effective option to guarantee a total endovascular repair of aortic arch aneurysm in high-risk patients in the presence of anatomical feasibility. Further evaluation is required to confirm these promising results. Such advanced aortic procedures are nevertheless reserved for those centers that have a good volume of interventions on complex aortic surgery.

Declarations

Acknowledgements

Not applicable.

Authors' contributions

Conceptualization, V.G.; methodology, D.B. and V.G.; validation, R.S. and L.F.; resources, R.S.; writing—original draft preparation D.B. and V.G.; writing—review and editing, R.S. D.B. and V.G.; visualization, R.S. and V.G.; supervision, L.F.; project administration, V.G. All authors have read and agreed to the published version of the manuscript.

Funding

Not applicable.

Availability of data and materials

The dataset supporting the conclusions of this article is included within the article, and any other inquiry is available from the corresponding author on reasonable request.

Ethics approval and consent to participate

The case is presented anonymously, and patient consent and hospital approval have been obtained for publication.

Consent for publication

Verbal informed consent was obtained from the patient for publication of this case report and accompanying images.

Competing interests

The authors declare that they have no competing interests.

Author details

[1] *Vascular Surgery, Hospital of National Importance San Giuseppe Moscati, Via Contrada Amoretta 83100 Avellino, Italy*

[2] *Department of Science and Technologies, University of Sannio, Benevento, Italy*

References

1. Conrad MF, Crawford RS, Davison JK, Thoracoabdominal aneurysm repair: a 20-year perspective. Ann Thorac Surg, 2007; 83: S856-S861.
2. Alonso Pérez M, Llaneza Coto JM, Del Castro Madrazo JA, Fernández Prendes C, González Gay M, Zanabili Al-Sibbai A. Debranching aortic surgery. J Thorac Dis. 2017; 9(Suppl 6): S465-S477. doi: 10.21037/jtd.2017.03.87.
3. Coselli JS, LeMaire SA, Preventza O, et al. Outcomes of 3309 thoracoabdominal aortic aneurysm repairs. J Thorac Cardiovasc Surg. 2016; 151:1323-37. 10.1016/j.jtcvs.2015.12.050.
4. Murana G, Castrovinci S, Kloppenburg G, et al. Open thoracoabdominal aortic aneurysm repair in the modern era: results from a 20-year single-centre experience. Eur J Cardiothorac Surg 2016; 49:1374-81.
5. Matsumura JS, Lee WA, Mitchell RS, The Society for Vascular Surgery Practice Guidelines: management of the left subclavian artery with thoracic endovascular aortic repair. J Vasc Surg. 2009;50:1155–1158.
6. Spear R, Haulon S, Ohki T, et al. Editor's choice—subsequent results for arch aneurysm repair with inner branched endografts. Eur J Vasc Endovasc Surg. 2016;51:380–385.
7. Franzese I, Petrilli G, Puppini G, Bacich D, Giambruno V, Faggian G. Total Endovascular Aortic Arch Repair with Branched Graft. Aorta (Stamford). 2019 Jun;7(4):121-124. doi: 10.1055/s-0039-1694014.
8. Gallitto E, Faggioli G, Spath P, Marrozzini C, Pini R, Bruno AG, Logiacco A, Gargiulo M. Trattamento endovascolare di un aneurisma dell'arco aortico mediante endoprotesi custom-made con tre branch interni G. Ital Cardio.l 2021;22(3 Suppl. 1):46S-50S doi 10.1714/3578.35635.
9. Zimmermann A, Menges AL, Rancic Z, Meuli L, Dueppers P, Reutersberg B. E-nside Off-the-Shelf Inner Branch Stent Graft: Technical Aspects of Planning and Implantation. J Endovasc Ther. 2022;29(2):167-174. doi: 10.1177/15266028211047967.
10. Tan KT, Mafeld SC, Lindsay TF. Endovascular Management of Unused Fenestrations or Branches in Fenestrated/Branched Aortic Endograft. J Endovasc Ther. 2022 Apr;29(2):175-180. doi: 10.1177/15266028211045704.
11. Inizio moduloFine moduloJoseph G, Premkumar P, Thomson V, Varghese M, Selvaraj D, Sahajanandan R. Externalized Guidewires to Facilitate Fenestrated Endograft Deployment in the Aortic Arch. J Endovasc Ther. 2016 Feb;23(1):160-71. doi: 10.1177/1526602815614557.
12. Czerny M, Schmidli J, Adler S. Current options and recommendations for the treatment of thoracic aortic pathologies involving the aortic arch: An expert consensus document of the European

Association for Cardio- Thoracic Surgery (EACTS) & the European Society for Vascular Surgery(ESVS). Eur J Vasc Endovasc Surg 2018. https://doi.org/10.1016/j. ejvs.2018.09.016

13. Rommens KL, Estrera AL. Contemporary Management of Aortic Arch Aneurysm. Semin Thorac Cardiovasc Surg. 2019; Winter;31(4):697-702. doi: 10.1053/j.semtcvs.2019.03.011.
14. Tsilimparis N, Haulon S, Spanos K, et al. Combined fenestrated-branched endovascular repair of the aortic arch and the thoracoabdominal aorta. J Vasc Surg. 2020; 71:1825-33.
15. Tsilimparis N, Detter C, Law Y, et al. Single-center experience with an inner branched arch endograft. J Vasc Surg. 2019; 69:977-85.e1.
16. Spanos K, Tsilimparis N, Rohlffs F, et al. Total endovascular arch repair is the procedure of the future. J Cardiovasc Surg 2018; 59:559-71
17. Clough RE, Spear R, Van Calster K, et al. Case series of aortic arch disease treated with branched stent-grafts. Br J Surg. 2018; 105:358-65.

Figures

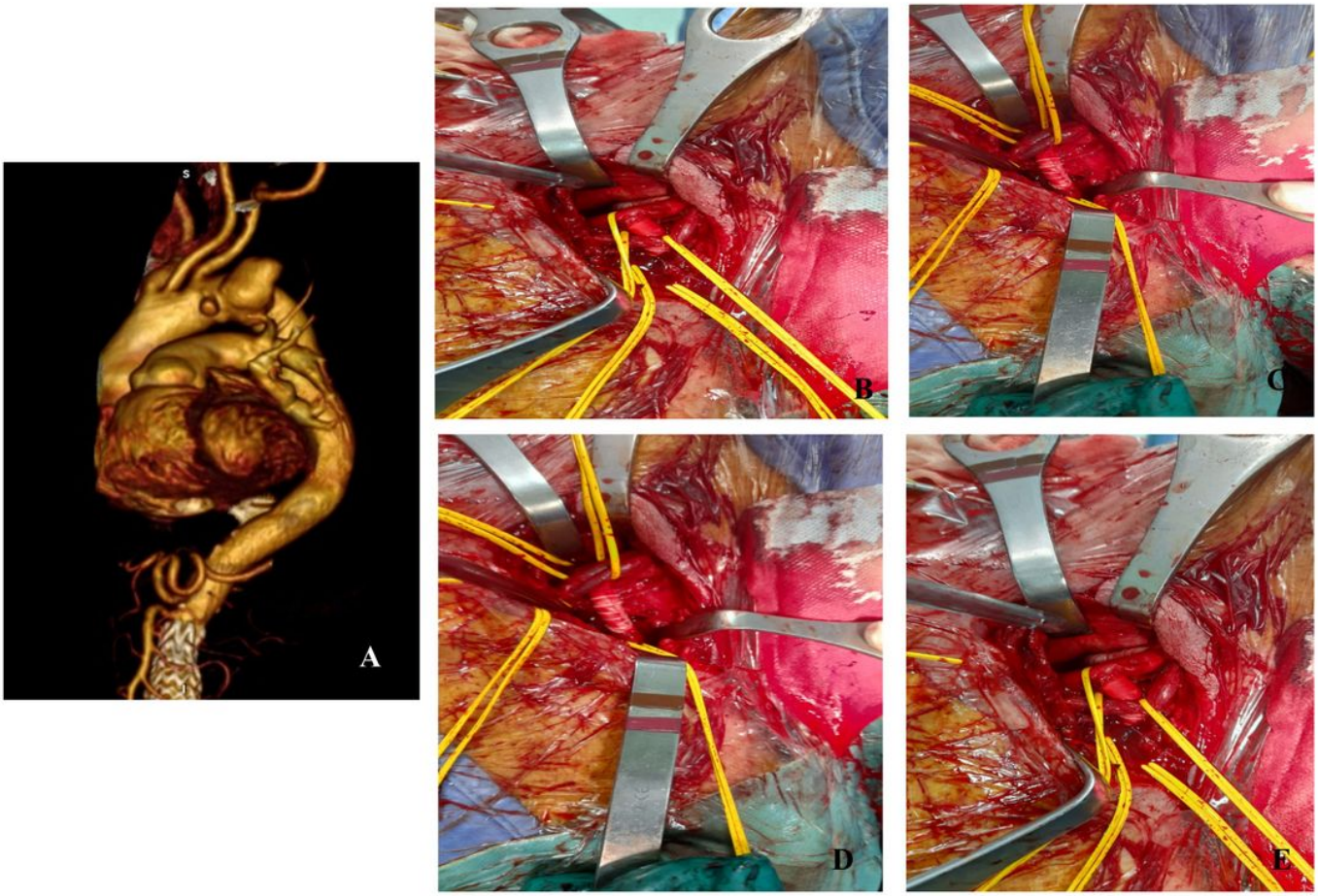

Figure 1

Three-dimensional reconstruction of angio-tomography in anterior-posterior view. Axial image of the saccular aneurysm of the aortic arch (A), a carotid-carotid-succlavium bypass (B, C, D, E). A more detailed description in the text.

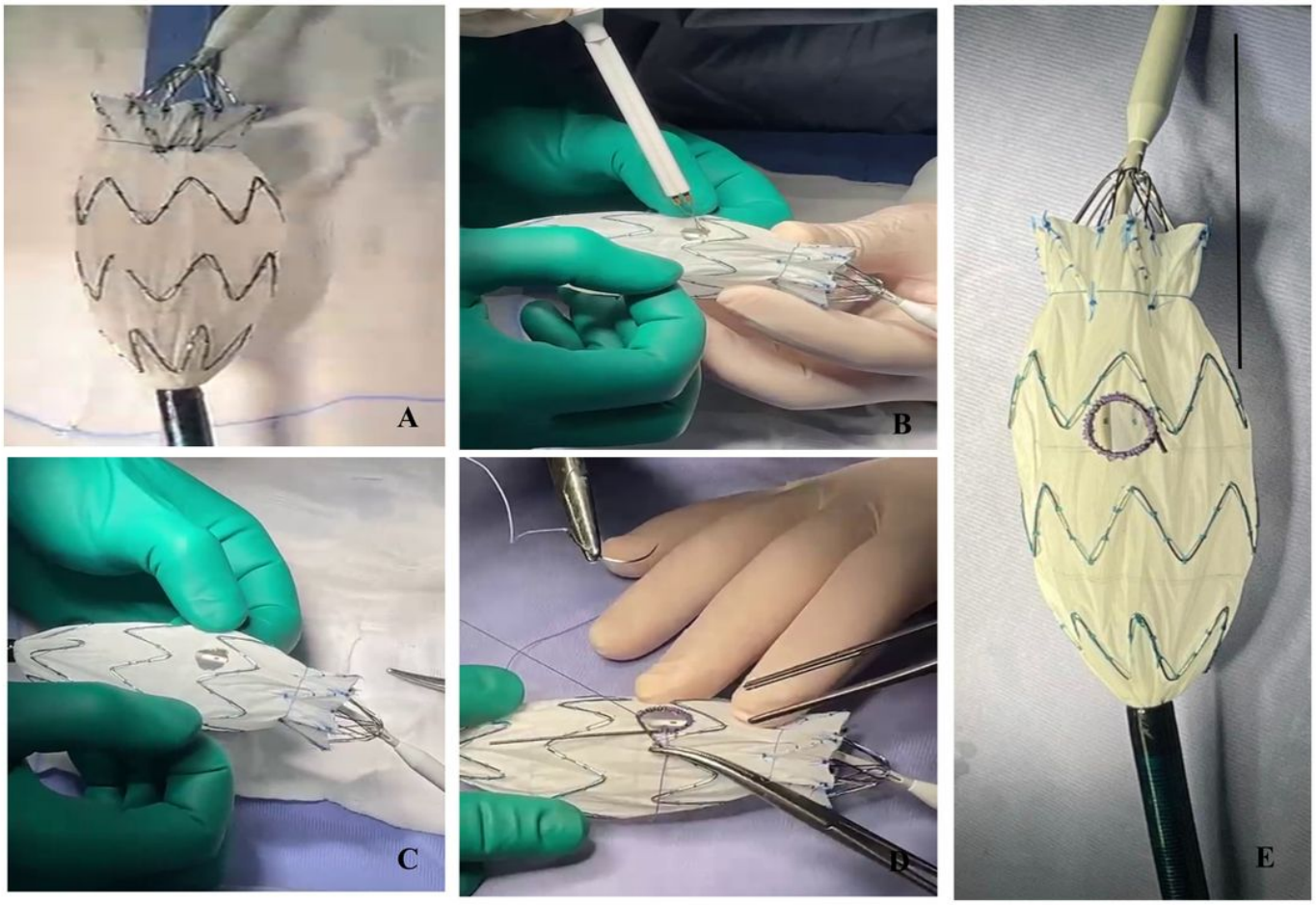

Figure 2

Photo of the self-made endograft with a single a single fenestration for the Brachio-Cephalic Trunk (BCT) (E). (A) The standard endograft (Zenith Alpha ™ Thoracic Endovascular Graft Proximal Component Cook Medical); (B-C) A single fenestration is using a thermal cautery instrument; (D) A radiopaque nitinol wire is sewn onto the edge of the fenestration. A more detailed description in the text.

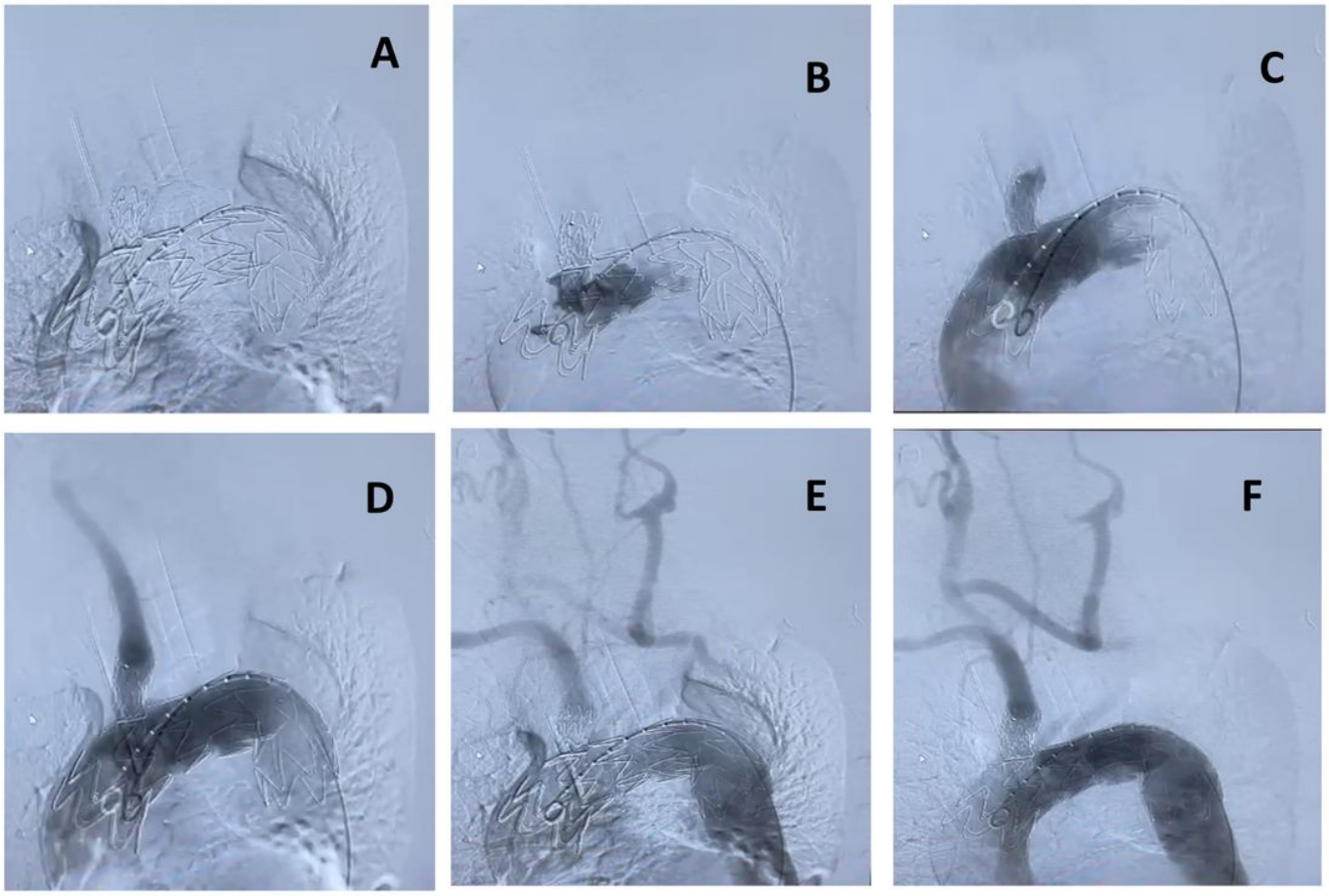

Figure 3

Intraoperative angiographic images in the positioning of the endograft in the aortic arch above the coronary plane and at the origin of the supra-aortic trunks (A). Control angiography after complete release of the self-made endograft (B). Selective angiographic control after delivery of the brachio-cephalic stem covered stent (C), left common carotid artery (D) and by pass of the left subclavian artery (E). The final angiography confirms the correct positioning of the endograft and the patency of the supra-aortic trunks (F).

Supplementary Files

This is a list of supplementary files associated with this preprint. Click to download.

- Table1.docx
- Table2.docx