Clinical and aesthetic outcomes of different papillae width following modified coronally advanced tunnel technique: A retrospective study

Huiwen Chen
Ninth People's Hospital, Shanghai Jiao Tong University School of Medicine
Jiachen Dong
Ninth People's Hospital, Shanghai Jiao Tong University School of Medicine
Sicheng Wu
Shanghai Jiao Tong University School of Medicine
Zhongchen Song (szhongchen@sina.com)
Ninth People's Hospital, Shanghai Jiao Tong University School of Medicine

Research Article

Keywords: Gingival recession, modified coronally advanced tunnel technique, papilla width, outcomes assessment

Posted Date: July 5th, 2022

DOI: https://doi.org/10.21203/rs.3.rs-1786644/v1

Abstract

Objective

This study was to investigate whether the width of the interdental papillae could contribute to clinical and aesthetic outcomes of the modified coronally advanced tunnel technique (MCAT).

Materials and Methods

A total of 28 patients with 70 class RT1 single and multiple gingival recessions (GRs) were treated by MCAT between March 2017 and March 2021. The apex angle of the mesial and distal papillae adjacent to the involved tooth were recorded at baseline. Clinical outcomes (mean root coverage (mRC) and complete root coverage (CRC)) were recorded at 12 months after surgery. Periodontal clinical parameters (keratinized tissue width (KTW), gingival index (GI), plaque index (PLI), periodontal probing depth (PPD), and clinical attachment loss (CAL)) were recorded at baseline and 12 months after surgery. Aesthetic evaluation was carried out using the root coverage esthetic score (RES) and patients' visual analogue scale (VAS). The possible relationship between papilla width and clinical and/or aesthetic outcomes was discerned by multiple linear regression and logistic regression.

Results

The mean width of papilla ranged from 22.6° to 74.65° with a median of 42.32° (IQR: 16.98°). For single GRs, the papilla width was not significantly correlated to mRC, RES, CRC, VAS gain, CAL gain, and KTW gain. The RES and CRC were only associated with papilla width in multiple GRs ($P = 0.012$). At 12 months, 95.79 ± 10.17% and 92.94 ± 10.64% of mRC were obtained for multiple GRs and single GRs, respectively. Better results in terms of CRC were obtained from multiple GRs compared with single GRs (78.94% vs. 66.67%). For aesthetic outcomes, 8.84 ± 1.54 and 9.16 ± 1.53 of RES were observed at single and multiple GR defects.

Conclusions

The CRC and RES of multiple GRs following MCAT is significantly correlated to papillae width. Relatively wide gingival papillae tend to have a greater chance to achieve complete root surface coverage.

Clinical relevance:

The width of the gingival papilla helps to speculate on the clinical outcome of root surface coverage. Although the findings are not yet highly predictable, the MCAT can yield better results in the wider gingival papilla area.

Introdution

Gingival recession (GR) is a pathological state which is defined as the location of gingival margin is apical to the cementoenamel junction (CEJ). The bare root surfaces have an increased risk for caries, erosions, plaque accumulation, dental hypersensitivity, and esthetic concerns for many patients[1]. The prevalence and severity of gingival recession increased with age. Epidemiological investigation shows that at least 40% of young adults have at least one site with 1 mm or more of recession[2].

The therapy of GRs includes conservative treatment and surgical intervention[3]. Generally, surgical intervention refers to periodontal plastic surgery to augment soft tissues coronal to the gingival margin (root coverage). Many surgical procedures have been developed to reach this goal. The coronally-advanced flap (CAF) with subepithelial connective tissue graft (SCTG) is considered the gold standard for root coverage, which achieves approximately 80% root coverage[4]. To meet the high esthetic demands of patients, advancements in technology and surgical methods have led periodontal plastic surgery into an era of minimally invasive surgery[5].

Zabalegui et al.[6] created the ‘tunnel’ technique based on the ‘envelope’ technique. Azzi et al.[7] presented a modification of Zabalegui’s flap design. They prepared a mucoperiosteal–mucosal tunnel that also involved the tissues of the interdental papillae. This extended tunneling flap design allowed, for the first time, for considerable coronal displacement of the entire gingivopapillary complex, including the grafted tissues. The technique was further improved by Zuhr et al[8]. using a microsurgical approach. Compared with other traditional root coverage procedures, the modified coronally advanced tunnel technique (MCAT) applies more delicate minimally invasive surgical instruments, which greatly reduces tissue damage in the operative area. The non-dissecting papillae and incision design (without vertical releasing incisions) provide great blood supply, great nutrition, and help would healing quickly. A randomized, double blind, mono-center clinical trial indicated that both CAF and modified tunnel technique with SCTG could result in optimal clinical outcomes, while the tunnel technique revealed less pain experience and better aesthetic assessments[9].

However, tunnel technique requires more proprietary instrumentation, and higher operating skill levels. In clinical practice, narrow and shallow papillae are difficult to deepithelialized and represent a weak anchorage for both the SCTG and the flap. Narrow papillae had an increased risk of tearing when separating the entire interproximal papillae. This tearing damage may in turn affect blood supply of papillae and early healing, which against the original intention of choosing this procedure[10].

Papillae dimension has been believed to have an important impact on determining the surgical management of soft tissues and the amount of achievable root coverage[11]. Most literature focus on the height of papillae. For CAF combined with CTG technique, a papilla height ≤ 1 mm was considered as an independent risk factor related with the inability of achieving a complete root coverage (odds ratio: 97.3)[12]. In the tunnel technique, Aroca S. et al.[13] demonstrated that the smaller the distance from the tip of the papilla and the contact point, the better mean root coverage. However, the existing literature evidence could not draw any clear conclusion on the effect of papillae width on root coverage treatment outcomes, especially for MCAT.

Therefore, we conducted a retrospective study with the purpose of determining whether any correlation exists between the papillae width and clinical and aesthetic outcomes with the MCAT.

Material And Methods

Ethic statement

The study design and protocol were conducted according to the Helsinki Declaration as revised in 2000 and were approved by the Institutional Ethics Committee of Ninth People's Hospital Affiliated to Shanghai Jiao Tong University School of Medicine (SH9H-2021-T102-1).

Study design

This retrospective study included patients with GRs who had treated with MCAT at the Department of Periodontology of Shanghai Ninth People's Hospital attached to Shanghai JiaoTong University School of Medicine between March 2017 and March 2021.

The baseline date was defined as the time of mucogingival surgery. The primary endpoint was root coverage esthetic score (RES) at 12 months.

The follow-up was the time between the baseline date until the primary endpoint, or the end of study follow-up period set as March 31, 2021 to allow at least a minimum follow-up of 12 months for all patients. All patients were recalled at 2 weeks, 1 month, 6 months and 12 months after surgery.

Baseline demographic characteristics of all patients were collected as following: age, gender, orthodontic history, frenum attachment, single or multiple GRs, classification of periodontitis (classified into 6 categories: periodontal health, gingivitis, periodontitis stage I, periodontitis stage II, periodontitis stage III, and periodontitis stage IV)[14], periodontal phenotype (classified into 3 categories: thin-scalloped, thick-scalloped, and thick flat)[15], position of the involved tooth (6 categories: anterior maxilla, maxillary premolars, maxillary molars, anterior mandible, mandibular premolars, and mandibular molars).

The primary outcome variable was root coverage esthetic score (RES). The secondary outcome variables were mean root coverage (mRC), complete root coverage (CRC), gain in clinical attachment level (CAL), increase in keratinized tissue width (KTW), changes in periodontal probing depth (PPD), changes in gingival index (GI), changes in plaque index (PLI), and changes in patients' aesthetic satisfaction by a visual analogue scale (VAS).

This study was performed according to the STROBE checklist.

Inclusion and exclusion criteria

Patients satisfying the following criteria were enrolled in this study:

- ≥ 18 years old

- Single or multiple GR defects of type I (RT1) (≤ 5 mm)
- Identifiable cemento-enamel junction (CEJ)
- Surgical treatment of GRs with modified coronally advanced tunnel technique (MCAT)
- Systemically healthy
- Minimum of 12 months of follow-up
- Availability at regular follow-up appointments for clinical examination, intra-oral photographs and periodontal maintenance therapy

To minimize the confounding factor of clinical and aesthetic outcomes following root-coverage procedure, patients were excluded from the study if they met 1 or more of the following criteria: smoking; extruded or malpositioned teeth; existing caries, pulpal and periapical diseases, dental restorations, or non-cavitated caries lesions (NCCL) in the area to be treated; have mucogingival surgery or other periodontal surgery on involved sites.

These exclusions are unlikely to cause major selection bias.

Definitions

We defined the average of the angles of the distal and mesial gingival papillae of the involved teeth as the gingival papilla width. The area of the gingival papilla is approximated as an isosceles triangle. The value of the apex angle of the papilla can be obtained by measuring the two lateral sides of the same length and the corresponding bottom side and then applying the trigonometric function. The measurements were rounded to the nearest 0.5mm (Fig. 1).

Data collection

An independent investigator (CHW) measured all trial outcomes. A total of six patients not included in the study with at least two GRs were used to calibrate the investigator, who assessed all GRs in each patient with an interval of 24 h between recordings. Calibration was accepted when ≥ 90% of the recordings were reproduced within a difference of 1.0 mm[16].

All subjects were evaluated by periodontal clinical examination (UNC-15 periodontal probe, Hu-Friedy®, Chicago, USA) and intra-oral photographs (Digital SLR camera, Cannon 700D, Cannon Inc., Tokyo, Japan) at baseline, 2 weeks after surgery, 1-month post-surgery, 6 months post-surgery and 1-year post-surgery.

Clinical assessments of the involved tooth were evaluated at baseline, 1, 6, and 12 months after surgery. The following measurements were collected: mRC and CRC at 12 months after surgery, periodontal probing depth (PPD) (baseline & after 12 months), clinical attachment level (CAL) (baseline & after 12 months), keratinized tissue width (KTW) (baseline & after 12 months), gingival index (GI) (Löe and Silness, 1963) (baseline, after 1, 6, 12 months) and plaque index (PLI) (Silness and Löe, 1964) (baseline, after 1, 6, 12 months).

At suture removal date, possible soft tissue complications (necrosis, infection, bleeding) were collected.

Aesthetic evaluation was carried out using the root coverage esthetic score (RES) at 12 months post-surgery. The RES system contained five variables: Gingival margin (GM: 0, 3 or 6), Marginal Tissue Contour (MTC: 0 or 1), Muco-Gingival Junction (MGJ: 0 or 1), Soft Tissue Texture (STT: 0 or 1) and Gingival Color (0 or 1), with final RES value ranging from 0 to 10[17]. Patients' aesthetic satisfaction with surgical site was evaluated quantitatively by a visual analogue scale (VAS) from 0 to 10 at baseline and at the 12-month evaluation.

Periodontal therapy

All patients received oral hygiene instruction (to modify traumatic tooth brushing habits), full-mouth supragingival scaling, subgingival scaling and polishing by the same periodontal specialist (DJC). 4–6 weeks later, reevaluation was performed. The mucogingival surgery was performed only when adequate plaque control was reached (Full-mouth plaque score and full-month bleeding score < 25%).

Surgical procedure

All surgical procedures were performed at the Department of Periodontology of Shanghai Ninth People's Hospital attached to Shanghai JiaoTong University School of Medicine by the same surgeon (DJC), who has 9-year experience as a periodontal specialist. Before the surgery, a 0.12% chlorhexidine rinse was applied for intraoral antisepsis. After disinfection of the oral cavity, injection of local anesthetics (Primacaine™ adrenaline 1/100000, Produits Dentaires Pierre Rolland, France) was performed. The tunnel flap was performed started with intrasulcular incisions by using microsurgical blade. To ensure a coronal positioning of the tunnel flap, the intrasulcular incisions were extended to the neighboring teeth. A split-full-split thickness flap was then preparation: after reaching the buccal bone crest with intrasulcular cuts, flap elevation was continued by full-thickness preparation for the next 3–4 mm with microsurgical periosteal separator (Stoma®, German). Subsequently, a sharp horizontal dissection of the periosteum had to be performed. The supraperiosteal dissection was extended well beyond the mucogingival junction, deep into the mucosal tissues, in order to gain sufficient flap mobility from the apical aspect. The full-thickness flap elevation was carefully performed at the buccal papillary regions. A subepithelial connective tissue graft (SCTG) was harvested from the palate according to the gingival recession width and height and then carefully inserted into the tunnel by guided sutures (5 – 0 polyglactin suture). Finally, sling sutures were performed with 6 – 0 nylon monofilament non-absorbable suture to position the flap coronal for completely covering the SCTG.

Patients were instructed to 0.12% chlorhexidine rinse three times a day for 1 minute every day and lightly brush surgical sites with an ultra-soft bristle toothbrush after 2 weeks postoperatively. In addition, amoxicillin (500 mg 3 times per day for 3 days) and ibuprofen (1 tablet per day when necessary) for infection and pain control. The suture was removed 10–14 days after surgery. A clinical case is shown in Fig. 2.

Statistical analysis

Patients' characteristics were presented as absolute and relative frequencies for categorical outcomes. The Shapiro-Wilk test was carried out to evaluate the normality. The normally distributed variables were described using the mean and standard deviation (SD) including 95% confidence intervals (CI), while the median and interquartile range (IQR) was used to describe non-normally distributed data.

Clinical parameters' changes from baseline through 12 months after surgery were analyzed with paired-samples *t*-test (or Wilcoxon signed-rank test) and repeated-measures ANOVA (or Friedman test) with a Bonferroni's post-test for multiple comparisons. In an attempt to determine whether the papilla width was associated with 12-month clinical and aesthetic outcomes, five multiple line regression models were set by the following dependent variables: RES, mRC, VAS change, gain in CAL, and gain in KTW (continuous dependent variables); and a logistic regression was set by CRC (binary variable). Multivariate analysis was performed to adjust for age, sex, periodontal phenotype, position of the involved tooth, and other potential confounders. All hypothesis tests were conducted at the 5% level of significance.

All data were analyzed by a statistical program (SPSS Statistical for Windows, IBM Corp., Armonk, NY, USA, Version 25.0). Patients' names were hidden during all of data analysis.

Results

Patient and surgical sites characteristics

A total of 28 patients (12 males, 16 females) with 70 GR defects met the inclusion criteria. The mean age of patients was 30.50 ± 4.80 years old. The mean width of papilla ranged from 22.6° to 74.65° with a median of 42.32° (IQR: 16.98°).

As shown in Table 1, the locations of the GR defects were as followed: 26 (37.1%) in the anterior maxilla, 15 (21.4%) in the maxillary premolars; 26 (37.1%) in the anterior mandible, and only 3 (0.04%) in the mandibular premolars. For periodontal status, most of GR sites had gingivitis (61.4%), 12.9% had periodontitis with stage I, and 25.7% presented periodontal health. In terms of localized or multiple GR defects, 27.1% were single gingival recession sites while the rest presented with multiple GR defects. Thirty-one (44.3%) surgical sites with thin-scalloped phenotype, 52.9% with thick-scalloped phenotype, and only 2.8% with thick-flat phenotype. Three GR defects (4.3%) were combined with abnormal frenum attachment. As for orthodontic history, 18 (25.7%) sites were demanded pre-orthodontic periodontal procedures to minimize gingival recession during the orthodontic treatment. 8.6% sites received mucogingival surgery during the orthodontic therapy and 7.1% sites referred to root coverage treatment after the orthodontic therapy were finished.

Table 1
Summary of characteristics

Variables	Number of Surgical sites (%)
Location	
Anterior maxilla	26 (37.1)
Maxillary premolars	15 (21.4)
Maxillary molars	0 (0)
Anterior mandible	26 (37.1)
Mandibular premolars	3 (0.04)
Mandibular molars	0 (0)
Classification of periodontitis	
Periodontal Health	18 (25.7)
Gingivitis	43 (61.4)
Periodontitis Stage I	9 (12.9)
Periodontitis Stage II	0 (0)
Periodontitis Stage III & IV	0 (0)
Single/multiple gingival recession defects	
Single	19 (27.1)
Multiple	51 (72.9)
Periodontal phenotype (gingival morphology)	
Thin-scalloped	31 (44.3)
Thick-scalloped	37 (52.9)
Thick-flat	2 (2.8)
Frenum attachment	
Normal	67 (95.7)
Abnormal	3 (4.3)
Orthodontic history	
Before orthodontic therapy	18 (25.7)
Undergoing orthodontic therapy	6 (8.6)
After orthodontic therapy	5 (7.1)

Variables	Number of Surgical sites (%)
No need for orthodontic therapy	41 (58.6)

Periodontal clinical parameters

The changes in the periodontal clinical parameters from baseline to 12 months after surgery were presented in Table 2. From all treatment sites, the mean CAL at baseline was 1.38 ± 0.53 mm, and the mean CAL at 12 months after surgery was 0.20 ± 0.45 mm. The difference in CAL before and after surgery was 1.19 ± 0.51 (95% CI: 1.07–1.32) mm. The mean KTW at baseline was 1.79 ± 0.12 mm, and the mean KTW at 12 months after surgery was 3.50 ± 0.08 mm. The difference in KTW after and before surgery was 1.69 ± 1.09 (95% CI: 1.43–1.95) mm. The changes of CAL and KTW from baseline to 12 months were significant ($P < 0.001$).

Table 2
Periodontal clinical parameters at baseline and 1, 6, 12 months after surgery

	PLI	GI	PPD (mm)	CAL (mm)	KTW (mm)
	Medium (IQR)	Medium (IQR)	Mean ± SD (95%CI)	Mean ± SD (95%CI)	Mean ± SD (95%CI)
Total sites					
Baseline	1.00 (1.00)	1.00 (1.00)	2.02 ± 0.05 (1.93–2.12)	1.38 ± 0.53 (1.27–1.50)	1.79 ± 0.12 (1.56–2.03)
1 month after surgery	1.00 (0.00)	1.00 (0.00)	/	/	/
6 months after surgery	1.00 (0.00)	1.00 (0.00)	/	/	/
12 months after surgery	1.00 (0.00)	1.00 (1.00)	1.91 ± 0.38 (1.83–1.98)	0.20 ± 0.45 (0.10–0.28)*	3.50 ± 0.08 (3.32–3.65)*
Single gingival recession sites					
Baseline	1.00 (1.00)	1.00 (1.00)	2.00 ± 0.09(1.82–2.19)	1.40 ± 0.11(1.18–1.63)	1.53 ± 0.26 (0.97–2.08)
1 month after surgery	1.00 (0.00)	1.00 (1.00)	/	/	/
6 months after surgery	1.00 (0.00)	1.00 (0.00)	/	/	/
12 months after surgery	1.00 (1.00)	1.00 (1.00)	1.79 ± 0.76 (1.63–1.95)	0.21 ± 0.87 (0.03–0.39)*	3.42 ± 0.18 (3.04–3.80)*
Multiple gingival recession sites					
Baseline	1.00 (1.00)	1.00 (1.00)	2.03 ± 0.06 (1.91–2.15)	1.37 ± 0.62 (1.25–1.50)	1.89 ± 0.13 (1.63–2.15)
1 month after surgery	1.00 (1.00)	1.00 (0.00)	/	/	/
6 months after surgery	1.00 (0.00)	1.00 (0.00)	/	/	/
12 months after surgery	1.00 (0.00)	1.00 (1.00)	1.87 ± 0.43 (1.72–1.90)	0.18 ± 0.05 (0.07–0.29)*	3.51 ± 0.09 (3.33–3.69)*

Note: PLI: plaque index; GI: gingival index; PPD: periodontal probing depth; CAL: clinical attachment level; PPD: Periodontal probing depth; KTW: keratinized tissue width; IQR: interquartile range

*: Compared with baseline, $P < 0.05$

For single GR sites, the mean CAL at baseline was 1.40 ± 0.11 mm, and the mean CAL at 12 months after surgery was 0.21 ± 0.87 mm. The mean KTW at baseline was 1.53 ± 0.26 mm, and the mean KTW at 12 months after surgery was 3.42 ± 0.18 mm. The changes of CAL and KTW from baseline to 12 months were also significant ($P < 0.001$). For multiple GR sites, the mean KTW at baseline was 1.89 ± 0.13 mm, and at 12 months after surgery the mean KTW was 3.51 ± 0.09 mm. The mean CAL was changed from 1.37 ± 0.11 mm to 0.18 ± 0.05 mm ($P < 0.001$).

No statistically significant differences had been found for changes in PLI, GI and PPD values both in single and multiple GR sites.

Clinical outcomes

No serious adverse events were observed. One of twenty-eight patients reported postoperative bleeding in the palatal donor area. During the surgical proceeding, three of seventy gingival papillae experienced incomplete tears when elevating the flap, and the apex angles of the impaired papillae were 21.4 °, 27.1 °, and 32 °, respectively.

The overall calculated mRC and CRC of MCAT for all GR defects were 93.71 ± 10.51% and 74.2%, respectively. The mRC for single and multiple GR defects were 92.94 ± 10.64% and 95.79 ± 10.17%, in addition to a CRC of 66.67% for single GR defects and 78.94% for multiple GR defects, respectively.

Aesthetic outcomes

An overall mean RES of 8.93 ± 1.53 and mean VAS of 9.40 ± 1.07 were observed at 12 months after surgery for all surgical sites included in this study. The mean RES and mean VAS for single GR defects were 8.84 ± 1.54 and 9.26 ± 1.28, respectively. While the average RES and VAS for multiple GR defects were 9.16 ± 1.53 and 9.45 ± 0.98. The difference in VAS after and before surgery was 3.32 ± 1.60 (95% CI: 2.54–4.08) ($P < 0.001$) for single GR sites, while the change was 3.63 ± 1.51 (95% CI: 3.20–4.05) ($P < 0.001$) for multiple GR sites. Keloid formation was not observed in any patient after 12 months.

Regression analysis

As shown in Table 3, the papilla width was not significantly correlated to the mRC, VAS change (from baseline to 12-month after surgery), gain in CAL, and gain in KTW. The regression coefficients (β) of each dependent variable in total sites were 0.293 ($P = 0.084$), -0.021 ($P = 0.905$), 0.213 ($P = 0.269$), and − 0.194 ($P = 0.314$), respectively. For single GR defects, the papilla width was not significantly correlated to each dependent variable. However, it was correlated to the RES after adjusting confounding factors in multiple GR sites ($P = 0.012$). The results of logistic regression were shown in Table 4. The complete root coverage was also correlated to the papilla width in multiple GR sites (OR = 1.175, 95%CI = 1.036–1.332, $P = 0.012$).

Table 3
Multiple linear regression analysis for papilla width with different dependent variables

	Dependent Variable	Model	Standardized β coefficients	*P* value
Total sites	RES	I	0.381	0.014*
		II	0.405	0.032*
	mRC	I	0.329	0.039*
		II	0.293	0.084
	VAS change	I	-0.002	0.991
		II	-0.021	0.905
	CAL gain	I	0.162	0.307
		II	0.213	0.269
	KTW gain	I	-0.149	0.354
		II	-0.194	0.314
Single GR sites	RES	I	0.230	0.520
		II	0.409	0.493
	mRC	I	0.253	0.374
		II	0.190	0.711
	VAS change	I	0.147	0.849
		II	0.603	0.650
	CAL gain	I	0.731	0.287
		II	1.395	0.234
	KTW gain	I	-0.748	0.450
		II	-1.112	0.502

Note:

Model I: adjusted for age, and sex.

Model II: as Model I, additionally adjusted for classification of periodontitis, periodontal phenotype, position of the involved tooth, orthodontic history, and frenum attachment.

GR: gingival recession; RES: root coverage esthetic score; mRC: mean root coverage; VAS: visual analogue scale; CAL: clinical attachment level; KTW: keratinized tissue width;

*: *P* value < 0.05

	Dependent Variable	Model	Standardized β coefficients	*P* value
Multiple GR sites		I	0.392	0.018*
	RES	II	0.377	0.012*
		I	0.253	0.036*
	mRC	II	0.197	0.082
		I	0.293	0.084
	VAS change	II	0.154	0.640
		I	0.180	0.562
	CAL gain	II	0.274	0.434
		I	0.230	0.519
	KTW gain	II	-0.230	0.622
		II	-0.295	0.546

Note:

Model I: adjusted for age, and sex.

Model II: as Model I, additionally adjusted for classification of periodontitis, periodontal phenotype, position of the involved tooth, orthodontic history, and frenum attachment.

GR: gingival recession; RES: root coverage esthetic score; mRC: mean root coverage; VAS: visual analogue scale; CAL: clinical attachment level; KTW: keratinized tissue width;

*: *P* value < 0.05

Table 4
Logistic regression analysis for papilla width with complete root coverage as dependent variable

	Dependent Variable	Model	OR (95%CI)	*P* value
Total sites	CRC	I	1.077 (1.011–1.148)	0.022*
		II	1.103 (1.012–1.203)	0.026*
Single GR sites		I	1.087 (0.954–1.239)	0.208
		II	1.080 (0.785–1.486)	0.635
Multiple GR sites		I	1.106 (1.009–1.213)	0.032*
		II	1.175 (1.036–1.332)	0.012*
Note:				
Model I: adjusted for age, and sex.				
Model II: as Model I, additionally adjusted for classification of periodontitis, periodontal phenotype, position of the involved tooth, orthodontic history, and frenum attachment.				
GR: gingival recession; CRC: complete root coverage				
*: *P* value < 0.05				

Discussion

This study was aimed to evaluate if the width of the interdental papilla adjacent to the gingival recession might influence the clinical and aesthetic outcomes using the MCAT procedure.

There is a range of influence factors associated with the treatment of gingival recession, such as the thin periodontal phenotype, interproximal attachment level, shallow vestibular depth, the presence of frenula, absence of keratinized gingiva, tooth location, and impropriety orthodontic treatment[18–22]. However, the impact of papillae width on root coverage outcomes or aesthetic outcomes have not been included among the mentioned parameters, as it had very little emphasis in the literature.

The values of papilla width and papilla height were used to describe papilla dimension in several studies. According to Olsson M. et al.[23], the base of the papilla is a line connecting the most apical point of the gingival margin (APGM) of a tooth with the APGM of the adjacent tooth. The height of the papilla is the distance from the top of the papilla to the base of the papilla. In case of gingival recession, the APGM of the involved tooth shifts apically and the base of the papilla changes due to this shift. Saletta et al[24]. reported a modified definition of the base of papilla to avoid the effects by the shift of the gingival margin. Mesial and distal papilla width were measured along the imaginary line connecting the CEJ of the involved tooth to the CEJ of adjacent teeth at the midline of the buccal surfaces. In this study, we simply defined papillae width as the average apex angle of mesial and distal interdental papillae. The

advantage of this definition is that it does not have to take into account the position of the gingival margin of the adjacent teeth and the base of the gingival papillae. The greater the angle of the gingival papilla, the greater the corresponding area of the coronal vascular bed.

Papillae dimension is believed to have an important impact on the periodontal plastic surgery: Once deepithelialized, they become the coronal vascular bed for the coronally positioned soft tissues[25]. Saletta et al.[24] concluded that the root coverage following CAF procedure was not significantly correlated to papilla dimension. However, they found that complete root coverage was significantly more frequent in sites with short height of the adjacent papilla. The importance of papillae height has also been confirmed in the tunnel technique[13]. Nevertheless, Berlucchi et al.[22] reported a contradicting result that there was not a clear relation between root coverage and some anatomical features as papilla width or papilla height. In this study, complete root coverage of multiple GR defects was significantly more frequent in sites with wider adjacent papilla. The root coverage score (full score: 10 points) was also higher for sites with wider gingival papillae, as influenced by the final position of the gingival margin. Because the gingival margin (full score: 6 points) accounts for a largest portion of RES, only CRC with a final gingival margin at or slightly covering the CEJ in conjunction with a physiological sulcus depth could represent the best outcome[17]. Although the wider papilla width seems to be significantly associated with a greater mRC for multiple GR defects ($P = 0.036$), after adjusting for confounding factors, gingival papilla width no longer affected on the mRC ($P = 0.082$). In contrast, it was more influenced by periodontal phenotype, which is consistent with the finding from other studies[26, 27].

Despite the limited number of studies comparing tunnel technique in single and multiple GR defects, the root surface coverage of multiple GR defects was always better than that of single GR defects[28, 29]. This is in agreement with our finding, showing a better clinical and aesthetic results in multiple GRs. It can be explained that the greater extension of the flap in multiple GR defects facilitates its passive displacement and suturing at a coronal position. In single GR defects, minimal flap extension may limit flap mobility, reducing the chances of achieving CRC[10]. Nevertheless, due to the small sample size of single GR defects included in this study, the results of regression analysis for single GRs still need to be confirmed with a larger sample size.

Mörmann & Ciancio[30] suggested that flaps should be broad enough at their base to include major gingival vessels. The increased flap width at its base will increase the blood supply and hence support a greater flap length. The papillary tissues are supplied by limited vascular supply, which can be considered as the terminal end point of the gingival microvasculature. Some experimental studies on the structure and organization of the vessels in the periodontal tissues demonstrated that the interdental col area is instead exclusively nourished from capillary vessels ascending from the periodontal ligament and the crestal area of the interdental bone[31]. Wide gingival papillae could be cautiously interpreted as having a more abundant blood supply, and increasing the possibilities for mechanical stabilization of the flap and suturing, which are potentially essential elements for successful root coverage outcomes. In addition, during the crucial phase of early wound healing, the mechanical load, as well as the microbiologic challenge, is expected to be highest in the interproximal area and the risk for secondary intention healing

in the papillary tissues is therefore rather high. This sign of overstressed wound-healing capacity may cause formation of scar tissue. The occurrence of wound dehiscences and subsequent scar tissue formation in the papillary tissues implies an esthetic failure of the procedure[32]. In tunneling flap procedures, the preparation of papilla region in the buccal soft tissues may be regarded as comparatively technique sensitive. Although the use of specifically designed microsurgical instruments allows for the best possible atraumatic preparation of the tissues, a too-narrow gingival papilla will still increase the risk of flap perforation. In the present study, all flap perforation events occurred in the narrow gingival papilla area and ultimately resulted in incomplete root surface coverage and poor aesthetic results.

The main limitation of our study is the fact that it is a retrospective study with its inherent limitations. The second major limitation of the study is the manual measurement of papilla width. Indeed, most of the digital measurements are likely more accurate and more objective than manual measurements. Another limitation of the study is the low number of single GR defects, which reduces the power of the study to analyze correlation. A further limitation of our study is the lack of information on papilla height and papilla area. The above limitations of this study do not allow us to draw a definite conclusion and further prospective clinical studies and randomized trials combined with digital scanning technology are needed.

Overall, this retrospective study indicated that complete root coverage and RES of multiple GR defects following MCAT is significantly correlated to papillae width. Relatively wide gingival papillae tend to have a greater chance to achieve complete root surface coverage.

Declarations

Acknowledgments

This work was supported by the Clinical Research Plan of SHDC (no. SHDC2020CR5015), Project of Biobank from Shanghai Ninth People's Hospital, Shanghai Jiao Tong University School of Medicine (no. YBKB201905).

Contributions

Huiwen Chen: designed the experiments, collected the data, and wrote the manuscript;

Jiachen Dong: helped to design the experiments and made the critical revision; **Sicheng Wu**: analysed all data and revised the manuscript;

Zhongchen Song: made substantial contributions to conception and design, made the critical revision. All authors agree to be accountable for the content of the work.

Ethics declarations

Conflicts of Interest

The authors declare that they have no known competing financial interests or personal relationships that could have appeared to influence the work reported in this paper.

Ethical approval

This retrospective chart review study involving human participants was in accordance with the ethical standards of the institutional and national research committee and with the 1964 Helsinki Declaration and its later amendments or comparable ethical standards. The institutional Ethics Committee of Ninth People's Hospital Affiliated to Shanghai Jiao Tong University School of Medicine approved this study (SH9H-2021-T102-1).

Informed consent

For this type of study, formal consent is not required.

Data Availability Statement

The data that support the findings of this study are available from the corresponding author upon reasonable request.

References

1. Merijohn GK (2016) Management and prevention of gingival recession. Periodontol 2000 71:228 – 42. doi: 10.1111/prd.12115
2. Chan HL, Chun YH, MacEachern M and Oates TW (2015) Does Gingival Recession Require Surgical Treatment? Dent Clin North Am 59:981 – 96. doi: 10.1016/j.cden.2015.06.010
3. Lin KL, Chou SH and Long CY (2019) Effect of Er:YAG Laser for Women with Stress Urinary Incontinence. Biomed Res Int 2019:7915813. doi: 10.1155/2019/7915813
4. Stefanini M, Marzadori M, Aroca S, Felice P, Sangiorgi M and Zucchelli G (2018) Decision making in root-coverage procedures for the esthetic outcome. Periodontol 2000 77:54–64. doi: 10.1111/prd.12205
5. Chambrone L, Salinas Ortega MA, Sukekava F, Rotundo R, Kalemaj Z, Buti J and Pini Prato GP (2018) Root coverage procedures for treating localised and multiple recession-type defects. Cochrane Database Syst Rev 10:Cd007161. doi: 10.1002/14651858.CD007161.pub3
6. Zabalegui I, Sicilia A, Cambra J, Gil J and Sanz M (1999) Treatment of multiple adjacent gingival recessions with the tunnel subepithelial connective tissue graft: a clinical report. Int J Periodontics Restorative Dent 19:199–206.
7. Azzi R, Etienne D, Takei H and Fenech P (2002) Surgical thickening of the existing gingiva and reconstruction of interdental papillae around implant-supported restorations. Int J Periodontics Restorative Dent 22:71–7.

8. Zuhr O, Fickl S, Wachtel H, Bolz W and Hürzeler MB (2007) Covering of gingival recessions with a modified microsurgical tunnel technique: case report. Int J Periodontics Restorative Dent 27:457–63.
9. Santamaria MP, Neves F, Silveira CA, Mathias IF, Fernandes-Dias SB, Jardini MAN and Tatakis DN (2017) Connective tissue graft and tunnel or trapezoidal flap for the treatment of single maxillary gingival recessions: a randomized clinical trial. J Clin Periodontol 44:540–547. doi: 10.1111/jcpe.12714
10. Tavelli L, Barootchi S, Nguyen TVN, Tattan M, Ravidà A and Wang HL (2018) Efficacy of tunnel technique in the treatment of localized and multiple gingival recessions: A systematic review and meta-analysis. J Periodontol 89:1075–1090. doi: 10.1002/jper.18-0066
11. Zucchelli G, Tavelli L, Barootchi S, Stefanini M, Wang HL and Cortellini P (2020) Clinical Remarks on the Significance of Tooth Malposition and Papillae Dimension on the Prediction of Root Coverage. Int J Periodontics Restorative Dent 40:795–803. doi: 10.11607/prd.4929
12. Ozcelik O, Seydaoglu G and Haytac MC (2015) Prediction of root coverage for single recessions in anterior teeth: a 6-month study. J Clin Periodontol 42:860–867. doi: 10.1111/jcpe.12449
13. Aroca S, Barbieri A, Clementini M, Renouard F and de Sanctis M (2018) Treatment of class III multiple gingival recessions: Prognostic factors for achieving a complete root coverage. J Clin Periodontol 45:861–868. doi: 10.1111/jcpe.12923
14. Tonetti MS, Greenwell H and Kornman KS (2018) Staging and grading of periodontitis: Framework and proposal of a new classification and case definition. J Clin Periodontol 45 Suppl 20:S149-s161. doi: 10.1111/jcpe.12945
15. Malpartida-Carrillo V, Tinedo-Lopez PL, Guerrero ME, Amaya-Pajares SP, Özcan M and Rösing CK (2021) Periodontal phenotype: A review of historical and current classifications evaluating different methods and characteristics. J Esthet Restor Dent 33:432–445. doi: 10.1111/jerd.12661
16. Górski B, Górska R, Szerszeń M and Kaczyński T (2022) Modified coronally advanced tunnel technique with enamel matrix derivative in addition to subepithelial connective tissue graft compared with connective tissue graft alone for the treatment of multiple gingival recessions: prognostic parameters for clinical treatment outcomes. Clin Oral Investig 26:673–688. doi: 10.1007/s00784-021-04045-w
17. Cairo F, Rotundo R, Miller PD and Pini Prato GP (2009) Root coverage esthetic score: a system to evaluate the esthetic outcome of the treatment of gingival recession through evaluation of clinical cases. J Periodontol 80:705–10. doi: 10.1902/jop.2009.080565
18. Zucchelli G, Tavelli L, Barootchi S, Stefanini M, Rasperini G, Valles C, Nart J and Wang HL (2019) The influence of tooth location on the outcomes of multiple adjacent gingival recessions treated with coronally advanced flap: A multicenter re-analysis study. J Periodontol 90:1244–1251. doi: 10.1002/jper.18-0732
19. Teixeira DNR, Zeola LF, Machado AC, Gomes RR, Souza PG, Mendes DC and Soares PV (2018) Relationship between noncarious cervical lesions, cervical dentin hypersensitivity, gingival recession,

and associated risk factors: A cross-sectional study. J Dent 76:93–97. doi: 10.1016/j.jdent.2018.06.017

20. Ashfaq M, Sadiq A, Sukhia RH and Fida M (2021) Association of hard and soft tissue factors with gingival recession in orthodontically treated patients: A retrospective study. Int Orthod 19:60–66. doi: 10.1016/j.ortho.2020.12.001
21. Rasperini G, Tavelli L, Barootchi S, McGuire MK, Zucchelli G, Pagni G, Stefanini M, Wang HL and Giannobile WV (2021) Interproximal attachment gain: The challenge of periodontal regeneration. J Periodontol 92:931–946. doi: 10.1002/jper.20-0587
22. Berlucchi I, Francetti L, Del Fabbro M, Basso M and Weinstein RL (2005) The influence of anatomical features on the outcome of gingival recessions treated with coronally advanced flap and enamel matrix derivative: a 1-year prospective study. J Periodontol 76:899–907. doi: 10.1902/jop.2005.76.6.899
23. Olsson M, Lindhe J and Marinello CP (1993) On the relationship between crown form and clinical features of the gingiva in adolescents. J Clin Periodontol 20:570–7. doi: 10.1111/j.1600-051x.1993.tb00773.x
24. Saletta D, Pini Prato G, Pagliaro U, Baldi C, Mauri M and Nieri M (2001) Coronally advanced flap procedure: is the interdental papilla a prognostic factor for root coverage? J Periodontol 72:760–6. doi: 10.1902/jop.2001.72.6.760
25. de Sanctis M and Clementini M (2014) Flap approaches in plastic periodontal and implant surgery: critical elements in design and execution. J Clin Periodontol 41 Suppl 15:S108-22. doi: 10.1111/jcpe.12189
26. Rasperini G, Codari M, Paroni L, Aslan S, Limiroli E, Solís-Moreno C, Suckiel-Papiór K, Tavelli L and Acunzo R (2020) The Influence of Gingival Phenotype on the Outcomes of Coronally Advanced Flap: A Prospective Multicenter Study. Int J Periodontics Restorative Dent 40:e27-e34. doi: 10.11607/prd.4272
27. Hwang D and Wang HL (2006) Flap thickness as a predictor of root coverage: a systematic review. J Periodontol 77:1625–34. doi: 10.1902/jop.2006.060107
28. Zuhr O, Rebele SF, Schneider D, Jung RE and Hürzeler MB (2014) Tunnel technique with connective tissue graft versus coronally advanced flap with enamel matrix derivative for root coverage: a RCT using 3D digital measuring methods. Part I. Clinical and patient-centred outcomes. J Clin Periodontol 41:582–92. doi: 10.1111/jcpe.12178
29. Azaripour A, Kissinger M, Farina VS, Van Noorden CJ, Gerhold-Ay A, Willershausen B and Cortellini P (2016) Root coverage with connective tissue graft associated with coronally advanced flap or tunnel technique: a randomized, double-blind, mono-centre clinical trial. J Clin Periodontol 43:1142–1150. doi: 10.1111/jcpe.12627
30. Mörmann W and Ciancio SG (1977) Blood supply of human gingiva following periodontal surgery. A fluorescein angiographic study. J Periodontol 48:681–92. doi: 10.1902/jop.1977.48.11.681

31. Folke LE and Stallard RE (1967) Periodontal microcirculation as revealed by plastic microspheres. J Periodontal Res 2:53–63. doi: 10.1111/j.1600-0765.1967.tb01996.x
32. Zuhr O, Rebele SF, Cheung SL and Hürzeler MB (2018) Surgery without papilla incision: tunneling flap procedures in plastic periodontal and implant surgery. Periodontol 2000 77:123–149. doi: 10.1111/prd.12214

Figures

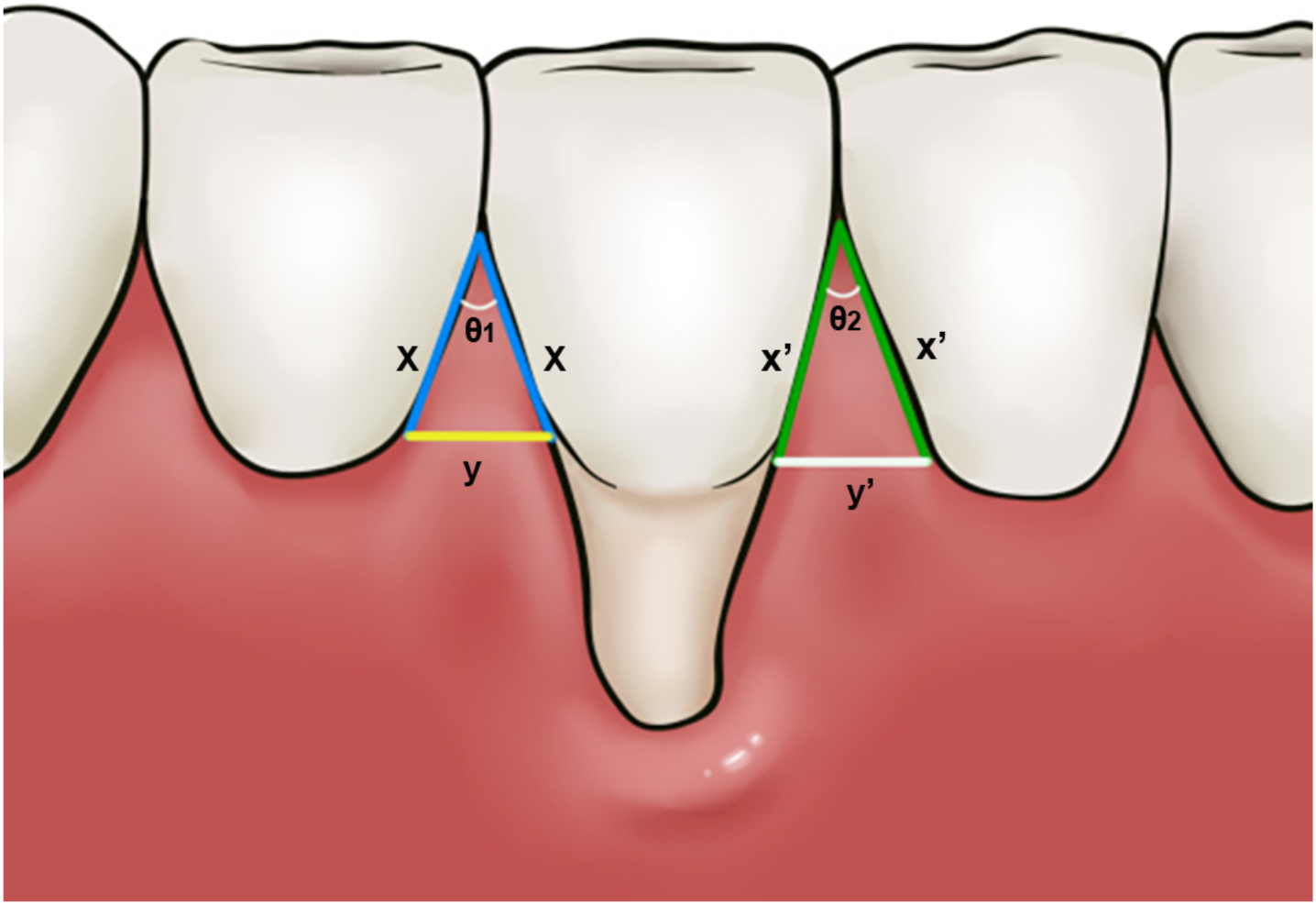

Figure 1. Schematic drawing illustrating the papilla width (PW). PW=1/2($\theta 1 + \theta 2$);

$\sin\frac{\theta}{2} = \frac{y}{2x}$

Figure 1

See image above for figure legend.

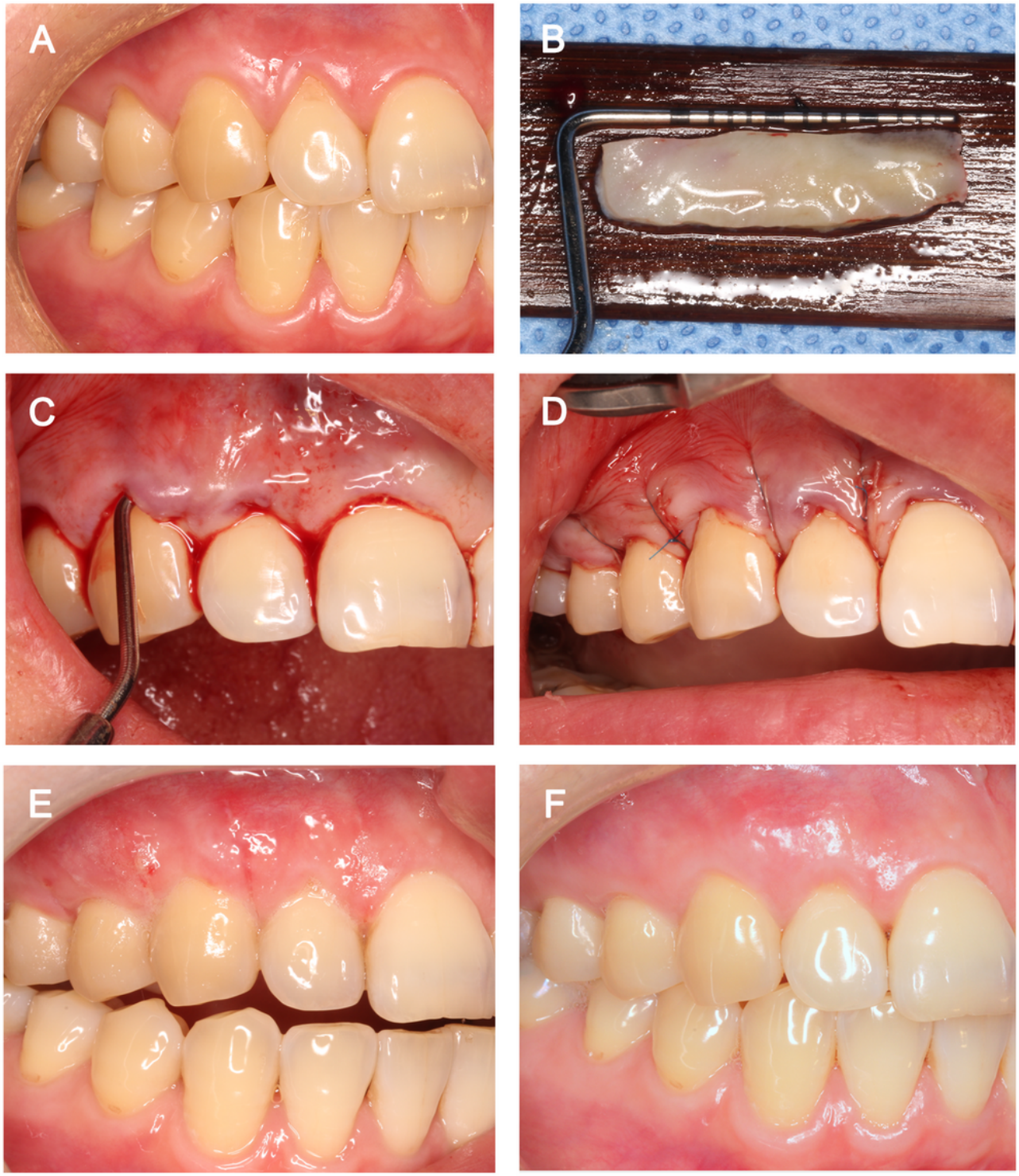

Figure 2

Surgical procedure. **A.** Gingival recession on maxillary lateral incisor and premolar. **B.** A subepithelial connective tissue graft (SCTG) was harvested. **C.** A split-full-split thickness flap elevation without any vertical incision was prepared **D.** Coronall advanced flap after sling suture. **E.** At 2 weeks post-surgery. **F.** Healing after 12 months.