

Comparative study of preoperative sagittal alignment between patients with multi-segment cervical ossification of the posterior longitudinal ligament and cervical spondylotic myelopathy

Hao Li

Qilu Hospital of Shandong University

Lianlei Wang

Qilu Hospital of Shandong University

Suomao Yuan

Qilu Hospital of Shandong University

Yonghao Tian

Qilu Hospital of Shandong University

Xinyu Liu (✉ newyuliu@163.com)

Qilu Hospital of Shandong University

Research Article

Keywords: Cervical, sagittal alignment, OPLL, CSM

Posted Date: July 6th, 2022

DOI: <https://doi.org/10.21203/rs.3.rs-1795763/v1>

License:   This work is licensed under a Creative Commons Attribution 4.0 International License.

[Read Full License](#)

Abstract

Background To compare preoperative sagittal alignment between patients with multi-segment cervical ossification of the posterior longitudinal ligament (OPLL) and multi-level cervical spondylotic myelopathy (CSM).

Methods A total of 198 patients (110 men, 78 women; mean age, 58.8 ± 10.4 years) with severe cervical spondylosis underwent surgical treatment from September 2013 to December 2021. In total, 103 patients were diagnosed with multi-segment cervical OPLL, including continuous type ($n = 31$), segmental type ($n = 31$), and mixed type ($n = 41$). The remaining 95 patients had multi-segment CSM. Several clinical variables were assessed preoperatively, including Japanese Orthopaedic Association (JOA) scores, visual analogue scale (VAS) score, number of hand actions in 10 seconds, hand-grip strength, C2–C7 Cobb angle, C2–C5 Cobb angle, C5–C7 Cobb angle, C2–C7 sagittal vertical axis, C7 slope, T1 slope, K-line, K-line tilt, and range of motion (ROM).

Results The JOA scores, number of hand actions in 10 seconds, hand-grip strength, and VAS scores were not significantly different between the two groups ($p > 0.05$). The C2–C7 and C5–C7 Cobb angles were significantly better in the OPLL group ($p < 0.05$). The CSM group had a larger ROM ($p < 0.001$). Within the OPLL group, the ROM was significantly different between the segmental type and continuous type ($p < 0.05$).

Conclusion The sagittal alignment in patients with multi-segment cervical OPLL is good. However, patients with OPLL have greater loss of ROM than those with CSM. Studying the sagittal alignment could provide a theoretical basis for preoperative decision-making.

Introduction

Degenerative cervical spondylosis and ossification of the posterior longitudinal ligament (OPLL) are the two most common causes of cervical spondylotic myelopathy (CSM), which can cause cervical spinal cord dysfunction in middle-aged and elderly patients [1, 2]. OPLL, characterized by pathological ectopic bone formation in the posterior longitudinal ligament, has been recognized as an important clinical entity that causes compressive myelopathy of the spinal cord or nerve roots [3]. It is a multi-etiological degenerative disease related to heredity and metabolism that may involve either local ossification or invasion of multi-level vertebrae, the latter of which results in the subtype known as continuous OPLL. Multi-segment cervical OPLL is generally considered to involve more than three levels of vertebral invasion.

Cervical sagittal alignment [4–6] is of great significance in the development of spinal deformities, degenerative diseases, preoperative planning, postoperative clinical evaluation, and functional recovery. Normal cervical physiological lordosis can slow down and buffer the shock of gravity, balance the stress between the anterior and posterior structures, maintain the biomechanical balance, and avoid spinal cord and nerve root compression [7]. Aging-related degeneration causes a series of unbalanced changes,

including loss of the lordosis angle, physiological curvature straightening, or kyphotic deformity [8–10]. Paying attention to patients' preoperative sagittal alignment can provide a sufficient basis for the selection and formulation of the preoperative plan and guide postoperative rehabilitation exercises. Reviewing the related literature, we found that few studies have focused on preoperative sagittal alignment in patients with multi-segment cervical OPLL. This study aims to reveal the characteristic of the sagittal alignment of patients with multi-level OPLL and provide a basis for preoperative planning.

Materials And Methods

Inclusion and exclusion criteria

The institutional review board of Qilu Hospital of Shandong University approved this study. The inclusion criteria were 3 months of ineffective conservative treatment and the presence of CSM due to either degenerative spondylosis or OPLL as confirmed by computed tomography and magnetic resonance imaging. All patients had three or more levels of stenosis. According to the OPLL types described by Izumi et al. [11], patients with continuous, segmental, and mixed OPLL types were included in the study (Fig. 1). The exclusion criteria were circumscribed OPLL; a history of cervical surgery; rheumatoid arthritis, tumors, trauma, and infection; and incomplete radiological data.

General patient information

In total, 198 patients with degenerative CSM or OPLL were included in this study from September 2013 to December 2021. Of the 198 patients, 95 had degenerative CSM (CSM group) and 103 had multi-segment OPLL (OPLL group), including continuous type (n = 31), segmental type (n = 31), and mixed type (n = 41). The CSM group comprised 56 men and 39 women with a mean age of 58.7 ± 10.9 years and disease course of 39.6 ± 59.1 months. The OPLL group comprised 59 men and 44 women with a mean age of 58.9 ± 9.9 years and disease course of 23.4 ± 41.9 months. The patients' demographic and clinical details are listed in Table 1.

Research methods and evaluation indices

Clinical symptom evaluation

The preoperative neurological function of the patients in each group was evaluated by Japanese Orthopaedic Association (JOA) scores, the number of hand actions in 10 seconds, and hand-grip strength. The visual analogue scale (VAS) score was used to evaluate neck and shoulder pain.

Radiographic evaluation

The presence and type of OPLL were evaluated by computed tomography and magnetic resonance imaging in the sagittal position. Cervical sagittal alignment was measured using the following parameters on preoperative X-rays in the standing position (Fig. 2):

C2–C7, C2–C5, and C5–C7 Cobb angle: the angle between two lines perpendicular to the endplates of the vertebrae.

C2–C7 sagittal vertical axis (SVA): the horizontal distance between the plumb line of the center of C2 and the posterior superior corner of C7.

C7 slope and T1 slope: the angle between the superior endplate and the horizontal line.

K-line tilt: the angle between the K-line and a line perpendicular to the horizon. The K-line is the line that connects the midpoints of the spinal canal at C2 and C7. OPLL does not exceed the K-line in the K-line (+) group and exceeds the K-line in the K-line (-) group.

Range of motion (ROM): sum of the C2–C7 Cobb angles in extension and flexion.

According to Toyama et al. [12], the cervical spine can be categorized as lordotic, straight, sigmoid, or kyphotic (Table 1, Fig. 3).

Lordotic type: all centroids are located in front of the posterior edge line of C2 and C7, and at least one centroid is more than 2 mm away from the line.

Straight type: the distance between the line and each centroid is less than 2 mm.

Sigmoid type: some centroids are anterior to and some posterior to the line, and at least one centroid is more than 2 mm away from the line.

Kyphotic type: all centroids are posterior to the line, and at least one centroid is more than 2 mm away from the line.

Statistical analysis

SPSS 20.0 statistical software (IBM Corp., Armonk, NY, USA) was used for the statistical analysis. In the event of statistical significance, an unpaired t-test and χ^2 test were performed. In different OPLL groups, one-way analysis of variance was performed. The significance level was set at $p < 0.05$.

Results

No significant differences in demographics were found between the two groups ($p > 0.05$) (Table 1). The cervical classification of the subtypes in the two groups is shown in Figures 4 and 5. The segments affected in the OPLL group are shown in Figure 6. There were no significant differences in the JOA scores, number of hand actions in 10 seconds, hand-grip strength, or VAS scores between the two groups ($p > 0.05$) (Table 2). With respect to the cervical sagittal alignment, the C2–C7 and C5–C7 Cobb angles were significantly better in the OPLL group ($p < 0.05$), and the CSM group had a greater ROM ($p < 0.001$) (Table 3). Within the OPLL group, the ROM was significantly different between the continuous type and segmental type ($p < 0.05$) (Table 4).

Discussion

Cervical sagittal alignment has become a focus of research in recent years. An imbalance of sagittal alignment may lead to neck pain, deterioration of neurological function, and decreased quality of life [13, 14]. Studying patients' preoperative cervical sagittal alignment can help to evaluate the severity of the disease, formulate an appropriate preoperative plan, predict the prognosis of the disease, and guide postoperative rehabilitation exercises.

The sagittal alignment changes with aging in the normal population. By stratifying asymptomatic people into different age groups, Scheer et al. [6] found that the C2–C7 Cobb angle initially decreased and then increased in people aged 20–39, 40–59, and > 60 years. They also found that the C2–C7 SVA and T1 slope were significantly different among the three age groups. These findings indicate that the sagittal alignment of the spine constantly changes throughout life, and when the spine is affected by disease (compared with normal asymptomatic individuals), it is likely to undergo further detrimental changes or even become unbalanced. Xing et al. [15] found that C2–C7 lordosis and the T1 slope decreased and that the C2–C7 SVA and neck tilt increased in patients with cervical degenerative disease. The C2–C7 Cobb angle can effectively reflect the cervical curvature. When the angle decreases, the muscles at the back of the neck become tensed and pull on bony structures, and spasms may occur in severe cases, resulting in spinal cord compression. In this study, the mean C2–C7 and C5–C7 Cobb angles in the OPLL group were $17.8^\circ \pm 8.6^\circ$ and $10.2^\circ \pm 6.3^\circ$, respectively, and were better than those in the CSM group ($15.3^\circ \pm 9.5^\circ$ and $7.8^\circ \pm 5.9^\circ$, respectively) ($p < 0.05$). These results indicate that the cervical lordosis angle is a priority in patients with OPLL, and its optimization is a prerequisite for good results of posterior surgery [16]. For patients with multi-segment OPLL, indirect decompression can be achieved by opening door through the posterior approach to make the spinal cord drift backward, and good surgical results can be obtained. This avoids the more difficult anterior surgery and associated complications.

The cervical ROM is of great significance to patients' quality of life. Fujimori et al. [17] found that the loss of ROM was significantly greater in the OPLL group than in the CSM group. Hyun et al. [18] confirmed that the preoperative ROM was smaller in the OPLL group than in the CSM group, and the decrease in the ROM after the operation was more obvious. The mean ROM of the patients with OPLL in the present study was $33.4^\circ \pm 8.0^\circ$, which was significantly lower than that of the patients with CSM ($40.5^\circ \pm 11.1^\circ$). This finding indicates that OPLL leads to a significant decrease in ROM in the process of formation and progression of ossification. Meanwhile, the ROM of the continuous, mixed, and segmental types was $29.5^\circ \pm 9.1^\circ$, $32.7^\circ \pm 7.7^\circ$, and $36.6^\circ \pm 6.6^\circ$, respectively. There was a significant difference between the continuous type and segmental type, indicating that the ROM gradually decreases as ossification progresses. Therefore, during postoperative rehabilitation exercises, the impact on ROM due to surgery should be considered in patients with OPLL. Paying attention to the preoperative ROM can provide a basis for formulation of the postoperative rehabilitation plan.

Previous studies have confirmed that the C2–C7 SVA is an important parameter with which to predict the clinical efficacy. Oe et al. [13] reported that a larger preoperative C2–C7 SVA will affect health-related

quality of life. Tang et al. [14] found that the C2–C7 SVA was positively correlated with the Neck Disability Index score and negatively correlated with the 36-item Short-Form Health Survey score. In the present study, the mean C2–C7 SVA was 21.3 ± 12.8 mm in the OPLL group and 19.4 ± 12.1 mm in the CSM group. There was no significant difference between the two groups. Sakai et al. [19] observed that the recovery of neurological function was not ideal when the preoperative C2–C7 SVA was > 40 mm. In this study, no patients in the CSM group and two patients in the OPLL group had a C2–C7 SVA of > 40 mm. Therefore, the C2–C7 SVA should be carefully evaluated during preoperative planning to obtain a better clinical efficacy.

The C7 and T1 slopes are important factors in evaluating the cervical sagittal alignment. Knott et al. [20] proposed the use of T1 slope to predict the whole sagittal alignment. Tamai et al. [21] confirmed a strong correlation between the C7 slope and T1 slope. The C7 and T1 slopes have thus become research hotspots. In the present study, the mean C7 and T1 slopes in the OPLL group were $22.1^\circ \pm 8.3^\circ$ and $25.6^\circ \pm 8.7^\circ$, respectively, and those in the CSM group were $21.7^\circ \pm 7.6^\circ$ and $25.3^\circ \pm 7.7^\circ$, respectively. There was no significant difference between the OPLL and CSM groups. Pearson correlation analysis showed a strong correlation between the C7 slope and T1 slope in the two groups (Pearson correlation coefficients for OPLL and CSM were 0.958 and 0.941, respectively). These results are consistent with previous studies, indicating that the C7 and T1 slopes are stable parameters. Kim et al. [22] found that patients with a high T1 slope (greater than an average of 26.4°) had larger cervical lordosis but more loss of lordosis after the operation. Kim et al. [23] confirmed that the improvement rate of the JOA score in patients with a high T1 slope was lower, indicating that the recovery of neurological function was worse. Therefore, for patients with a high T1 slope, the changes in postoperative cervical lordosis and the recovery of neurological function should be considered to formulate appropriate rehabilitation strategies.

Fujiyoshi et al. [24] proposed the concept of the K-line, arguing that for patients with anterior compression exceeding the K-line, posterior decompression cannot achieve adequate neurological function recovery because of insufficient spinal cord drift. This suggests that the K-line should be considered comprehensively in preoperative surgical planning for patients with OPLL, and reasonable and comprehensive imaging evaluation should be carried out to select surgical approaches that can achieve satisfactory efficacy. Kim et al. [25] studied the sagittal alignment of 50 patients with cervical spondylosis and found that the K-line tilt was correlated with the T1 slope minus C2–C7 lordosis and strongly correlated with the C2–C7 SVA. Rao et al. [26] reported that patients with a high K-line tilt (greater than an average of 14.1°) had more loss of lordosis and higher VAS scores after the operation. In the present study, the mean K-line tilt in the OPLL and CSM groups was $9.7^\circ \pm 8.2^\circ$ and $8.5^\circ \pm 6.0^\circ$, respectively. No significant difference was found between the two groups. Further studies are still needed to explore the significance of the K-line tilt in sagittal alignment.

Through clinical evaluation and examination of the sagittal alignment of patients with multi-segment OPLL, we found that multi-segment OPLL has the following four characteristics. First, multi-segment OPLL mainly involves C3–C6, and the involvement of C4 and C5 is the most common. Second, the disease course is short. The average course of OPLL in this study was 23.4 months, which was

considered to be related to the natural course of OPLL. On the one hand, the compression caused by OPLL is hard, persistent compression. Also, the range of compression caused by the ossification in the horizontal and vertical dimensions increases over time. Minor trauma or sudden irritation may significantly aggravate patients' clinical symptoms. Third, the overall lordosis angle (C2–C7 Cobb angle) and local C5–C7 Cobb angle are good; thus, posterior open-door decompression can obtain good surgical outcome. For patients with special conditions such as excessive local spinal canal invasion, cervical instability, or kyphosis, and other surgical methods such as posterior decompression fixation or posterior combined anterior surgery can be performed accordingly [27, 28]. Finally, the ROM is decreased, and early rehabilitation after surgery should be encouraged to avoid further loss of ROM.

Conclusion

Through evaluation of the neurological function and sagittal alignment of patients with multi-segment OPLL, we found that the C2–C7 and C5–C7 Cobb angles of patients with OPLL were superior to those with CSM; however, the ROM was lower, and it was lowest in patients with the continuous type of OPLL. The results of this study provide a theoretical basis for selecting a surgical plan and guiding postoperative rehabilitation.

Abbreviations

OPLL: ossification of the posterior longitudinal ligament.

CSM: cervical spondylotic myelopathy.

JOA: Japanese Orthopaedic Association.

VAS: visual analogue scale.

SVA: sagittal vertical axis.

ROM: range of motion.

Declarations

Ethics approval and consent to participate

This study was approved by the ethics committee of Qilu Hospital of Shandong University [KYLL-2021(KS)-055]. The informed consent was obtained from all subjects. All methods were carried out in accordance with relevant guidelines and regulations.

Consent for publication

Not applicable

Availability of data and materials

The datasets used and/or analysed during the current study are available from the corresponding author on reasonable request.

Competing interests

The authors declare that they have no competing interests

Funding

This work was supported in part by the National Nature Science Foundation (81874022 and 82172483 to Xinyu Liu; 82102522 to Lianlei Wang) and Shandong Natural Science Foundation (ZR202102210113 to Lianlei Wang).

Authors' contributions

HL is responsible for data collection, statistical analysis and writing the main manuscript text. LLW, SMY and YHT is responsible for statistical analysis and revising article. XYL proposed the concept and revised article finally. All authors reviewed the manuscript.

Acknowledgements

Not applicable

References

1. Klineberg E (2010). Cervical spondylotic myelopathy: a review of the evidence. *Orthop Clin North Am* 41(2):193-202.
2. Nakashima H, Tetreault L, Nagoshi N, et al (2016). Comparison of Outcomes of Surgical Treatment for Ossification of the Posterior Longitudinal Ligament Versus Other Forms of Degenerative Cervical Myelopathy: Results from the Prospective, Multicenter AOSpine CSM-International Study of 479 Patients. *J Bone Joint Surg Am* 98(5):370-378.
3. Furusawa N, Baba H, Imura S, et al (1996). Characteristics and mechanism of the ossification of posterior longitudinal ligament in the tip-toe walking Yoshimura (twy) mouse. *Eur J Histochem* 40(3):199-210.
4. Fujiwara H, Oda T, Makino T, et al (2018). Impact of Cervical Sagittal Alignment on Axial Neck Pain and Health-related Quality of Life After Cervical Laminoplasty in Patients With Cervical Spondylotic Myelopathy or Ossification of the Posterior Longitudinal Ligament: A Prospective Comparative Study[J]. *Clinical Spine Surgery* 31(4):E245-E251.
5. Protopsaltis TS, Scheer JK, Terran JS, et al (2015). How the neck affects the back: changes in regional cervical sagittal alignment correlate to HRQOL improvement in adult thoracolumbar

- deformity patients at 2-year follow-up. *J Neurosurg Spine* 23(2):153-8.
6. Scheer J K, Tang J A, Smith J S, et al (2013). Cervical spine alignment, sagittal deformity, and clinical implications: a review[J]. *Journal of Neurosurgery Spine* 19(2):141-159.
 7. Yan K, Tian W (2015). Effect of single-level Discover cervical artificial disc replacement on cervical sagittal alignment[J]. *Chinese Journal of Orthopaedics* 35(12) :1177-1183.
 8. Chen Y, Luo J, Pan Z, et al (2017). The change of cervical spine alignment along with aging in asymptomatic population: a preliminary analysis. *Eur Spine J* 26(9):2363-2371.
 9. Iyer S, Lenke LG, Nemani VM, et al (2016). Variations in Sagittal Alignment Parameters Based on Age: A Prospective Study of Asymptomatic Volunteers Using Full-Body Radiographs. *Spine (Phila Pa 1976)* 41(23):1826-1836.
 10. Yukawa Y, Kato F, Suda K, et al (2018). Normative data for parameters of sagittal spinal alignment in healthy subjects: an analysis of gender specific differences and changes with aging in 626 asymptomatic individuals. *Eur Spine J* 27(2):426-432.
 11. Izumi T, Hirano T, Watanabe K, et al (2013). Three-dimensional evaluation of volume change in ossification of the posterior longitudinal ligament of the cervical spine using computed tomography. *Eur Spine J* 22(11):2569-74.
 12. Toyama Y, Hirabayashi H, Kamata M (1997). Long-term clinical result of anterior interbody fusion for cervical spondylotic myelopathy [in Japanese]. *East Jpn J Orthop Traumatol* 9:487–92.
 13. Oe S, Togawa D, Nakai K, et al (2015). The influence of age and sex on cervical spinal alignment among volunteers aged over 50[J].*Spine (Phila Pa 1976)* 40(19):1487-1494.
 14. Tang J A, Scheer J K, Smith J S, et al (2012). The impact of standing regional cervical sagittal alignment on outcomes in posterior cervical fusion surgery.[J]. *Neurosurgery* 12(9):S65-S65
 15. Xing R, Liu W, Li X, et al (2018). Characteristics of cervical sagittal parameters in healthy cervical spine adults and patients with cervical disc degeneration[J]. *BMC Musculoskeletal Disorders* 19(1):37
 16. Aita I, Hayashi K, Wadano Y, et al (1998). Posterior movement and enlargement of the spinal cord after cervical laminoplasty[J]. *Journal of Bone & Joint Surgery British Volume* 80(1):33-7
 17. Fujimori T, Le H, Ziewacz J E, et al (2013). Is there a difference in range of motion, neck pain, and outcomes in patients with ossification of posterior longitudinal ligament versus those with cervical spondylosis, treated with plated laminoplasty?[J]. *Neurosurgical Focus* 35(1):E9
 18. Hyun SJ, Riew KD, Rhim SC (2013). Range of motion loss after cervical laminoplasty: a prospective study with minimum 5-year follow-up data. *Spine J* 13(4):384-90.
 19. Sakai K, Yoshii T, Hirai T, et al (2017). Impact of the surgical treatment for degenerative cervical myelopathy on the preoperative cervical sagittal balance: a review of prospective comparative cohort between anterior decompression with fusion and laminoplasty[J].*Eur Spine J* 26:104-112
 20. Knott PT, Mardjetko SM, Tschy F (2010). The use of the T1 sagittal angle in predicting overall sagittal balance of the spine. *Spine J* 10(11):994-8.

21. Tamai K, Buser Z, Paholpak P, et al (2018). Can C7 Slope Substitute the T1 slope?: An Analysis Using Cervical Radiographs and Kinematic MRIs. *Spine (Phila Pa 1976)* 43(7):520-525.
22. Kim T H, Lee S Y, Kim Y C, et al (2013). T1 slope as a predictor of kyphotic alignment change after laminoplasty in patients with cervical myelopathy[J]. *Spine* 38(16):E992-7
23. Kim B, Yoon D H, Ha Y, et al (2016). Relationship between T1 slope and loss of lordosis after laminoplasty in patients with cervical ossification of the posterior longitudinal ligament[J]. *Spine Journal* 16(2):219-225.
24. Fujiyoshi T, Yamazaki M, Kawabe J, et al (2008). A new concept for making decisions regarding the surgical approach for cervical ossification of the posterior longitudinal ligament: the K-line[J]. *Spine* 33(26):E990-3.
25. Kim H S, Kim T H, Park M S, et al (2018). K-line tilt as a novel radiographic parameter in cervical sagittal alignment[J]. *Eur Spine J* 27(8):2023-2028.
26. Rao H, Chen Y, Xu W, et al (2021). Clinical Effects of Preoperative K-Line Tilt on Patient Outcomes After Laminoplasty for Cervical Ossification of the Posterior Longitudinal Ligament. *World Neurosurg* 150:e639-e644.
27. Kim B, Yoon DH, Shin HC, et al (2015). Surgical outcome and prognostic factors of anterior decompression and fusion for cervical compressive myelopathy due to ossification of the posterior longitudinal ligament. *Spine J* 15(5):875-84.
28. Zhu B, Xu Y, Liu X, et al (2013). Anterior approach versus posterior approach for the treatment of multilevel cervical spondylotic myelopathy: a systemic review and meta-analysis[J]. *European Spine Journal* 22(7):1583-1593.

Tables

Table 1 The demographic and clinical details of the patients

		OPLL group	CSM group	P value
Number of patients		103	95	
Male		59	56	P 0.05
female		44	39	
Age(years)		58.9±9.9	58.7±10.9	P 0.05
course of disease		23.4±41.9	39.6±59.1	P 0.05
classification	lordosis	75	66	P=0.346
	straight	22	17	
	sigmoid	3	4	
	kyphosis	3	8	

Table 2 Comparison of the preoperative clinical symptoms of two groups.

	OPLL group	CSM group	P value
JOA score	9.4±1.8	10.2±1.9	0.425
Number of left hands action in ten seconds	10.8±3.7	11.2±2.6	0.631
Number of right hands action in ten seconds	11.1±4.3	11.7±1.8	0.552
Left hand-grip strength(kg)	16.3±7.2	16.7±3.5	0.727
Right hand-grip strength(kg)	16.6±4.8	17.2±4.9	0.569
VAS score	2.6±1.7	2.4±2.1	0.472

Table 3 Comparison of the cervical sagittal alignment of OPLL and CSM groups

	OPLL group	CSM group	P value
C2-C7 Cobb angle °	17.8±8.6	15.3±9.5	0.05*
C2-C5 Cobb angle °	8.9±6.1	8.2±6.6	0.437
C5-C7 Cobb angle °	10.2±6.3	7.8±5.9	0.006
C7 slope °	22.1±8.3	21.7±7.6	0.731
T1 slope °	25.6±8.7	25.3±7.7	0.811
K-line tilt (°)	9.7±8.2	8.5±6.0	0.253
C2-C7 SVA (mm)	21.3±12.8	19.4±12.1	0.297
ROM °	33.4±8.0	40.5±11.1	0.001**

*P 0.05 **P 0.001

Table 4 Comparison of the cervical sagittal alignment in different OPLL groups

	continuous type	segmental type	mixed type
C2-C7 Cobb angle °	16.4±9.7	18.9±8.0	17.9±8.2
C2-C5 Cobb angle °	7.8±4.2	10.8±6.6	8.2±6.7
C5-C7 Cobb angle °	10.0±8.0	8.8±4.3	11.3±6.1
C7 slope °	22.4±8.6	20.8±7.8	22.7±8.6
T1 slope °	26.6±8.9	23.4±7.8	26.6±9.1
K-line tilt (°)	9.9±5.7	9.0±7.4	10.7±9.7
C2-C7 SVA (mm)	21.0±11.9	20.5±12.4	22.2±13.9
ROM °	29.5±9.1*	36.6±6.6*	32.7±7.7

Note * indicates that the difference between the two groups is statistically significant(p 0.05)

Figures

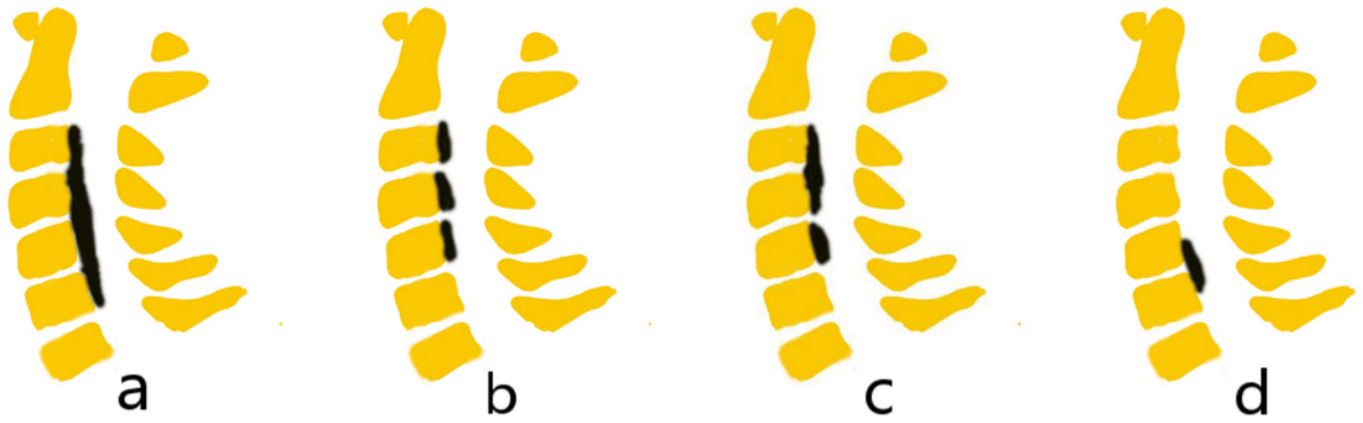


Figure 1

Types of OPLL. (a) Continuous. (b) Segmental. (c) Mixed. (d) Circumscribed.

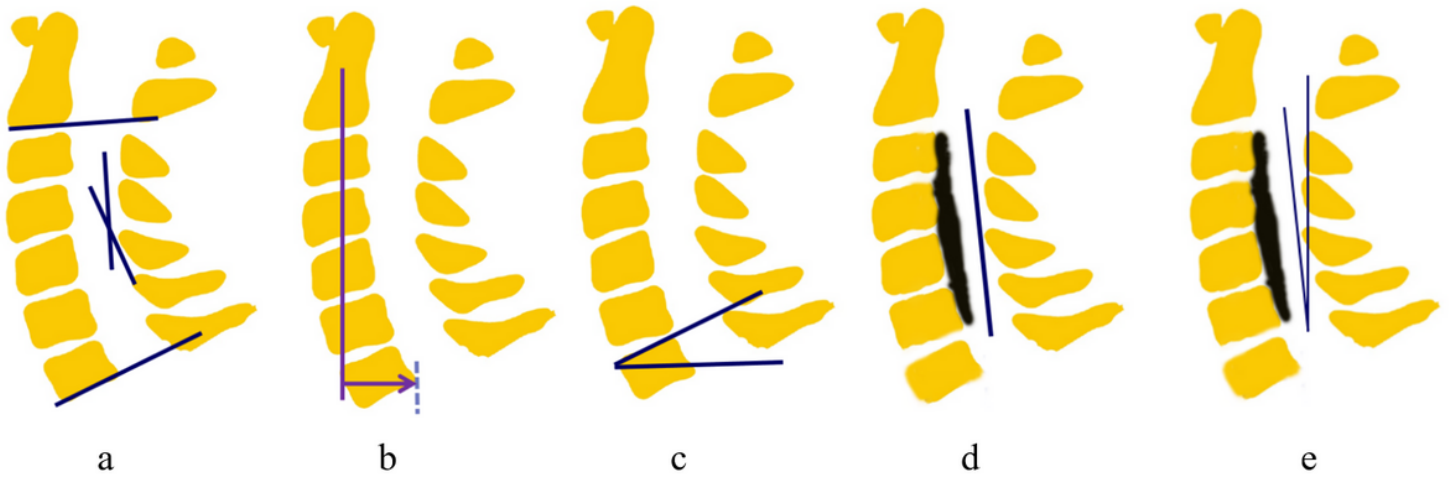


Figure 2

Cervical sagittal alignment indices. (a) Cobb angle: the angle between two lines perpendicular to the endplates of the vertebrae. ROM: sum of the C2–7 Cobb angles in extension and flexion. (b) T1 and C7 slope: the angle between the superior endplate and the horizontal line. (c) C2–C7 SVA: the horizontal distance between the plumb line of the center of C2 and the posterior superior corner of C7. (d) K-line: the line that connects the midpoints of the spinal canal at C2 and C7. OPLL does not exceed the K-line in the K-line (+) group and exceeds the K-line in the K-line (-) group. (e) K-line tilt: the angle between the K-line and a line perpendicular to the horizon.

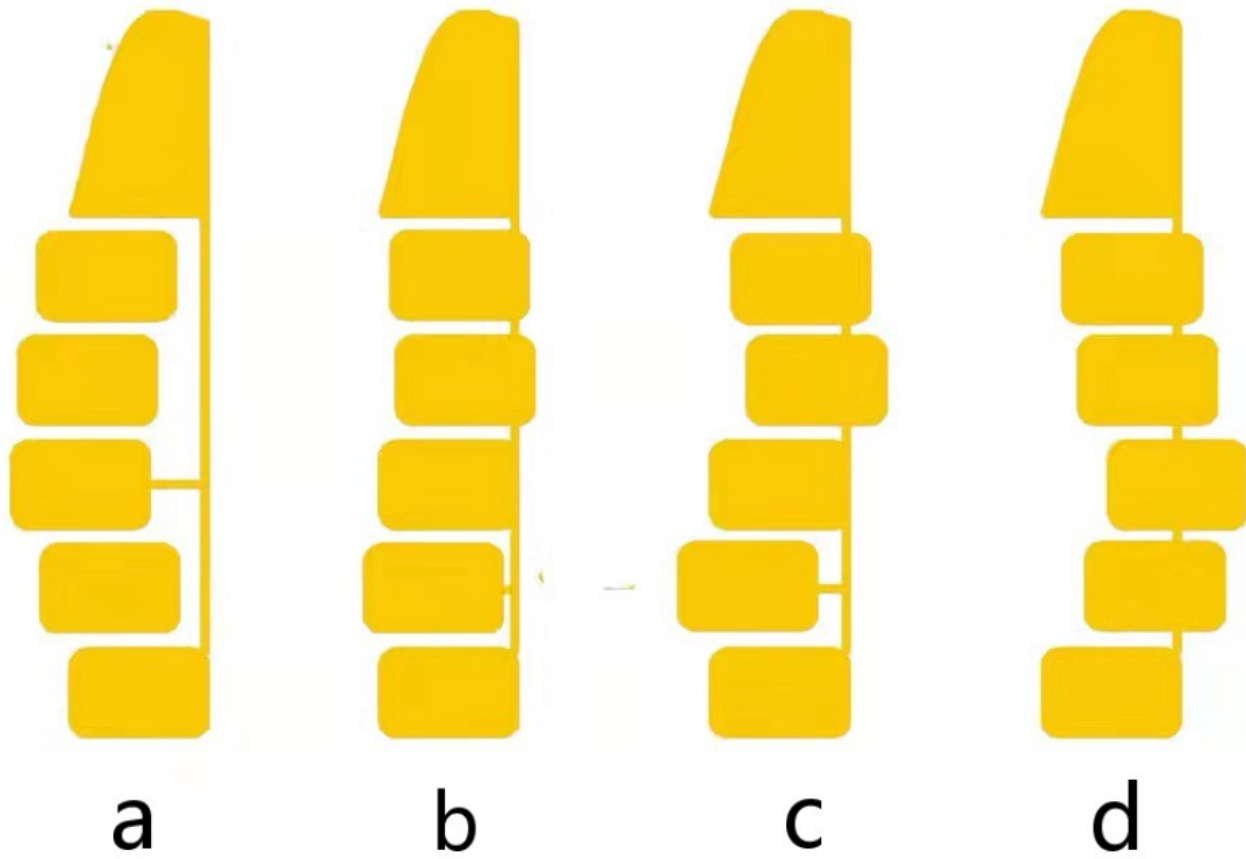


Figure 3

Cervical spine categorization. (a) Lordotic. (b) Straight. (c) Sigmoid. (d) Kyphotic.

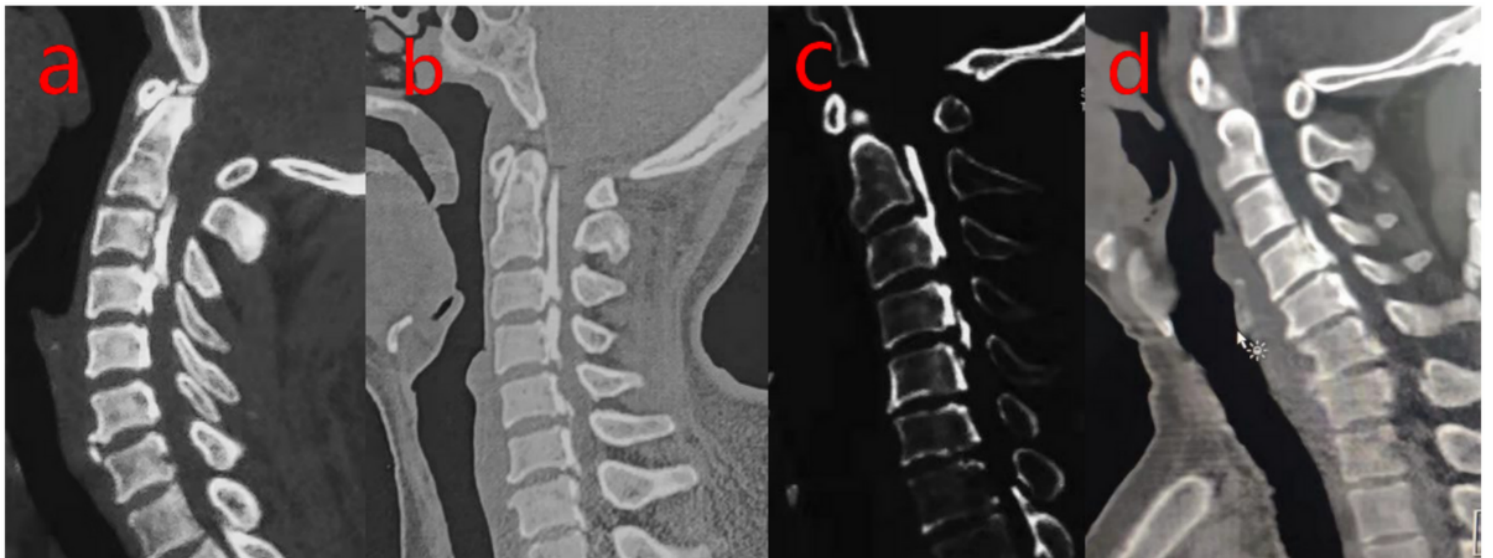


Figure 4

Subtypes in OPLL group. (a) Lordotic. (b) Straight. (c) Sigmoid. (d) Kyphotic.

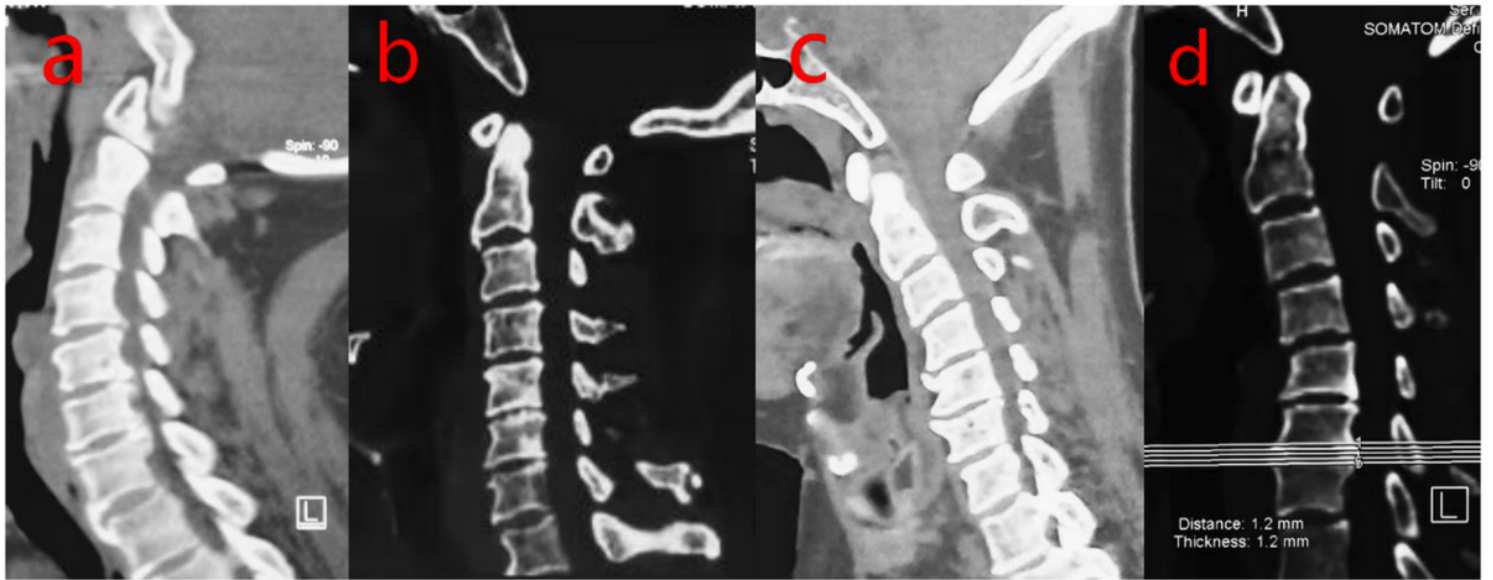


Figure 5

Subtypes in CSM group. (a) Lordotic. (b) Straight. (c) Sigmoid. (d) Kyphotic.

LESION IN THE SEGMENTS

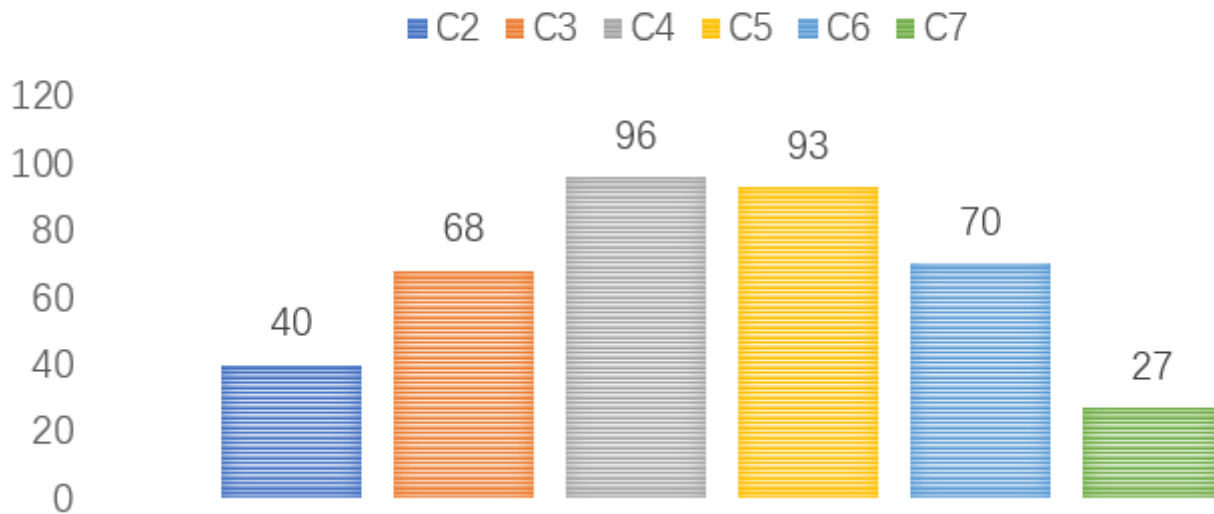


Figure 6

Segments involved in the OPLL group