The impact of cervical sagittal parameters on axial neck pain in patients with cervical kyphosis

Jia Li
Hebei Medical University Third Affiliated Hospital
Di Zhang
Hebei Medical University Third Affiliated Hospital
Yong Shen (docshenyong@163.com)
Hebei Medical University Third Affiliated Hospital

Research article

Keywords:

Posted Date: March 26th, 2020

DOI: https://doi.org/10.21203/rs.3.rs-18000/v1

Version of Record: A version of this preprint was published on September 22nd, 2020. See the published version at https://doi.org/10.1186/s13018-020-01909-x.

Abstract

Background:Cervical sagittal alignment is closely related with cervical disc degeneration and impacts the spinal function and quality of life, especially for cervical kyphosis (CK). The purpose of this study was to evaluate the influence of cervical sagittal parameters on the axial neck pain (ANP) in patients with CK.

Methods: A retrospective analysis was performed of data from 263 patients who underwent to the authors' department of this institution between January 2012 and December 2018. Radiographic evaluations were performed at authors' department, including CK types, C2-7 sagittal vertical axis (SVA), thoracic inlet angle (TIA), T1 slope, neck tilt (NT), cranial tilt and cervical tilt. Sagittal alignment of the cervical spine was classified into 2 types: global and regional type. Multivariate logistic regression analysis was performed to evaluate these parameters as the risk factors for ANP.

Results: Patients in this study were divided into 2 groups according to ANP. There were 92 patients in ANP group and 171 patients in Non-ANP group. There was no significant difference in age (P=0.196), gender (P=0.516), TIA(P=0.139), NT (P=0.676), CK types (P=0.533), cranial tilt (P=0.332), cervical tilt (P=0.585) and cervical disc degeneration (P=0.695) between the two groups. T1 slope, C2-7 SVA in the ANP group was significantly higher than in the Non-ANP group ($P < 0.05$). After multivariate logistic regression analysis, C2-7 SVA (P=0.003, OR 2.318, 95% CI 1.373-4.651) and T1 slope (P=0.028, OR 2.563, 95% CI 1.186-4.669) were the two risk factors for the ANP.

Conclusions: Based on this study, cervical sagittal parameters have a significant effect on the happening of axial neck pain in patients with CK. A higher T1 slope and larger C2-7 SVA are closely lead to the development of neck pain.

Background

Cervical sagittal imbalance is the one of the main reasons for decreased intervertebral disc height, further leads to the cervical degenerative disease[1, 2]. The misalignment exacerbates more distribution of the load on the intervertebral disc and posterior joints, accelerates the progression of spinal degenerative diseases during the range of motion. However, there is limited data exploring the relationship between cervical sagittal alignment and axial neck pain(ANP).

Sagittal alignment of the cervical spine is a complex problem. It is important to catch out the risk factors which accelerates the degeneration of the cervical spine. Patients with cervical sagittal imbalance are easier to developing ANP. It is difficult to evaluate if not classified into proper subgroups. Previous studies usually only used the Cobb angle method to make decisions on cervical sagittal alignment. However, segmental deformities could not be assessed exactly with this method[3−6]. Owing to the segmental deformity, cervical alignment is often misled by the Cobb angle method,.especially for the cervical kyphosis (CK).

Thoracic inlet angle (TIA) has been described by many researchers as important as pelvic incidence (PI). In particular, the T1 slope is considered to be a crucial parameter in the determination of cervical sagittal alignment. However, as a result of shoulder and thoracic trunk, T1 slope could not be clearly assessed sometimes[7–9]. To overcome this limitations, magnetic resonance imaging (MRI) have been used for measuring these parameters and evaluating the cervical disc degeneration. Oshina et al demonsrated the sagittal alignments in the patients with CK was similar between the standing radiographs and the supine MRI[10].

Although ANP is widely considered a multifactorial condition, to our knowledge, effect of cervical sagittal parameters for ANP have not been clearly identified, especially for the CK. Authors' hypothesized that patients with different CK types who have higher potential abilities to develop ANP. The purpose of this study was to evaluate the influence of cervical sagittal parameters on ANP in the patients with CK.

Methods

A retrospective analysis was performed of data from 263 patients with CK who visited the outpatient department of our hospital between January 2012 and December 2018. Each patient had MRI and radiograph of cervical spine. ANP was frequently complained by patients as neck pain, stiffness or dullness. Exclusion criteria were patietns with tumor, spinal infection, rheumatic disease, cervical fractures, history of cervical spine surgery and traumatic injuries. Patients without sufficient radiographic parameters were also excluded.This study was approved by Ethics Committee of the Third Hospital of Hebei Medical University in China. This study was a retrospective analysis of collected data of patients who underwent the outpatient department of our hospital. Patients' consent to review medical records was not required, as all data was de-identified. All methods were conducted in accordance with the approved guidelines.

Radiographic Evaluation

Radiographic evaluations were performed at authors' department. All radiographs were performed by two doctors without patients' information. The mean values were applied for analysis. Cervical disc degeneration was assessed as in signal intensity and/or height decreased in disc, with/without posterior disc protrusion. Cervical sagittal parameters included: T1 slope was measured the angle between a horizontal line and the upper end plate of T1; neck tilt (NT) was measured the angle between a vertical line from the sternum tip and a line connecting the center of the T1 upper end plate and the upper end of the sternum), thoracic inlet angle (TIA) was measured the angle between a perpendicular line off the T1 upper end plate and another line connecting the center of the T1 upper end plate and the upper point of the sternum, (T1 slope+NT) and C2-7sagittal vertical axis (SVA) was measured the distance from the posterosuperior corner of C7 to a vertical line from the C2 center; cranial tilt was measured an angle between the line the vertical line from the upper end plate of T1 and a line from the center of the upper end plate of T1 to the C2 center cervical tilt was measured an angle between the lines both originated

from the center of the T1 upper end plate, the vertical line and the line from the center of upper end plate of T1 to the C2 center.(Figure 1)CK was classified into two types: global and regional type.

Statistical analysis

Statistical analysis was performed using SPSS software (Version 22.0, Chicago, IL, USA). Continuous variables are shown as mean ± standard deviation. Quantitative data were analyzed using t test, and categorical data were analyzed using the chi-squared test. The relevant factors for the ANP were analyzed by a multivariate logistic regression model. In all analysis, significance was defined as p 0.05.

Results

The patient characteristics and cervical sagittal parameters between group ANP group and Non-ANP group were showed in Table 1. In total, 263 patients (120 males and 143 females) with CK were included in our study. Of these patients, 92 patients (35.0%) complained ANP (ANP group), and the other 171 patients (65.0%) did not have ANP (Non-ANP group). Comparison of the ANP group and Non-ANP group, no significant differences were found in age (P=0.196), gender (P=0.516), TIA(P=0.139), NT (P=0.676), CK types (P=0.533) cranial tilt (P=0.332), cervical tilt (P=0.585) and cervical disc degeneration (P=0.695) between the two groups. However,.the T1 slope was 26.3°±6.2° in the ANP group and 21.5°±7.6° in the Non-ANP group, with significant differences between the two group (P=0.027). In the ANP group, C2-7 SVA was 20.9±10.3mm which was larger than that in the Non-ANP group(P=0.003).

Using ANP as a dependent variable, a multivariate logistic regression for exploring the risk factors was created. With a p value < 0.2 in the univariate analysis, age, TIA, T1 slope and C2-7 SVA were analyzed as dependent variables by a forward stepwise method. The statistical results show that the C2-7 SVA (P=0.003, OR 2.318, 95% CI 1.373–4.651) and T1 slope (P=0.028, OR 2.563, 95% CI 1.186–4.669) were significant independent factors associated with ANP in participants with CK. (Table 2)

Discussion

The ideal cervical balance provides the minimal muscular energy expenditure and reduces the ANP. Regardless of whether lordosis or kyphosis, cervical sagittal alignment is important for slowing down the ANP and maintaining global sagittal balance. The sagittal imbalance is considered associated with poor quality of life. This study highlighted the relationship between ANP and cervical sagittal alignment, and demonstrated C2-7 SVA and T1 slope were significant independent factors associated with ANP in patients with CK. The results provided suggestions for the treatment strategies of CK.

It is generally acknowledged that CK could easier lead to cervical disc degeneration compared to normal sagittal alignment of the cervical spine. However, little attention has been paid to ANP [11–13]. Previous researchers proved thoracic inlet parameters correlates highly with the other cervical parameters and had a critical effect on cervical sagittal alignment [14–16]. Therefore, it is necessary to discuss the impact of thoracic inlet parameters on ANP in CK. Sun et al found patients with sagittal imbalance of TIA have

higher risk of degenerative cervical spondylotic myelopathy. When T1 slope was less than 18.5°, it showed significant diagnostic value for the incidence of degenerative cervical disease. Yet, most of the cervical curvature in their study were lordosis, CK was not included[17]. Jouibari et al had compared cervical sagittal parameters between patients with neck pain and healthy controls. In their study, T1 slope was signifcantly lower in neck pain group compared to healthy control group, but no difference in cervical lordosis between the two groups[18]. Lin et al analyzed 90 patients who underwent cervical surgery and found the larger C2-7 SVA, lower TIA, and higher NT values were independent predictors of high preoperative neck disability[19]. Therefore, it indicated that if patients with CK could keep the cervical sagittal balance, they would not suffered the neck pain. In other words, CK was a normal physiological state. This study was imilar to research of Le Huec et al. In their study, it had analyzed radiographic parameters of 106 asymptomatic participants to evaluate the sagittal balance and found almost one third of participants had CK[27].

Similar to PI, TIA is considered the constant morphologic parameter. NT was a constant parameter, A higher T1 slope means the TIA become larger. In the present study, the mean TIA of the ANP group and Non-ANP group were 73.5°±5.6° and 71.2°±7.0°, respectively. Multivariate logistic regression pointed out that TIA was not the risk factor in the development of ANP. Yet, this study showed that T1 slope were associated with ANP in patients with CK, which would help elucidate the occurrence of ANP. Therefore, in the patients with ANP, the center of gravity of the head to moved forward and aggravated the kyphosis. Furthermore, C2-7SVA was also increased.

C2-7SVA is thought to be another important indicators of cervical sagittal balance [20, 21]. It is well known that the threshold for cervical imbalance is C2-7SVA ≥ 40 mm.[22, 23]. In the present study, C2-7SVA in both groups 40 mm meaned the cervical spine was in basic equilibrium. It was insufficient to assess the cervical alignment parameters with C2-7SVA and cervical curvature alone. Previous studies has also proved the T1 slope is a parameter that represents the angle, whereas C2-7SVA represents global sagittal alignment. Hyun et al and Tang et al considered C2-7 SVA was the best indicator of cervical malalignment, which significantly impacted by the T1 slope and cervical curvature[24, 25].

The T1 slope has been the only value linking both the cervical and thoracic spine. It has closely correlation with thoracic kyphosis, TIA and C2-7 SVA[26]. A higher thoracic kyphosis often results in a higher T1 slope[21].. It has to increase the cervical lordosis to compensated. However, in patients with CK, it is completely different. Staub et al reviewed 103 adult spinal deformity patients to find the relationship between T1 slope and cervical lordosis. Then, it implied that the T1 slope minus cervical lordosis ranged form 14.5°to 26.5°could maintain the horizontal balance.[26]. In our study, the multivariate logistic regression analysis showed T1 slope was the risk factor of ANP. On account of this reason, A higher T1 slope might lead to the ANP. Our findings are similar to their results. However, cervical alignment has a C2-7 SVA in the normal range if cervical lordosis is high or the T1 slope is low. The worst mismatch is a higher T1 slope and lower cervical lordosis. Regarding to the CK, it is different compared to the cervical lordosis. When a smaller C2-7 SVA accompanied a lower T1 slope, it is easily to keep cervical sagittal

balance and achieve the posterior neck muscles compensatory mechanism, which is getting the center of head position back to the spinal axis. Otherwise, a larger C2-7 SVA with a higher T1 slope lead to cervical malalignment, which could not achieve the posterior neck muscles compensatory mechanism and eventually causes the ANP. The translational mobility of upper and middle cervical levels in regional CK type are higher than global CK type, a larger C2-7 SVA and higher T1 slope may accelerate disc degeneration at transition zone. Furthermore, the transition zone and apex of the level have the higher risk to result in ANP, especially accompanied with a larger C2-7 SVA and/or higher T1 slope. For the global CK type, the angular motion was higher at the apex of kyphosis, a larger C2-7 SVA or a higher T1 may be the reason of the ANP. From the evidence we have found so far, a smaller C2-7 SVA accompanied a lower T1 slope were tolerable with patients with CK. On the other hand, a larger C2-7 SVA with a higher T1 slope is intolerable which may lead to the ANP. Therefore, this statistical results show that larger C2-7 SVA and higher T1 slope were significant independent factors associated with ANP in patients with CK.

In addition, the posterior neck muscles also play an important role in maintaining cervical curvature. For the purpose of minimizing the energy expenditure, patients with CK require strengthening the posterior paraspinal neck muscles, especially for patients with a higher T1 slope.

In the ANP group, the mean T1 slope and C2-7 SVA in the ANP group was significantly greater than in the Non-ANP group. Theoretically, a higher T1 slope and larger C2-7 SVA might increase the risk of developing cervical sagittal imbalance in patients with CK, and eventually cause the neck pain.

Cervical alignment is a complex problem which also impacts the kinematics of the cervical spine. With regard to the CK, the sagittal alignment has different effects correlated with appearance of CK types[30]. The position of spinal cord compression is at the transition zone of the regional CK type or apex of kyphosis of the global CK type. Furthermore, the apex of regional CK type is also at high risk. Extension segmental motion of the global CK type is increased in the upper cervical spine compared to the regional CK type whose position is lordosis. It is opposite when cervical spine is flexion. Nevertheless, multivariate logistic regression showed different CK types was not the risk factor for the ANP, in spite of disc degeneration caused by abnormal kinematics. Previous studies demonstrated almost 20% asymptomatic individuals have cervical disc degeneration[28, 29]. Therefore, similar to their study, disc degenration was also found in Non-ANP group.

Limitation

However, there are a few limitations in this study. Firstly, there is lack of the global spinal sagittal radiographs to estimate the mutual effect of the lumbar and thoracic spine and CK; second, the kinematic MRI is a better method compared to supine MRI in the assessment of cervical instability and degeneration; thirdly, owing to this retrospective study, it is difficult to control for the many variables inherent in the patients; forth, there is really small sample size in patients with CK. The long-term and large scale studies should be performed to define the relationship between CK and ANP. In the future study, we can explore the correlation global spinal balance and the development of ANP.

Conclusions

Based on this study, cervical sagittal parameters have a significant effect on the happening of axial neck pain in patients with cervical kyphosis. A higher T1 slope and larger C2-7 SVA are closely lead to the development of neck pain.

Abbreviations

Axial neck pain
ANP
CK
cervical kyphosis
TIA
thoracic inlet angle
PI
pelvic incidence
MRI
magnetic resonance imaging
NT
neck tilt
C2-7SVA
C2-7sagittal vertical axis

Declarations

Acknowledgements

Not applicable.

Authors' contributions

JL carried out the manuscript preparation and experimental design,

DZ conducted patient visits and statistical analysis of the data. JL and DZ carried out the statistical analysis of the data.YS revised the manuscript critically for important intellectual content and gave final approval of the version to be published.All authors read and approved the final version of this manuscript.

Authors' information

[1]Department of Orthopedic Surgery, Third Hospital of Hebei Medical University;[2]The Key Laboratory of Orthopedic Biomechanics of Hebei Province, 139 Ziqiang Road, Shijiazhuang 050051, China.

Funding

There was no direct funding source aligned to this study.

Availability of data and materials

Not applicable.

Ethics approval and consent to participate

This study was a retrospective analysis of collected data of patients who underwent the outpatient department of our hospital. Patients' consent to review medical records was not required, as all data was de-identified. All methods were conducted in accordance with the approved guidelines. .

Consent for publication

Not applicable.

Competing interests

This material has not been published and is not under consideration elsewhere. The authors declare that they have no competing interests.

Acknowledgements

We thank Dr. Yingze Zhang for his support in obtaining the approval of the ethics committee for this study.

References

1. Nicholson KJ, Millhouse PW, Pflug E et al. Cervical Sagittal Range of Motion as a Predictor of Symptom Severity in Cervical Spondylotic Myelopathy.Spine (Phila Pa 1976). 2018;43(13):883-889.
2. Liu S, Lafage R, Smith JS, et al. Impact of dynamic alignment, motion, and center of rotation on myelopathy grade and regional disability in cervical spondylotic myelopathy. J Neurosurg Spine. 2015;23(6):690–700.
3. Zhang L, Zeitoun D, Rangel A, et al. Preoperative evaluation of the cervical spondylotic myelopathy with flexion-extension magnetic resonance imaging: about a prospective study of fifty patients. Spine 2011;36:1134–9.
4. Hardacker JW, Shuford RF, Capicotto PN, et al. Radiographic standing cervical segmental alignment in adult volunteers without neck symptoms. Spine (Phila Pa 1976) 1997;22:1472–80.
5. Schuller S, Charles YP, Steib JP. Sagittal spinopelvic alignment and body mass index in patients with degenerative spondylolisthesis. Eur Spine J 2011;20:713–9.

6. Kim SW, Jang SB, Lee HM, et al. Analysis of Cervical Spine Alignment and its Relationship with Other Spinopelvic Parameters After Laminoplasty in Patients with Degenerative Cervical Myelopathy.J Clin Med. 2020;9(3). pii: E713.
7. Kong C, Li XY, Sun XY, et al.The ratio of C2-C7 Cobb angle to T1 slope is an effective parameter for the selection of posterior surgical approach for patients with multisegmental cervical spondylotic myelopathy.JJ Orthop Sci. 2020 Jan 9. pii: S0949-2658(19)30378-1.
8. Rydman E, Elkan P, Eneqvist T,et al. The significance of cervical sagittal alignment for nonrecovery after whiplash injury.Spine J. 2020 Feb 10. pii: S1529-9430(20)30049-8.
9. Ninomiya K, Shiraishi T, Aoyama R, et al.Analysis of the impact of spinopelvic radiographic parameters on the severity of cervical spondylotic myelopathy.J Orthop Sci. 2020 Feb 13. pii: S0949-2658(20)30012-9.
10. Oshina M, Tanaka M, Oshima Y, et al.Correlation and differences in cervical sagittal alignment parameters between cervical radiographs and magnetic resonance images.Eur Spine J. 2018;27(6):1408-1415.
11. Aykac B, Ayhan S, Yuksel S, et al. Sagittal alignment of cervical spine in adult idiopathic scoliosis. Eur Spine J 2015;24:1175–82.
12. Iyer S, Nemani VM, Nguyen J, et al. Impact of cervical sagittal alignment parameters on neck disability. Spine (Phila Pa 1976) 2016;41:371–7.
13. Matsubayashi Y , Chikuda H , Oshima Y, et al. C7 sagittal vertical axis is the determinant of the C5–C7 angle in cervical sagittal alignment. Spine J 2017;17:622-6
14. Li W, Li F, Yang X, et al. Magnetic Resonance Imaging Research of Thoracic Inlet Parameters in the Cervical and Cervicothoracic Spine in Degenerative Cervical Spondylosis.World Neurosurg. 2020 Jan 17. pii: S1878-8750(20)30097-8.
15. Tamai K, Grisdela P Jr, Romanu J, et al.The Impact of Cervical Spinal Muscle Degeneration on Cervical Sagittal Balance and Spinal Degenerative Disorders.Clin Spine Surg. 2019 May;32(4):E206-E213.
16. Shao ZX, Yan YZ, Pan XX, et al.Factors Associated with Cervical Spine Alignment in an Asymptomatic Population: A Preliminary Analysis.World Neurosurg. 2019 Feb;122:e48-e58.
17. Sun J, Zhao HW, Wang JJ, et al.Diagnostic Value of T1 Slope in Degenerative Cervical Spondylotic Myelopathy.Med Sci Monit. 2018;24:791-796.
18. Jouibari MF, Le Huec JC, Ranjbar Hameghavandi MH, et al. Comparison of cervical sagittal parameters among patients with neck pain and healthy controls: a comparative cross-sectional study.Eur Spine J. 2019;28(10):2319-2324.
19. Lin T, Chen P, Wang Z, et al. Does Cervical Sagittal Balance Affect the Preoperative Neck Disability Index in Patients With Cervical Myelopathy?Clin Spine Surg. 2020;33(1):E21-E25.
20. Tamai K, Romanu J, Grisdela P Jr., et al. Small C7-T1 lordotic angle and muscle degeneration at C7 level were independent radiological characteristics of patients with cervical imbalance: a propensity score-matched analysis. Spine J. 2018 Jan 31. pii: S1529-9430(18)30015-9

21. Hyun SJ, Kim KJ, Jahng TA, et al. Relationship between T1 slope and cervical alignment following multi-level posterior cervical fusion surgery: Impact of T1 slope minus cervical lordosis. Spine (Phila Pa 1976) 2016;41:E396-402.
22. Patwardhan AG, Khayatzadeh S, Havey RM, et al.Cervical sagittal balance: a biomechanical perspective can help clinical practice.Eur Spine J. 2018;27(Suppl 1):25-38.
23. Siasios I, Winograd E, Khan A, et al. Cervical sagittal balance parameters after single-level anterior cervical discectomy and fusion: Correlations with clinical and functional outcomes.J Craniovertebr Junction Spine. 2018 Jan-Mar;9(1):56-62.
24. Hyun SJ, Kim KJ, Jahng TA, et al. Relationship between T1 slope and cervical alignment following multi-level posterior cervical fusion surgery: Impact of T1 slope minus cervical lordosis. Spine (Phila Pa 1976) 2016;41:E396–402.
25. Tang JA, Scheer JK, Smith JS, et al. The impact of standing regional cervical sagittal alignment on outcomes in posterior cervical fusion surgery. Neurosurgery 2015;76:S14–21
26. Staub BN, Lafage R, Kim HJ, et al.Cervical mismatch: the normative value of T1 slope minus cervical lordosis and its ability to predict ideal cervical lordosis.J Neurosurg Spine. 2018;30(1):31-37.
27. Le Huec JC, Demezon H, Aunoble S.Sagittal parameters of global cervical balance using EOS imaging: normative values from a prospective cohort of asymptomatic volunteers.Eur Spine J. 2015;24(1):63-71.
28. Xing R, Liu W, Li X, et al. Characteristics of cervical sagittal parameters in healthy cervical spine adults and patients with cervical disc degeneration. BMC Musculoskelet Disord. 2018;19:37
29. Kwon WK, Kim PS, Ahn SY, et al. Analysis of Associating Factors With C2-7 Sagittal Vertical Axis After Two-level Anterior Cervical Fusion: Comparison Between Plate Augmentation and Stand-alone Cages. Spine (Phila Pa 1976). 2017;42:318-25.
30. Ruangchainikom M, Daubs MD, Suzuki A, et al. Effect of cervical kyphotic deformity type on the motion characteristics and dynamic spinal cord compression. Spine (Phila Pa 1976). 2014; 39:932-8.

Tables

Table 1 Demographic characteristics and radiological data between Degeneration and Non-degeneration groups

	ANP group	Non- ANP group	P value
Age	43.5±12.9	40.8 ± 13.6	0.196
Gender (M/F)	39/53	81/90	0.516
CK types			0.533
Global type	61	77	
Regional type	50	75	
Cervical disc degeneration			0.695
yes	39	68	
no	53	103	
C2-7 SVA	20.9±10.3	13.3±7.5	0.003
T1 slope	26.3±6.2	21.5±7.6	0.027
NT	47.1±5.1	49.6±6.8	0.676
TIA	73.5±5.6	70.2±7.0	0.139
Cranial tilt	5.2±6.5	4.91±7.11	0.332
Cervical tilt	17.3±15.3	18.7±16.3	0.585

Table 2 Risk factors for cervical disc degeneration: multiple logistic regression analysis

Risk factor	P	OR	95%CI
Age	0.175	1.539	0.963–2.661
C2–7 SVA	0.003	2.318	1.373–4.651
T1 slope	0.028	2.563	1.186–4.669
TIA	0.221	1.373	0.834–2.259

Figures

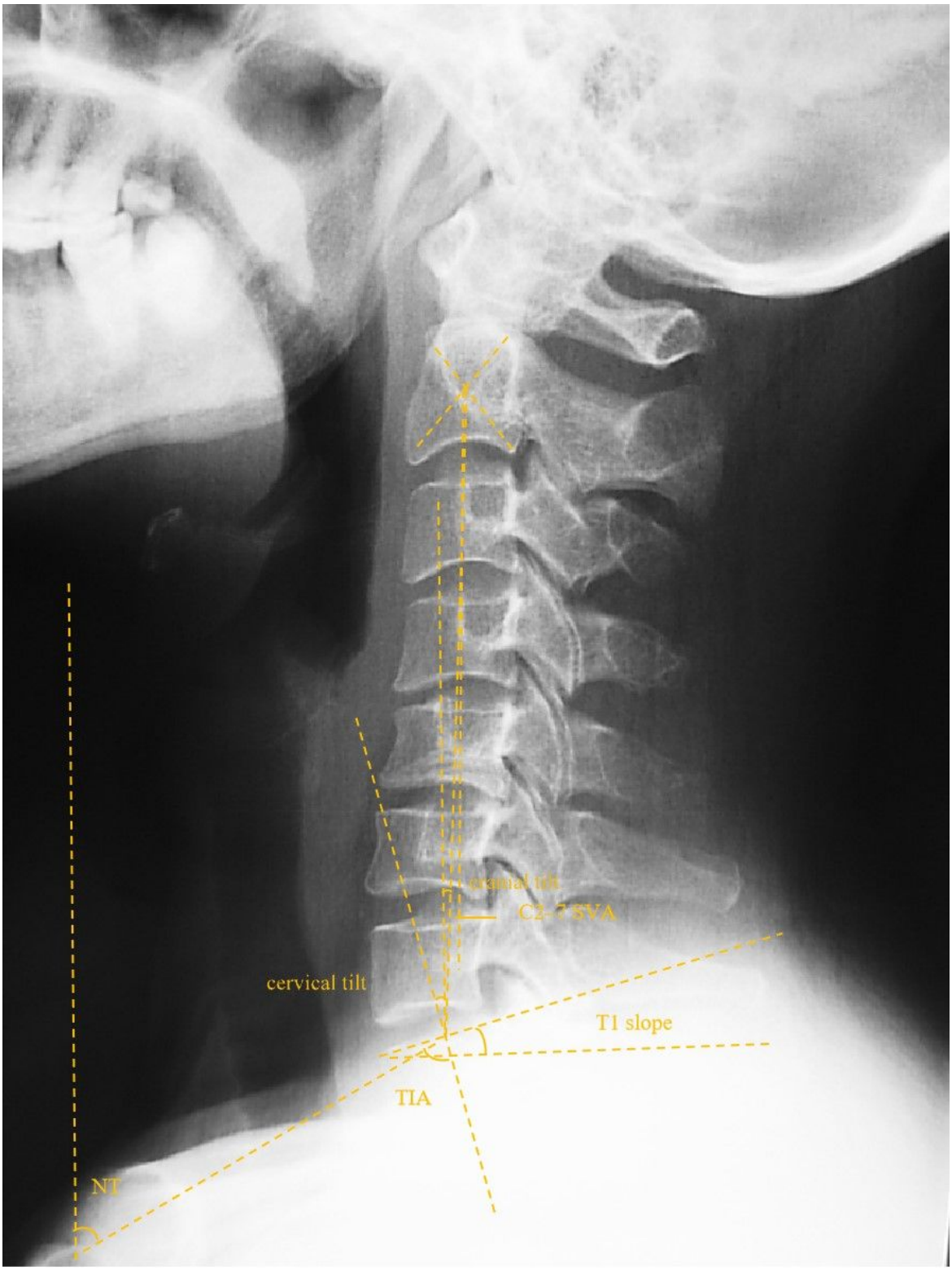

Figure 1

T1 slope: the angle between a horizontal line and the upper end plate of T1. NT: the angle formed by a vertical line from the sternum tip and a line connecting the center of the T1 upper end plate and the upper end of the sternum. TIA: the angle formed by a perpendicular line off the T1 upper end plate and another line connecting the center of the T1 upper end plate and the upper point of the sternum. C2-7 SVA: the distance from the posterosuperior corner of C7 to a vertical line from the center of the C2 vertebra. Cranial

tilt: angle between the line the vertical line from the upper end plate of T1 and a line from the center of the upper end plate of T1 to the C2 center Cervical tilt: angle between the lines both originated from the center of the T1 upper end plate, the vertical line and the line from the center of upper end plate of T1 to the C2 center

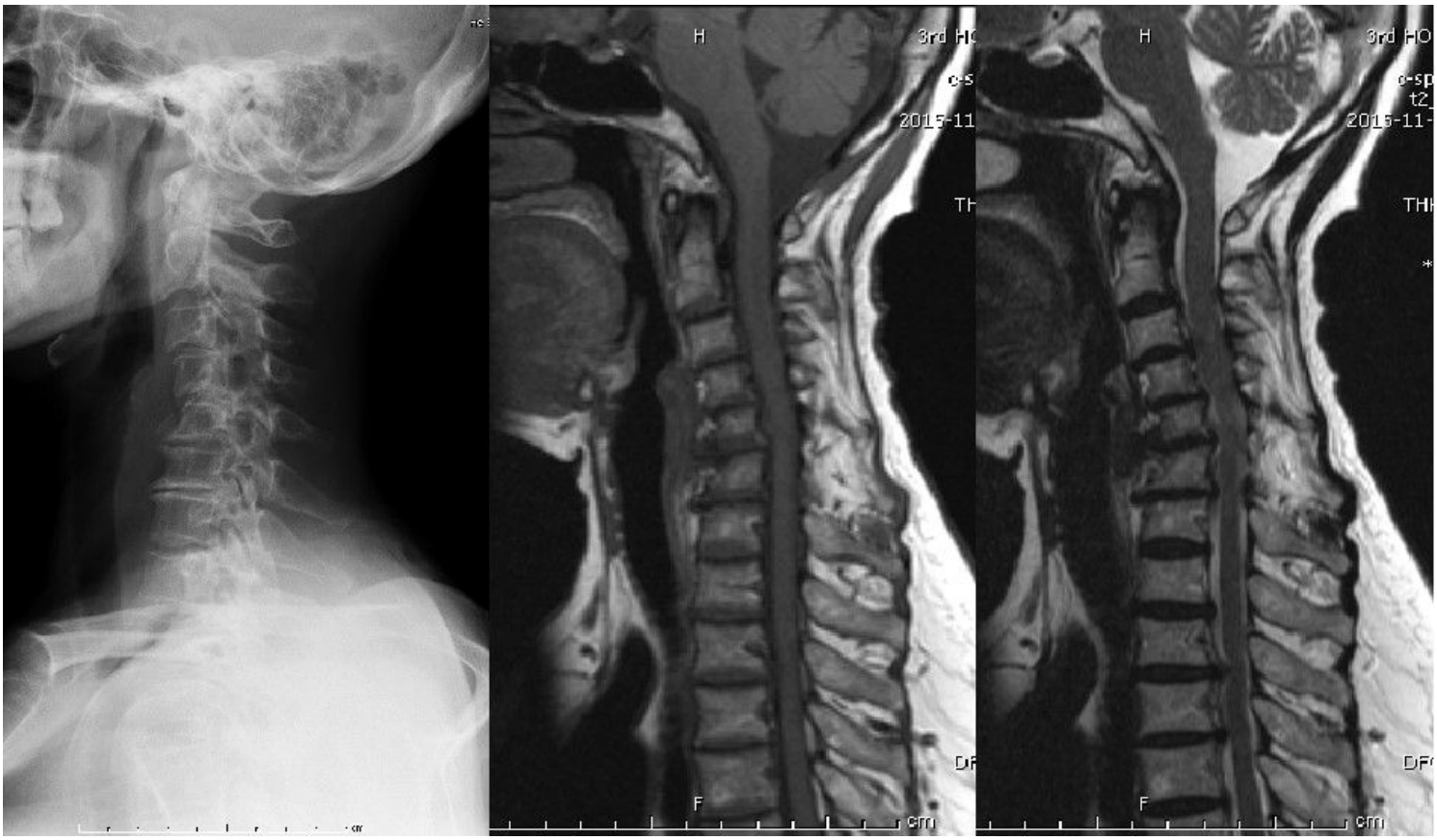

Figure 2

Global type: All the centroids areposterior to the C2–C7 centroid line and the distance between at least 1 centroid and the line is 2 mm or more.

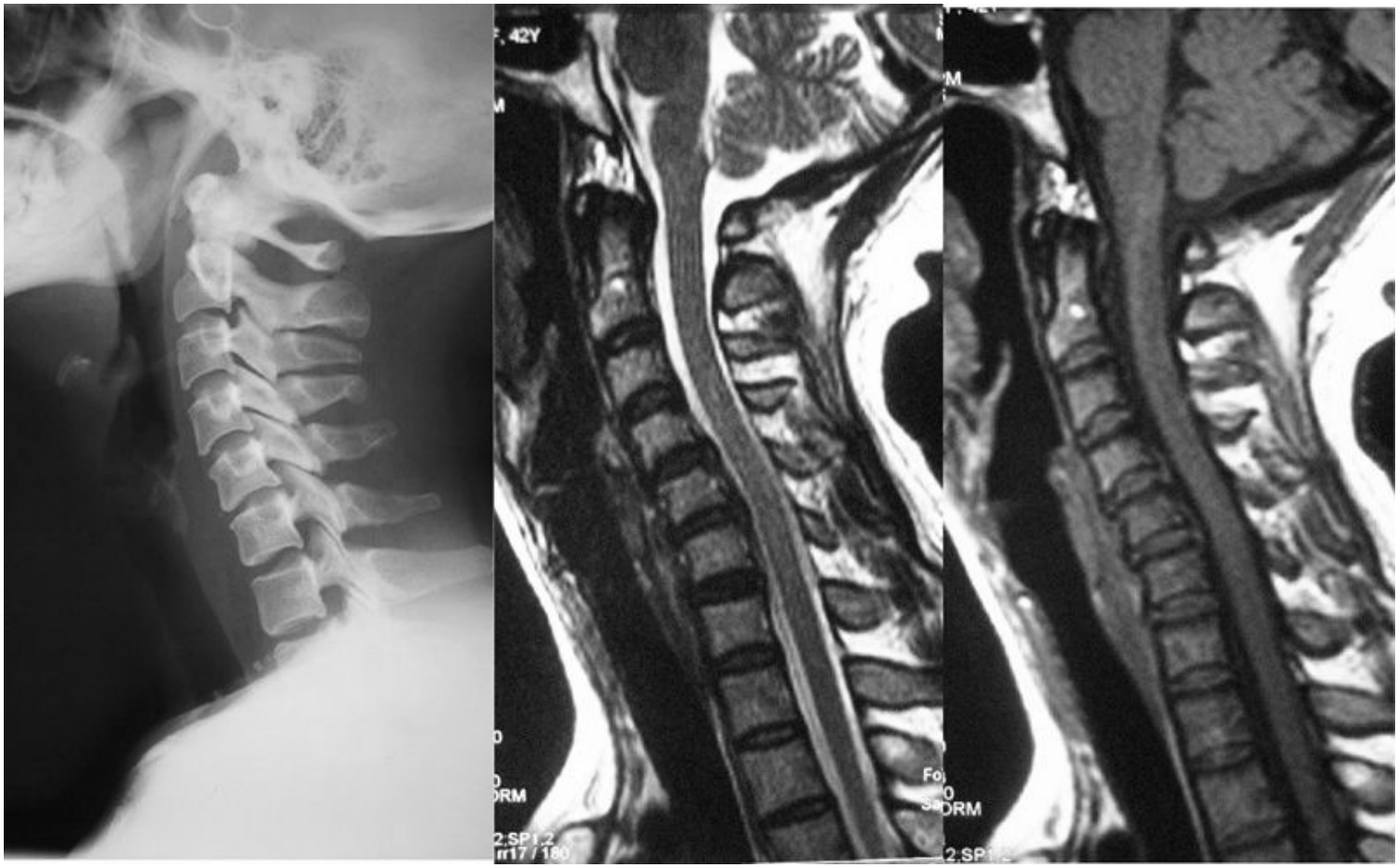

Figure 3

regional type I:At least 1 of the upper cervical centroids is anterior to and at least 1 of the lower cervical centroids is posterior to the C2–C7 centroid line, and the distance between the C2–C7 centroid line and at least 1 centroid is 2 mm or more.

Figure 4

Regional type II: At least 1 of the upper cervical centroids is posterior to and at least 1 of the lower cervical centroids is anterior to the C2–C7 centroid line, and the distance between the C2–C7 centroid line and at least 1 centroid is 2 mm or more.