Clinical characteristics of 10 children with COVID-19 outside of Wuhan in Hubei Province

Ming Chen
Xiangyang Central Hospital
Panpan Fan
Wuhan University Zhongnan Hospital
Zhi Liu
Wuhan University Zhongnan Hospital
Junhua Li
Xiangyang Central Hospital
Shaowu Huang
Xiangyang Central Hospital
Wanwan Wu
Xiangyang Central Hospital
Rui Pan
Xiangyang Central Hospital
Dongchi Zhao (zhao_wh2004@hotmail.com)
Wuhan University Zhongnan Hospital https://orcid.org/0000-0002-9454-6041

Research article

Keywords: COVID-19, SARS-CoV-2, Pediatric patients, clinical characteristics, ACE2

Posted Date: March 27th, 2020

DOI: https://doi.org/10.21203/rs.3.rs-18255/v1

Abstract

Background: An outbreak of coronavirus disease 2019 (COVID-19) caused by the Severe Acute Respiratory Syndrome Coronavirus 2 (SARS-CoV-2) began in Wuhan, Hubei Province, China in December 2019. This study aims to report the clinical characteristics of children COVID-19 in Xiangyang, a city outside of Wuhan within Hubei Province.

Methods: We retrospectively investigated the clinical manifestations, Chest CT imaging, and laboratory characteristics of confirmed cases of children with COVID-19 with WHO interim guidance in Xiangyang Central Hospital from Feb 1 to Mar 10, 2020. 10 children cases were confirmed by real-time RT-PCR, and were analyzed for epidemiological, demographic, clinical, radiological features and laboratory data. Outcomes were followed up until Mar 10, 2020.

Results: 6 cases (60%) had never been to Wuhan but closely contacted with family members with confirmed COVID-19, and 4 cases (40%) had made short term trips to Wuhan alone without familial cluster. Most common symptoms was cough (50%) followed by fever (40%), 4 cases (40%) showed asymptomatic characteristics including 2 cases (20%) with abnormal chest CT imag e . 9 cases (90%) were mild type, only 1 case (10%) was moderate type, none of them progressed in severe or critically disease. 4 (40%) cases showed leucopenia but nonelymphopenia. Abnormalities on chest computed tomograms (CT) were detected among 8 cases (80%), 2 of 4 cases without obvious symptoms had abnormal chest CT.

Conclusions: Children's infection is mainly caused by family clusters, and COVID-19 seems less likely to spread from children to adults.The clinical manifestations in children with COVID-19 are non-specific with milder symptoms and good outcomes.

Background

Since late December, 2019, an outbreak of Coronavirus disease 2019 (COVID-19)[1] was reported in Wuhan, China, which has subsequently spread worldwide[2]. As of March 10, 2020, there were 80,924 reported cases in China and 32,778 cases out of China, including more than 800 children cases. There have been 4012 deaths worldwide[3], and no deaths have been reported in children cases.

Given the rapid spread of COVID-19, we determined that an updated analysis of cases in children in other city around Wuhan within Hubei province, which might help identify the defining transmission dynamica, clinical characteristics and severity of the disease in children. Here, we describe the results of the clinical characteristics of COVID-19 in 10 children cases in Xiangyang,China.

Methods

Patients And Date Collection

All enrolled 10 pediatric patients identified to be viral nucleic acid-detection for SARS-CoV-2, who were referred to the Xiangyang Central Hospital from Feb 1 to Mar 10, 2020, were retrospectively analyzed. The clinical outcomes (ie, discharges, mortality, length of stay) were monitored up to Mar 10, 2020, the final date of follow-up.Epidemiological, clinical, laboratory, and radiological characteristics, as well as the treatment and outcomes data were obtained with collection forms from electronic medical records.

Inclusion Criteria

According to “Diagnosis and treatment protocol for COVID-19 (Seventh Trial Edition)” by the National Health Commission of the People's Republic of China, cases in this study were defined as individuals with epidemiological history and two or more persistent clinical manifestations followed by pathogenic evidence[4].The details are as follows:

1. Epidemiological history: (1)There were tourism or residence histories of Wuhan or its surrounding areas or other communities with confirmed cases within 14 days before onset ; (2) There were contacts with confirmed cases of COVID-19 within 14 days before onset; (3) There were contacts with patients with fever or respiratory symptoms from Wuhan and surrounding areas or other communities with confirmed cases within 14 days before onset; (4) Aggregation: Two or more cases with fever and/or respiratory symptoms were found in an enclosed environment (such as a family house,an office, a class, etc.) within 14 days.
2. Clinical manifestations: (1) Fever and/or respiratory symptoms; (2) Chest imaging indicated multiple mottling and interstitial changes during the early stage, mostly at the periphery of the lung, which subsquently developed into bilateral ground-glass opacity, infiltrates shadows and even lung consolidation.Pleural effusion was rarely seen; (3) Normal or decreased total white blood cell count and lymphocyte count in the early stages of the disease.
3. Etiology evidences: Quantitative real-time PCR(qRT-PCR) was performed to detect viral nucleic acid of nasopharyngeal swab samples. Nasopharyngeal swabs were detected immediately after admission, and COVID-19 was identified by qRT-PCR assay using a 2019-nCoV nucleic acid detection kit according to the manufacturer’s protocol (Bioperfectus technologies,Jiangsu,China). qRT-PCR assay was performed under the following conditions: incubation at 50℃for 30 minutes and 95℃for 5 minutes, 45 cycles of denaturation at 95℃for 10 seconds, and extending and collecting fluorescence signal at 55 ℃ for 40 seconds. A cycle threshold value (Ct-value) less than 35 was defined as a positive test result, and a Ct-value of 38 or more was defined as a negative test. A medium load, defined as a Ct-value from 35 to less than 38, required confirmation by retesting.

Ethics Approval

This study was approved by the Medical Ethical Committee of Zhongnan Hospital of Wuhan University (clinical ethical approval number 2020004) and informed consents of specimen's collection was waived.

Results

The 10 cases were identified between Jan 31, 2020, and Feb 18, 2020. 7 patients were female. They range in age from 2 to 15 years old(Table 1). All the 10 pediatric patients were native residents in Xiangyang about 350 kilometers away from Wuhan.

Table 1
Demographics, baseline characteristics, and epidemiological history of 10 hospitalized children with COVID-19

	Patients								
Characteristic	1	2	3	4	5	6	7	8	9
Demographics									
Sex	Female	Male	Female	Male	Female	Male	Male	Female	Male
Epidemiologic history									
No. of family members infected	2	2	2	2	1	1	0	0	0
Linkage to Wuhan	No	No	No	No	No	No	Yes	Yes	No
Clinical manifestation									
Symptoms and signs	Fever,cough	Fever	None	None	None	None	Cough	Fever,cough, expectoration	Cough
Severe complications	None	None	None	None	None	None	None	None	None
Treatment and prognosis									
Duration of hospitalization	22	17	14	19	21	16	12	7	26
Intensive unit care	No	No	No	No	No	No	No	No	No
Oxygen therapy	Non-invasive	None	None	None	None	None	None	None	None
Antiviral drugs	Lopinavir/Ritonavir	Lopinavir/Ritonavir	Arbidol	Arbidol	Arbidol	Oseltamivir	Oseltamivir	Lopinavir/ Ritonavir	Lopinavir/Rito
Antibiotic	None	None	None	None	None	None	None	None	None
Traditional Chinese medicine	Yes	Yes	None	Yes	Yes	None	None	Yes	Yes

The Disease Timeline Of Each Child

Of the 10 cases, 6 cases (Case1-Case6) had never been to Wuhan but closely contacted with family members with confirmed COVID-19, the incubation period of each child after the first confirmed COVID-19 in the family developed symptoms were 4–13 days(Fig. 1). Four cases (Case7-Case10) had made short term trips to Wuhan or visited relatives with confirmed COVID-19 alone, and they started to show symptoms 3–10 days after they went back home.

The 4 children had been living with their families throughout the whole course of the disease, including elderly grandparents,but no familial members else had been infected(confirmed by nucleic acid test and chest CT).(Table 1).Admittedly, the 6 cases with family cluster demonstrated adult-to-child transmission, however, the other 4 children did not show the viral transmission to long-time closely contacted adults households including elderly people, seems implied that SARS-CoV-2 did not tend to spread from children to adults.

Clinical Characteristics

In term of clinical classification, 9 cases were mild (5) or asymptomatic (4), only 1 case with moderate sign, none of them progressed in severe critically illness. The most common symptoms were cough (5,50%) and fever (4,40%) respectively. Myalgia, fatigue,headache, diarrhea or other symptoms had not been found in the 10 cases. Among the 6 cases who had symptoms, 4 cases got rid of the symptoms within 1 week, the duration of symptoms lasted for 2-15days.

Laboratory Results And Radiologic Findings

On admission, the blood routine test of 4 patients(40%) showed leucopenia (Leucocytes count < 5 × 10^9/L), none had lymphopenia (lymphocyte count < 1.1 × 10^9/L). Paradoxically, 8 cases (80%) showed relatively higher lymphocyte percent, which were not consistent with previous reports. All the 10 cases had normal serum levels of procalcitonin (PCT, < 0.5 ng/mL), and only 1 case had elevated C-reactive protein (CRP) (Table 2). None of the 10 cases showed abnormal liver and kidney function and electrolytes (date not shown).

Table 2
Laboratory results and radiologic findings of 10 hospitalized children with COVID-19

	Patients									
Parameter	1	2	3	4	5	6	7	8	9	10
Blood routine										
Neutrophils (%)	53	60	44.1↓	43.7↓	38.2↓	54.2	65.6	50.7	38.6↓	55.6
Neutrophils (× 10^9/L)	3.35↓	2.32↓	4.15↓	5.4	7.74	6.84	7.19	5.36	4.97↓	5.25
Lymphocytes(%)	32.7	32	41.7↑	37	52.6↑	31.5	19.2	37.4	47.1↑	30.8
Lymphocytes(× 10^9/L)	1.78	1.39	1.83	2.36	2.96	3.71↑	4.72↑	2.27	1.92	2.92
Infectious biomarkers										
C-reactive protein(mg/L)	4.49	5	3	4	3	3	5.5↑	3.5	3.5	33.4
Procalcitonin(ng/mL)	0.02	0.03	0.04	0.03	0.02	0.03	0.03	0.04	0.03	0.05
Nucleic acid tests										
Positive times/ Total Times	4/6	3/5	4/6	5/7	4/6	5/7	2/4	1/3	4/6	1/3
Negative conversion days	20	16	10	18	21	16	7	5	22	6
CT imaging										
On admission	Single high density shadow	Single high density shadow	Normal	Single high density shadow	Ground-glass opacity	Normal	Multiple high density shadow	Multiple high density shadow	Ground-glass opacity	Grou Opa Con
Before discharge	Improvement	Normal	Normal	Improvement	Improvement	Normal	Improvement	Improvement	Normal	Imp

7 cases (70%) had more than 4 times of nucleic acid tests. The ranges for virus nucleic acid to turn negative were 14 days (5-22days).

Abnormalities on chest computed tomograms (CT) were detected in 8 cases (80%), mostly manifested as single or multiple localized high density shadow(4/8), and unilateral ground-glass opacity(3/8,37.5%), except for 2 cases who showed asymptomatic characteristics. It should be noted that 2 of 4 cases without obvious symptoms also had localized high density shadow or ground-glass opacity imaging. Representative radiologic findings in two cases were provided in Fig. 2.

Treatment And Clinical Outcomes

At the very beginning, there were neither effective antiviral drugs nor any experience in treatment for pediatric patients with COVID-19. Treatment for pediatric patients was based on the experience of adult treatment. All cases received antiviral treatment, and only one were given empirical antibiotic treatment. No one received systematic corticosteroid or immunoglobulin treatment. In addition, 6 cases were given traditional Chinese medicine (Lianhua Qingwen Capsule) (Table 2).

All cases were discharged without any complication when they met the discharge standard : body temperature returned to normal for more than 3 days, respiratory symptoms improved significantly, and respiratory pathogenic nucleic acid test was negative for two consecutive times (Sampling interval at least 1 day). The median times of hospital stay were 18 days (7–26 days). Prolonged hospital stay was mainly duo to prolonged positive nucleic acid tests.

Discussion

The current outbreak of COVID-19, which has affected more than 100,000 people worldwide and continues to grow rapidly by now, poses a huge potential threat to children.In this report, we summarized the pediatric characteristics with COVID-19.

Based on our observations and current scattered case reports on children[5–13] and adults[14–18],the clinical manifestations of children patients were relatively mild,which was similar to SARS. A few reports about children with SARS showed that the clinical presentation in pediatric patients had milder disease and were less likely to be admitted to an intensive care unit, receive supplemental oxygen or be treated with methylprednisolone[16, 19]. Similarly, no deaths were reported among children or adolescents with SARS[16]. The molecular mechanism of mild symptoms in children may be related to angiotensin-converting enzyme II (ACE2). Already identifed as the SARS-CoV receptor[20, 21], ACE2 has been shown mediates SARS-CoV-2 infection of the type II alveolar cells [22–24]. Paradoxically, although ACE2 mediates viral entry to the host, its deficiency worsens lung injury in experimental models[25, 26]. Most important of all, there had been a significant age-specific decline of ACE2 expression in rat lung, especially during the later aging process[27], which may explain why pediatric patients with SARS or COVID-19 showed milder or no symptoms.

In addition to respiratory droplet and direct contact transmission, COVID-19 has been proven to be transmitted through the faecal-oral route[30] and ocular conjunctival route. Considering this, once exposed, children are very likely to be infected. Most if not all children patients have been in close contact with infected adults as a household contact, suggestting a"parent to child"transmission, which was believed to be the most important route of transmission that put children at a particular risk. However, in our observations and some other reports[5, 6], no reverse transmission (ie a "child to parent"transmission) have been identified even after long-term closely contact with the siblings and elderly. Similarly and surprisingly, there had been no major spread of the disease among classmates in schools during the SARS epidemic in 2003–2004.It seems that SARS-CoV-2 are less likely to transmit between children or from children to adults. Which requires larger sample investigations to confirm.

There is no known effective pharmaceutical agent for COVID-19 ,especially for children. Several potential drug candidates, including lopinavir/ritonavir (Kaletra®), nucleoside analogs, neuraminidase inhibitors, remdesivir, umifenovir (arbidol), DNA synthesis inhibitors, chloroquine, and Chinese traditional medicine have been proposed[28, 29]. Interferon-α2b nebulization and Lopinavir/litonavir have been recommended as treatment for children[17, 18, 30], however, the safety,efficacy, treatment course and side effects remain unknown. It has been suggested that antiviral drugs should not be used routinely unless in critical cases, and that the goals of treatment should be to alleviate symptoms and maintain the immune balance[31].

Children might be less likely to become infected or, if infected, may show milder symptoms, and either of these situations would account for under representation in the confirmed case count[32]. It is likely that future serological studies will show much asymptomatic disease in children. There are limitations in this study, with few samples and short follow-up time, which limit the interpretation of more clinical significance.

Although most people try to understand covid-19, many questions remain unclear.What we can do now is aggressively implement infection control measures to prevent the spread of the SARS-CoV-2 to children. More studies should be done, as the more we learn about this disease and its associated outbreaks, the better we can respond accurately.

Declarations

Ethics approval and consent to participate: This study was approved by the Medical Ethical Committee of Zhongnan Hospital of Wuhan University (clinical ethical approval number 2020004) and informed consents of specimen's collection was waived.

Consent for publication: All author are aware to publish this study and availability of data and materials.

Availability of data and materials: Not applicable.

Competing interests: The authors declare that they have no competing interests.

Funding: No funding.

Acknowledgement: All authors approved the final manuscript as submitted and agree to be accountable for all aspects of the work.

Authors' contributions: Drs. MC, PF, RP and DZ conceptualized the study design. Drs. ZL, JL, SH and WW recruited the patients, collected specimens, collected demographic, clinical, and laboratory data; MC, PF, RP and DZ analyzed the data; and MC, PF, RP and DZ wrote the initial drafts of the manuscript; All authors read and approved the final report.

References

[1] Wu F, Zhao S, Yu B, et al. A new coronavirus associated with human respiratory disease in China[J]. Nature,2020.

[2] Db J, CDC COVID- Response Team. Update: Public Health Response to the Coronavirus Disease 2019 Outbreak - United States, February 24, 2020.[J]. MMWR. Morbidity and mortality weekly report (MMWR Morb. Mortal. Wkly. Rep.),2020,69(8):216-219.

[3] World Health Organization. Coronavirus disease 2019 (COVID-19) Situation Report-50,https://www.who.int/docs/default-source/coronaviruse/situation-reports/20200310-sitrep-50-covid-19.pdf.Acess10 Mar 2020.

[4] National Health Commission of People's Republic of China. Diagnosis and treatment of pneumonia caused by novel coronavirus (trial version 7). http://www.nhc.gov.cn/yzygj/s7653p/202003/46c9294a7dfe4cef80dc7f5912eb1989/files/ce3e6945832a438eaae415350a8ce964.pdf.Access 4 Mar 2020.

[5] Chen F, Liu Z S, Zhang F R, et al. [First case of severe childhood novel coronavirus pneumonia in China][J]. Zhonghua Er Ke Za Zhi,2020,58(3):179-182.

[6] Zhang Y H, Lin D J, Xiao M F, et al. [2019-novel coronavirus infection in a three-month-old baby][J]. Zhonghua Er Ke Za Zhi,2020,58(0):E6.

[7] Kam K Q, Yung C F, Cui L, et al. A Well Infant with Coronavirus Disease 2019 (COVID-19) with High Viral Load[J]. Clin Infect Dis,2020.

[8] Wang D, Ju X L, Xie F, et al. [Clinical analysis of 31 cases of 2019 novel coronavirus infection in children from six provinces (autonomous region) of northern China][J]. Zhonghua Er Ke Za Zhi,2020,58(4):E11.

[9] Cai J H, Wang X S, Ge Y L, et al. [First case of 2019 novel coronavirus infection in children in Shanghai][J]. Zhonghua Er Ke Za Zhi,2020,58(2):86-87.

[10] Xiong D,Jiang J,Feng D,et al. Two cases of new coronavirus pneumonia in children[J]. Chinese Pediatric Emergency Medicine,2020(00):E2.

[11] Deng H,Zhang Y,Wang Y,et al.Two cases of new coronavirus pneumonia in children[J]. Chinese Pediatric Emergency Medicine,2020(00):E1.

[12] Feng K,Yun Y,Wang X,et al. Analysis of CT features of 15 Children with 2019 novel coronavirus infection. Chinese Journal of Pediatrics, 2020. 58(0): p. E007.

[13] Ma H,Shao J,Wang S,et al. High-resolution CT findings of children with 2019 new coronavirus pneumonia[J]. Chinese Journal of Radiology,2020(00):E2.

[14] Chen N, Zhou M, Dong X, et al. Epidemiological and clinical characteristics of 99 cases of 2019 novel coronavirus pneumonia in Wuhan, China: a descriptive study[J]. The Lancet,2020,395(10223):507-513.

[15] Guan W, Ni Z, Hu Y, et al. Clinical Characteristics of Coronavirus Disease 2019 in China[J]. New England Journal of Medicine,2020.

[16] Lj S, Ms M, R H, et al. Severe acute respiratory syndrome in children.[J]. The Pediatric infectious disease journal (Pediatr. Infect. Dis. J.),2007,26(1):68-74.

[17] Zm C, Jf F, Q S, et al. Diagnosis and treatment recommendations for pediatric respiratory infection caused by the 2019 novel coronavirus.[J]. World journal of pediatrics : WJP (World J Pediatr),2020.

[18] K S, Y Y, T W, et al. Diagnosis, treatment, and prevention of 2019 novel coronavirus infection in children: experts' consensus statement.[J]. World journal of pediatrics : WJP (World J Pediatr),2020.

[19] Am L, Pc N. Severe acute respiratory syndrome (SARS) in neonates and children.[J]. Archives of disease in childhood. Fetal and neonatal edition (Arch. Dis. Child. Fetal Neonatal Ed.),2005,90(6):F461-F465.

[20] Kuba K, Imai Y, Rao S, et al. A crucial role of angiotensin converting enzyme 2 (ACE2) in SARS coronavirus–induced lung injury[J]. Nature Medicine,2005,11(8):875-879.

[21] Li W, Moore M J, Vasilieva N, et al. Angiotensin-converting enzyme 2 is a functional receptor for the SARS coronavirus[J]. Nature,2003,426(6965):450-454.

[22] Jf C, Kh K, Z Z, et al. Genomic characterization of the 2019 novel human-pathogenic coronavirus isolated from a patient with atypical pneumonia after visiting Wuhan.[J]. Emerging microbes & infections (Emerg Microbes Infect),2020,9(1):221-236.

[23] Li R, Qiao S, Zhang G. Analysis of angiotensin-converting enzyme 2 (ACE2) from different species sheds some light on cross-species receptor usage of a novel coronavirus 2019-nCoV[J]. Journal of Infection,2020.

[24] Xu H, Zhong L, Deng J, et al. High expression of ACE2 receptor of 2019-nCoV on the epithelial cells of oral mucosa[J]. Int J Oral Sci,2020,12(1):8.

[25] Wang J, Zhao S, Liu M, et al. ACE2 expression by colonic epithelial cells is associated with viral infection, immunity and energy metabolism[J]. medRxiv,2020:2020-2022.

[26] Wu Y. Compensation of ACE2 Function for Possible Clinical Management of 2019-nCoV-Induced Acute Lung Injury[J]. Virol Sin,2020.

[27] Xudong X, Junzhu C, Xingxiang W, et al. Age- and gender-related difference of ACE2 expression in rat lung[J]. Life Sciences,2006,78(19):2166-2171.

[28] H L. Drug treatment options for the 2019-new coronavirus (2019-nCoV).[J]. Bioscience trends (Biosci Trends),2020.

[29] M W, R C, L Z, et al. Remdesivir and chloroquine effectively inhibit the recently emerged novel coronavirus (2019-nCoV) in vitro.[Z]. 2020.30,269-271.

[30] Ym A, A A, Hh B, et al. Treatment of Middle East Respiratory Syndrome with a combination of lopinavir-ritonavir and interferon-β1b (MIRACLE trial): study protocol for a randomized controlled trial.[Z]. 2018.19,81.

[31] Yang P, Liu P, Li D, et al. Corona Virus Disease 2019, a growing threat to children?[J]. Journal of Infection,2020.

[32] Q L, X G, P W, et al. Early Transmission Dynamics in Wuhan, China, of Novel Coronavirus-Infected Pneumonia.[J]. The New England journal of medicine (N. Engl. J. Med.),2020.

Figures

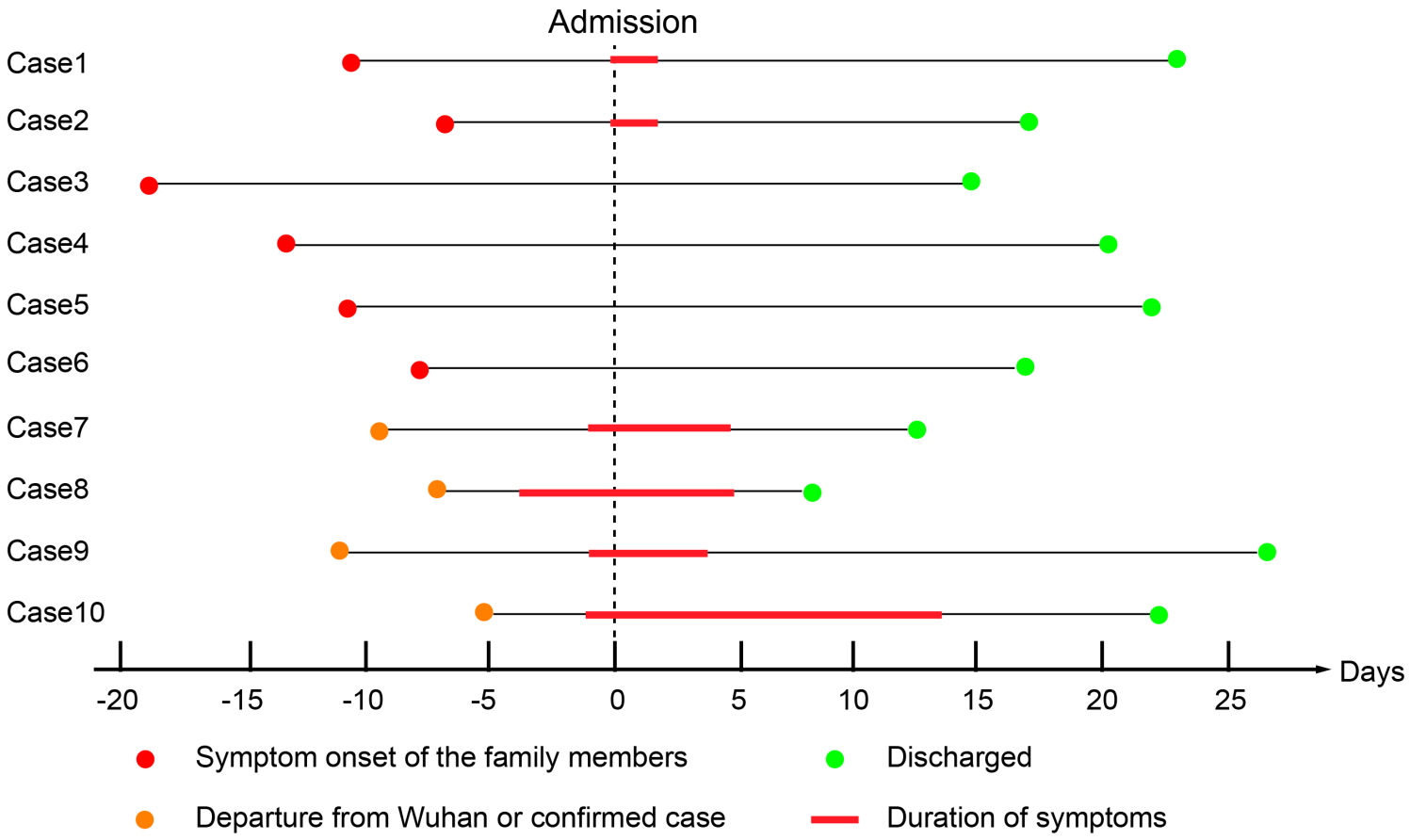

Figure 1

Transverse chest computed tomograms from a girl (case 1). A showed a single localized high density shadow of left lower lobe near the pleura on day 1 after symptom (fever) onset. B showed great improvement 12 days later before discharge.

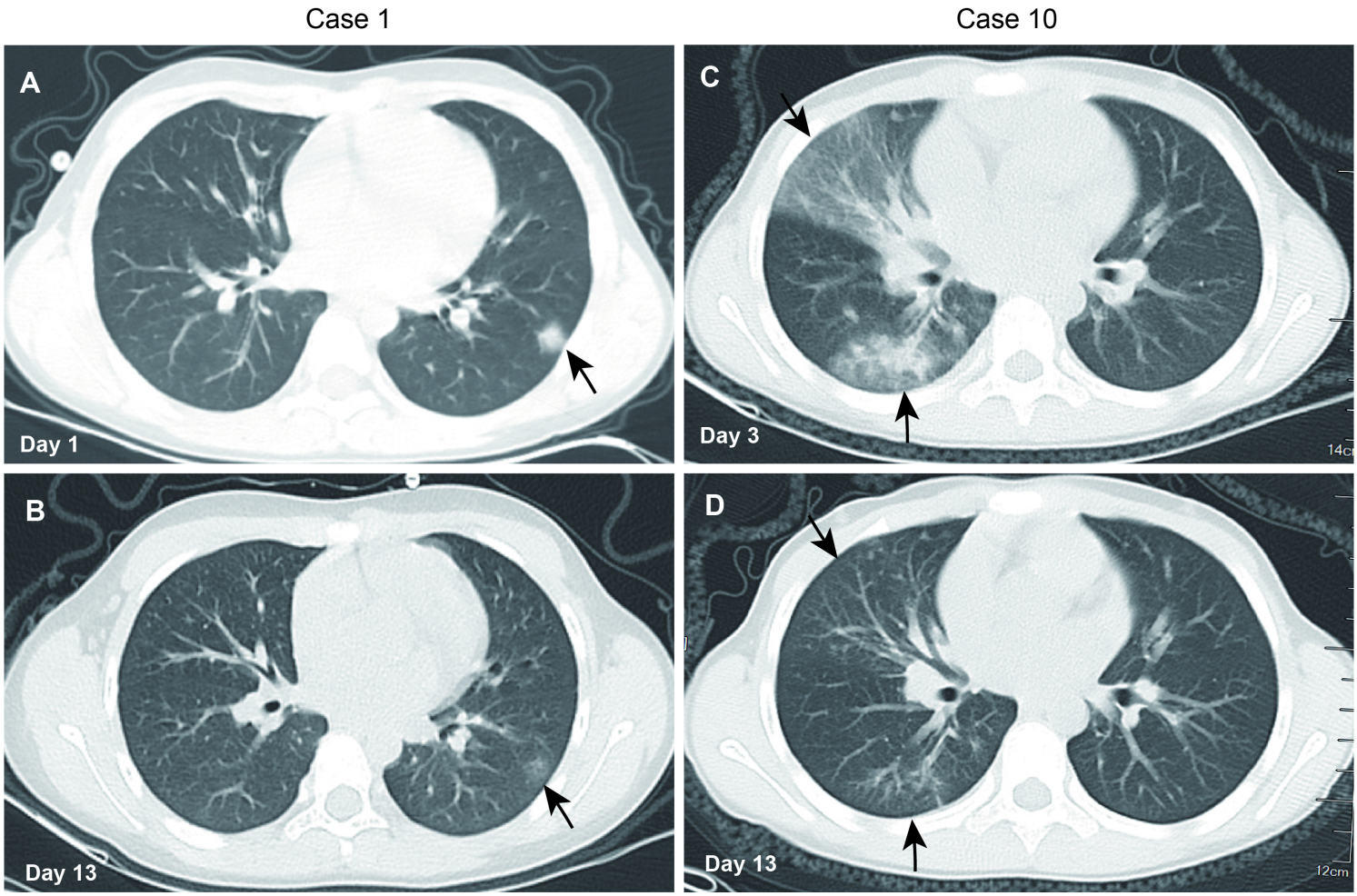

Figure 2

Transverse chest computed tomograms from a girl (case 10). C showed ground-glass opacity with consolidation of right middle and lower lobes at admission 3 days after symptom (cough and fever) onset. D showed great improvement 10 days later before discharge.