TaTME Combined with IORT for the Treatment of Locally Advanced Rectal Cancer：A case report

Yu Guo
the Second Hospital of Jilin University
Shuang Wang
the Second Hospital of Jilin University
Zeyun Zhao
The Second Hospital of Jilin University
Wangsheng Xue
The Second Hospital of Jilin University
Jiannan Li
The Second Hospital of Jilin University
An Shang
The Second Hospital of Jilin University
Donglin Li
The Second Hospital of Jilin University
Min Wang (jdeywangmin@163.com)
The Second Hospital of Jilin University https://orcid.org/0000-0002-1288-016X

Case report

Keywords: taTME, IORT, DRM, LC, CRM, OS

Posted Date: February 9th, 2021

DOI: https://doi.org/10.21203/rs.3.rs-183341/v1

Title page

TaTME Combined with IORT for the Treatment of Locally Advanced Rectal Cancer：A case report

Authors:

Yu Guo†: The Second Hospital of Jilin University, China. Guoyu126344@163.com

Shuang Wang†: The Second Hospital of Jilin University, China. jdeywangshuang@163.com

Zeyun Zhao: The Second Hospital of Jilin University, China. dearzhaoyun@163.com

Wangsheng Xue: The Second Hospital of Jilin University, China. imsurgeon@163.com

Jiannan Li: The Second Hospital of Jilin University, China. jnli@jlu.edu.cn

An Shang: The Second Hospital of Jilin University, China. 1724302294@qq.com

Donglin Li: The Second Hospital of Jilin University, China.846763584@qq.com

Min Wang*: The Second Hospital of Jilin University, China. jdeywangmin@163.com

†**The author has similar contribution**

* **Corresponding author**: Min Wang

Department of the General Surgery, Jilin University Second Hospital, Changchun, Jilin, China No.218, Ziqiang Street, Nanguan District, Changchun City, Jilin Province, China

E-mail: jdeywangmin@163.com Tel:(+86)18135435372

Abstract

Transanal total mesorectal excision (taTME) which aims to achieve more accurately complete resection of distal mesorectum has arouse much more attention worldwide. TaTME can significantly improve the local control (LC) and overall survival (OS) of the patients with locally advanced rectal cancer. Intraoperative radiotherapy (IORT), also as a emerging treatment method for locally advanced tumors, can lead to the potential for dose escalation, reduce overall treatment time, and increase patient convenience. Our study firstly combined taTME and IORT for the treatment of locally advanced rectal cancer. The tumor involved 60 mm rectal wall and located 30 mm from anal margin. TaTME and IORT were successfully achieved in this patient. There was no obvious complications occurred, including the anastomotic fistula. The patient recovered well and further systematic systematic chemotherapy and radiotherapy were suggested. We conclude that taTME with low-energy X-rays IORT may not only benefit the circumferential resection margin (CRM) but also improve the local control (LC) for the patient with locally advanced rectal cancer.

Key words: taTME, IORT, DRM, LC, CRM, OS

Background

Colorectal adenocarcinoma is the third most common cancer worldwide and the total mesorectal excision (TME) rule is a gold standard of surgery to achieve negative distal resection margin (DRM) and circumferential resection margin (CRM) which are closely associated with local recurrence (LR) and disease-free survival (DFS)[1,2]. Medium or lower rectum cancer is often a challenge for surgeons to take the surgical dissection due to the limited width of distal pelvis and with the difficulties in visualization. Especially, narrow male pelvis, high body mass index (BMI), bulky tumors, visceral obesity, locally advanced tumors, has been identified as risk factors predicting intraoperative difficulty and potentially leading to a poor oncology specimen.

Due to the limited field of vision, laparoscopic or open TME is difficult to identify the resection of DRM, which may lead to the risks of uncomplete TME or

positive CRM in paitens with above factors. Furthermore, in the narrow pelvis, endoscopic stapler is not flexible and usually requires multiple stapler firings, which will lead to angulated and crossing staple lines, increasing the risk of anastomotic leakage[3]. To overcome these chanllenges and combinie the concept of Natural Orifice Transluminal Endoscopic Surgery (NOTES) and Transanal Endoscopic Microsurgery (TEM), transanal TME (taTME) aiming to achieve more accurately complete resection of distal mesorectum was firstly introduced by Sylla[4] and has been arouse a great deal of attention.

Although the rate of LR has been obviously reduced with the TME surgery, LR rate of locally advanced cancer is still higher. Furthermore, the achievement of complete surgical excision and margins is significant, multiple modalities involving surgery, external beam radiotherapy, and chemotherapy are still required. Nowadays, to improve LR and avoid the risks related to preoperative external beam radiotherapy (EBRT), intraoperative radiotherapy (IORT), as a part of multimodality treatmet, allows the precise delivery of a large tumoricidal dose to the target areas to reduce the LR[5] during operation. Compared with external beam radiotherapy, the advantages of IORT include the potential for dose escalation, reduced overall treatment time, and increased patient convenience. Especially, the main advantage of IORT is sterilizing close or positive resection margins.

Recently, compared with intraoperative electron radiation therapy (IOERT) which is delivered in special shielded operating rooms[6] and higher surface dose of high-dose rate brachytherapy (HDR-IORT) [7], the mobile device of INTRABEAM IORT that emits low-energy (50 kV) photons at a high dose-rate and modulates the electron beam to soft x-ray in a uniform dose[8] has been widely used in tumors of breast, rectum, brain, and vertebrae. INTRABEAM mobile IORT could precisely administer high dose of radiation to the at-risk areas while concurrently minimizing exposure to surrounding structures (bowel, bladder) to optimize the local effects of radiotherapy[9].

To overcome the higher positive rate of CRM and improve the local control (LC), we take the advantages of taTME and INTRABEAM IORT using low-energy X-rays to provide a new treatment modality in locally advanced patiens with above risk factors.

As far as we know, our study is the first report of this novel treatment modality and the purpose of this study is to demonstrate our preliminary experience.

Patients and Methods

A 65-year-old male visited our hospital with bloody stools for 1 month and difficulty defecation for 1 week. The colonoscopy showed a rectal mass located approximately 6 cm from the anal verge and the biopsy revealed rectal adenocarcinoma. No distant metastasis was found by the whole body computed tomography (CT) scan. Magnetic resonance image (MRI) showed the tumor involved 60 mm rectal wall (Figure 1A) and located 30 mm from anal margin(Figure 1B,C). In addition, some suspected lymph nodes were also observed by MRI (Figure 1D). The mesorectum fascia (MRF) and extramural vascular invasion (EMVI) was positive and the preoperative stage was $T_2N_{2b}M_0$.

He had no family history and other systemic diseases. The level of carcinoembryonic antigen (CEA) was 1.11 ng/ml (normal, 0-3 ng/ml) and carbohydrate antigen199 (CA199) level is 37.4 U/ml (normal, 0-35 U/ml). In addition, the BMI was 25.43 kg/m^2. The patient presented with bowel obstruction and strongly refused preoperative neoadjuvant chemotherapy, and according to the preoperative evaluation, our medical team planned to take the taTME surgery combined with IORT using low-energy X-rays after the patient signed the consent form.

Preoperative preparation

The patient underwent a full mechanical bowel preparation, and received parenteral antibiotics prophylaxis prior to operation. After general anesthesia was performed, the patient was placed in lithotomy position to facilitate perineal view and transanal approach. A 10-mm trocar port was inserted through the umbilicus to insufflated the abdomen and a 12-mm trocar port was inserted through the site preoperatively marked for ileostomy. Other three 5-mm trocar ports were routinely inserted following the laparoscopic rectal surgery.

Surgical steps

The operation was performed at the Second Hospital of Jilin University, Changchun, China, by a team of colorectal surgeons and radiological physicians. The first case of laparoscopic-assisted taTME combined with INTRABEAM IORT was approved by the Ethics Committee and Institutional Review Board of the Second Hospital of Jilin University, China.

Transabdominal approach

1) Laparoscopic exploration was performed.

2) The origin of inferior mesenteric artery (IMA) was ligated and lymphadenectomy around IMA was done after patient was placed in the right-head-ventral position to achieve optimal view of the left colon. (Figure 2A)

3) Dissect the left side colon to splenic flexure of colon with the medial-lateral retroperitoneal approach.

4) The anterior mesorectum dissection was progressed to the level of seminal vesicles anteriorly (Figure 2B) and the posterior mesorectum dissection was progressed the level of 5th sacral or caudal vertebrae. (Figure 2C)

5) The transanal approach was operated while the IORT device was modulated.

Transanal approach

1) The skin around anus was stretched in six directions by sutures to achieve optimal view.

2) Under direct surveillance, purse-string suture was performed at 1 cm from the lower edge of tumor to close the rectal cavity and created an operating cavity.(Figure 3A)

3) Connect the laparoscopinc pneumatic machine and the transanal operation platform pushed into anus to reach a stable pressure of the operating cavity in 13 mmHg. (Figure 3B). In this study, we used the plastic bag to connect the laparoscopic pneumatic machine to the transanl operation platform to obtain a stable pressure.

4) Under laparoscopic surveillance, dissect the full thickness of rectal wall circumferentially (Figure 3C) and the mesorectum along the “holy plane” between the visceral and parietal layers of pelvic fascia to meet the transabdominal dissection plane.

5) After the rectal mass was dragged up transanally, the proximal sigmoid colon was fixed by the purse-string forceps and cut off by scalpel to remove the rectal specimen (Figure 3D) , and the top part of stapler was inserted into the colon. The dissected rectal specimen was photographed (Figure 3E).

6) Based on the width of anus, 4-cm in diameter applicator was pushed into the tumor bed transanally (Figure 3F,G). Under the transabdominally laparoscopic surveillance, the applicator was pushed closely to the tumor bed and wet gauzes were put to isolate and protect the adjacent structures from radiation (Figure 3H).

7) IORT was operated with a prescribed dose of 18 Gy.

8) Purse-string suture was performed at distal resection site of the intestinal tissue and the digestive continuity was restructed by the circular stapler(Figure 3I).

9) Prophylactic ileostomy was performed synchronously.

Results

The whole operative time was approximately 350 min, consisting of 40 min for laparoscopic dissection, 120 min for taTME procedure, 30 min for radiation, 40 min for the connection and prophylactic ileostomy.

The bowel recovery of patient happened at the 8th day post surgery. The Foley catheter and anal catheter were removed at the 7th and the 12th day, respectively. Postoperative pathology revealed the moderately differentiated rectum adenocarcinoma ($pT_3N_{2b}M_0$) and the DRM and CRM were negative. To prevent the occurrence of the anastomotic or anal stenosis, dilation of anal canal was done by finger three to five times a day. The patient recovered uneventfully and discharged the hospital at the 15th day. Six to eight cycles of XELOX chemotherapy regimen were suggested to the patient in the next treatment phase. The patient underwent postoperative chemotherapy as recommended, and until now(01,2021), there is no sign of postoperative recurrence.

Discussion and Conclusions

TME, which is a standard surgical approach aiming to achieve complete resection of the rectum and mesorectal lymph nodes, has been lead to improve LC and overall survival (OS)[10]. CRM is one of the key prognostic factors that determine the LR. The value of CRM involvement is not only concerning for LR or development of distant metastases but also a strong predictor of whether postoperative chemoradiotherapy should be provided.

TaTME includes the"push me-pull you" and "bottom-to-up" approaches, which allows two-team synchronous collaboration to further shorten the operation time[11]. The "push me-pull you" approach can afford the crucial medial retraction of the mesorectum to secure sexual function by providing better visualization of the pillars, plexuses, and neurovascular bundles[12]. The "bottom-to-up" approach makes the dissection more easily and efficiently by overcoming the limitations[13] and also allows for no need for an extra abdominal assist incision. Furthermore, cutting specimen in vitro can avoid multiple stapler firings to reduce the incidence of anastomosis leakage[14].

When the abdominal dissection completed, based on the transanal approaches of deep pelvic dissection, laparoscopic-assisted taTME can identify the resection plane clearly to achieve a beeter visualization of distal rectum and more clearly distal resection margin to assure the safety of CRM in these challenging patients[15]. In a RCT comparing taTME to laparoscopic TME in 100 patients with low rectal cancer, Denost *et al*[16] revealed lower positive CRM rates in taTME group (4%) than that in laparoscopic TME group (18%). TaTME can also reduce the rate of coversion to open surgery with only 0-9.1% in taTME cases, which is much more lower compared with that in laparoscopic TME cases in COLOR II[17].

Despite of the advance in the treatment of locally advanced rectal cancer, LR still a major challenge. IORT has been introduced to the multiple treatment modality. Cantero-Munoz P *et. al.* [18] reported a systematic review of 15 studies and revealed the 5- to 6-year LC rates of IORT (> 80%) and the OS of IORT (65%) for primary locally

advanced rectal cancer. Susan *et. al.* [19] reported a retrospective review of 42 patients treated with INTRABEAM IORT. The 1-year recurrence rate and distant metastasis were 16% and 32% in the whole cohort, respectively. Potemin *et. al.*[20] also reported that the recurrence rate was 13% in 68 patients (47 stage II vs 21 patients stage III) treated with INTRABEAM IORT.

The mobile device of INTRABEAM PRS can generate isotropic dose distribution in the applicator with higher application dose rate of about 10Gy/min, which not only inhibits the potential proliferation or metastasis of residual tumor cells but also shortens the treat time[21]. Furthermore, with the increased distance from applicator surface, the dose attenuates quickly so that it could lead to better LC and reduce damage to the adjacent critical tissues and surrounding organs. In addition, the applicator with the flexibility at 6 degrees[22] of freedom enables it to be placed into the targeted area by anus easily, which not only avoids the extra abdominal incision but also accords with the concept of "NOTES".

INTRABEAM PRS could deliver a large radiation dose (10–20 Gy) to the targeted area with rapid dose attenuation. For IORT, the radiation dose (18-20 Gy) is equivalent to the external dose of 50 Gy [23]. In a multi-institutional phase randomized trial of IORT of rectal cancer, Dubois *et. al* [24] delivered 18 Gy in the IORT arm and the results revealed that there was no significant superior radiative toxicity. Guo *et. al.* [19] delivered a median safe surface dose of 14.4 Gy and a dose of 5 Gy was prescribed to a depth of 1 cm in locally advanced rectal cancer. In our institution, we have performed INTRABEAM IORT combining Miles, Dxion, laparoscopic intersphincteric resection (Lap ISR) in locally advanced rectal cancer for more than 4 years. Until now, no obvious radiative toxicity has occurred under the radiation dose of 18 Gy. As a result, 18 Gy radiation dose was recommended in this study. In future studies, more factors will be considered with larger samples and longer follow-up.

In our study, the male patient with locally advanced rectal cancer accords to the indications of taTME. Specially, the BMI of the patient is 25.43 kg/m^2 which indicates that the pelvis is narrow for the male patient, the maximum diameter of the tumor is about 7 cm, and the lower edge of the tumor locates 3 cm from the anal margin. All of

these above can lead to the insufficient space of DRM and positive CRM. As a result, the taTME method is suitable for this patient. Considering the medical costs, the patient refused to receive preoperative chemotherapy or radiotherapy. Therefore, the INTRABEAM IORT aimed to substitute the treatment efficacy of preoperative chemotherapy and radiotherapy in our study. However, systematic chemotherapy and local radiotherapy for the lynphathic drainage area are still important post-surgery. To our knowledge, this is the first time combining taTME with INTRABEAM IORTto improve the LC in locally advanced rectal cancer patients with risk factors predicting difficult manipulation and a poor oncology specimen in laparosopic TME.

There was no symptoms of urinary dysfunction observed and the result of urinary function questionnaire was satifactory, which indicated the good preservation of autonanerve of taTME and dose attenuation effect of INTRABEAM IORT. However, compared to the abdominal approaches for rectal cancer, taTME arises new specific complications, including rectal or vaginal perforation[25], bladder injury, and the injury of the urethra and urethral sphincter[26], which not commonly occurred in laparoscopic TME. Thus, in the future follow-up, we should not only pay attention on LC, anastomotic stenosis, anorectal manometry and incontinence, but also the LARS and urethral function.

Importantly, the DRM was negative and there was no signs of anastomotic fistula in this patient. The color of the anal canal tissues near the anastomosis changed to normal gradually which indicated good blood supply. And the anastomosis healed well and no fistula occurred. This may be explained by the dose attenuation of IORT and good anastomosis of taTME for our patient. To achieve the satisfacroty anastomosis in taTME, the two-steps purse-string suture are vital. For the fist step of purse-string suture which is performed at 1 cm from the lower edge of tumor, the needle shouldn't be inserted too deep and only the mucosal layer and submucosa should be sutured. When suturing too much tissues, the purse-string may not be sutured tightly and the isolation of the tumor may not be achieved. For the second step of purse-string suture, fully sutured intestinal wall should be achieved to obtain the full-thickness anastomosis of the disconnected intestinal tissues.

No matter the taTME surgery or the IORT, we should pay attention to the anorectal function, especially the bowel frequency and fecal incontinence. TaTME transanal approach may bring injury to the intersphincteric resection[27] and the radiotherapy may induce the fibrosis around rectum affecting the compliance of rectum[28]. Both of them may lead to the low anterior resection syndrome (LARS), a complex of symptoms consisting of incontinence for flatus and /or feces, constipation, urgency, and bowel movements[29]. In our study, the anorectal function should be investigated after the return of ileostomy.

Although the lack of special pneumatic machine to maintain the stable pressure in transanal procedure, we used the plastic bag to connect the laparoscopic pneumatic machine to the transanl operation platform to obtain a stable pressure. Furthermore, the anus could be exposed by sutures instead of Longstar retractor to achieve optimal operation field. To our knowledge, our study is the first to report the taTME with INTRABEAM IORT using low-energy X-rays in locally advanced low rectal cancer, and several advantages of the treatment modality was concluded as follows.

Firstly, taTME benefits in achieving a good oncology specimen and lowering the positive rate of CRM in patients with risk factors, and the addition of INTRABEM IORT can further enhance the LC. Secondly, based on the concept of Natural Orifice Transluminal Endoscopic Surgery (NOTES), the removal of specimen and the input of IORT applicator which are both transanally can avoid the extral abdominal incision and reach a good cosmetology. Thirdly, the characteristics of dose attenuation of INTRABEAM IORT can enhance the radiotherapy in tumor bed while reduce the injury to surrounding normal structures and it can partially replace preoperative neoadjuvant treatment[30]. Forthly, due to the mobility of device, INTRABEAM IORT can be performed in the common operation room instead of transporting patients to specially shiled room, which not only shorten the time but also lower the transport risks.

Therefore, when encounters the challenging male and fat patients with narrow pelvis in locally advanced rectal cancer, taTME with low-energy X-rays IORT may not only benefit the CRM but also improve the LC.

In this study, we report the first case of locally advanced rectal cancer who

underwent the combined therapy of hybrid taTME and INTRABEAM IORT. We took the advantages of these two methods. The anus of this patient was successfully preserved and no obvious complications, including the anastomotic fistula, occurred. The patient recovered well and further systematic systematic chemotherapy and radiotherapy were received. And, until now, there is no sign of postoperative recurrence.

Declarations:

Abbreviations

TaTME: Transanal total mesorectal excision; IORT: intraoperative radiotherapy; LC: local control; OS: overall survival; CRM:circumferential resection margin; DRM:distal resection margin; DFS:disease-free survival; EBRT:external beam radiotherapy; NOTES:Natural Orifice Transluminal Endoscopic Surgery;

Ethics approval and consent to participate

This study conforms to the Declaration of Helsinki. The ethics committee of the Second Affiliated Hospital of Jilin University obtained the consent of the patient.

Consent for publication

Written consent was obtained from the patient for publication of this study and accompanying images.

Availability of data and material

The datasets used and/or analyzed during the current study are available from the corresponding author on reasonable request.

Competing interests

The authors declare that they have no competing interests.

Funding

None.

Authors' contributions

YG wrote the first draft of the manuscript. WSX collected the files. All authors read and approved the final manuscript.

Acknowledgements

Not applicable.

References

1. Enker WE (1997) Total mesorectal excision--the new golden standard of surgery for rectal cancer. Ann Med 29 (2):127-133
2. Park IJ, Kim JC (2010) Adequate length of the distal resection margin in rectal cancer: from the oncological point of view. J Gastrointest Surg 14 (8):1331-1337. doi:10.1007/s11605-010-1165-3
3. Ito M, Sugito M, Kobayashi A, Nishizawa Y, Tsunoda Y, Saito N (2008) Relationship between multiple numbers of stapler firings during rectal division and anastomotic leakage after laparoscopic rectal resection. Int J Colorectal Dis 23 (7):703-707. doi:10.1007/s00384-008-0470-8
4. Sylla P, Rattner DW, Delgado S, Lacy AM (2010) NOTES transanal rectal cancer resection using transanal endoscopic microsurgery and laparoscopic assistance. Surg Endosc 24 (5):1205-1210. doi:10.1007/s00464-010-0965-6
5. Ferenschild FT, Vermaas M, Nuyttens JJ, Graveland WJ, Marinelli AW, van der Sijp JR, Wiggers T, Verhoef C, Eggermont AM, de Wilt JH (2006) Value of intraoperative radiotherapy in locally advanced rectal cancer. Dis Colon Rectum 49 (9):1257-1265. doi:10.1007/s10350-006-0651-x
6. Sole CV, Calvo FA, Serrano J, Del Valle E, Rodriguez M, Munoz-Calero A, Turegano F, Garcia-Sabrido JL, Garcia-Alfonso P, Peligros I, Rivera S, Deutsch E, Alvarez E (2014) Post-chemoradiation intraoperative electron-beam radiation therapy boost in resected locally advanced rectal cancer: long-term results focused on topographic pattern of locoregional relapse. Radiother Oncol 112 (1):52-58. doi:10.1016/j.radonc.2014.05.012
7. Nuyttens JJ, Kolkman-Deurloo IK, Vermaas M, Ferenschild FT, Graveland WJ, De Wilt JH, Hanssens PE, Levendag PC (2004) High-dose-rate intraoperative radiotherapy for close or positive margins in patients with locally advanced or recurrent rectal cancer. Int J Radiat Oncol Biol Phys 58 (1):106-112
8. Armoogum KS, Parry JM, Souliman SK, Sutton DG, Mackay CD (2007) Functional intercomparison of intraoperative radiotherapy equipment - Photon Radiosurgery System. Radiat Oncol 2:11. doi:10.1186/1748-717X-2-11
9. Vaidya JS, Baum M, Tobias JS, Wenz F, Massarut S, Keshtgar M, Hilaris B, Saunders C, Williams NR, Brew-Graves C, Corica T, Roncadin M, Kraus-Tiefenbacher U, Sutterlin M, Bulsara M, Joseph D (2011) Long-term results of targeted intraoperative radiotherapy (Targit) boost during breast-

conserving surgery. Int J Radiat Oncol Biol Phys 81 (4):1091-1097. doi:10.1016/j.ijrobp.2010.07.1996

10. Heald RJ, Ryall RD (1986) Recurrence and survival after total mesorectal excision for rectal cancer. Lancet 1 (8496):1479-1482

11. Xu W, Xu Z, Cheng H, Ying J, Cheng F, Xu W, Cao J, Luo J (2016) Comparison of short-term clinical outcomes between transanal and laparoscopic total mesorectal excision for the treatment of mid and low rectal cancer: A meta-analysis. Eur J Surg Oncol 42 (12):1841-1850. doi:10.1016/j.ejso.2016.09.002

12. Heald RJ (2013) A new solution to some old problems: transanal TME. Techniques in Coloproctology 17 (3):257-258. doi:10.1007/s10151-013-0984-0

13. Bretagnol F, Lelong B, Laurent C, Moutardier V, Rullier A, Monges G, Delpero JR, Rullier E (2005) The oncological safety of laparoscopic total mesorectal excision with sphincter preservation for rectal carcinoma. Surg Endosc 19 (7):892-896. doi:10.1007/s00464-004-2228-x

14. Braunschmid T, Hartig N, Baumann L, Dauser B, Herbst F (2017) Influence of multiple stapler firings used for rectal division on colorectal anastomotic leak rate. Surg Endosc 31 (12):5318-5326. doi:10.1007/s00464-017-5611-0

15. Fernandez-Hevia M, Delgado S, Castells A, Tasende M, Momblan D, Diaz del Gobbo G, DeLacy B, Balust J, Lacy AM (2015) Transanal total mesorectal excision in rectal cancer: short-term outcomes in comparison with laparoscopic surgery. Ann Surg 261 (2):221-227. doi:10.1097/SLA.0000000000000865

16. Denost Q, Adam JP, Rullier A, Buscail E, Laurent C, Rullier E (2014) Perineal transanal approach: a new standard for laparoscopic sphincter-saving resection in low rectal cancer, a randomized trial. Ann Surg 260 (6):993-999. doi:10.1097/SLA.0000000000000766

17. Jeong SY, Park JW, Nam BH, Kim S, Kang SB, Lim SB, Choi HS, Kim DW, Chang HJ, Kim DY, Jung KH, Kim TY, Kang GH, Chie EK, Kim SY, Sohn DK, Kim DH, Kim JS, Lee HS, Kim JH, Oh JH (2014) Open versus laparoscopic surgery for mid-rectal or low-rectal cancer after neoadjuvant chemoradiotherapy (COREAN trial): survival outcomes of an open-label, non-inferiority, randomised controlled trial. Lancet Oncol 15 (7):767-774. doi:10.1016/S1470-2045(14)70205-0

18. Cantero-Munoz P, Urien MA, Ruano-Ravina A (2011) Efficacy and safety of intraoperative radiotherapy in colorectal cancer: a systematic review. Cancer Lett 306 (2):121-133. doi:10.1016/j.canlet.2011.02.020

19. Guo S, Reddy CA, Kolar M, Woody N, Mahadevan A, Deibel FC, Dietz DW, Remzi FH, Suh JH (2012) Intraoperative radiation therapy with the photon radiosurgery system in locally advanced and recurrent rectal cancer: retrospective review of the Cleveland clinic experience. Radiat Oncol 7:110. doi:10.1186/1748-717X-7-110

20. Potemin S, Uvarov I, Vasilenko I (2015) Intraoperative radiotherapy in locally-advanced and recurrent rectal cancer: Retrospective review of 68 cases, vol 4. doi:10.3978/j.issn.2218-676X.2015.04.07

21. Vaidya JS, Joseph DJ, Tobias JS, Bulsara M, Wenz F, Saunders C, Alvarado M, Flyger HL, Massarut S, Eiermann W, Keshtgar M, Dewar J, Kraus-Tiefenbacher U, Sutterlin M, Esserman L, Holtveg HM, Roncadin M, Pigorsch S, Metaxas M, Falzon M, Matthews A, Corica T, Williams NR, Baum M (2010) Targeted intraoperative radiotherapy versus whole breast radiotherapy for breast cancer (TARGIT-A trial): an international, prospective, randomised, non-inferiority phase 3 trial. Lancet 376 (9735):91-102. doi:10.1016/S0140-6736(10)60837-9

22. Eaton DJ (2012) Quality assurance and independent dosimetry for an intraoperative x-ray device. Med Phys 39 (11):6908-6920. doi:10.1118/1.4761865

23. Willett CG, Czito BG, Tyler DS (2007) Intraoperative radiation therapy. Journal of Clinical Oncology 25 (8):971-977. doi:10.1200/Jco.2006.10.0255

24. Dubois JB, Bussieres E, Richaud P, Rouanet P, Becouarn Y, Mathoulin-Pelissier S, Saint-Aubert B, Ychou M (2011) Intra-operative radiotherapy of rectal cancer: results of the French multi-institutional randomized study. Radiother Oncol 98 (3):298-303. doi:10.1016/j.radonc.2011.01.017

25. Chouillard E, Regnier A, Vitte RL, Bonnet BV, Greco V, Chahine E, Daher R, Biagini J (2016) Transanal NOTES total mesorectal excision (TME) in patients with rectal cancer: Is anatomy better preserved? Tech Coloproctol 20 (8):537-544. doi:10.1007/s10151-016-1449-z

26. Muratore A, Mellano A, Marsanic P, De Simone M (2015) Transanal total mesorectal excision (taTME) for cancer located in the lower rectum: short- and mid-term results. Eur J Surg Oncol 41 (4):478-483. doi:10.1016/j.ejso.2015.01.009

27. Montesani C, Pronio A, Santella S, Boschetto A, Aguzzi D, Pirozzi R, D'Amato A, Vestri A (2004) Rectal cancer surgery with sphincter preservation: functional results related to the level of anastomosis. Clinical and instrumental study. Hepatogastroenterology 51 (57):718-721

28. Bruheim K, Guren MG, Skovlund E, Hjermstad MJ, Dahl O, Frykholm G, Carlsen E, Tveit KM (2010) Late side effects and quality of life after radiotherapy for rectal cancer. Int J Radiat Oncol Biol Phys 76 (4):1005-1011. doi:10.1016/j.ijrobp.2009.03.010

29. Juul T, Ahlberg M, Biondo S, Emmertsen KJ, Espin E, Jimenez LM, Matzel KE, Palmer G, Sauermann A, Trenti L, Zhang W, Laurberg S, Christensen P (2014) International validation of the low anterior resection syndrome score. Ann Surg 259 (4):728-734. doi:10.1097/SLA.0b013e31828fac0b

30. Larsen SG, Pfeffer F, Korner H, Norwegian Colorectal Cancer G (2019) Norwegian moratorium on transanal total mesorectal excision. Br J Surg 106 (9):1120-1121. doi:10.1002/bjs.11287

Figures

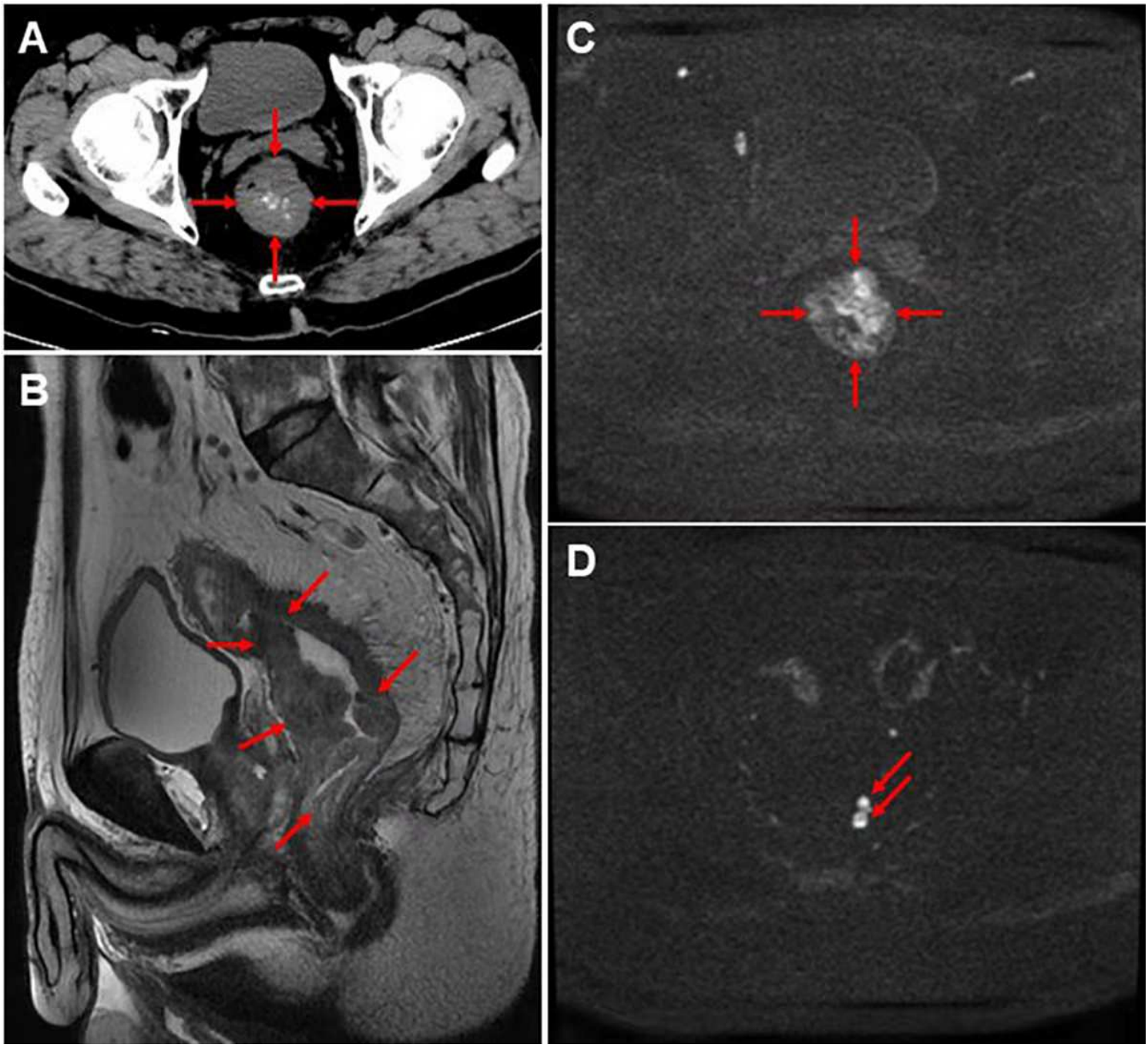

Figure 1

located 30 mm from anal margin(Figure 1B,C). In addition, some suspected lymph nodes were also observed by MRI (Figure 1D). The mesorectum fascia (MRF) and extramural vascular invasion (EMVI) was positive and the preoperative stage was T2N2bM0.

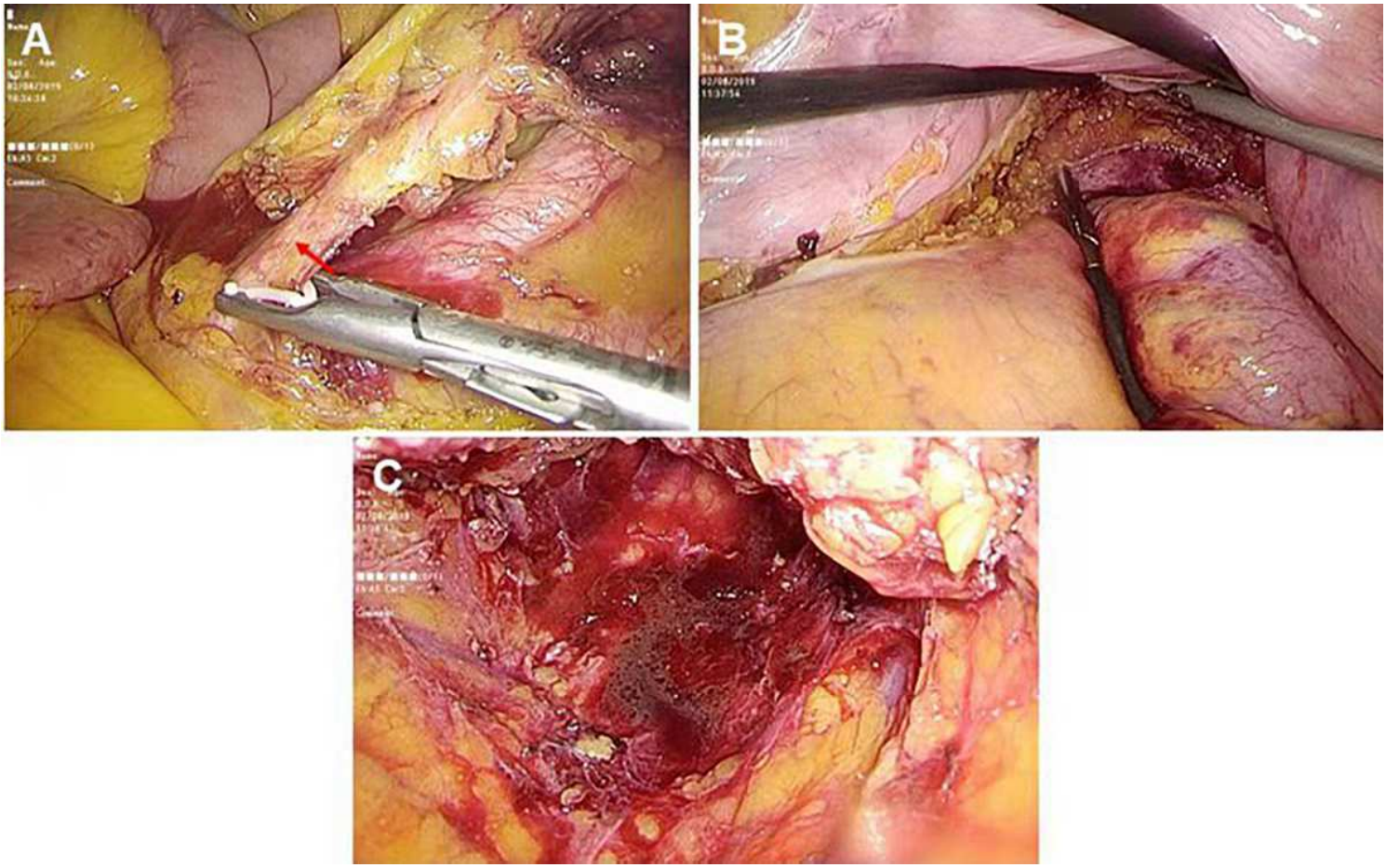

Figure 2

The origin of inferior mesenteric artery (IMA) was ligated and lymphadenectomy around IMA was done after patient was placed in the right-head-ventral position to achieve optimal view of the left colon. (Figure 2A) Dissect the left side colon to splenic flexure of colon with the medial-lateral retroperitoneal approach. The anterior mesorectum dissection was progressed to the level of seminal vesicles anteriorly (Figure 2B) and the posterior mesorectum dissection was progressed the level of 5th sacral or caudal vertebrae. (Figure 2C)

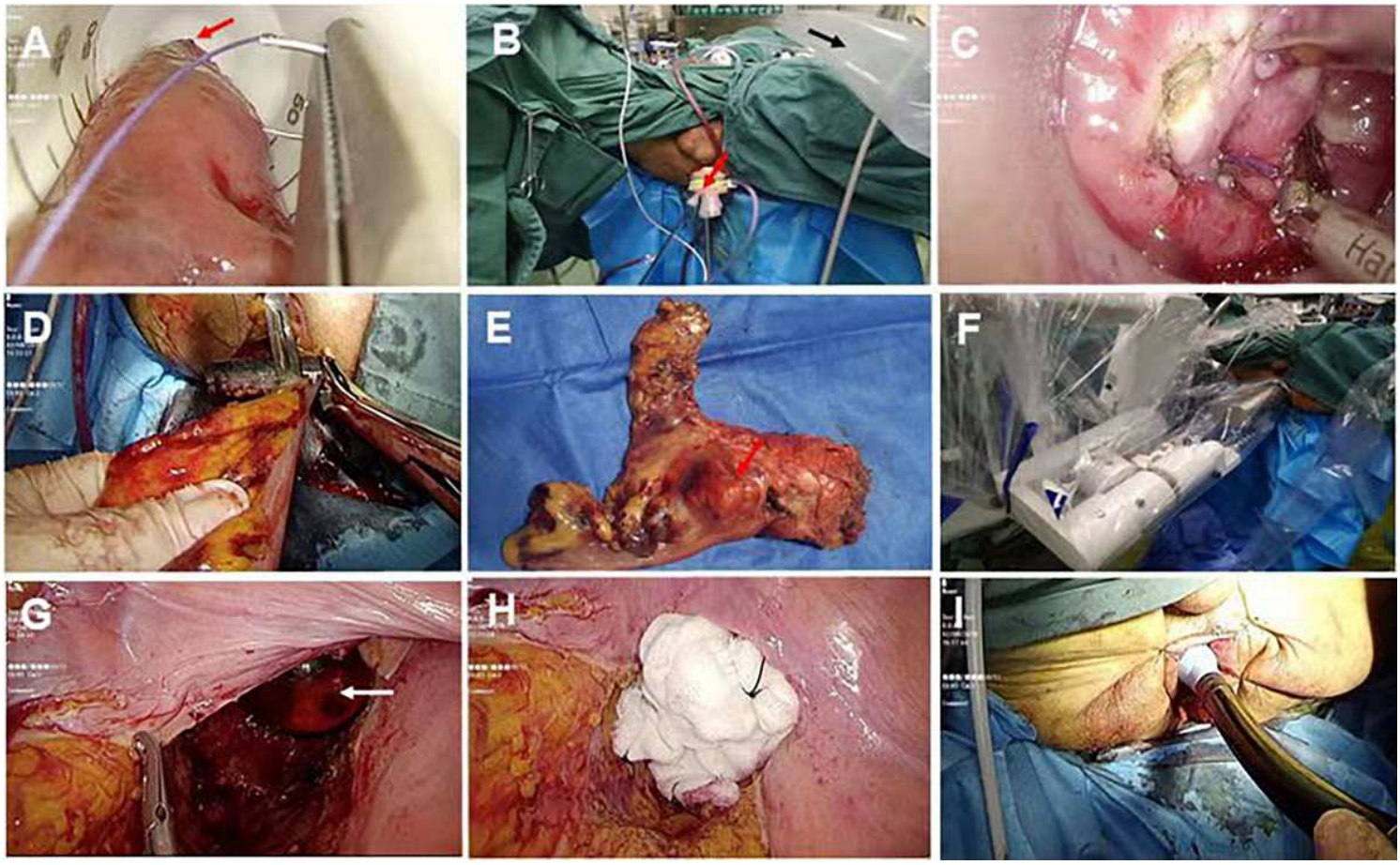

Figure 3

Under direct surveillance, purse-string suture was performed at 1 cm from the lower edge of tumor to close the rectal cavity and created an operating cavity. (Figure 3A) Connect the laparoscopinc pneumatic machine and the transanal operation platform pushed into anus to reach a stable pressure of the operating cavity in 13 mmHg. (Figure 3B) In this study, we used the plastic bag to connect the laparoscopic pneumatic machine to the transanl operation platform to obtain a stable pressure. Under laparoscopic surveillance, dissect the full thickness of rectal wall circumferentially (Figure 3C) and the mesorectum along the “holy plane” between the visceral and parietal layers of pelvic fascia to meet the transabdominal dissection plane. After the rectal mass was dragged up transanally, the proximal sigmoid colon was fixed by the purse-string forceps and cut off by scalpel to remove the rectal specimen (Figure 3D), and the top part of stapler was inserted into the colon. The dissected rectal specimen was photographed (Figure 3E). Based on the width of anus, 4-cm in diameter applicator was pushed into the tumor bed transanally (Figure 3F,G). Under the transabdominally laparoscopic surveillance, the applicator was pushed closely to the tumor bed and wet gauzes were put to isolate and protect the adjacent structures from radiation (Figure 3H). IORT was operated with a prescribed dose of 18 Gy. Purse-string suture was performed at distal resection site of the intestinal tissue and the digestive continuity was restructed by the circular stapler (Figure 3I). Prophylactic ileostomy was performed synchronously.