Stability of anterior segments in patients with moderate and high myopia one year after SMILE

Cheng Lei (chenglei2003new@163.com)
Xuzhou No.1 People's Hospital
Zhu Yuhao
Xuzhou Medical College
Zhu Ran
Xuzhou No.1 People's Hospital
Song Chao
Xuzhou No.1 People's Hospital

Research Article

Keywords: SMILE, Pentacam AXL anterior segment analyzer, corneal surface elevation , Q value, anterior chamber depth, anterior chamber volume, anterior chamber angle

Posted Date: July 20th, 2022

DOI: https://doi.org/10.21203/rs.3.rs-1847134/v1

Abstract

Background: SMILE is one of the most leading-edge corneal refractive surgery.In our study, we aim to investigate the stability of anterior segments in patients with moderate and high myopia one year after SMILE.

Methods: 30 eyes of 15 patients who underwent SMILE surgery from July 2020 to January 2021 were collected, including 7 males and 8 females, aged from 20 to 37 years (average 27.20 ± 5.40 years old). Pentacam AXL anterior segment analyzer was performed before operation, 1 month and 1 year after operation to measure the relevant data of anterior segments, including the elevation of posterior corneal surface, Q value of anterior and posterior corneal surface (8mm), curvature of anterior and posterior corneal surface, central anterior chamber depth (ACD), anterior chamber volume and peripheral anterior chamber angle (ACA).

Results: all the operations were successful without complications. There were significant differences in preoperative and postoperative equivalent spherical lens, average curvature(km) of anterior and posterior corneal surface , posterior elevation at the thinnest corneal point and Q value of anterior and posterior corneal surface (F = 755.055, $P < 0.05$; F = 700.001, $P < 0.05$; F = 3.494, $P = 0.037$, $P < 0.05$; F = 8.374, $P = 0.001$; F = 393.012, $P < 0.05$; F = 28.179, $P < 0.05$). There was no significant difference in posterior elevation at the apex corneal point(F = 0.301, $P = 0.693$ 0.05); Among them, there was significant difference in equivalent spherical lens,posterior elevation at the thinnest corneal point , Q value of anterior and posterior corneal surface between before operation and two points of time after operation ($P < 0.05$), and there was no significant difference between the two points of time after operation ($P = 0.051,1.000,0.805,0.531 > 0.05$); The pairwise comparison between the three groups were statistically significant in the mean corneal anterior surface curvature ($P < 0.05$); There was significant difference in the mean corneal posterior surface curvature between preoperative and 1 month after operation ($P = 0.047 < 0.05$), but there was no significant difference between preoperative and 1 year after operation, between 1 month after operation and 1 year after operation (P=0.117,1.000>0.05);The pairwise comparison among three groups were not statistically significant ($P = 1.000 > 0.05$); There were significant differences in anterior chamber depth (ACD), anterior chamber volume (ACV) and anterior chamber angle (ACA) before operation and 1 month 1 year after operation (F = 52.649,95.697,10.520, $P < 0.05$); There was significant difference in ACD and ACV between before operation and two times after operation ($P < 0.05$); There was no significant difference in ACA between before operation and 1 month after operation ($P = 0.297 > 0.05$), but there was significant difference in ACA between before operation and 1 year after operation, 1 month after operation and 1 year after operation ($P = 0.001,0.035 < 0.05$).

Conclusions: the corneal surface morphology before and after SMILE will change in the early stage, but it will gradually stabilize in the medium and long term, and the anterior chamber parameters change, which needs more attention.

Background

Femtosecond small-incision lenticule extracion (SMILE) is one of the most leading-edge corneal refractive surgery. SMILE is a flap-free intrastromal refractive procedure which is currently considered to be less invasive to the corneal biomechanics and with high safety[1-2]. Meanwhile the superiority of SMILE in visual quality and neural repair have been widely reported[3-5]. However, whether the structure of eyeball after corneal refractive surgery would be affected remains controversial , especially for changes in the anterior segment. In particular, only few studies have researched the morphological changes of the anterior segment in the medium and long term after SMILE. In our study, we aim to investigate the stability of anterior segments in patients with moderate and high myopia one year after SMILE.

Materials And Methods

1.1 General materials Retrospective analysis was used in this study.30 eyes of 15 patients who met the surgical indications and underwent SMILE in our hospital during July 2020 to January 2021 were collected , including 7 males and

8 females aged from 20-37 years(mean27.20±5.40 years old). Patients had the following characteristics:1) dioptric power<-8 00D, ≥ -3.00 astigmatism <-3.00D; 2)Age≥ 18 years , best corrected visual acuity(BCVA) ≥ 0.8;3) the central corneal thickness > 500 μm, and the residual stromal thickness after treatment was estimated to be > 250 μm.

Spherical equivalent of patients were from -3.5 D to -10.00 D mean -4.913 ± 0.990D .The preoperative corrected vision were ≥0.8. All patients underwent routine preoperative examinations to exclude surgical contraindications.

All procedures adhered to the tenets of the Declaration of Helsinki, and was approved by an Ethics Committee of Xuzhou First People's Hospital (No. xyyll[2021]-XJSXZ-026). Written informed consent for study participation was obtained from all participants.

1.2 Preoperative examinations

1.2.1 Routine examinations: Routine examinations included measurement of manifest refraction RT-5100 Nidek Co.Ltd. Gamagori,Japan Tonometry TX-20 Canon Inc.,Japan ,Pentacam AXL anterior segment analyer (Oculus pentacam AXL,Oculus,Germany),mydriatic optometry,funduscopy(Ocular 90D OCUL USA).

1.2.2 Examination methods of Pentacam AXL Anterior Segment Analyzer: Pentacam AXL Anterior Segment Analyzer was performed independently by the same experienced optometrist :the patient took a sitting position, placing his mandible on the mandible pad, and looked at the fixed target with a blue light band in the center of the rotation axis. The examiner used the operating lever to aim and focus following the on-screen prompt (the patient was required to blink 1 to 2 times quickly to make sure the tear film was evenly distributed.). During the measurement ,the patient should try to open their eyes and keep their eyes still. Data were collected in a dark room. Only the test results that QS showed OK were accepted.

1.3 Surgical procedure: All procedures were performed by the same experienced surgeon.A Visumax femtosecond laser platform was used for the SMILE procedure. All the operations were successful with no complications. The parameters were set as follows: the lenticule diameter was 6.5mm,the cap thickness was 120mm, the cap diameter was 7.5mm and the side-cut was 2mm.The femtosecond laser platform was used to create the stromal lenticule. The lenticule was separated and extracted through the small incision. At last the corneal stromal bed was clean with a balanced salt solution.

1.4 Postoperative examination

Routine examinations were scheduled for 1 month,3 months,6 months and 1 year after operation, including uncorrected visual acuity, computer optometry, introcular pressure and slit-lamp examination. Pentacam AXL anterior segment analyzer was performed 1 month and 1 year after operation.

1.5 Statistics analysis: Statistics analysis was performed by using an SPSS software package(version 26.0 SPSS, Chicago, IL,USA).The method of boxplot drawing was designed to judge and exclude the abnormal distribution, expressed as mean± SD. Repeated measurement of one-way ANOVA was used to compare the overall differences. Multiple comparison was performed by Bonferroni test. Pearson general linear correlation analysis method was used to analyze the correlation between the difference of anterior chamber parameters and the depth of cornea ablation. Differences were considered statistically significant when the P value was less than 0.05.

Results

2.1 General information

The general data of all patients could be showed in table 1.

Table1 general data (mean±SD

	Age（years）	Preoperative corneal thickness（μm）	Corneal ablation depth（μm）
Mean±SD	27.20±5.40	546.367±26.492	104.367±15.386

2.2 Comparison of corneal morphology related data

Corneal morphology related data was shown in Table 2:There were statistically significant differences in preoperative and postoperative equivalent spherical lens, average curvature(km) of anterior and posterior corneal surface , posterior elevation at the thinnest corneal point and Q value of anterior and posterior corneal surface (F = 755.055, $P < 0.05$; F = 700.001, $P < 0.05$; F = 3.494, $P = 0.037$, $P < 0.05$; F = 8.374, $P = 0.001$; F = 393.012, $P < 0.05$; F = 28.179, $P < 0.05$). There was no significant difference in posterior elevation at the apex corneal point(F = 0.301, $P = 0.693$ 0.05); Among them, there was significant difference in equivalent spherical lens, posterior elevation at the thinnest corneal point , Q value of anterior and posterior corneal surface between before operation and two points of time after operation ($P < 0.05$), and there was no significant difference between the two points of time after operation ($P = 0.051,1.000,0.805,0.531 > 0.05$); The data of pairwise comparison was shown in Table 3 and pairwise comparison between the three groups were statistically significant in the mean corneal anterior surface curvature ($P < 0.05$); There was significant difference in the mean corneal posterior surface curvature between preoperative and 1 month after operation ($P = 0.047 < 0.05$), but there was no significant difference between preoperative and 1 year after operation, between 1 month after operation and 1 year after operation (P=0.117,1.000>0.05); The pairwise comparison among three groups were not statistically significant ($P = 1.000 > 0.05$).

Table 2 Comparison of corneal morphology related data mean±SD

	Preoperative	1 mouth follow-up	1 year follow-up	F Value	*P* Vaule
Spherical equivalent D	-4.913±0.990	0.216±0.362	0.000±0.432	755.055	0*
Mean curvature of anterior corneal surface	43.093±1.427	38.790±1.330	39.000±1.286	700.001	0*
Mean curvature of posterior corneal surface	-6.307±0.267	-6.290±0.278	-6.290±0.252	3.494	0.037*
Posterior elevation at the apex corneal surface	2.23±2.046	2.37±2.822	2.470±3.048	0.301	0.693
Posterior elevation at the thinnest corneal point	4.5±2.193	3.47±2.662	3.270±2.741	8.374	0.001*
Q value of the anterior corneal surface 8mm	-0.369±0.107	0.512±0.254	0.493±0.248	393.012	0*
Q value of the posterior corneal surface 8mm	-0.339±0.098	-0.287±0.0916	-0.295±0.082	28.179	0*

Compared with preoperative value *P<0.05

Table 3 Pairwise comparison with Bonferroni test

Time comparison		Preoperative/1 month follow-up	Preoperative/1 year follow-up	1 month follow-up/1 year follow-up
Spherical equivalent	P value	0.000*	0.000*	0.051
Mean curvature of anterior corneal surface		0.000*	0.000*	0.001*
Mean curvature of posterior corneal surface		0.047*	0.117	1
Posterior elevation at the apex corneal surface		1	1	1
Posterior elevation at the thinnest corneal point		0.009*	0.007*	1
Q value of the anterior corneal surface 8mm		0.000*	0.000*	0.805
Q value of the posterior corneal surface 8mm		0.000*	0.000*	0.531

Multiple comparison was performed by Bonferroni test,*P<0.05

2.3 Changes in morphology anterior chamber

The data of morphology anterior chamber was shown in Table 4:There were significant differences in anterior chamber depth (ACD), anterior chamber volume (ACV) and anterior chamber angle (ACA) before operation ,1 month after operation and 1 year after operation (F = 52.649,95.697,10.520, $P < 0.05$); The data of pairwise comparison was shown in Table 5.There was significant difference in ACD and ACV between before operation ,1 month after operation and 1 year after operation ($P < 0.05$); There was no significant difference in ACA between before operation and 1 month after operation ($P = 0.297 > 0.05$), but there was significant difference in ACA between before operation and 1 year after operation, 1 month after operation and 1 year after operation ($P = 0.001,0.035 < 0.05$)(see Table 5)

Table 4 Comparison of anterior chamber morphology related data

Time comparison	Preoperative	1 mouth follow-up	1 year follow-up	F Value	*P* Value
Anterior chamber depth ACD	3.042±0.237	2.970±0.231	2.914±0.250	52.649	0.000*
Anterior chamber volume(ACV)	180.900±23.859	174.267±23.644	159.867±23.027	95.697	0.000*
Anterior chamber angle (ACA)	39.127±6.047	38.537±5.422	36.900±5.604	10.52	0.001*

Compared with preoperative value *$P<0.05$

Table 5 Pairwise comparison with Bonferroni test

Time comparison		Preoperative/1 month follow-up	Preoperative/1 year follow-up	1 month follow-up/1 year follow-up
Anterior chamber depth ACD	*P*	0.000*	0.000*	0.000*
Anterior chamber volume(ACV)		0.001*	0.000*	0.000*
Anterior chamber angle (ACA)		0.297	0.001*	0.035*

Bonferroni test was used for multiple comparisons,*$P<0.05$

2.4 Analysis of the correlation between the difference of anterior chamber parameters and the depth of ablation:

There was no significant correlation between difference in ACD between before operation and 1 month after operation and depth of ablation (r=- 0.044, P=0.817), and as shown in Fig 1, there was a significant correlation between difference in ACD between before operation and 1 year after operation and depth of ablation (r=- 0.405, P =0.026); There was no significant correlation between difference in ACV, ACA 1 month and 1 year after operation and depth of ablation (r=-0.311, -0.143; P =0.095, 0.451; r=-0.011, 0.270 ; P =0.955, 0.149>0.05).

Discussion

Currently, femtosecond laser is the mainstream procedure of corneal refractive surgery, and the emergence of femtosecond small-incision lenticule extracion has brought femtosecond laser surgery into the flap-free era, which avoids the possible complications of FS-LASIK ,brings better biomechanics and reduces the occurrence of dry eye[6-7].The safety and effectiveness of SMILE surgery has been recognized by many experts and scholars [1-2]. However, it may have a certain impact on the anterior segment. To date, there have been few related reports, and the observation time was short[8-9]; changes in the anterior chamber structure may have an impact on the occurrence and management of intraocular diseases in patients. Pentacam, one of the most widely used instruments for detecting the corneal morphology, is a new anterior segment analysis system introduced by OCULUS, a German company, which uses a 360° rotating probe to scan the anterior segment of the eye and obtain Scheimpflug images. Rotation allows better access to the data of corneal morphology, especially for the posterior corneal surface [10]. Since the refractive surgery, including SMILE, has been performed in the anterior corneal stromal, it directly changes the curvature and morphology of the anterior corneal surface. However the changes of posterior corneal surface are not directly caused by the surgery but could be caused by intraocular pressure and the thinner cornea [11]. In our study, we found statistically significant changes in the curvature of anterior and posterior corneal surface before and after surgery (F=700.001, P <0.05; F=3.494, P <0.05), indicating that the curvature of posterior surface also changed after SMILE. However the curvature of posterior corneal surface stabilized 1 year after surgery, and the difference was not statistically significant between preoperative and 1 year after operation(preoperative/1 month or 1 year after operation, P=0.117,1.000).That means the curvature of posterior corneal surface became stable in medium and long term after SMILE. The result was in agreement with the study by Manrong Yu et al [12], who found no statistically significant difference in curvature of posterior corneal surface between preoperative and 3 months after operation.However they also found a trend toward flattening of the posterior surface at 3 years after SMILE (preoperative - 6.22 ± 0.23,3 years after operation - 6.17 ± 0.24), which needs to be further observed.

In our study,we found that there was no statistically significant difference in preoperative and postoperative posterior elevation at the apex corneal surface (F=0.301, P =0.693), but there was statistically significant difference in the posterior elevation at the thinnest corneal point (F=8.374, P =0.001);there was also a statistically significant difference between preoperative and time points after operation P=0.009 0.008 , and the posterior elevation at the thinnest corneal point decreased (4.5±2.193, 3.47±2.662, 3.270±2.741) gradually over three time points. This was in agreement with the

results of Yu Zhao et al. [13], who found that there was no statistically significant difference in the posterior elevation at the apex corneal surface before and 3 years after SMILE, while there was statistically significant difference in the posterior elevation at the thinnest corneal point, which was considered that the steepening of the peripheral corneal stroma and flattening of the central corneal stroma caused mild hyperopia drift. Changes in posterior elevation at the apex corneal surface and posterior elevation at the thinnest corneal point showed that the corneal posterior surface was relatively stable in the medium and long term after SMILE.

Q value of the corneal surface is a significant parameter to reflect the state of aspherical corneal surface . The normal cornea of human eye becomes flattened from the center to the periphery, which is prolate oval, so the Q value is negative. Amelia Nieto-Bona et al. [14] measured 118 healthy eyes and found that Q values ranged from -0.83 to -0.01. After different corneal refractive surgery, the central cornea flattens, changing the state of the corneal asphericity, and the Q value of the anterior corneal surface often changes from negative to positive [15].Zhang Wenwen et al.[16] argued that the change of Q value of the anterior corneal surface after SMILE was smaller than that of SBK, and was negatively correlated with the preoperative spherical equivalent .Our study also found that the negative value of Q value of the anterior corneal surface decreased after SMILE, and the difference was statistically significant compared with the Q value before operation($P < 0.05$).Q value
of the anterior corneal surface was relatively stable from 1 month to 1 year after SMILE (-0.287 ±0.0916, -0.295±0.082)and there was no significant difference (P =0.805> 0.05).The Q value of the posterior corneal surface also changed (preoperative Q value=-0.339±0.098, Q value 1 month after operation= -0.287±0.0916, Q value1 year after operation=-0.295±0.082),and the difference was statistically significant before and after operation (F=28.179, P <0.05)while the difference was relatively stable from 1 month to 1 year after surgery and the difference was not statistically significant (P=0.531>0.05), The data above was in agreement with the observation of Lin Zhang et al.[17] that the negative value of Q value of the posterior corneal surface decreased 6 months after SMILE. It was considered that although the posterior corneal surface was relatively stable after SMILE, there was still a slight backward movement, which was consistent with the changes of posterior elevation at the thinnest corneal point.

Many reports [18-19] found that the ACD became shallower after corneal refractive surgery, and many paper believed that factors affecting ACD included age, corneal diameter, pupil diameter and lens thickness, while there was no significant correlation with intraocular pressure and corneal thickness [20-22]. In our study, we found that both ACD and ACV decreased after SMILE (ACD 2.970±0.231, 2.914±0.250ACV174.267±23.644, 159.867±23.027). Compared with that before operation(ACD3.042±0.237,ACV180.900±23.859), the difference was statistically significant; as time went by, postoperative ACD and ACV were still changing, and the differences were statistically significant (P<0.05). At the same time, we also found that there was no significant difference in ACA between 1 month after operation and preoperative (P =0.297), and there was significant difference in ACA between
1 year after operation and preoperative or 1 month after operation (P=0.001,0.035<0.05). This result ,however ,was slightly different compared to the results of Yang Dandan et al[23]. they found statistically significant difference in ACD, ACV, ACA of high myopia group between 1 month after operation and preoperative , but there was no statistically significant difference in ACA of low and moderate myopia between 1 month after operation and preoperative, which was different from the change of ACA in our study and may be associated with different groups of diopter. The changes of ACD and ACV are believed to be related to the backward movement of the posterior corneal surface[10];on the other hand, postoperative patients are often in a state of emmetropia or mild hyperopia, which requires accommodation in near vision, resulting in the increasing in lens thickness[24-25], and reduction in ACD and ACV. However, the changes of ACA should be considered if the changes of the posterior corneal surface and the anterior chamber mainly occurred in the central corneal ablation area in the early postoperative period, and had little effect on the peripheral ACA. Some studies found that there was no statistically significant difference in the peripheral anterior chamber angle of patients with low or medium myopia between 3 months after FS-LASIK compared with that before surgery[18], which was in agreement with what we have found. However, as time went by, the ACD decreased further, which would also have certain influence on the peripheral

structure.In addition, whether it was related to the increase of lens thickness and forword movement of lens needs to be further explored.

In addition, we found that although the changes of ACV and ACA were not significantly correlated with the ablation depth, there was a certain correlation between the changes of ACD and the ablation depth one year after surgery . It indicated that the greater the ablation depth is, the greater the changes of ACD will be. It also reminded us to make a reasonable choice when choosing SMILE surgery, and the ablation depth must be strictly controlled.

This study investigated the changes of anterior segment parameters in patients with moderate to high myopia 1 year after SMILE and found that although the curvature of the anterior and posterior corneal surfaces would change in the early postoperative stage after SMILE, it would gradually become stable in the medium and long term. At the same time, the elevation of posterior corneal surface decreased. However, the anterior chamber, especially the ACD, changed significantly, and it was still changing 1 year after the operation. At the same time, there are some limitations in the present study. For example, the sample size was relatively small and this study was not grouped by diopter.We could expand the sample size and prolong the observation time for further observation.

Declarations

1 This study was conducted in accordance with the principles of the Declaration of Helsinki and was approved by the Ethics Committee of Xuzhou No.1 People's Hospital(No. xyyll[2021]-XJSXZ-026). Written informed consent was

obtained from all participants. .

2 Consent for publication

Not applicable

3 Availability of data and materials

The data and Materials are available upon request from the corresponding

author at chenglei2003new@163.com

4 Competing interests

The authors declare that there is no competing interest.

5 funding

The study was supported by Xuzhou No.1 People's Hospital

6 Authors’ contributions

Literature screening and selection was performed by Cheng lei and zhu yuhao partici

pated in the design of the study. Zhu Ran and Song Chao collected the data .

7Acknowledgements

The authors thank all the patients participating in the study.

8 Author details

1 Xuzhou No.1 People's Hospital, China

2 Xuzhou Medical College ,China

References

1. Kaiwei Cao Lina Liu Ting Yu et al.Changes in corneal biomechanics during small-incision lenticule extraction (SMILE) and femtosecond-assisted laser in situ keratomileusis (FS-LASIK) .Lasers Med Sci. 2020 Apr;35(3):599-609.doi: 10.1007/s10103-019-02854-w.
2. Ang M, Gatinel D, Reinstein DZ et al. Refractive surgery beyond 2020.Eye (Lond). 2021 Feb;35(2):362-382. doi: 10.1038/s41433-020-1096-5.
3. FeiXia,YangShen,TianHan.Small Incision Lenticule Extraction(SMILE)for Moderate and High Myopia:Seven-Year Outcomes of Refraction,Corneal Tomography,and Wave front Aberrations.Journal of Ophthalmology.2020 Apr 22:3825864. doi: 10.1155/2020/3825864.
4. Suphi Taneri, Saskia Kießler, Anika Rost.Small incision lenticule extraction for the correction of high myopia .Eur J Ophthalmol. 2020 Sep;30(5):917-927. doi: 10.1177/1120672119861481.
5. Yuan Sun, Ting Zhang, Manli Liu et al.Early Corneal Wound Healing Response After Small Incision
6. Lenticule Extraction .Cornea. 2019 ;00:1-7.doi: 10.1097/ICO.0000000000002105.
7. Asif MI, Bafna RK, Mehta JS, *et al*. Complications of small incision lenticule extraction. Indian J Ophthalmol. 2020 Dec;68(12):2711-2722. doi: 10.4103/ijo.IJO_3258_20.
8. Zhang YL, Cao LJ, Chen HW,et al.
9. Comparison of changes in refractive error and corneal curvature following small-incision lenticule extraction and femtosecond laser-assisted *in situ* keratomileusis surgery. Indian J Ophthalmol 2018;66:1562-7. doi: 10.4103/ijo.IJO_366_18.
10. Bu Ki Kim, Su Joung Mun, Young Hoon Yang et al.Comparison of anterior segment changes after femtosecond laser LASIK and SMILE using a dual rotating Scheimpflug analyzer .BMC Ophthalmology.2019;19:251.doi.org/10.1186/s12886-019-1257-0.
11. Junjie Wang, Bernardo T. Lopes, Hechen Li ,et al.Unintended changes in ocular biometric parameters during a 6-month follow-up period after FS-LASIK and SMILE .Eye and Vision.2021;8:9.doi.org/10.1186/s40662-021-00232-8.
12. Mahsaw N Motlagh , Majid Moshirfar, Michael S Murri et al.Pentacam® Corneal Tomography for Screening of Refractive Surgery Candidates: A Review of the Literature, Part I.Med Hypothesis Discov Innov Ophthalmol. 2019;8(3):177-203.
13. Twa MD, Nichols JJ, Joslin CE,et al. Characteristics of corneal ectasia after LASIK for myopia. Cornea. 2004;23:447–57. doi: 10.1097/01.ico.0000122702.49054.12.
14. Manrong Yu,Minjie Chen,Jinhui Dai.Comparison of the posterior corneal elevation and biomechanics after SMILE and LASEK for myopia:a short-and long-term observation.Graefe's Archive for Clinical and Experimental Ophthalmology.2019;257(3):601-606.doi:10.1007/s00417-018-04227-5.
15. Yu Zhao, Weijun Jian, Yingjun Chen et al.Three-Year Stability of Posterior Corneal Elevation After Small Incision Lenticule Extraction (SMILE) for Moderate and High Myopia.J Refract Surg. 2017;33(2):84-88.doi: 10.3928/1081597X-20161117-01.
16. Amelia Nieto-Bona,Amalia Lorente-Velázquez,Robert Mòntes-Micó.Relationship between anterior corneal asphericity and refractive variables.Graefes Arch Clin Exp Ophthalmol
17. . 2009 Jun;247(6):815-20.doi: 10.1007/s00417-008-1013-2.

18. Yanli Zhang,XianghuiXu,Lei Liu ,et al. Comparison research of FS-LASIK and SMILE on anterior corneal asphericity. Int Ophthalmol 2019 19(12):
19. 2107 2110 .DOI:10.3980/ j.issn.1672 5123.2019.12.25.
20. Wenwen Zhang,Jianru Cai,Xinliang Cheng ,et al. Changes in the anterior corneal surface morphology after SMILE. Chinese Journal of Optometry Ophthalmology and Visual Science 2017;19 7 .421-427.doi
21. 10.3760/cma.j.issn.1674-845X.2017.07.007.
22. Lin Zhang Yan Wang Wei Zhao ,et al.Corneal remodeling and spatial profiles following small
23. incision lenticule extraction .Int Ophthalmol .2019;39:1827–1836 .doi.org/10.1007/s10792-018-1010-3 .
24. Lei Cheng,Ran Zhu,Danmei Wang,et al.Early changes of anterior chamber parameters after FS-LASIK Int Ophthalmol. 2015; 15(3) : 432 435 .DOI: 10 3980 /j issn 1672 5123 2015 3 14 .
25. Kunert KS Blum M eich M et al Effect of a suction device for femtosecond laser on anterior chamber depth and crystalline lens position measured by OCT J efract Surg 2009; 25(11) : 1005 1011. doi: 10.3928/1081597X-20091016-06.
26. absilber TM Becker KA Frisch IB et al Anterior chamber depth in relation to refractive status measured with the Orbscan II Topography System J Cataract efract Surg 2003; 29(11) : 2115 2121 .doi:10.1016/S0886-3350(03)00409-7.
27. Ryo Nishimura, Kazuno Negishi, Murat Dogru,et al.Effect of age on changes in anterior chamber depth and volume after laser in situ keratomileusis.J Cataract Refract Surg
28. . 2009 Nov;35(11):1868-72. doi: 10.1016/j.jcrs.2009.06.022.
29. Hashemi H Yazdani K Khabazkhoob M et al Distribution of photopic pupil diameter in the Tehran eye study Curr Eye es 2009; 34(5) : 378 385 .DOI: 10.1080/02713680902853327.
30. Dandan Yang,He Yin,Jingkai Peng,et al.Changes of anterior chamber morphology after SMILE. Int Ophthalmol . ; ( ) 869-873. : . / . . . . . .
31. Ke Zheng,Tian Han,Xingtao Zhou.Accommodative changes after SMILE for moderate to high myopia correction.BMC Ophthalmol. 2016 Oct 4;16(1):173.doi: 10.1186/s12886-016-0352-8.
32. Yao Ni,Xia-Lin Liu,Ming-Xing Wu,et al.Objective evaluation of the changes in the crystalline lens during accommodation in young and presbyopic populations using Pentacam HR system.Int J Ophthalmol. 2011;4(6):611-5. doi: 10.3980/j.issn.2222-3959.2011.06.07.

Figures

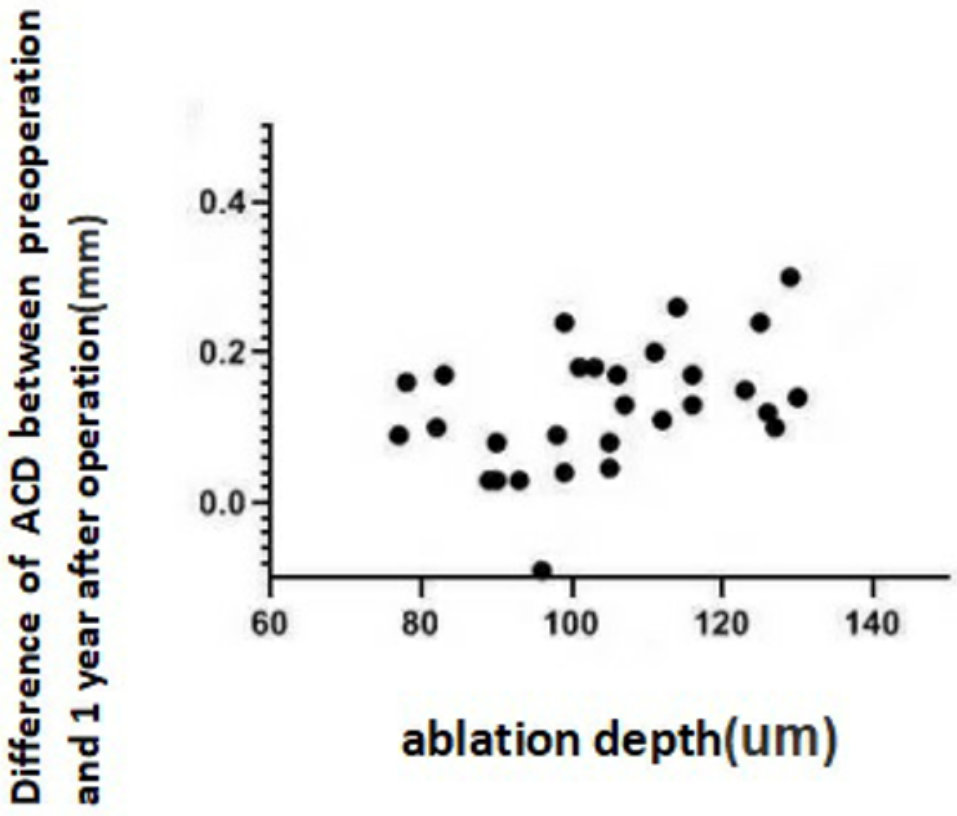

Figure 1

scatter diagram of correlation between difference in ACD and depth of ablation