# Assessment of the Relationship between the Maxillary Sinus and the Canine Root tip using Cone Beam Computed Tomography

**Leila Khojastepour**
Shiraz University of Medical Sciences

**Najmeh Movahhedian** ( movahedian@sums.ac.ir )
Shiraz University of Medical Sciences

**Mohadeseh Zolghadrpour**
Shiraz University of Medical Sciences

**Research Article**

**Keywords:** Maxillary Sinus, Anterior extension, Canine apex, Incisor, Cone beam computed tomography

**Posted Date:** February 11th, 2021

**DOI:** https://doi.org/10.21203/rs.3.rs-184809/v1



**Version of Record:** A version of this preprint was published at BMC Oral Health on July 10th, 2021. See the published version at https://doi.org/10.1186/s12903-021-01700-2.

# Abstract

**Background:** The purpose of the present study is to investigate the frequency and amount of extension of the maxillary sinus to the anterior region and to evaluate the vertical distance between the maxillary sinus floor and canine apices.

**Methods:** Cone beam computed tomographic images of 300 individuals (154 males and 146 females) over 20 years (with mean age of 35.12 ± 8.40 years) were evaluated. The subjects were categorized into three age groups (20-30, 30-40 and 40-50 years). When maxillary sinus extended to the canine area, the vertical distance between them were recorded and their relationship were classified into three types: I (> 2 mm distance), II (2 mm < distance or in-contact) and III (interlock).

**Results:** 413 out of 600 maxillary sinuses (68.8%) were extended into the canine area or beyond. Among them, 15 maxillary sinuses pneumatized into the incisor area (2.5%). The prevalence of the maxillary sinuses extended to the anterior region of the jaw was not significantly different between genders, but it was significantly less frequent in older age group and more frequent in the left side. The mean amount of anterior extension of maxillary sinus (mm) was significantly lower in older age group. Type I was the most frequent vertical relationship between the maxillary sinuses and canine apices with no significant difference in gender, side and age groups.

**Conclusions:** Most of the maxillary sinuses extended to the canine area. Maxillary sinus extended into incisor area with the frequency of 2.5% . The amount of extension of the maxillary sinus to the anterior region and its vertical distance with canine apices decreased in older age group.


# Background

The maxillary sinuses are the largest paranasal sinuses which are very small at birth, but expand by physiologic pneumatization until completion of skeletal development[1], or around the age of 20 years[2]. The maxillary sinus often extends from the distal aspect of the canine tooth to the posterior wall of the maxilla above the tuberosity[3]. Occasionally, practitioners encounter pneumatization of the anterior part of the maxilla by sinus extension misinterpreted as a cystic lesion on the intraoral or panoramic radiographs[4]. The relationship between the maxillary sinus and dentition is important for dental procedures, particularly implant or apical surgeries and orthodontic treatment [5, 6]. Moreover, the close proximity between these structures leads to infectious spread from periodontal or peri-apical lesions to the maxillary sinus which may cause maxillary sinusitis [7-9].

Several studies evaluated the relationships between the posterior teeth and the maxillary sinus [4, 10-16]. While the anterior part of the maxilla is often assumed as a relatively safe region for surgical intervention, based on a recent cone beam computed tomographic (CBCT) study[4], the maxillary sinus extended to the canine region in 68.9% of cases and to the incisor region in 15.5%.

Two- or three-dimensional (2D or 3D) imaging has been used for evaluating the paranasal sinuses. However, in cases with accompanying signs and symptoms regarding sinuses or need for a thorough examination of the sinuses prior to surgeries, 3D imagings are the modalities of choice[9]. In this regard, CBCT provides accurate and distortion-free images of the craniofacial bones with lower absorbed radiation dose compared with multi-slice computed tomography [17-19].

To the best of the authors' knowledge, there are only few CBCT studies regarding the relationship of the anterior teeth and maxillary sinus [20, 21]. Therefore, the aim of the present study was to assess the location of the anterior border of the maxillary sinus in relation to the teeth and amount of anterior extension of the maxillary sinus (AEMS) beyond the canine tooth long axis. Moreover, the vertical distance between the maxillary sinus floor and canine apices was evaluated.

# Methods

This cross-sectional study was approved by the Human Ethics Review Committee of the Faculty of Dentistry, University of Medical Sciences. Shiraz, Iran (# IR Sums.Dental.REC.1399.020).

1430 CBCT scans of the patients who had referred to Oral & maxillofacial Department of Shiraz Dental School (since May 2017 to May 2020) were reviewed retrospectively. CBCT images were taken for different purposes other than the present study. Written consent had been taken at the time of radiographic examination from all the patients for probable use of their anonymous information in future studies. Personal information of all individuals was kept totally undisclosed. At the end, 300 scans (154 men and 146 women with a mean age of 35.12±8.40 years) met the study criteria.

To be included in the study, the field of view of the CBCT images should cover the entire maxilla of the individuals over 20 years and both maxillary canines should be completely erupted with closed apices. Exclusion criteria were distorted CBCT images due to metallic or motion artifacts, history of previous apical surgery, evidence of root resorption/fracture or bony pathologies, supernumerary/missing/extracted or impacted teeth in the maxillary anterior area, congenital anomalies, or severe jaw deformities. High-buccal canines, not being in line with the incisal/occlusal surface of the dentition, were also excluded from the study.

All CBCT images were obtained using New Tom Evo CBCT unit (QR S.R.L. Company, Verona, Italy) with the following technical parameters: 3 mA, 1.8 exposure time, 110 Kvp, 0.3 mm voxel size, axial pitch, and axial thickness of 0.3 mm. The Frankfort horizontal plane of all the subjects was parallel to the floor when acquiring the images. All the measurements were done using NNT software (NNT 9.2 Image Works, Verona, Italy) by two oral and maxillofacial radiologists with consensus. One third of CBCT scans (100) were re-evaluated by the same observers after a two-week-interval.

The study sample was categorized into three age groups: 20-30, 30-40, and 40-50 years. For each subject, the most anterior limit of the anterior border of the maxillary sinus was marked on the axial image. Then, panoramic views were reconstructed based on the curved line parallel to the dental arch at the cervical

area on the axial image. The axial and reformatted panoramic views served as the reference image for localization of the anterior limit of the maxillary sinus. Bucco-lingual cross-sections were prepared perpendicular to the dental arch with 0.5 mm thickness and interval (Fig 1). Then, the location of the anterior border of the maxillary sinus was recorded in relation to different teeth. In cases with maxillary sinus extension to the canine region, AEMS beyond the canine tooth long axis, the vertical relationship between the maxillary sinus floor and canine apices, and the absolute vertical distance between the maxillary sinus floor and floor of the nasal fossa (MS-NF) were evaluated.

The number of slices (cross-sections) with sinus pneumatization beyond the canine tooth long axis was counted and multiplied by the slice thickness (0.5 mm) to calculate the AEMS beyond the canine tooth long axis (AEMS=Number of slices × Slice thickness). For example, if the maxillary sinus pneumatization existed on 6 slices beyond the canine tooth long axis, the AEMS would be 3 mm (6×0.5) (Fig 2).

Vertical relationship between the maxillary sinus floor and canine teeth apices was assessed based on the following classification (Fig 3):

Type I: Apex located below the sinus floor with more than 2 mm distance

Type II: Apex located below the sinus floor with less than 2 mm distance or being in contact with it.

Type III: Apex located above the sinus floor (protruded into the maxillary sinus)

Figure 4 depicts how vertical distance between the floors of the maxillary sinus and the nasal fossa was measured.

# Statistical analyses

Statistical analyses were conducted using the SPSS software (version 20; IMB; Chicago; IL). Quantitative and qualitative variables were described by mean ± standard deviation (SD) and frequency (percentage), respectively. Chi-square test was used to compare the AEMS as well as the type of vertical relationship between the maxillary sinus floor and canine apex in different genders, sides and age groups. ANOVA test was performed for comparison of the mean distances (mm) between the MS-NF, and the anterior extension of maxillary sinus in different age groups. P value <0.05 was considered statistically significant. The intra-class correlation coefficient (ICC) was also used to evaluate the intra-examiner error.

# Results

CBCT images of 300 individuals (600 maxillary sinuses (met the study criteria and were evaluated. The mean age of the subjects was 35.12±8.40 years. The study sample consisted of 146 (48.7%) women with a mean age of 34.66±8.78 years and 154 (51.3%) men with a mean age of 35.56±8.03 years old. ICC was 96% which is considered a perfect agreement.

Out of 600 maxillary sinuses, 413 (68.83%) extended into the canine area or beyond. 15 sinuses (2.5 %), which belonged to 8 subjects, involved the incisor region. The location of the anterior border of the maxillary sinuses in relation to other teeth were as follows: 149 (24.83%) into the first premolar, 36 (6%) into the second premolar, and 2 (0.33 %) into the first molar area.

Sinus extension had bilateral symmetry in 244 individuals (81.33%) and was non-symmetrical in 56 (18.66%). Among the cases with symmetric sinus extension, 178 cases (59.33%) extended into canine region, and 66 cases (22%) extended posterior to the canine bilaterally.

Table 1 shows the frequency of the maxillary sinuses which extended to the anterior region in different genders, sides, and age groups. Anterior extension was significantly more frequent in the left side (P value = 0.006) and less frequent in the older age group (40-50 years old) (P value =0.001). No gender difference was found in the prevalence of anterior extension of the maxillary sinus (P value =0.377).

Table 1
Comparison of the number (N) and percent (%) of maxillary sinuses extended to the anterior region between genders, sides and age groups

| | | **Maxillary sinus extended to anterior part of the jaw** | | | **P Value*** |
|---|---|---|---|---|---|
| | | **+** | **-** | **Total** | |
| | | **N (%)** | **N (%)** | **N (%)** | |
| **Gender** | **M** | 207 (67.21) | 101 (32.79) | 308 (100) | 0.377 |
| | **F** | 206 (70.55) | 86 (29.45) | 292 (100) | |
| **Side** | **R** | 191 (63.67) | 109 (36.33) | 300 (100) | 0.006 |
| | **L** | 222 (74.00) | 78 (26.00) | 300 (100) | |
| **Age group** | **20-30** | 149 (74.50) | 51 (25.50) | 200 (100) | 0.001 |
| | **30-40** | 150 (75.00) | 50 (25.00) | 200 (100) | |
| | **40-50** | 114 (57.00) | 86 (43.00) | 200 (100) | |

Regarding the vertical relationship between the sinus floor and canine apices, type I was the most frequent. 351 out of 413 (84.99%) maxillary sinuses which were extended to the canine area had type I vertical relationship with the canine apices. Types II and III were noted in 37(8.96%) and 25 (6.05%) maxillary sinuses, respectively. As shown in Table 2, there were no significant differences between the vertical relationship of the maxillary sinus floor and canine apices in different genders, sides, and age groups (P value = 0.153, 0.355, and 0.111, respectively)

Table 2
Comparison of the number (N) and percent (%) of different types of vertical relationship between maxillary sinus floor and canine apices in different genders, sides and age groups

| | | Maxillary sinus and canine apex relation | | | Total | P Value* |
|---|---|---|---|---|---|---|
| **Variable** | | **Type I** | **Type II** | **Type III** | | |
| | | N (%) | N (%) | N (%) | | |
| **Gender** | **M** | 169 (81.64) | 23 (11.11) | 15 (7.25) | 207 (100) | 0.153 |
| | **F** | 182 (88.35) | 14 (6.79) | 10 (4.85) | 206 (100) | |
| **Side** | **R** | 160 (83.77) | 16 (8.37) | 15 (7.85) | 191 (100) | 0.355 |
| | **L** | 191 (86.03) | 21 (9.50) | 10 (4.52) | 222 (100) | |
| **Age group** | **20-30** | 124 (83.22) | 15 (10.07) | 10 (6.71) | 149 (100) | |
| | **30-40** | 122 (81.33) | 15 (10.00) | 13 (8.67) | 150 (100) | 0.111 |
| | **40-50** | 105 (92.11) | 7 (6.14) | 2 (1.75) | 114 (100) | |

The mean vertical distance between the maxillary sinus floor and canine apex, in cases with extended maxillary sinus into the canine region (type I and II), was 11.99 ±5.97 mm. 25 canine apices were located above the maxillary sinus floor (Type III). Their distances to the maxillary sinus floor were evaluated separately. The mean distance in this group was 4.71±3.83 mm. Although the distance between the maxillary sinus floor and canine apex increased with increase in age, the difference was not statistically significant (P value = 0.207). There was no significant difference between the right and left sides in this regard.

The floor of the nasal fossa was located below the sinus floor in most of the cases which extended to the canine area. The mean absolute distance of MS-NF was 10.13±4.76 mm in the study population, 9.84±4.77 mm for the right and 9.49±4.60 mm for the left sides. The difference between these values was not statistically significant.

The mean of AEMS beyond the maxillary canine long axis was 2.03±1.17 mm with a maximum extension of 16 mm. This value was 2.25±1.18 mm for the left side which was significantly more than the right side (2.04±1.08 mm). Extensive pneumatization of the maxillary sinus was detected in one case which involved the entire hard plate and extended to the central incisor region (Fig 5).

Table 3 shows that the mean AEMS was significantly lower in the 40-50 year age group compared to the other age groups (P value =0.001). Moreover, the mean distance between MS-NF was significantly higher in the same age group compared with the two others (P value =0.001).

Table 3
Comparison of the anterior extension of maxillary sinus (AEMS) beyond the canine tooth long axis and the mean absolute distances of the floors of maxillary sinus and nasal fossa (MS-NF) between different age groups.

| | AEMS | MS-NF |
|---|---|---|
| **Age Group** | **Mean ± SD (mm)** | **Mean ± SD (mm)** |
| **20-30** | 2.23±1.147 [a] | 9.24±4.57[a] |
| **30-40** | 2.19±1.189 [a] | 10.04±4.93[a] |
| **40-50** | 1.54±1.044 [b] | 11.43±4.53[b] |
| **P Value*** | 0.001 | 0.001 |

Mean values with at least one same letter in superscript were not statistically different*

AEMS: Anterior extension of the maxillary sinus; MS-NF: Distance between maxillary sinus and nasal floor.

# Discussion

In the present study, the amount of anterior extension of the maxillary sinus beyond the canine tooth long axis and the relationship between the root apex of the permanent maxillary canine and the maxillary sinus floor were evaluated in 300 CBCT images.

The proximity of the sinus floor and root apices of the maxillary teeth is of critical importance in several clinical procedures such as endodontic surgery, orthodontic treatment, and implant placement. CBCT scans, with dedicated 3D software allow the reconstruction of the image in three orthogonal planes precise morphometric measurements, and provision of accurate information for case selection, treatment planning, and avoidance of collateral damage during the surgery[17–19].

The relationship between the maxillary sinus floor and posterior teeth has already been evaluated in various studies [4, 10–16]. In contrast, few studies have addressed the relationship between the maxillary sinus floor and canine apex [4, 20–22]. AL-Qasab et al. [22] evaluated this relationship in a limited sample size (30 individuals) and in periapical radiographs. Ducommun et al.[21] evaluated 83 CBCT images for the distance between the apices of the anterior teeth to the nasal floor or maxillary sinus, whichever was closer, and they did not report the results separately for each structure. Their study also included the anterior teeth with apical lesions. To the best of our knowledge, only one comparable study has been published recently which evaluated the relationships between the maxillary teeth (molars, premolars, and canine) and maxillary sinus floor in CBCT [20].

The result of the present study shows that most of the maxillary sinuses (68.83%) extended to the canine area which is almost equal to Zhang et al.'s finding (68.9%)[4]. In contrast, Kim et al. [23] and Kopecka et al. [24] reported much less percentage of canine area pneumatization by the maxillary sinus, (33% and

2.4%, respectively). Regarding the pneumatization of the incisor region, Zhang et al.[4] reported a higher frequency (15.5%) in their study population compared to the present study (2.5%).

In this study, most of the maxillary sinuses (81.33 %) had bilateral symmetry with regard to the location of the anterior border in the jaw. This finding was in accordance with previous studies [2, 25, 26]. Comparably, Shahbazian et al. [27] reported the symmetric morphology of the maxillary sinus in 83% of their cases, and according to Hamdy et al.[28], the average linear cranio-caudal, antero-posterior, and medio-lateral measurements were almost bilaterally-matched in all cases. Based on our results, bilateral symmetry was even more common in those maxillary sinuses which extended into the canine area. Further studies are required to confirm this result.

Despite the reported dissimilarity of the maxillary sinus volume between different genders[25, 29], the frequency of the maxillary sinus which extended to the anterior region was similar in both genders in the present study. This result is almost comparable to those reported by Jun et al. [1] who found no significant difference in the maxillary sinus volume between the males and females after the developmental period.

The frequency of the maxillary sinus which extended to the anterior region and also the mean AEMS beyond the canine long axis were significantly lower in older cases (40–50 years) compared with the other age groups. Additionally, in the vertical dimension, the MS-NF was found to be significantly higher in the older age group. These findings confirm those of Belgin et al. [25], Takahashi et al. [30] and Velasco-Torres et al. [31] who found decreasing maxillary sinus volume with increase in age. Jun et al. [1] also showed that the maxillary sinus increased in size until the completion of skeletal development in both sexes and then an age-related decrease occurred in its volume. Similarly, Ariji et al. [2] reported an increasing maxillary sinus volume up to 20 years of age and a decline process subsequently. Contrary to all these findings, Sahlstrand-Johnson et al. [32] reported that maxillary sinus volume was not related to age in their study sample.

Oishi et al.[20] found a negative correlation between the distance of maxillary sinus floor to the root apices of all teeth (posterior teeth and canine) and age in CBCT images. The same result was found by AL Qasab et al. [22] regarding the distance between the canine apex and maxillary sinus floor in periapical radiographs. Similarly, we found that the distance between the maxillary sinus floor and canine apex increased with increase in age; however, the difference was not statistically significant.

As part of this study, it was found that when the maxillary sinus extended to the canine area, the canine apices, most commonly (84.99 %), was located below the sinus floor at more than 2 mm distance (type I). It was followed by types II and III relationship with much less percentage (8.96% and 6.05%, respectively). This order was in accordance with a recent study by Oishi et al.[20]. They defined type 0 for those cases in which sinus floor did not appear above the root apices. Types I, II and III define the separate, in-contact and interlock relationship between the maxillary sinus floor and canine apices, respectively. They reported that whenever maxillary sinus appeared above the canine apices, type I was the most and type III was the least frequent relationship; this is similar to our findings.

Oishi et al.[20] assessed the proximity of the maxillary canine and posterior teeth to the sinus floor in the standard sagittal and coronal planes. However, in the present study, the classification and measurements were done based on bucco-lingual cross-sections perpendicular to the dental arch of each side of the jaw. This corrected plane seems to be more sensible for evaluating the relationship and distance of the root apices and the sinus floor. In their study [20], the sample size weighted toward the female group (225) which was 3 times more than the male group (76). Moreover, the number of the younger subjects was twice that of the older age group. In the present study, we tried to select a similar number of male (154) and female (146) subjects and have a uniform subject distribution in different age groups to overcome the possible biases. We recommend further studies with lager sample size and wider age span in different population to evaluate the possible population-specific variation.

## Conclusion

Within the limitations of this study, the following conclusions may be drawn:

1. Most of the maxillary sinuses extended to the canine area.
2. In most cases with the maxillary sinus extended to the canine area, the canine apex was located more than 2 mm below the maxillary sinus floor.
3. The maxillary sinus could extend into the incisor region. This is particularly important for surgical procedures and implant treatment in the maxillary anterior region.
4. Extension of the maxillary sinus to the anterior region was less frequent in the older age group.
5. The mean absolute distance between the maxillary sinus and nasal floor was higher in the older age group.

## Abbreviations

CBCT: cone beam computed tomography

2D or 3D: Two- or three-dimensional

AEMS: anterior extension of maxillary sinus

MS-NF**:** vertical distance between the maxillary sinus floor and floor of the nasal fossa

SD: standard deviation

ICC: intra-class correlation coefficient

## Declarations

# Ethical approval:

This study has been performed in accordance with the Declaration of Helsinki and was approved by the Human Ethics Review Committee of the Faculty of Dentistry, University of Medical Sciences, Shiraz, Iran (# IR Sums.Dental.REC.1399.020).

# Consent to participate:

Written consent had been taken at the time of radiographic examination from all the patients for probable use of their anonymous information in future research. The form will surely be available upon the journal requirement.

# Availability of data and materials:

The datasets used and/or analyzed during the current study are available from the corresponding author on reasonable request.

# Conflict of interest:

The authors declare that they have no conflict of interest.

# Funding:

This study was funded by Shiraz University of Medical Science (Grant # 20827)

# Author contributions:

All authors contributed to the study conception and design. Material preparation, data collection and analysis were performed by Leila Khojastepour and Najmeh Movahhedian, and Mohadeseh Zolghadrpour. The first draft of the manuscript was written by Leila Khojastepour; reviewed and the edition was done by Najmeh Movahhedian. All authors read and approved the final manuscript.

# Acknowledgement:

The authors thank the Vice-Chancellory of Shiraz University of Medical Science for supporting this research (Grant # 20827). This manuscript is based on the thesis by Dr. Mohadeseh Zolghadrpour. We also thank Dr. Mehrdad Vossoughi of the Center for Research Improvement of the School of Dentistry for the statistical analysis.

## References

1. Jun B-C, Song S-W, Park C-S, Lee D-H, Cho K-J, Cho J-H. The analysis of maxillary sinus aeration according to aging process; volume assessment by 3-dimensional reconstruction by high-resolutional CT scanning. Otolaryngol Head Neck Surg. 2005;132:429-34.
2. Ariji Y, Kuroki T, Moriguchi S, Ariji E, Kanda S. Age changes in the volume of the human maxillary sinus: a study using computed tomography. Dentomaxillofac Radiol. 1994;23:163-8.
3. Mallya S, Lam E. White and Pharoah's Oral Radiology E-Book: Principles and Interpretation: Second South Asia Edition E-Book: Elsevier India; 2019.
4. Zhang YQ, Yan XB, Meng Y, Zhao YN, Liu DG. Morphologic Analysis of Maxillary Sinus Floor and its Correlation to Molar Roots using Cone Beam Computed Tomography. The Chinese journal of dental research : the official journal of the Scientific Section of the Chinese Stomatological Association (CSA). 2019;22:29-36.
5. Drake R, Vogl AW, Mitchell AW. Gray's Anatomy for Students E-Book: Elsevier Health Sciences; 2009.
6. Misch CE. Contemporary implant dentistry. Implant Dentistry. 1999;8:90.
7. Hauman C, Chandler N, Tong D. Endodontic implications of the maxillary sinus: a review. Int Endod J. 2002;35:127-41.
8. Monkhouse S. Cranial nerves: functional anatomy: Cambridge University Press; 2005.
9. Zhang B, Wei Y, Cao J, Xu T, Zhen M, Yang G, et al. Association between the dimensions of the maxillary sinus membrane and molar periodontal status: A retrospective CBCT study. J Periodontol. 2020;
10. Ok E, Güngör E, Çolak M, Altunsoy M, Nur BG, Ağlarci OS. Evaluation of the relationship between the maxillary posterior teeth and the sinus floor using cone-beam computed tomography. Surg Radiol Anat. 2014;36:907-14.
11. Von Arx T, Fodich I, Bornstein MM. Proximity of premolar roots to maxillary sinus: a radiographic survey using cone-beam computed tomography. J Endod. 2014;40:1541-8.
12. Kilic C, Kamburoglu K, Yuksel SP, Ozen T. An Assessment of the Relationship between the Maxillary Sinus Floor and the Maxillary Posterior Teeth Root Tips Using Dental Cone-beam Computerized Tomography. Eur J Dent. 2010;4:462-7.
13. Jung YH, Cho BH. Assessment of the relationship between the maxillary molars and adjacent structures using cone beam computed tomography. Imaging science in dentistry. 2012;42:219-24.
14. Sharan A, Madjar D. Correlation between maxillary sinus floor topography and related root position of posterior teeth using panoramic and cross-sectional computed tomography imaging. Oral Surg Oral Med Oral Pathol Oral Radiol Endod. 2006;102:375-81.
15. Gu Y, Sun C, Wu D, Zhu Q, Leng D, Zhou Y. Evaluation of the relationship between maxillary posterior teeth and the maxillary sinus floor using cone-beam computed tomography. BMC Oral Health. 2018;18:1-7.
16. Estrela C, Nunes CA, Guedes OA, Alencar AHG, Estrela CR, Silva RG, et al. Study of anatomical relationship between posterior teeth and maxillary sinus floor in a subpopulation of the Brazilian

central region using cone-beam computed tomography-part 2. Braz Dent J. 2016;27:9-15.

17. Nascimento HAR, Andrade MEA, Frazão MAG, Nascimento EHL, Ramos-Perez FMM, Freitas DQ. Dosimetry in CBCT with different protocols: emphasis on small FOVs including exams for TMJ. Braz Dent J. 2017;28:511-6.
18. Pauwels R. Cone beam CT for dental and maxillofacial imaging: dose matters. Radiat Prot Dosimetry. 2015;165:156-61.
19. Szabo BT, Aksoy S, Repassy G, Csomo K, Dobo-Nagy C, Orhan K. Comparison of hand and semiautomatic tracing methods for creating maxillofacial artificial organs using sequences of computed tomography (CT) and cone beam computed tomography (CBCT) images. Int J Artif Organs. 2017;40:307-12.
20. Oishi S, Ishida Y, Matsumura T, Kita S, Sakaguchi-Kuma T, Imamura T, et al. A cone-beam computed tomographic assessment of the proximity of the maxillary canine and posterior teeth to the maxillary sinus floor: Lessons from 4778 roots. Am J Orthod Dentofacial Orthop. 2020;157:792-802.
21. Ducommun J, Bornstein MM, Wong MCM, von Arx T. Distances of root apices to adjacent anatomical structures in the anterior maxilla: an analysis using cone beam computed tomography. Clinical oral investigations. 2019;23:2253-63.
22. AL-Qasab SJ, Mohammed AR, Kaka LN. Relationship between permanent maxillary canine and floor of the maxillary sinus through aging. MUSTANSIRIA DENTAL JOURNAL. 2010;7:83-6.
23. Kim HJ, Yoon HR, Kim KD, Kang MK, Kwak HH, Park HD, et al. Personal-computer-based three-dimensional reconstruction and simulation of maxillary sinus. Surg Radiol Anat. 2003;24:393-9.
24. Kopecka D, Simunek A, Brazda T, Rota M, Slezak R, Capek L. Relationship between subsinus bone height and bone volume requirements for dental implants: a human radiographic study. The International journal of oral & maxillofacial implants. 2012;27:48-54.
25. Belgin CA, Colak M, Adiguzel O, Akkus Z, Orhan K. Three-dimensional evaluation of maxillary sinus volume in different age and sex groups using CBCT. European Archives of Oto-Rhino-Laryngology. 2019;276:1493-9.
26. Demir UL, Akca M, Ozpar R, Albayrak C, Hakyemez B. Anatomical correlation between existence of concha bullosa and maxillary sinus volume. Surgical and Radiologic Anatomy. 2015;37:1093-8.
27. Shahbazian M, Xue D, Hu Y, Cleynenbreugel J, Jacobs R. Spiral Computed Tomography Based Maxillary Sinus Imaging in Relation to Tooth Loss, Implant Placement and Potential Grafting Procedure. Journal of oral & maxillofacial research. 2010;1:e7.
28. Hamdy RM. Three-dimensional linear and volumetric analysis of maxillary sinus pneumatization. Journal of advanced research. 2014;5:387-95.
29. Prabhat M, Rai S, Kaur M, Prabhat K, Bhatnagar P, Panjwani S. Computed tomography based forensic gender determination by measuring the size and volume of the maxillary sinuses. Journal of forensic dental sciences. 2016;8:40.
30. Takahashi Y, Watanabe T, Iimura A, Takahashi O. A study of the maxillary sinus volume in elderly persons using Japanese cadavers. Okajimas folia anatomica Japonica. 2016;93:21-7.

31. Velasco-Torres M, Padial-Molina M, Avila-Ortiz G, García-Delgado R, O'Valle F, Catena A, et al. Maxillary sinus dimensions decrease as age and tooth loss increase. Implant Dentistry. 2017;26:288-95.
32. Sahlstrand-Johnson P, Jannert M, Strömbeck A, Abul-Kasim K. Computed tomography measurements of different dimensions of maxillary and frontal sinuses. BMC medical imaging. 2011;11:8.

# Figures

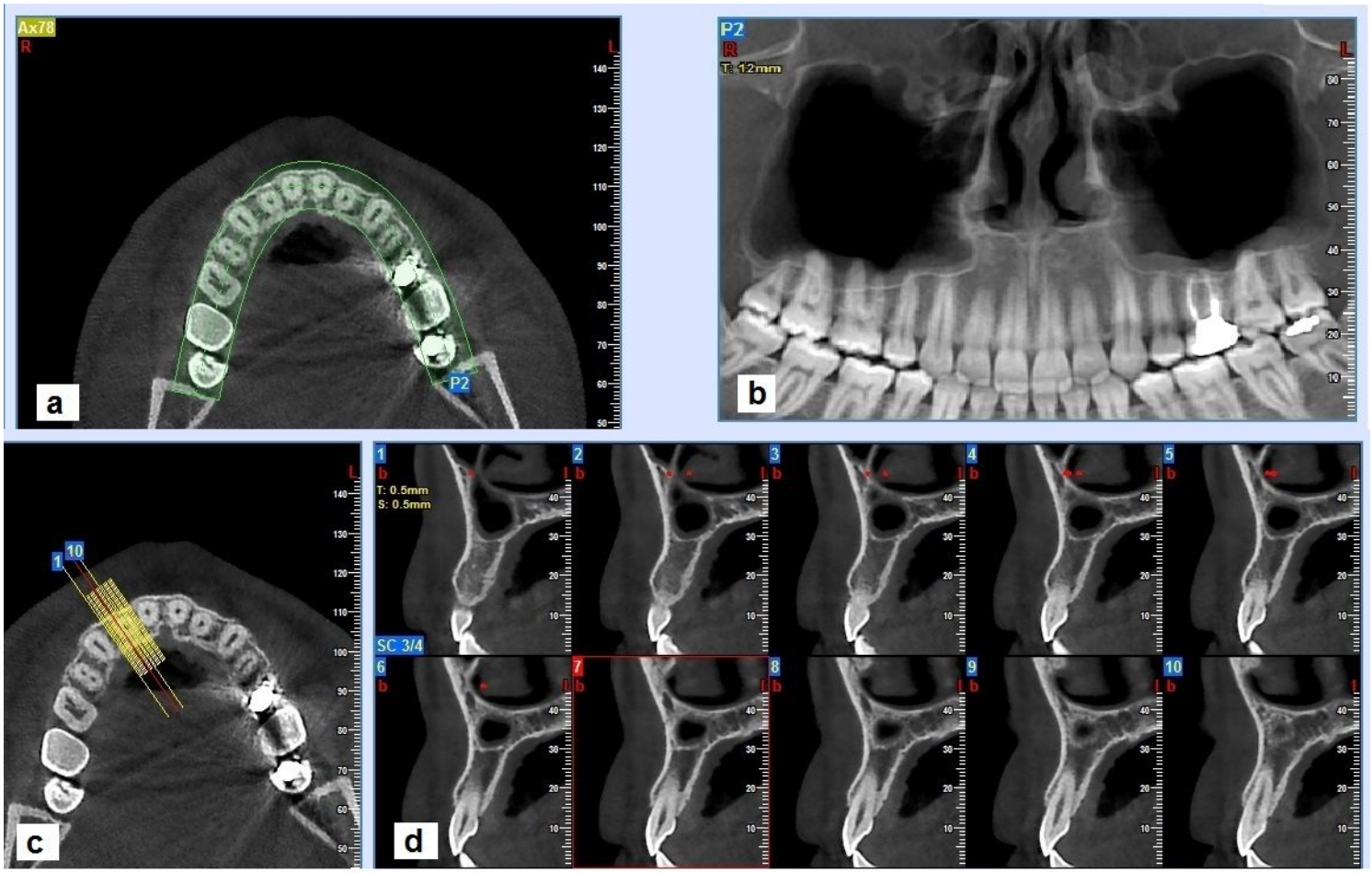


**Figure 1**

a Axial image and curved line used for panoramic reconstruction. b Reconstructed panoramic image. c Reference axial image for preparing buccolingual cross-sections. d Buccolingual cross-sections perpendicular to dental arch with 0.5mm thickness and interval in a case of maxillary sinus pneumatization into the lateral incisor area

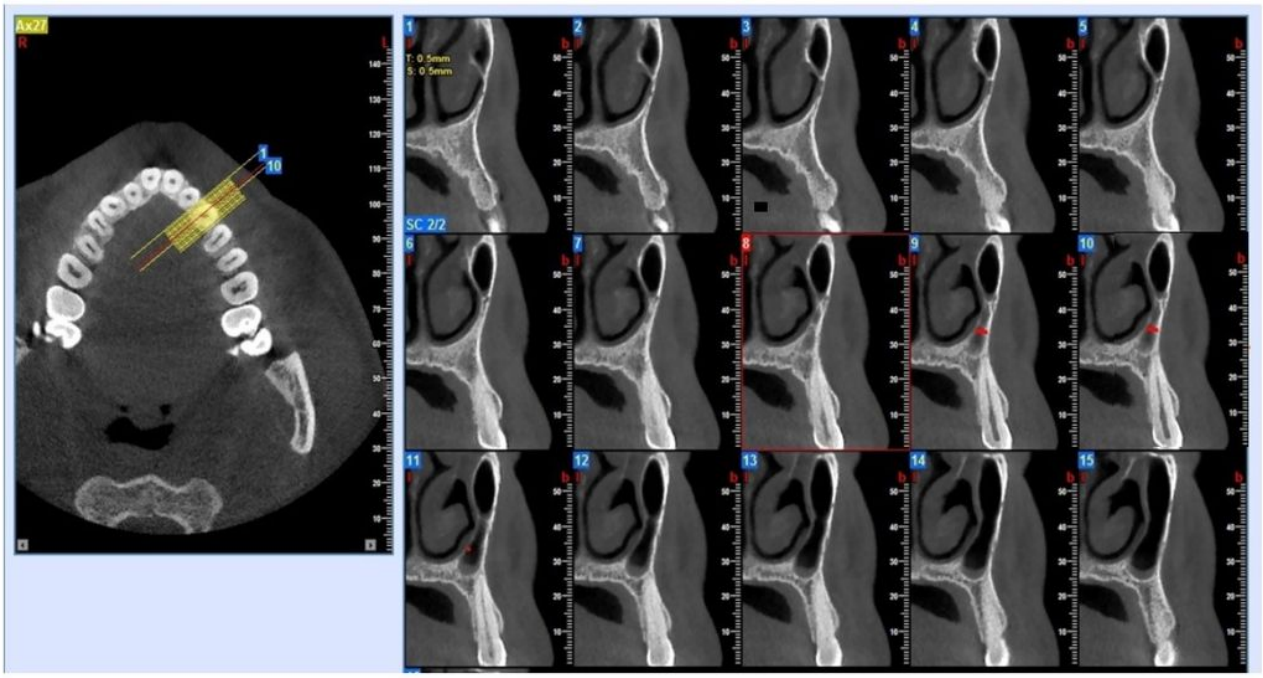

## Figure 2

A case in which the maxillary sinus extended to the canine area. In this case, the maxillary sinus could be seen in 8 cross-sections beyond the canine tooth long axis. Thus, the AEMS in this case is equal to 4 mm (8×0.5).

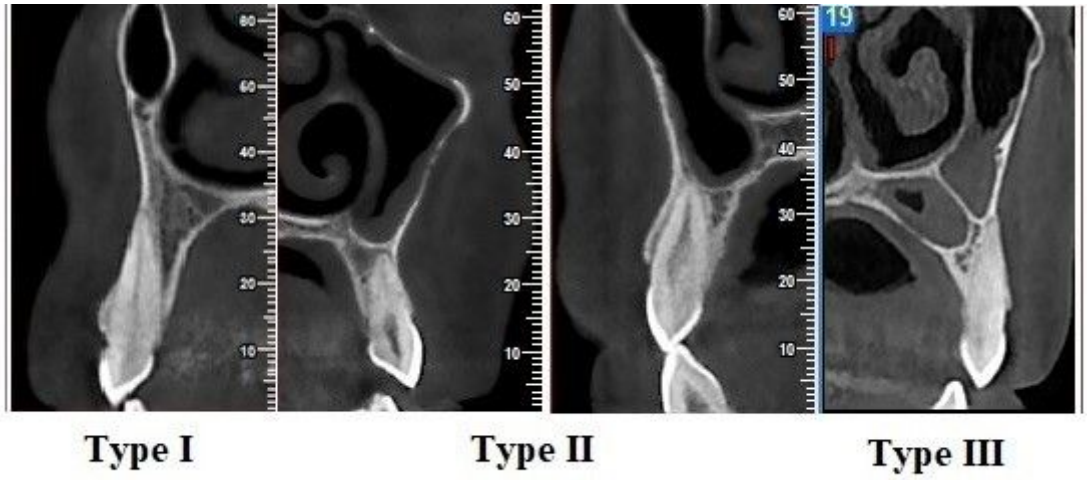


## Figure 3

Three types of vertical relationship between the maxillary sinus floor and canine apex on bucco-lingual CBCT cross sections: Type I (> 2 mm distance), II (2 mm < distance or contact) and III (interlock) relationship.

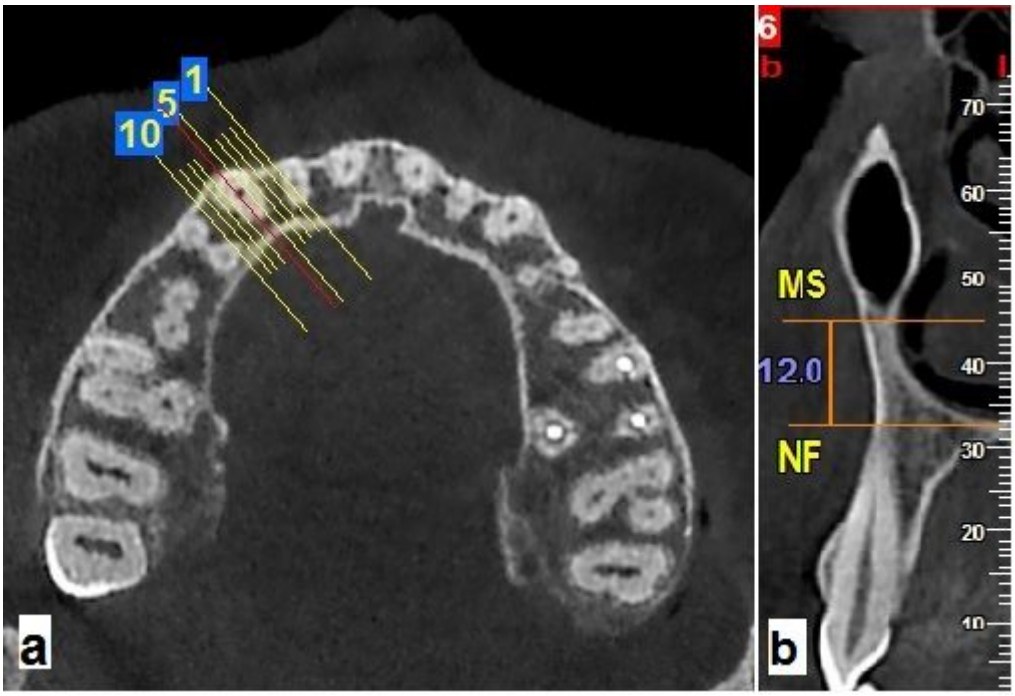


**Figure 4**

a axial reference image and b bucco-lingual cross-section for measurement of the distance between the floors of the maxillary sinus (MS) and nasal fossa (NF) at the canine tooth long axis

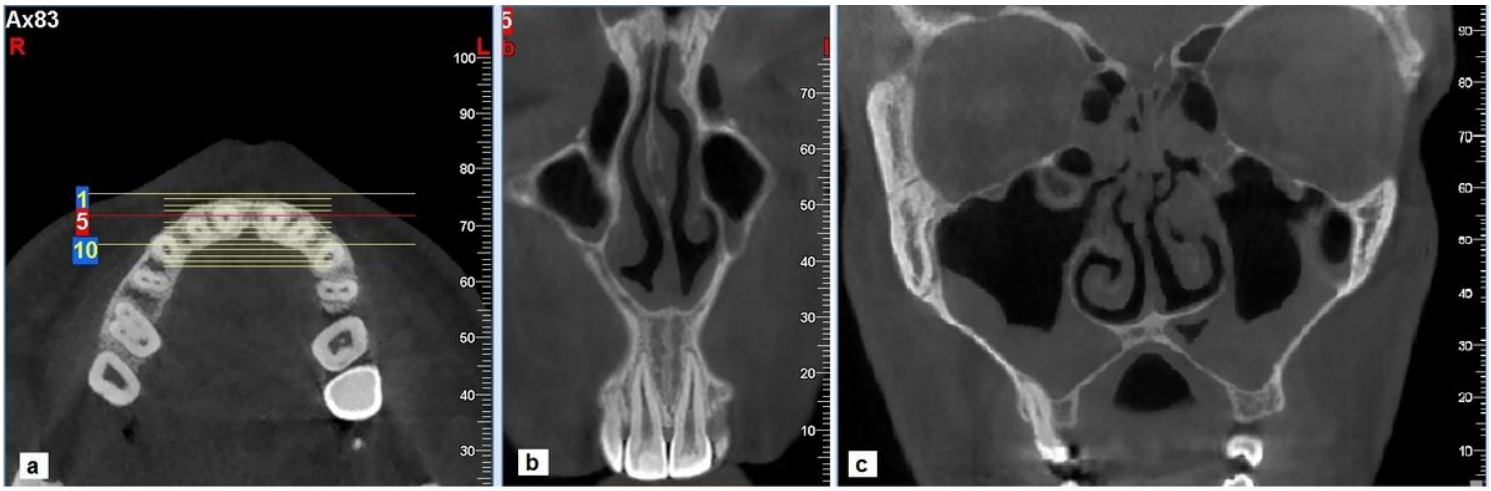


**Figure 5**

A case of extensive maxillary sinus pneumatization: a reference axial image b the extension to the central incisor region. c involvement of the entire the hard plate