Thyroid Hemiagenesis With TI-RADS 2 Nodule in the Contralateral Lobe: a Case Report

Senai Goitom Sereke (nayhersen@gmail.com)
Makerere University Faculty of Medicine: Makerere University College of Health Sciences
https://orcid.org/0000-0001-8190-2070

Anthony Oriekot
Makerere University Faculty of Medicine: Makerere University College of Health Sciences

Felix Bongomin
Makerere University Faculty of Medicine: Makerere University College of Health Sciences

---

Case report

Keywords: Hemiagenesis, thyroid, neck ultrasound, nodule, TI-RADS

Posted Date: February 5th, 2021

DOI: https://doi.org/10.21203/rs.3.rs-186435/v1

Abstract

Background**:** Thyroid hemiagenesis is a rare congenital anomaly in which one lobe of thyroid gland fails to develop. There is a higher incidence of associated thyroid disorders in patients with thyroid hemiagenesis.

Case presentation: A 32-year-old female presented to a hospital with complaint of painless neck swelling of 3-month duration with associated globus sensations. There were no history of thyroid related problems or thyroid related treatment prior to her presentation. Physical examination demonstrated a mobile right thyroid swelling but no obvious nodular contour. Neck ultrasound demonstrated absent left lobe of thyroid gland, right thyroid gland with solitary nodule of TI-RADS 2 and isthmus *in situ*. Extensive search for possible ectopic thyroid tissue was negative. Thyroid function test was euthyroid.

Conclusion: Early detection of this entity and follow up monitoring of thyroid morphologic and hormonal function have paramount importance.

Background

Thyroid hemiagenesis (THA) is a rare congenital disorder that is characterized by an absence of one thyroid lobe with an estimated prevalence rate of 0.02%(1). This anomaly is often detected incidentally. The pathogenesis and clinical significance of this malformation remain unclear hence there is no specific recommendation/s of management especially in asymptomatic cases(2).

The mechanisms responsible for thyroid morphogenesis or agenesis have not been clearly understood(3). Congenital thyroid anomalies may be caused either by abnormal descent of the gland or by incomplete genesis of a lobe. However, the etiology still remains unclear. Genetic component was mentioned as an etiology as it was seen in monozygotic twins(4).

Thyroid hemiagenesis may involve either lobe, with or without agenesis of the isthmus. Studies carried out in living population showed that it affects the left lobe in 80% of the cases (with left to right ratio = 4:1). Left lobe hemiagenesis is associated with agenesis of the isthmus in 50% of cases while right lobe agenesis is predominantly associated with isthmus agenesis(5).

Patients with thyroid hemiagenesis are most frequently clinically euthyroid and consequently will have normal circulating levels of thyroxine (T4) and triiodothyronine (T3)(6). If there is high index of clinical suspicion, diagnosis can be confirmed by imaging techniques, mostly by the means of ultrasonography or thyroid scintiscan(6, 7). Less frequently, the anomaly may be incidentally detected on cross-sectional imaging performed in the evaluation of other medical conditions. The utility and popularity of thyroid ultrasonography has grown to almost gold-standard status due to its wide availability, non-invasiveness, and low cost(7). Herein, we present a case of an adult Ugandan woman in whom we diagnosed a biochemically euthyroid left THA.

Case Presentation

On the end of 2019, a 32-year-old Ugandan female who was relatively healthy three months prior to her presentation with a complaint of right neck swelling with associated occasional local pain. She reported an occasional sensation of an object or food stuck in the throat (globus sensation). There was no documented treatment related to thyroid, nor history of surgery. No known family history of thyroid related problem could be traced. She had no history of menstrual irregularities and had given birth to 2 children.

Physical examination demonstrated right mobile thyroid swelling with no obvious nodular contour, otherwise was normal and no obvious congenital nor acquired condition was observed. Her blood pressure was 90/60mmHg and the pulse was 80/min. Auscultation of the swelling was unremarkable with no bruit.

Ultrasound examination of the neck showed a well-defined nodule, with smooth margins (ACT TI-RADS point-0), wider than taller (0), hypoechoic (2), spongiform composition (0), and with no echogenic foci (0) in the right lobe of thyroid gland, measuring 1.8X1.8X1.4cm, with mild to moderate flow on color Doppler and low resistance flow on spectral Doppler. There was no left lobe of thyroid but isthmus of the thyroid in situ and measured 0.5cm in AP diameter. The remaining normal right lobe of thyroid measured 2.2X2.8X1.7cm (Vol 5.5ml) (Fig. 1)(Fig. 2). There were no enlarged cervical lymph nodes. The finding prompted the examiner to search for any possible ectopic thyroid tissue and no midline neck swelling was detected. And thorough upper neck ultrasound examination was done and no thyroid tissue was seen in the suprahyoid, prehyoid, infrahyoid, submandibular, sublingual and prelaryngeal region. The ultrasound findings were consistent with right thyroid lobe nodule (TI-RADS 2) and left thyroid lobe hemiagenesis.

The TSH was 3.92 µIU/ml (Reference interval 0.27–4.20 µIU/ml), Free T3 of 3.21 pmol/L (reference interval 3.10-6.80pmol/L) and free T4 of 11.79 pmol/L (reference interval 12.0–22.0 pmol/L).

The patient was counseled on her condition and was put on to a regular follow up the TI-RADS 2 nodule.

Discussion

Thyroid hemiagenesis is a rare congenital anomaly of thyroid with about 300 cases reported in the literature until 2010(8). It is three times more common in females as compared to males. In 80% the hemiagenesis involves the left lobe of thyroid gland (with left to right ratio 4:1) and about 50% of patients with left lobe hemiagenesis will also have an absent thyroid isthmus (5, 9). The present case was female and had no known family history of thyroid abnormality. Left lobe hemiagenesis without involvement of the isthmus was found on ultrasound.

Patients with hemiagenesis of thyroid gland are most frequently clinically euthyroid as in the present case (6). However, a large case-control study observed a significantly higher incidence of concomitant

thyroid disorders such as Graves' disease, Hashimoto's thyroiditis, subacute thyroiditis, nodular goiter, hyper functioning adenoma, primary carcinoma, and metastatic carcinoma, the most frequent disorders being thyroid nodules and autoimmune thyroid disease than subjects with bilobate thyroid glands (10). We found solitary thyroid nodule in the present case of hemiagenesis as a reason to seek medical attention.

Ultrasonography (US) and radionuclide thyroid scanning are the imaging modalities of choice in the evaluation of the thyroid gland (11). Thyroid scintigraphy using technetium or iodine can be helpful in hemiagenesis of thyroid gland but showed drawbacks due to artefacts related to non-visualization of one thyroid lobe due to neoplasm, contralateral autonomous solitary thyroid nodule that is suppressing normal tissue, inflammatory, and infiltrative diseases of the thyroid (12, 13). Therefore, scintigraphy findings should be supplemented by ultrasound to avoid false positive results (14). Ultrasonography is a better diagnostic tool as it is widely available and cost-effective with no radiation exposure to the patient (15). The patient was examined with ultrasound of the neck and laboratory tests of thyroid function test.

Thyroid hemiagenesis has been considered benign congenital anomaly that requiring no medical or surgical treatment. Nevertheless, the entity has been associated with high incidence of associated thyroid disorders as mentioned earlier. Therefore, early detection of those disorders, follow up and intervention when indicated are of paramount importance (6, 16).

Conclusion

Ultrasound can easily establish the diagnosis of thyroid hemiagenesis and is considered as the investigation of choice. We found associated thyroid nodule in the presented case. Therefore, the diagnosis of thyroid hemiagenesis should prompt an active search of any associated morphologic or functional abnormality.

Declarations

Ethics approval and consent to participate

No institutional approval was required to publish the case details. The patient provided a written informed consent to participate in the study.

Consent for publication

The patient provided an informed written consent for this case to be published in a peer-reviewed journal.

Availability of data and materials

The information used and/or analyzed during this case report is available from the corresponding author on reasonable request.

Competing interests

The authors declare that they have no competing interests.

Funding

No funding

Authors' contribution

All authors made substantial contributions to conception and design, acquisition of data, or analysis and interpretation of data; took part in drafting the article or revising it critically for important intellectual content; agreed to submit to the current journal; gave final approval of the version to be published; and agree to be accountable for all aspects of the work.

Acknowledgements

We would like to acknowledge, the patient for her active support in the process of data collection.

References

1. Karabay N, Comlekci A, Canda MS, Bayraktar F, Degirmenci B. Thyroid hemiagenesis with multinodular goiter: a case report and review of the literature. Endocr J. 2003;50(4):409-13.
2. Szczepanek-Parulska E, Zybek-Kocik A, Wartofsky L, Ruchala M. Thyroid Hemiagenesis: Incidence, Clinical Significance, and Genetic Background. J Clin Endocrinol Metab. 2017;102(9):3124-37.
3. Kenichi S, Sadao A, Katsuhisa E, Sadanori M, Akira K. Primary hyperparathyroidism with thyroid hemiagenesis. ASIAN JOURNAL OF SURGERY. 2007;30:151-3.
4. Cakir M, Gonen S, Dikbas O, Ozturk B. Thyroid hemiagenesis with Graves' disease, Graves' ophthalmopathy and multinodular goiter. Intern Med. 2009;48(12):1047-9.
5. Bergami G, Barbuti D, Di Mario M. [Echographic diagnosis of thyroid hemiagenesis]. Minerva Endocrinol. 1995;20(3):195-8.
6. Ruchala M, Szczepanek E, Szaflarski W, Moczko J, Czarnywojtek A, Pietz L, et al. Increased risk of thyroid pathology in patients with thyroid hemiagenesis: results of a large cohort case-control study. Eur J Endocrinol. 2010;162(1):153-60.
7. Nsame D, Chadli A, Hallab L, El Aziz S, El Ghomari H, Farouqi A. Thyroid Hemiagenesis Associated with Hashimoto's Thyroiditis. Case Rep Endocrinol. 2013;2013:414506-.
8. Wu YH, Wein RO, Carter B. Thyroid hemiagenesis: a case series and review of the literature. Am J Otolaryngol. 2012;33(3):299-302.
9. Kocakusak A, Akinci M, Arikan S, Sunar H, Yucel AF, Senturk O. Left Thyroid Lobe Hemiagenesis with Hyperthyroidism: Report of a Case. Surgery Today. 2004;34(5):437-9.

10. Oh J, Hong K, Yoon Y. Thyroid Hemiagenesis Associated with Papillary Carcinoma. International Journal of Thyroidology. 2015;8:194.
11. Mikosch P, Gallowitsch HJ, Kresnik E, Molnar M, Gomez I, Lind P. Thyroid hemiagenesis in an endemic goiter area diagnosed by ultrasonography: report of sixteen patients. Thyroid. 1999;9(11):1075-84.
12. Huysmans D A, Hermus A R. Iodine and Technetium Scintigraphy of the Thyroid. In: W.W. dH, editor. Functional and Morphological Imaging of the Endocrine System. 7. Boston, MA.: Springer; 2000.
13. Elif K-A, Serap T, Ihsan A, Fuat D, Pinar I, Erdal A, et al. Pitfalls in the diagnosis of thyroid dysgenesis by thyroid ultrasonography and scintigraphy. European Journal of Endocrinology 2012;166:43-8.
14. Ayaz ÜY, Ayaz S, Döğen ME, Api A. Ultrasonographic and Scintigraphic Findings of Thyroid Hemiagenesis in a Child: Report of a Rare Male Case. Case Reports in Radiology. 2015;2015:917504.
15. De Remigis P, D'Angelo M, Bonaduce S, Di Giandomenico V, Sensi S. Comparison of ultrasonic scanning and scintiscanning in the evaluation of thyroid hemiagenesis. J Clin Ultrasound. 1985;13(8):561-3.
16. De Sanctis V, Soliman AT, Di Maio S, Elsedfy H, Soliman NA, Elalaily R. Thyroid Hemiagenesis from Childhood to Adulthood: Review of Literature and Personal Experience. Pediatr Endocrinol Rev. 2016;13(3):612-9.

Figures

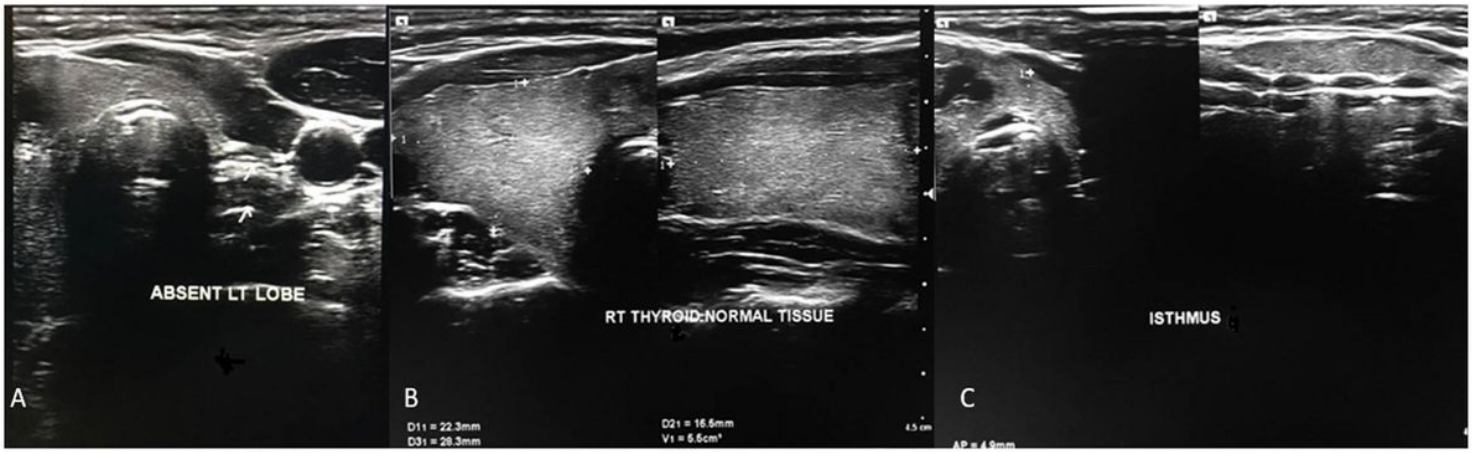

Figure 1

Ultrasound of the thyroid gland with high frequency linear probe demonstrated A. Absent left thyroid lobe B. The right thyroid lobe normal tissue volume C. Isthmus in situ both in longitudinal and transverse planes

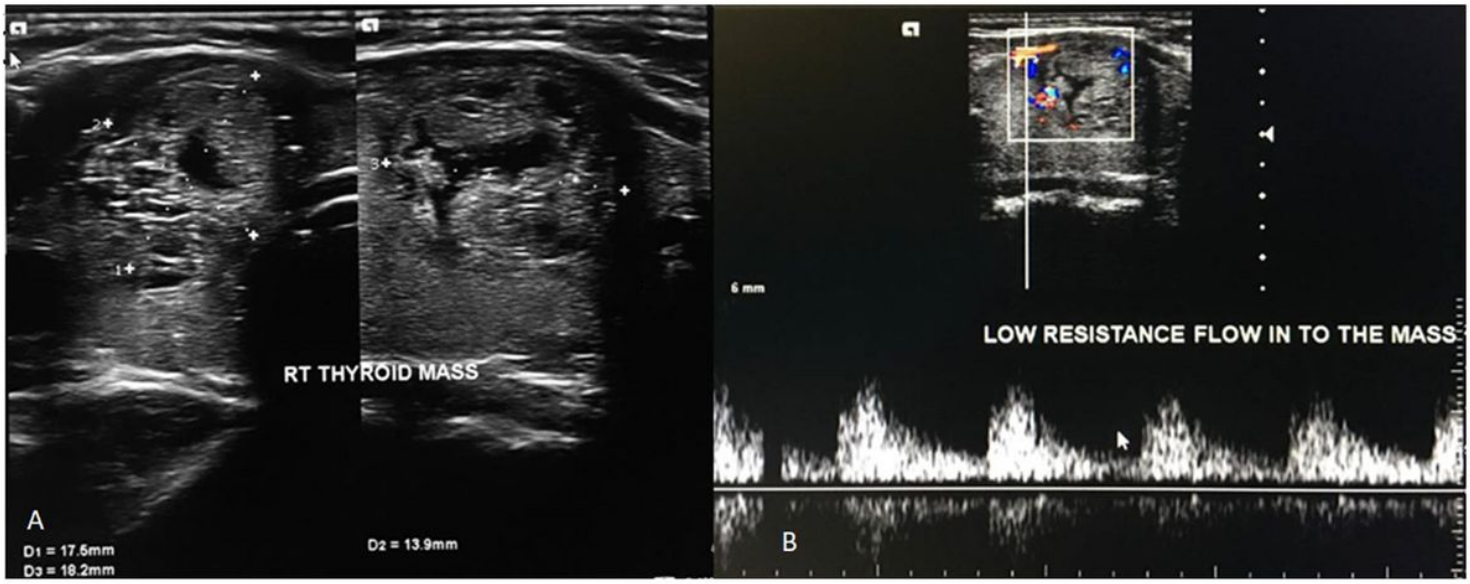

Figure 2

Ultrasound of the right thyroid nodule A. a well-defined nodule, with smooth margins, wider than taller, hypoechoic, spongiform composition, and with no echogenic foci B. Color and spectral Doppler (triplex Doppler) of the nodule showed moderate and low resistance flow respectively.