A case of idiopathic unilateral calcification of the optic nerve, chiasm and optic tract.

Yauhen A. Piashko (pzm77731@gmail.com)
Republican Scientific and Practical Center of Neurology and Neurosurgery https://orcid.org/0000-0002-7935-6442

Vladimir Zhurauliou
Belarusian Medical Academy of Post-Graduate Education

Aleksandra N. Kramarenko
Republican Scientific and Practical Center of Neurology and Neurosurgery

Ayya Bayramova
4th City Clinical Hospital

Research Article

Keywords:

Posted Date: July 27th, 2022

DOI: https://doi.org/10.21203/rs.3.rs-1866326/v1

Abstract

Purpose

We present a rare case of unilateral calcification of the optic nerve, half of the chiasm, and optic tract.

Methods

Observational case report.

Results

The patient has no traumatic history or metabolic disorders which we can associate with this disease. Complete blindness of the left eye noted from the age of 3. We detected nerve calcification at 36 after removing the tuberculum sellae meningioma.

Conclusion

Our clinical case isn't a consequence of a meningioma since blindness developed. At this age, the appearance of meningiomas is extremely unlikely, which is confirmed by absence of sings of a tumor on neuroimaging from 2014.

Introduction

We can consider optic nerve calcination as a type of calcinates of the central nervous system, which is common, but the localization of this process in the optic nerve is a rare phenomenon [1, 4, 5, 7, 8]. Most calcifications of the optic nerve are one-sided process. Most often they are random find, but they can be part of various pathological syndromes and cause a violation of nerve function [2, 3, 4, 5, 6, 7, 8, 9, 10].

Case Report

A 36-year-old man was admitted to the neurosurgical department with a tuberculum sellae meningioma spreading into the left optic nerve channel. From ophthalmological disorders, the patient has complete atrophy of the left optic nerve, divergent strabismus, paresis of the external rectus muscle of the left eye, amaurosis on the left, complex myopic astigmatism, accommodation disorder. During the neurological examination of the patient, besides visual and oculomotor disorders, no other focal and cerebral symptoms were detected. By the endocrine system, the patient had postoperative hypothyroidism (he had a history of total thyroidectomy for Basedow-Graves' disease). No deviations in the test results were detected during laboratory examination. The calcium level was normal 2.46 (2.2–2.65 mmol/L).

The patient underwent endoscopic transcranial removal of the tuberculum sellae meningioma. On an MRI from 2014, we detected no signs of a tumor of the tubercule. In the postoperative period, it performed a control CT scan of the brain with contrast enhancement, which revealed calcification of the left optic nerve (Fig1, 2). No contrast set was detected. No tumor tissue was detected.

Discussion

Such calcification is a lesion not only of the nerve membranes, but also of its entire cross-section. Calcination is unilateral, with a spread to the unilateral half of the chiasm and the visual tract.

Meningiomas, and other tumors of the nerve membranes. The soft-tissue component is not present. There are no signs of contrast accumulation. There are no characteristic changes by the bones of the orbit, the inclined process, the optic nerve channel [5, 9]. Our clinical case isn't a consequence of a nerve tumor, for example meningioma, since blindness developed at 3. At this age, the appearance of meningiomas is extremely unlikely, which is confirmed by the absence of sings of a nerve tumor on neuroimaging from 2014.

Endocrine diseases (hypoparathyroidism, hyperparathyroidism and other endocrinopathies). The patient has no clinical and laboratory signs of impaired calcium metabolism. The patient has a unilateral lesion [2, 3, 4, 5, 10].

Post-traumatic changes. Absence of anamnestic information showing injury. There are no typical post-traumatic changes by the eyeball. There are no calcifications in the eyeball and nerve area near the eyeball itself [6].

Metabolic diseases. The patient has no clinical and laboratory signs of metabolic disorders [3, 5, 8].

The clinical case presented for discussion is unusual for several reasons:

1. No history of causes of vision loss in the left eye. There are no references to trauma, eye diseases, systemic diseases, endocrinopathy.
2. There is no anamnestic data on the dynamics of vision loss.
3. Discrepancy between clinical data and neuroimaging data: ossification of the entire optic nerve across the entire diameter, throughout the orbital part, in the optic canal, and the intracranial part of the nerve. Ossification extends to the unilateral half of the chiasm and the initial parts of the visual tract. Several contradictory points are noted. First, it doesn't reduce the size of the eyeball compared to a healthy one. There were no signs of atrophic changes on his part. Second, there are no signs of atrophic changes in the initial parts of the optic nerve from the eyeball to calcification. Third, it spread calcification to the area of the chiasm and the unilateral optic nerve in the absence of sings of homonymous hemianopsia (syndrome of disfunction to half of the chiasm and the visual tract). (Fig. 3)

Conclusion

Can this case of optic nerve calcification be classified into any group (subgroup)? Unlikely. According to the authors, this case should be idiopathic calcification. [4, 5]. The only symptom is the blindness of this eye, without anamnestic data, is probably the outcome, the end point, and not the pathological process that triggered the calcification process.

References

1. Reske-Nielsen E, Jensen PK, Hein-Sørensen O, Abelskov K (1988) Calcification of the central nervous system in a new hereditary neurological syndrome. Acta Neuropathol. ;75(6):590-6. doi: 10.1007/BF00686204. PMID: 3376762
2. Chappel D, Farrington K (1991 May) Primary hyperparathyroidism presenting as unilateral visual loss. Postgrad Med J 67(787):469–470. doi: 10.1136/pgmj.67.787.469. PMID: 1852669; PMCID: PMC2398843
3. Caldemeyer KS, Smith RR, Edwards-Brown MK (1995 Jun-Jul) Familial hypophosphatemic rickets causing ocular calcification and optic canal narrowing. AJNR Am J Neuroradiol 16(6):1252–1254 PMID: 7677018; PMCID: PMC8337831
4. Murray JL, Hayman LA, Tang RA, Schiffman JS (1995) Dec;15(4):203-8 Incidental asymptomatic orbital calcifications. J Neuroophthalmol. doi: 10.3109/01658109509044603. PMID: 8748555
5. Phadke RV, Agarwal P, Sharma K, Chauhan SS (1996) May;51(5):359 – 61 Idiopathic duro-optic calcification–a new entity? Clin Radiol. doi: 10.1016/s0009-9260(96)80116-4. PMID: 8641101
6. Crompton JL, O'Day J, Hassan A (2004) Dec;24(4):293-4 Optic nerve calcification after trauma. J Neuroophthalmol. doi: 10.1097/00041327-200412000-00004. PMID: 15662243
7. Patankar T, Prasad S, Goel A (1997 Apr-Jun) Sphenoid wing meningioma–an unusual cause of duro-optic calcification. J Postgrad Med 43(2):48–49 PMID: 10740720
8. Nicholson BP, Lystad LD, Emch TM, Singh AD (2011) Feb;95(2):290 Idiopathic dural optic nerve sheath calcification. Br J Ophthalmol. 299. doi: 10.1136/bjo.2008.157032. PMID: 19515640
9. Bains S, Kim U, Shanti R (2016 Dec) Orbital melanoma with calcification: A diagnostic dilemma. Indian J Ophthalmol 64(12):932–934. doi: 10.4103/0301-4738.198849. PMID: 28112137; PMCID: PMC5322711
10. Ramos JN, Urbano H, Costa J, Casimiro C (2021 Nov) Bilateral and symmetrical optic nerve sheath calcification due to primary hyperparathyroidism. J Neuroradiol 48(6):461–463. doi: 10.1016/j.neurad.2020.09.005. Epub 2020 Sep 26. PMID: 32987035

Declarations

Statement of consent

Appropriate written patient consent to publish was obtained. Informed consent was obtained from the patient to use images.

Statement of conflicting interests

The authors report no potential conflicts of interest with respect to the materials or methods used in this study or the findings specified in this paper.

Statement of funding

The authors received no financial support for the research, authorship; the findings specified in this paper and/or publication of this article.

Figures

Figure 1

Patient’s CT. Bone algorithm. Calcification of the intraorbital part of the left optic nerve, the left half of the chiasm and the initial part of the left optic tract

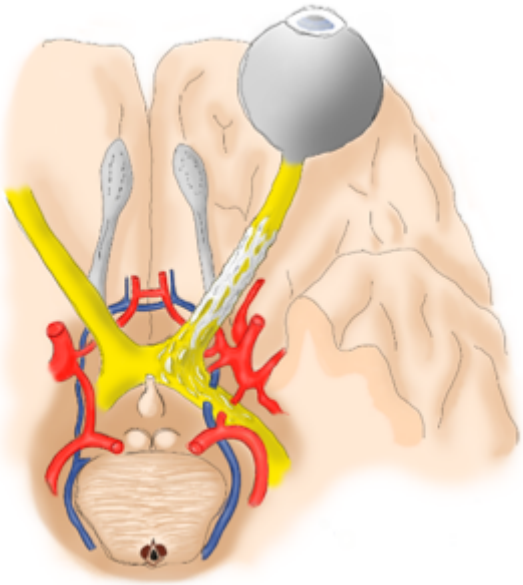

Figure 2

Scheme of calcification of the left optic nerve, half of the chiasm and the left optic tract

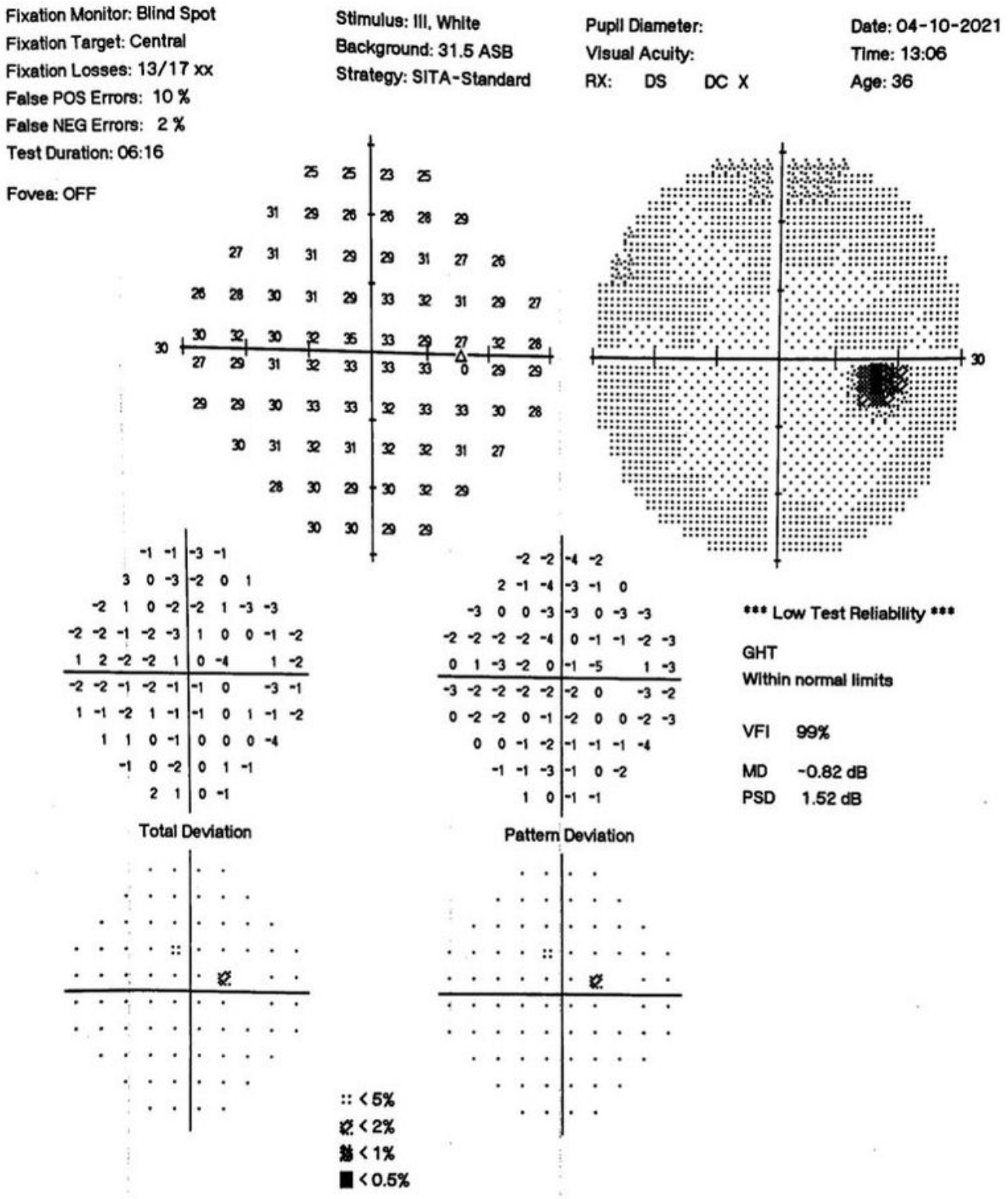

Figure 3

Visual field of a healthy eye, the absence of damage sings to the chiasm and the optic tract (syndrome of disfunction to half of the chiasm and the optic tract)