Two-year outcome of a patient after LASIK following SMILE lenticule in situ implantation to treat a rare complication

Jing Zhao
Fudan University Eye Ear Nose and Throat Hospital
Jianmin Shang
Fudan University Eye Ear Nose and Throat Hospital
Lingling Niu
Fudan University Eye Ear Nose and Throat Hospital
Haipeng Xu
Fudan University Eye Ear Nose and Throat Hospital
Dong Yang
Fudan University Eye Ear Nose and Throat Hospital
Yu Zhao
Fudan University Eye Ear Nose and Throat Hospital
Dan Fu
Fudan University Eye Ear Nose and Throat Hospital
Xingtao Zhou
Fudan University Eye Ear Nose and Throat Hospital https://orcid.org/0000-0002-3465-1579

Case Report

Keywords: SMILE, Lenticule, Re-implantation, Complication

Posted Date: January 9th, 2019

DOI: https://doi.org/10.21203/rs.2.188/v1

Version of Record: A version of this preprint was published on August 8th, 2019. See the published version at https://doi.org/10.1186/s12886-019-1188-9.

Abstract

Background: To report a case of femtosecond laser-assisted in situ keratomileusis (FS-LASIK) following small incision lenticule extraction (SMILE) lenticule in situ implantation to treat a rare complication.

Case presentation: The hyperopic left eye of a 46-year-old patient with refraction of +7.75 diopters sphere (DS)/-1.25 diopters cylinder (DC)×5°and corrected distance visual acuity (CDVA) of 20/50 mistakenly underwent SMILE procedure for myopic astigmatism (-8.50DS/-1.50DC×175°) due to medical record error. The extracted lenticule was subsequently re-implanted in situ. After 8 months, the left eye underwent FS-LASIK to correct hyperopia and astigmatism +5.0DS/-0.75DC×100°. Two years after FS-LASIK, corneal tomography showed no ectasia and microscopy revealed transparent cornea. The left eye obtained CDVA of 20/50 and the refraction was -0.75DS/-0.25DC×165°.

Conclusion: SMILE lenticule in situ implantation offers a solution for rare complications and correction of refractive error following lenticule re-implantation with FS-LASIK is feasible and effective.

Keywords: SMILE, Lenticule, Re-implantation, Complication

Background

Small incision lenticule extraction (SMILE) has been proposed as an alternative to laser-assisted in situ keratomileusis (LASIK) for treatment of myopia and astigmatism, as it causes fewer dry-eye symptoms and avoids flap-related complications.[1-3] Moreover, refractive lenticules extracted during the SMILE procedure can be used successfully for autologous or allogenic implantation to reverse myopic correction and treat presbyopia, hyperopia, keratoconus, and other corneal diseases.[4-10] Notably, it is rare for a patient with hyperopia to mistakenly undergo SMILE. We present the first SMILE lenticule re-implantation in situ to restore corneal volume and thickness in this patient's cornea , followed by LASIK to correct hyperopia and astigmatism after complicated refractive surgery.

Case Presentation

A 46-year-old man was transferred to the doctor (Prof. Xingtao Zhou) of our refractive surgery center after complicated refractive surgery. Only some preoperative information and operation parameters were available. Preoperative ophthalmic examinations were normal, with the exception of hyperopia with astigmatism and amblyopia. Uncorrected distance visual acuity (UDVA) was 20/125 for both eyes. Manifest refraction was OD: +7.25 diopters sphere (DS)/-1.25 diopters cylinder (DC)×10°with corrected distance visual acuity (CDVA) of 20/40, OS: +7.75DS/-1.25DC×5°with CDVA of 20/50. The right eye was the dominant eye and the addition power was +0.25D. Corneal tomography was evaluated by a Scheimpflug camera (Pentacam; Oculus, Wetzlar, Germany). The preoperative central corneal thickness (CCT) and mean keratometry readings were 523 μm and 41.3 D in the right eye; these values were 517 μm and 41.4 D in the left eye, respectively. Intraocular pressure (IOP) was normal in both eyes.

The patient complained about vision fatigue at both far and near distances, and he was scheduled for bilateral femtosecond laser-assisted in situ keratomileusis (FS-LASIK) to treat hyperopia and astigmatism. The patient's right eye underwent an uneventful FS-LASIK procedure for hyperopia and astigmatism first. But his left eye mistakenly underwent a SMILE procedure using the VisuMax femtosecond laser (Carl Zeiss Meditec AG, Jena, Germany) for myopic astigmatism (refractive correction: -8.50DS/-1.50DC×175°) due to medical record error. The attempted lenticule thickness was 134 μm, with cap thickness of 110 μm and optical zone of 6.1 mm. A 90° single side cut with a length of 2 mm was created in the superior position. The mistake was quickly recognized and the extracted lenticule was maintained in balanced salt solution (BSS) temporarily, and the patient was immediately transferred to the Dr. Zhou.

The extracted lenticule of the left eye was re-implanted in situ within 2 hours. A lamellar dissector was inserted to gently release the pocket adhesions. The refractive lenticule was grasped with a forceps and partially folded, then inserted into the original site gradually through the small incision. Thereafter, the lamellar dissector was used to spread the lenticule; each edge of the lenticule was carefully flattened and smoothened with a spatula. To remove the striae, the cap was hydrostretched with sponge swabs soaked in BBS. Each step of the treatment was carefully evaluated and adjusted to enable proper positioning of the refractive lenticule.

The patient was followed up at 1day, 3 weeks, 3 months, and 8 months postoperatively. On the first day after surgery, both eyes displayed mild edema under slit-lamp observation. Anterior optical coherence tomography (OCT) (RTVue, Optovue, Fremont, CA, USA) examination demonstrated that the re-implanted lenticule in the left eye was well attached to the stromal bed with visible demarcation lines (Figure 1A). No displacement or striae were observed. Corneal topography assessments revealed CCT of 520 μm and mean keratometry (K) value of 45.1 D in the left eye (Figure 2B). At 8 months after lenticule in situ implantation, the refraction had remained stable since 3 months and indicated reduction of hyperopia compared with preoperative level (+5.00DS/-1.25DC×100°with a stable CDVA of 20/50. The lenticule remained smoothly spread in the interface and identifiable with visible demarcation lines that showed partial hyper-reflection (Figure 1C). The CCT was 502 μm and mean keratometry value was 43.8 D (Figure 2E).

Due to contact lens and glasses intolerance, poor visual acuity, and severe anisometropia, the patient asked for a retreatment. After the risks, benefits, and alternatives were explained and informed consent was obtained, the patient underwent standard FS-LASIK on the left eye for correcting hyperopia and astigmatism 8 months after lenticule re-implantation. The flap had a diameter of 7.9 mm, a thickness of 90 μm, standard 90° hinges, and 90° side cut angles. Refractive correction was +5.0DS/-0.75DC×100°with attempted ablation thickness of 90 μm and optical zone of 6.5 mm. A MEL 80 excimer laser (Carl Zeiss Meditec) was used for stromal ablation with a pulse energy of 185 nJ, followed by flap reposition. A silicone hydrogel contact lens was applied as a bandage after surgery and removed the next day.

At postoperative day 1, the cornea exhibited moderate edema and the lenticule was spread smoothly on the stromal bed with decreased peripheral thickness (Figure 1D & 3C). Corneal topography assessments revealed a CCT of 477 μm and mean keratometry value of 51.3 D (Figure 2F). The UDVA, manifest refraction, CDVA, mean keratometry, CCT, and corneal volume (as measured by Pentacam) before operation, after refractive lenticule re-implantation, and after LASIK are displayed in Table 1. Figures 1-3 show the patient's assessments over the postoperative course. During 2 years of follow-up, the cornea was transparent with no flap striae, inflammation, epithelial ingrowth, or diffuse lamellar keratitis under slit-lamp examination. Corneal tomography showed no signs of ectasia (Figure 2). The UDVA, manifest refraction, and CDVA of the left eye were 20/63, -0.75DS/-0.25DC×165°, and 20/50 at the last visit; these values were 20/40, +0.5DS/-0.5DC×150°, and 20/32 for the right eye. The patient gained binocular uncorrected distance visual acuity of 20/40 and near visual acuity of 20/50, achieving improved satisfaction.

Discussion And Conclusions

The SMILE procedure provides similar results to other corneal refractive procedures for correction of myopia, in terms of safety, efficacy, predictability, accuracy, and stability; but it is flap-free and involves minimal trauma.[2, 3] However, intraoperative and postoperative complications have been reported.[1, 11] We report the first case of a mistaken SMILE procedure, in which refractive lenticule in situ implantation successfully reversed the surgery ,remedied the accompanying complications, and the residual refractive error was corrected by FS-LASIK following lenticule re-implantation.

It was quite difficult to appropriately manage this case. The first step was to re-implant the lenticule in situ and maintain the original structure of the cornea. Notably, it was difficult to detect anterior and posterior surfaces of the lenticule after extraction without any mark. Fortunately, the lenticule was successfully re-implanted with the correct surface position, and there were no abnormalities, such as infection or striae after re-implantation; CDVA had not declined after 3 weeks. Corneal topography examinations and slit-lamp microscope observation showed mild edema that gradually improved. At 8 months after lenticule re-implantation, CCT and cornea volume were 502 μm and 53.7 mm^3, near the preoperative values of 517 μm and 57.2 mm^3. This has been confirmed by previous studies, which demonstrated that corneal thickness and volume could be restored to preoperative levels after post-SMILE autologous lenticule re-implantation.[4, 6]

Interestingly, the mean K value increased from 41.4 D preoperatively to 45.1 D on postoperative day 1, then decreased to 43.8 D at the 8-month follow-up; spherical equivalent refraction decreased from +7.13 DS before surgery to +4.38 DS and remained stable within 8 months after lenticule re-implantation, showing reduction of hyperopia. Thus, anterior corneal curvature may contribute to prediction of refractive status. Pradhan et al.[5] described a patient who underwent implantation of an allogeneic lenticule obtained from a -10.5 D myopic donor via SMILE for the correction of high hyperopia, but achieved only 50% of the intended correction at the 1-year follow-up. Similarly, Ganesh et al.[10] reported undercorrection of transplanted corneal lenticules for hyperopia after cryopreservation. Sun et al.[7] demonstrated that autologous lenticule transplantation was feasible for treatment of hyperopia in patients with anisometropia; however, refractive predictability was unsatisfactory, which may be related to the shape of lenticule due to astigmatism correction. We speculate that corneal edema in the early stage, epithelial remodeling, anterior and posterior surface changes, and postoperative wound healing contributed to the changes in this case. Moreover, refractive predictability after lenticule re-implantation requires further investigation.

After refraction became stable following lenticule re-implantation, standard FS-LASIK was performed. A thin flap of 90 μm was created, avoiding cutting the flap on the re-implanted lenticule. Due to the accuracy of femtosecond laser and smooth scanning, the patient achieved a satisfactory outcome after LASIK treatment. The re-implanted lenticule attached well on the stromal bed postoperatively during the 2-year follow-up, without complications. Lim et al. [12] demonstrated the feasibility of LASIK after reversal of myopic SMILE through refractive lenticule re-implantation in a rabbit model. Our results suggest that SMILE lenticule re-implantation to restore corneal volume and thickness in a human cornea, followed by LASIK to correct hyperopia and astigmatism, is feasible and effective. Although lenticule re-implantation results in unpredictable refractive outcome, FS-LASIK is able to correct the residual refractive error. Nevertheless, alternative methods could be used in this case. Another option may be to perform a CIRCLE procedure with the VisuMax femtosecond laser and convert the cap into a flap followed by excimer ablation on the lenticule surface.

Although we treated this complicated case successfully, the cause of this complication remains to be considered. This case brings to light the importance of preoperative surgical checks. It is necessary to verify the patient's information before and during surgery in order to minimize the risk of unintentional events. Besides, this case reminds surgeons that it is necessary to maintain calm following rare complications of refractive surgery.

Refractive lenticule in situ implantation offers a solution for rare complications during SMILE, which is a reversible procedure; corneal volume and thickness can be restored, but refractive predictability requires further investigation. Correction of residual refractive error following lenticule re-implantation with FS-LASIK is feasible and effective.

Abbreviations

FS-LASIK：Femtosecond laser-assisted in situ keratomileusis

DS : diopters sphere

DC: diopters cylinder

SMILE: Small incision lenticule extraction

LASIK: laser-assisted in situ keratomileusis

UDVA: Uncorrected distance visual acuity

CDVA: Corrected distance visual acuity

BSS: balanced salt solution

OCT: optical coherence tomography

CCT: central corneal thickness

Declarations

Competing Interests

The authors declare that they have no competing interests.

Ethics approval and consent to participate

This study followed the tenets of the Declaration of Helsinki and was approved by the ethics committee of the Eye and ENT Hospital of Fudan University. Informed consent was obtained from the patient.

Consent to Publish

Written informed consent was obtained from the patient for publication of this paper and any accompanying images. A copy of the written consent is available for review by the Editor of this journal.

Availability of data and materials

All data generated or analyzed during this study are included in this article.

Funding

Supported in part by the National Natural Science Foundation of China for Young Scholars Grant No. 81600762Jing Zhao , the National Natural Science Foundation of ChinaGrant No. 81570879 & 81770955Xingtao Zhou and the Project of Shanghai Science and TechnologyGrant No .17140902900 & 17411950201Xingtao Zhou. The funders have no financial orproprietary interest in the materials and products presented herein.

Authors' Contributions

Study concept and design (TXZ); data collection (JZ, MJS, LLN, PHX, DY, YZ, DF); analysis and interpretation of data (JZ, MJS); drafting of the manuscript (JZ,MJS); critical revision of the manuscript (JZ, MJS,TXZ); supervision (TXZ)

Acknowledgments

None

References

1. Ivarsen A., Asp S. and Hjortdal J. Safety and complications of more than 1500 small-incision lenticule extraction procedures. Ophthalmology. 2014;121:822-828.
2. Teus M. A. and Garcia-Gonzalez M. Comparison of the visual results after small incision lenticule extraction and femtosecond laser-assisted LASIK for myopia. J Refract Surg. 2014;30:582.
3. Reinstein D. Z., Archer T. J., Gobbe M., et al. Corneal sensitivity after small-incision lenticule extraction and laser in situ keratomileusis. J Cataract Refract Surg. 2015;41:1580-1587.
4. Angunawela R. I., Riau A. K., Chaurasia S. S., et al. Refractive lenticule re-implantation after myopic ReLEx: a feasibility study of stromal restoration after refractive surgery in a rabbit model. Invest Ophthalmol Vis Sci. 2012;53:4975-4985.

5. Pradhan K. R., Reinstein D. Z., Carp G. I., et al. Femtosecond laser-assisted keyhole endokeratophakia: correction of hyperopia by implantation of an allogeneic lenticule obtained by SMILE from a myopic donor. J Refract Surg. 2013;29:777-782.
6. Riau A. K., Angunawela R. I., Chaurasia S. S., et al. Reversible femtosecond laser-assisted myopia correction: a non-human primate study of lenticule re-implantation after refractive lenticule extraction. PLoS One. 2013;8:e67058.
7. Sun L., Yao P., Li M., et al. The Safety and Predictability of Implanting Autologous Lenticule Obtained by SMILE for Hyperopia. J Refract Surg. 2015;31:374-379.
8. Zhao J., Sun L., Shen Y., et al. Using Donor Lenticules Obtained Through SMILE for an Epikeratophakia Technique Combined With Phototherapeutic Keratectomy. J Refract Surg. 2016;32:840-845.
9. Liu R., Zhao J., Xu Y., et al. Femtosecond Laser-Assisted Corneal Small Incision Allogenic Intrastromal Lenticule Implantation in Monkeys: A Pilot Study. Invest Ophthalmol Vis Sci. 2015;56:3715-3720.
10. Ganesh S., Brar S. and Rao P. A. Cryopreservation of extracted corneal lenticules after small incision lenticule extraction for potential use in human subjects. Cornea. 2014;33:1355-1362.
11. Zhao J., He L., Yao P., et al. Diffuse lamellar keratitis after small-incision lenticule extraction. J Cataract Refract Surg. 2015;41:400-407.
12. Lim C. H., Riau A. K., Lwin N. C., et al. LASIK following small incision lenticule extraction (SMILE) lenticule re-implantation: a feasibility study of a novel method for treatment of presbyopia. PLoS One. 2013;8:e83046.

Tables

Table 1. The data of Patient's left eye before operation and after refractive lenticule re-implantation and after FS-LASIK

Parameter	Preoperative	Postoperative					
		After refractive lenticule re-implantation				After FS-LASIK	
		1day	3 weeks	3 months	8 months	1day	1 month
UDVA	20/125	20/125	20/125	20/200	20/200	20/100	20/100
Manifest refraction (D)	+7.75DS/-1.25 DC×5°	/	+6.00DS/-1.00DC×100°	+5.00DS/-1.25DC×100°	+5.00DS/-1.25DC×100°	-1.50DS/-0.25DC×30°	-1.25DS/-1.25DC×120° -0
CDVA	20/50	/	20/50	20/50	20/50	20/63	20/50
CCT (μm)	517	520	518	512	502	477	452
mean K (D)	41.4	45.1	43.6	43.4	43.8	51.3	50.1
Cornea Volume (mm^3)	57.2	55.6	55.5	54.9	53.7	51.1	51.1

UDVA = uncorrected distance visual acuity; D = diopters; CDVA = corrected distance visual acuity; CCT=central corneal thickness; K = keratometry(DS=diopters sphere; DC= diopters cylinder

Figures

Figure 1

Corneal topographic images before operation, after refractive lenticule re-implantation(LRI)and after femtosecond Laser-assisted in situ keratomileusis (FS-LASIK).

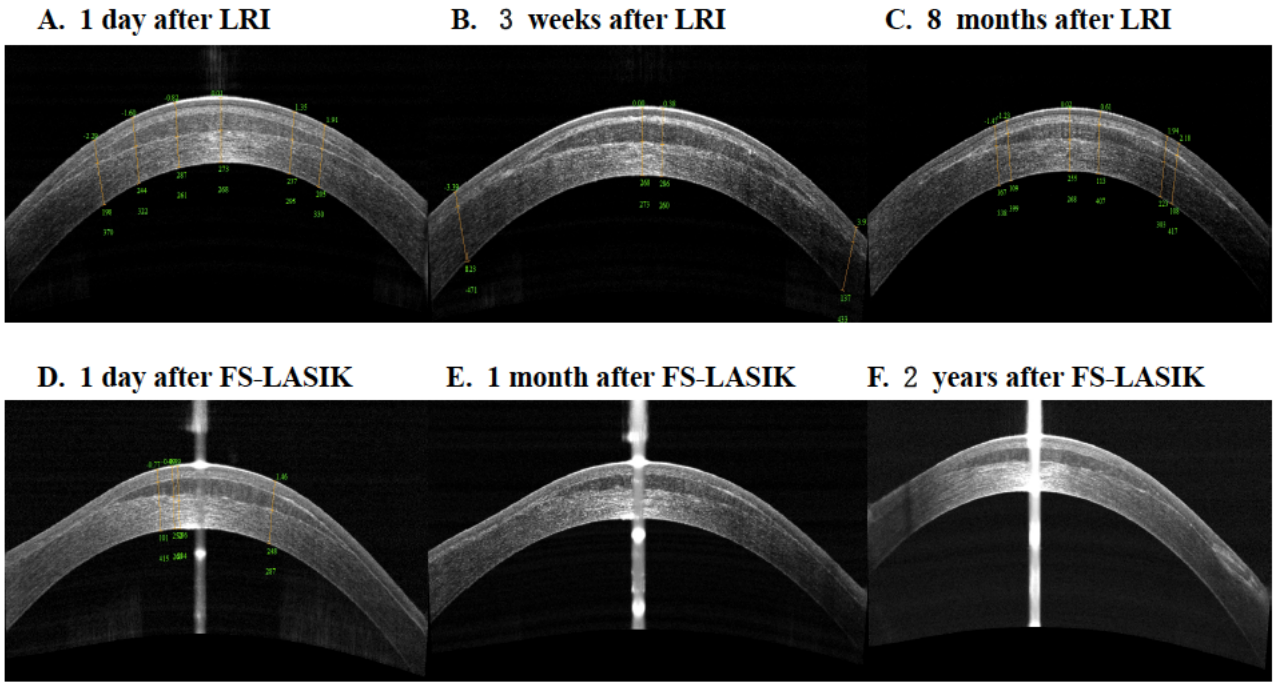

Figure 2

Anterior segment optical coherence tomographic (OCT) images after refractive lenticule re-implantation and after LASIK.

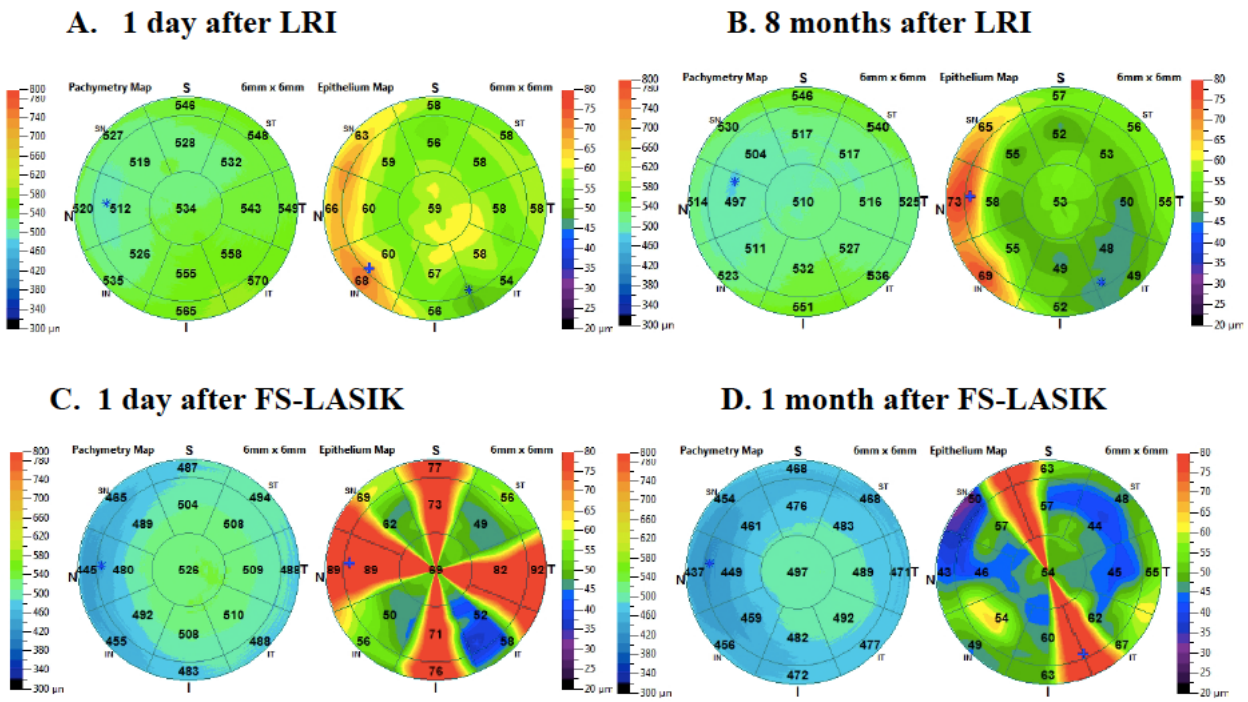

Figure 3

Distribution of corneal thickness and epithelium thickness over the postoperative course.

Supplementary Files

This is a list of supplementary files associated with this preprint. Click to download.

- supplement1.pdf