Is the supine position suitable for ultrasound-guided percutaneous nephrolithotomy in patients with complex renal stones?

Bo Xiao
Tsinghua University Affiliated Beijing Tsinghua Changgung Hospital
Xue Zeng (cengx12@tsinghua.org.cn)
Tsinghua University Affiliated Beijing Tsinghua Changgung Hospital
Gang Zhang
Tsinghua University Affiliated Beijing Tsinghua Changgung Hospital
Chaoyue Ji
Tsinghua University Affiliated Beijing Tsinghua Changgung Hospital
Song Jin
Tsinghua University Affiliated Beijing Tsinghua Changgung Hospital
Wenjie Bai
Tsinghua University Affiliated Beijing Tsinghua Changgung Hospital
Yuzhe Tang
Tsinghua University Affiliated Beijing Tsinghua Changgung Hospital
Bixiao Wang
Tsinghua University Affiliated Beijing Tsinghua Changgung Hospital
Jianxing Li
Tsinghua University Affiliated Beijing Tsinghua Changgung Hospital

---

Research Article

Keywords: US-guided PCNL, complex renal stones,

Posted Date: August 3rd, 2022

DOI: https://doi.org/10.21203/rs.3.rs-1901860/v1

Abstract

Introduction To assess the safety and efficacy of ultrasound (US)-guided percutaneous nephrolithotomy (PCNL) for complex renal stones when performed in a modified supine position.

Methods We retrospectively reviewed the charts of patients who underwent PCNL for complex renal stones at our institution between August 2018 and December 2021. During this time, 188 consecutive patients underwent US-guided PCNL in the prone position (P group, n=129) or in the flank-free modified supine position (S group, n=59). Patient demographics and intraoperative and postoperative data were analyzed.

Results Successful renal access was achieved in all patients. The baseline demographics were comparable between the two groups. The numbers of renal access was significantly higher (2.1±0.4 vs 1.2±0.2, p=0.002) and the operation time was comparable (79.1±14.6 minutes vs 96.2±19.6 minutes, p=0.06) between the two groups. The postoperative hospital stay was also shorter in the P group (6.2±1.5 d vs 10.2±1.7 d, p=0.008). The postoperative hemoglobin loss was similar between the P and S groups (1.7±0.4 g/dl vs 1.8±0.3 g/dl, p=0.12). The stone-free rate (SFR) was significantly lower in the S group (57.5% vs 82.7%, p<0.001). There were no embolization or septic complications. Twelve patients (20.3%) in the S group underwent simultaneous or staged retrograde flexible ureteroscopy to remove residual stones.

Conclusion US-guided PCNL in the modified supine position was a safe treatment for complex renal stones. However, the single-session stone clearance rate was not ideal. The supine flank-free position may be unsuitable for US-guided PCNL in patients with complex renal stones.

Introduction

Percutaneous nephrolithotomy (PCNL) has been considered to be the most effective treatment for large kidney stones since 1976 and has been performed under fluoroscopic guidance in the prone position for decades. The prone position can provide a wide space for puncture access with a low risk of injury to the abdominal viscera[1]. However, PCNL has disadvantages in patients with certain diseases, including morbid obesity, cardiopulmonary dysfunction, and severe ankylosing spondylitis. A variety of modified supine positions has been assessed since the supine position was first introduced by Valdivia et al[2]. Compared with the prone position, the supine position and its modifications have the advantages of no cardiopulmonary risk and easier anesthetic management and are more conducive to performing simultaneous retrograde intrarenal surgery (RIRS). However, the supine and modified supine positions also has disadvantages, including a limited puncture surface area and a longer distance between the skin and the kidney[3]. Although several early studies confirmed that both the prone and supine positions are effective when treating simple stones, there are limited data on the relative value of these positions when treating complex stones, particularly under total ultrasound (US) guidance[4]. The outcomes in patients with complex stones are different from those in patients with simple calculi[5]. Considering the

substantially increased radiation doses associated with fluoroscopy, Chinese clinicians prefer US-guided puncture and access, and X-ray-free PCNL has been popular in China for more than 15 years. The aim of this study was to investigate the role of patient positioning in the outcomes of total US-guided PCNL in patients with complex renal stones.

Patients And Methods

This retrospective study was performed in the urology department at Beijing Tsinghua Changgung Hospital in China. The medical records of 188 consecutive patients who underwent PCNL between August 2018 and December 2021 were reviewed. Patients were included in the study if they had staghorn stones or multiple calyx stones (maximum diameter > 2 cm). Data for patients with a renal anomaly, coagulopathy, or untreated urinary tract infection, pediatric patients, and those with a solitary kidney were excluded. PCNL was performed in the modified flank-free supine position in 59 patients (S group) and in the traditional prone position in 129 patients (P group). Puncture was performed and the tract was established under US guidance. All procedures were performed by the same two experienced urologists (each of whom had performed at least 2000 PCNL procedures). Preoperative demographic data, including age, sex, body mass index, length of access (from skin to target calyx), and stone size (maximum length measured on a computed tomography scan) were reviewed.

Surgical Procedures

All of the procedures were performed under general anesthesia. In the prone position, a 5-Fr ureteral catheter is first placed in the lithotomy position. Next, the distal end of the catheter is connected to the saline bag, which is placed 90 cm above and used to fill the pelvis. The patient is then shifted to the prone position. A 3.5-MHz convex abdominal US transducer (Philips Healthcare, Eindhoven, Netherlands) is used to detect the stones and collecting system. Our US-guided puncture procedure is described in a previous publication[6]. Percutaneous access is achieved using an 18-G needle (Urotech GmbH, Bad Aibling, Germany), after which the guidewire is introduced and the tract is dilated to 24-Fr using either a series of Alken coaxial telescopic dilators or a high-pressure balloon dilator (X Force® N30 balloon, Bard Urological, Covington, GA, USA). The stones are then fragmented and suctioned using a combined ultrasonic/pneumatic lithotripter (Swiss LithoClast, EMS Electro Medical Systems, Nyon, Switzerland), after which US is used to check for residual stones if there are multiple tracts. A ureteral stent and a nephrostomy tube are placed at the end of surgery. In the S group, the patient is placed in the lithotomy position with a 30° tilt of the ipsilateral flank, which is created using a saline bag under the rib cage and a gel pad under the pelvis. The ipsilateral arm is supported with the elbow flexed over the chest and the contralateral arm is tucked next to the torso with the elbow extended. A retrograde flexible ureteroscope can be used at the same time if needed. The puncture and access procedures are essentially the same as described above. A ureteral stent and nephrostomy tube are placed at the end of the procedure, as in the P group.

The single-session SFR was calculated 2–3 days after the procedure, and overall stone-free status was evaluated 4 weeks after surgery on a kidney-ureter-bladder (KUB) radiograph or a non-enhanced computed tomography scan. Patients were deemed to be stone-free if there were no residual stones or only residual stone fragments ≤ 4 mm were detected. Patients with significant residual stones were scheduled for second-look PCNL or flexible ureteroscopy 5–7 days later. Postoperative complications were assessed using the Clavien-Dindo grading system. Stone composition was analyzed by infrared spectroscopy in all cases.

Continuous data are shown as the mean ± standard deviation and were compared between the study groups by one-way analysis of variance. Categorical data are shown as the number and/or percentage and were analyzed using the chi-squared test or Fisher's exact test. All statistical analyses were performed using SPSS version 20.0 (IBM Corp., Armonk, NY, USA). A p-value < 0.05 was considered statistically significant.

Results

US-guided percutaneous renal access and stone fragmentation were performed in all 188 patients in this series. The patient background characteristics (age, sex, body mass index) and stone size were similar between the two study groups. The proportion of patients with ureteral stones was significantly higher in the S group than in the P group (20.3% vs 8.9%, p = 0.003). The numbers of renal access were significantly higher in the P group (2.1 ± 0.4 vs 1.2 ± 0.2, p = 0.002). There was no significant between-group difference in operation time (79.1 ± 14.6 minutes vs 96.2 ± 19.6 minutes, p = 0.06) or postoperative hemoglobin loss (1.7 ± 0.4 g/dl vs 1.8 ± 0.3 g/dl, p = 0.12). The postoperative hospital stay was significantly shorter in the P group than in the S group (6.2 ± 1.5 d vs 10.2 ± 1.7 d, p = 0.008). The single-session SFR was significantly lower in the S group (57.5% vs 82.9%, p < 0.001). Simultaneous retrograde flexible ureteroscopy was performed to remove ureteral stones during ipsilateral PCNL in 12 patients (20.3%) in the S group. Second-session surgery was performed in 20 of 25 patients with residual stones in the S group (RIRS, n = 3; needle-perc combined with RIRS, n = 8; second-look PCNL combined with RIRS, n = 9) and ancillary procedures were performed in 15 patients in the P group (RIRS, n = 3; second-look PCNL combined with needle-perc, n = 12). Overall, the SFR was 83% (49/59) in the S group and 91.5% (118/129) in the P group (p = 0.052). Blood transfusion was required in three patients in the P group because of moderate anemia that was present preoperatively but not in any patients in the S group. No embolization was found in either study group. The most common postoperative infectious complication was fever (> 38°C), which developed in 15/129 patients (11.6%) in the P group and in 6/59 (10.2%) in the S group. All cases were successfully managed by intravenous antibiotics. There were no cases of sepsis or septic shock in either group. One patient in the P group developed hydrothorax immediately after removal of the nephrolithotomy tube, which resolved without treatment. The rate of severe complications (Clavien-Dindo grade ≥ III) was similar in the two groups. There was no significant between-group difference in stone composition. The patient background characteristics and perioperative data are summarized in Table 1.

Table 1
Patient background characteristics and perioperative data

Parameters	P Group (n = 129)	S Group (n = 59)	*P* value
Age(years), mean ± SD	51.4 ± 11.9	49.2 ± 14.1	0.52
Gender(male/female)	72/57	32/27	0.12
BMI(kg/m^2), mean ± SD	27.5 ± 6.8	24.1 ± 3.5	0.19
Stone side(Rt/Lt)	62/67	29/29	0.22
Stone size(cm), mean ± SD	4.1 ± 1.3	4.5 ± 1.2	0.33
Stone shape,n(%)	78(60.5%)	38(64.4%)	0.58
Staghorn	51(39.5%)	21(35.6%)	
Multiple			
Ipsilateral ureteral stones	19(14.7)	18(30.5)	0.003
History of stone surgery, n(%)	5(3.9)	2(3.4)	0.12
Open	18(14)	9(23.7)	
URL/RIRS	16(12.4)	4(6.8)	
PNL			
Operative duration(min), mean ± SD	79.1 ± 14.6	96.2 ± 19.6	0.06
Number of access, mean ± SD	2.1 ± 0.4	1.2 ± 0.2	0.002
Hemoglobin loss(g/L), mean ± SD	1.7 ± 0.4	1.8 ± 0.3	0.12
Instant SFR, n(%)	107(82.9)	34(57.5)	< 0.001
Ancillary procedures, n(%)	3(2.3)	3(5.1)	0.02
RIRS	12(9.3)	9(15.3)	
Second look PCNL + Needle-perc	/	8(13.6)	
Needle-perc + RIRS			
Overall SFR, n(%)	118(91.5)	49(83)	0.052
Postoperative hospitalization (d),mean ± SD	6.2 ± 1.5	10.2 ± 1.7	0.008

Parameters	P Group (n = 129)	S Group (n = 59)	*P* value
Postoperative complications, n(%)	15(11.6)	6(10.2)	0.09
Fever	1	/	
Pleural injury	/	/	
Organ damage	3	/	
Blood transfusion	/	/	
Embolization	/	/	
Sepsis/Shock			
Stone composition, n(%)	92(71.3)	39(66.1)	0.92
Calcium-contained	18(14)	10(16.9)	
Struvite	11(8.5)	5(8.5)	
Uric acid	8(6.2)	5(8.4)	
Others			

Discussion

PCNL in the prone position has been preferred for decades and its advantages have been highlighted in many studies. Prone positioning for PCNL provides a wide surface area for puncture and affords adequate space for manipulation of the nephroscope[7, 8]. Nevertheless, this position can be contraindicated for anesthesiology reasons in patients with circulatory or ventilatory problems[9]. In recent years, the supine position has been increasingly investigated and used. Supine PCNL may be preferable in patients with cardiopulmonary disease and those who are obese because it allows optimal airway control by the anesthesiologist during surgery. The original prone position for PCNL described by Valdivia et al[10] in 1998 is seldom used now because it does not allow for simultaneous RIRS and affords limited space for renal access. Various modified supine positions have recently been proposed. The Galdakao-modified Valdivia position allows combined use of retrograde instruments in the entire urinary system simultaneously without the need for repositioning[11]. The Barts flank-free modified position has been introduced and requires a 15° tilt, which is achieved by placing a 3-l saline bag under the ipsilateral rib cage and a gel pad under the pelvis. There is no support under the flank area when using this position, which allows more space for renal access; however, the kidney is in a neutral position and less mobile, which makes the nephroscope more difficult to maneuver.[12], A variety of other modified supine positions have been proposed, including the supine oblique position[13], semi-supine position[14], and complete supine position[15]. Each modification has strengths and weaknesses. Several meta-analyses have reported that the SFR is better in the prone position but that the operation time is shorter with a lower blood transfusion rate in the supine position[3]. However, some of the published findings have been inconsistent[16]. At our center, the supine position preferred for modified flank-free

lithotomy is similar to the Galdakao-modified Valdivia position described above. All our operators routinely perform puncture and tract dilation for PCNL under US guidance, which also permits simultaneous retrograde surgery or insertion of a ureteral catheter. Our modified lithotomy position is achieved by placing the patient supine with a gel pillow under the thorax and another under the hip with the leg on the operated side extended and the contralateral leg fully abducted. Most of the previous studies of PCNL included fluoroscopic guidance and there is limited information on the use of the US-guided technique, especially in patients with complex stones. To our knowledge, this is the first study to compare outcomes of US-guided PCNL for complex renal stones on the basis of whether the patient is in the standard prone position or a modified supine position.

We found that the numbers of renal access and single-session SFR were lower when PCNL was performed in the modified supine position, which is in contrast with the findings of a meta-analysis[16] but in accordance with the conclusions reached by Yuan et al[3]. There may be several reasons for the smaller tract number and higher SFR in our P group. First, the distance between the 11th rib and the iliac crest is short in the modified supine position, which would have limited the choice of puncture site in the S group. Second, this position results in rotation of the kidney such that the posterior calyx moves to the ventral side; therefore, puncture is difficult even under US guidance. Third, the kidney is highly mobile in this position, including during access performing. Meanwhile, the lower pole of the kidney is deeper down and the distance between the skin and calyx is greater, which affects visual clarity under US and increases the difficulty of establishing the tract [Figure 1]. Although retrograde ureteroscopy was performed simultaneously in 20 patients in the S group, the stone clearance rate was still not as good as in the P group, probably because PCNL often involves bleeding more or less during the procedure, resulting in a poor endoscopic view and limited ability to use a flexible ureteroscope. The fourth reason is also related to patient positioning. The recently developed needle-perc nephroscope is now used widely to treat complex stones at our institution. The needle-perc is presently the smallest nephroscope available worldwide and has recently been confirmed to reduce perioperative complications and improve the SFR[17]. However, although needle-perc-assisted standard access is convenient in the prone position, puncture is more difficult even in a modified position because of the limited space and ventral movement of the kidney.

Although the operation time was longer in our S group, we found no statistically significant between-group difference in operation time. This finding is in accordance with that in a study by Knoll et al[18] who reported that the operation time was similar, even for mini-PCNL and standard PCNL. Our present findings may be attributed to use of a flexible ureteroscope. Frequent introduction of lithotripsy instruments, such as a fiber laser, and replacement of the retrieval basket and other equipment may prolong the operation time. Furthermore, the operation time in our P group was measured from renal puncture to placement of the nephrostomy tube and did not include the time taken for placement of the ureteral catheter, which would have contributed to the short operation time in this group.

In our study, the postoperative hospital stay was significantly shorter in the P group than in the S group, probably because of the lower single-session SFR in the S group. More patients in the S group needed a

second session to remove residual stones, which would have contributed to a longer hospital stay. Furthermore, the overall length of hospital stay was longer in both our study groups than in many previous studies[6]; however, this could reflect traditional Chinese culture and aspects of the health care system. First, many patients with complex stones are referred to our institution from different regions throughout the country and are not discharged from hospital until they have made a complete recovery. Second, because of regional inconsistencies in health care facilities, many local hospitals are poorly equipped to manage postoperative complications of PCNL. Therefore, most patients want to be sure there is no risk before leaving our center.

In this study, there were no significant differences in the rates of postoperative fever and severe complications between the two groups, which is consistent with most of the previous studies[19]. One patient in our P group developed pneumothorax after removal of the nephrostomy tube, and a thoracic drainage tube was placed for 2 days. There were no cases of sepsis or septic shock in this series, possibly because standard access was used, which may result in a lower intrapelvic pressure and reduce the possibility of pyelovenous or pyelosinus backflow and the subsequent risk of infectious complications. Moreover, there were no cases of organ damage or embolization in either of our study groups; this may reflect the routine use of US guidance, which allows tissues along the puncture path to be clearly identified. As we have reported previously[20], there have been no cases of visceral or intestinal injury since the introduction of PCNL at our center.

Three patients in our P group required blood transfusion postoperatively for anemia that had been present before surgery and were not included in our postoperative bleeding data. There was no significant difference in blood loss between the two groups, which is in line with the findings of a previous meta-analysis[19]. However, there may have been some more specific between-group differences that affected blood loss, in that patients in the S group had significantly fewer tracts than those in the control group and access-related bleeding was greater in the P group during similar operation time. We speculate that this might be related to puncture of the target calyx. Given that the kidneys are more medial and have greater mobility in the supine position, there is a greater likelihood of puncturing the anterior calyx rather than the posterior calyx, which may increase the risk of vascular injury when the tract is established.

This study had some limitations. First, it had a retrospective design, which inevitably introduced a degree of selection bias. Therefore, a prospective randomized study is needed to confirm its findings. Second, although the study was performed after the surgeons had mastered the learning curve for PCNL in both the supine position and prone position, they may have been less skilled in performing the procedure in the supine position. With improved learning and experience, better results can be anticipated.

Conclusion

This retrospective study investigated the feasibility and safety of US-guided PCNL in patients with complex kidney stones on the basis of whether the operation was performed in a modified supine position or in the traditional prone position. We found that although the modified supine position was

safe, the single-session stone clearance rate was not ideal. The modified supine position may be unsuitable for US-guided PCNL in patients with complex renal stones.

Declarations

Acknowledgment

We thank Liwen Bianji (Edanz) (www.liwenbianji.cn) for editing the English text of a draft of this manuscript.

Statement of Ethics

Not applicable.

Consent to participate statement: All written informed consent was obtained from participants. This study protocol was reviewed and approved Beijing Tsinghua Changgung Hospital Ethic Committee. An ethics statement is not applicable because this study is a retrospective study and ethics statements could be exampted.

Consent to publish statement: Informed consents of all details of medical cases and images of informed consents were obtained from participants.

Conflict of interest statement

All authors declare that they have no conflict of interest.

Funding Sources

Supported by Beijing Municipal Administration of Hospitals Clinical Medicine Development of Special Funding, code: XMLX202118

Author contributions

Bo Xiao, Xue Zeng: project development, manuscript writing

Gang Zhang, Chaoyue Ji: manuscript editing

Song Jin: manuscript editing

Wenjie Bai, Yuzhe Tang, Bixiao Wang,: data collection

Jianxing Li: project development, manuscript editing

All authors read and approved the final manuscript.

Data Availability Statement

All data generated or analysed during this study are included in this. Further enquiries can be directed to the corresponding author.

References

1. de la Rosette JJ, Tsakiris P, Ferrandino MN, Elsakka AM, Rioja J, Preminger GM. Beyond prone position in percutaneous nephrolithotomy: a comprehensive review. Eur Urol. 2008 Dec;54(6):1262–9
2. Valdivia Uría JG, Lachares Santamaría E, Villarroya Rodríguez S, Taberner Llop J, Abril Baquero G, Aranda Lassa JM. Percutaneous nephrolithectomy: simplified technic (preliminary report)]. Arch Esp Urol. 1987 Apr;40(3):177–80.
3. Yuan D, Liu Y, Rao H, Cheng T, Sun Z, Wang Y, Liu J, Chen W, Zhong W, Zhu J. Supine Versus Prone Position in Percutaneous Nephrolithotomy for Kidney Calculi: A Meta-Analysis. J Endourol. 2016 Jul;30(7):754–63
4. El-Shaer W, Kandeel W, Abdel-Lateef S, Torky A, Elshaer A. Complete Ultrasound-guided Percutaneous Nephrolithotomy in Prone and Supine Positions: A Randomized Controlled Study. Urology. 2019 Jun;128:31–37
5. Perrella R, Vicentini FC, Paro ED, Torricelli FCM, Marchini GS, Danilovic A, Batagello CA, Mota PKV, Ferreira DB, Cohen DJ, Murta CB, Claro JFA, Giusti G, Monga M, Nahas WC, Srougi M, Mazzucchi E. Supine versus Prone Percutaneous Nephrolithotomy for Complex Stones: A Multicenter Randomized Controlled Trial. J Urol. 2022 Mar;207(3):647–656.
6. Xiao B, Zhang G, Ji C, Jin S, Hu W, Bai W, Tang Y, Wang B, Li J. Percutaneous Nephrolithotomy Under X-Ray-Free Technique in Upper Urinary Stone Patients with Autosomal Dominant Polycystic Kidney Disease: Experience from a Large-Volume Stone Management Center. J Endourol. 2021 Jul;35(7):967–972.
7. Duty B, Waingankar N, Okhunov Z, Ben Levi E, Smith A, Okeke Z. Anatomical variation between the prone, supine, and supine oblique positions on computed tomography: implications for percutaneous nephrolithotomy access. Urology. 2012 Jan;79(1):67–71
8. Yuan D, Liu Y, Rao H, Cheng T, Sun Z, Wang Y, Liu J, Chen W, Zhong W, Zhu J. Supine Versus Prone Position in Percutaneous Nephrolithotomy for Kidney Calculi: A Meta-Analysis. J Endourol. 2016 Jul;30(7):754–63
9. Peces-Barba G, Rodríguez-Nieto MJ, Verbanck S, Paiva M, González-Mangado N. Lower pulmonary diffusing capacity in the prone vs. supine posture. J Appl Physiol (1985). 2004 May;96(5):1937-42
10. Valdivia Uría JG, Valle Gerhold J, López López JA, Villarroya Rodriguez S, Ambroj Navarro C, Ramirez Fabián M, Rodriguez Bazalo JM, Sánchez Elipe MA. Technique and complications of percutaneous nephroscopy: experience with 557 patients in the supine position. J Urol. 1998 Dec;160(6 Pt 1):1975–8.

11. Ibarluzea G, Scoffone CM, Cracco CM, Poggio M, Porpiglia F, Terrone C, Astobieta A, Camargo I, Gamarra M, Tempia A, Valdivia Uria JG, Scarpa RM. Supine Valdivia and modified lithotomy position for simultaneous anterograde and retrograde endourological access. BJU Int. 2007 Jul;100(1):233–6
12. Kumar P, Bach C, Kachrilas S, Papatsoris AG, Buchholz N, Masood J. Supine percutaneous nephrolithotomy (PCNL): 'in vogue' but in which position? BJU Int. 2012 Dec;110(11 Pt C):E1018-21.
13. Arrabal-Polo MA, Arrabal-Martin M, Saz T, Paiz P (2011) Emergency percutaneous nephrostomy in supine-oblique position without cushion. Urol Res 39:521–522.
14. Xu K-W, Huang J, Guo Z-H et al (2011) Percutaneous nephrolithotomy in semisupine position: a modified approach for renal calculus. Urol Res 39:467–475
15. Falahatkar S, Moghaddam AA, Salehi M et al (2008) Complete supine percutaneous nephrolithotripsy comparison with the prone standard technique. J Endourol 22:2513–2517
16. Wu P, Wang L, Wang K. Supine versus prone position in percutaneous nephrolithotomy for kidney calculi: a meta-analysis. Int Urol Nephrol. 2011 Mar;43(1):67–77.
17. Su B, Hu W, Xiao B, Ding T, Liu Y, Li J. Needle-perc-assisted endoscopic surgery for patients with complex renal stones: technique and outcomes. Urolithiasis. 2022 Feb 18. doi: 10.1007/s00240-021-01299-7. Epub ahead of print.
18. Knoll T, Wezel F, Michel MS, Honeck P, Wendt-Nordahl G. Do patients benefit from miniaturized tubeless percutaneous nephrolithotomy? A comparative prospective study. J Endourol. 2010 Jul;24(7):1075–9.
19. Liu Q, Zhou L, Cai X, Jin T, Wang K. Fluoroscopy versus ultrasound for image guidance during percutaneous nephrolithotomy: a systematic review and meta analysis. Urolithiasis. 2017 Oct 1;45(5):481-7.
20. Li J, Xiao B, Hu W, Yang B, Chen L, Hu H, Wang X. Complication and safety of ultrasound guided percutaneous nephrolithotomy in 8,025 cases in China. Chin Med J (Engl). 2014;127(24):4184–9.

Figures

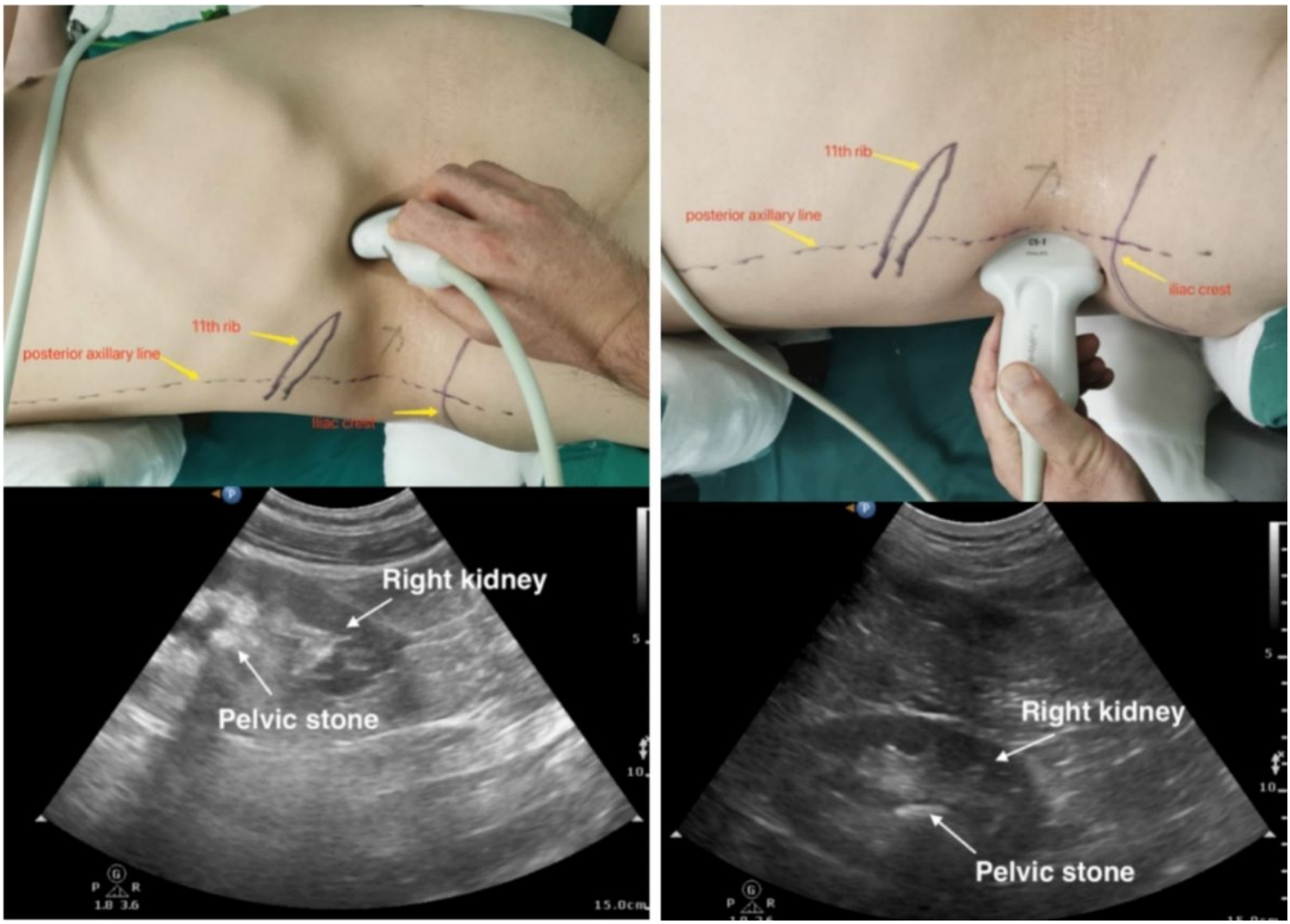

Figure 1

In modified supine position, the kidney moved ventrally in ultrasound image, and the optimal puncture point was in the anterior side of posterior axillary line