Research Square

Preprints are preliminary reports that have not undergone peer review. They should not be considered conclusive, used to inform clinical practice, or referenced by the media as validated information.

In-situ suture based on a nasoseptal mucosal flap for repair of grade 3 leaks associated with an expanded endoscopic endonasal approach

Pingan Song
the Second Affiliated Hospital of Nanchang University
Guowen Hu
the Second Affiliated Hospital of Nanchang University
Yuanyuan Xiong
the Second Affiliated Hospital of Nanchang University
Shigang Lv
the Second Affiliated Hospital of Nanchang University
Shaoguang Li
the Second Affiliated Hospital of Nanchang University
Jiang Xu
the Second Affiliated Hospital of Nanchang University
Hua Guo
the Second Affiliated Hospital of Nanchang University
Lei Wu (doctorleiming@163.com)
the Second Affiliated Hospital of Nanchang University

Research Article

Keywords: postoperative cerebrospinal fluid leak, skull base reconstruction, expanded endoscopic endonasal approaches, dural suture, nasoseptal mucosal flap

Posted Date: August 4th, 2022

DOI: https://doi.org/10.21203/rs.3.rs-1906282/v1

License: This work is licensed under a Creative Commons Attribution 4.0 International License. Read Full License

Abstract

Background

To investigate the reliability and efficacy of a modified technique for preventing postoperative grade 3 leaks associated with an expanded endoscopic endonasal approach (EEEA).

Method

This study was a retrospective review of 33 patients who presented with intraoperative grade 3 leaks after the use of an EEEA for resection of skull base lesions from January 2017 to February 2022. Patients who received the conventional method from January 2017 to December 2019 were included in Group A. Patients who received the modified in-situ suture technique from 2020 onward were included in Group B. The Whitney test and chi-square test or Fisher's exact test were conducted to analyze the differences in several postoperative outcomes between the two groups.

Result

Five cases of postoperative CSF leaks and a single intracranial infection occurred in Group A. No postoperative CSF leaks or intracranial infection occurred in Group B. The in-situ suture technique avoided the need to take autologous fat and fascia lata from the thigh ($p < 0.001$), reduced postoperative bed rest ($p < 0.001$), and decreased the incidence of postoperative CSF leaks ($p = 0.049$) and the total hospital stay ($p = 0.011$). No significant differences in re-repair, hospitalization costs or postoperative intracranial infection were noted between the two groups.

Conclusion

This modified technique could represent an effective and safe option for repairing grade 3 leaks associated with the EEEA. In the future, the focus should be on increasing the number of surgeries and continuing follow-up to monitor and evaluate the long-term efficacy of this approach.

Introduction

Through the development and modification of transsphenoidal approaches and the addition of the endoscope, an expanded endoscopic endonasal approach (EEEA) has been established and has become one of the important surgical methods to remove tumors located at the skull base[1]. When the lesion is located along the midline, EEEA is a better surgical option than the conventional transcranial approach[2]. However, due to some limits, such as the depth within the nasal cavity, lack of blood and 2D of view, reconstruction after EEEA is more difficult and less reliable[3]. Moreover, removing more skull base bone and opening the third ventricle further increase the risk of postoperative cerebrospinal fluid (CSF) leaks[4].

In addition, postoperative CSF leaks increases the risk of intracranial infection, pneumocephalus or meningitis[5].

Hence, based on the vascularized flap concept, Hadad et al [6] proposed a multilayer repair technique in 2006, involving a vascular pedicle nasoseptal flap (VP-NSF) based on the nasoseptal artery, which greatly reduced the incidence of CSF leaks after skull base reconstruction for larger dural defects or grade 3 leaks. In general, the multilayer repair technique consists of at least three layers[7], from the inner to the outer layer. Specifically, fat grafts or synthetic grafts that fill the void created via tumor removal and reduce the risk of CSF leaks. In addition, autologous fascia lata and VP-NSF provide good watertight properties to prevent CSF leaks. In recent years, based on the multilayer repair technique, surgeons have also made some suture improvements, such as the technique of continuous suturing of the dura with fascia lata grafts, a method of 360° closure by suturing 11 points around the defect, and a nasal septum bone flap combined with VP-NSF[8-10]. These factors have further reduced the rate of CSF leaks and related complications.

Nevertheless, CSF leaks still exists after EEEA, especially when intraoperative grade 3 leaks occur. The usage of repair materials, such as autologous fat and fascia lata, can cause additional damage in the patient. Therefore, it is still necessary to improve or even invent new repair techniques. In this article, we present a modified skull base repair method that we investigated, which avoids the use of autologous fat and fascia lata. After the defect is lined with artificial dura, it is sutured in situ with a nasoseptal mucosal flap to the edge of the defective dura. By reviewing the clinical data of patients using this method and the conventional technique, we found that this modified method provides better watertightness and robust support with less patient injury.

Materials And Methods

1.5.1 Patient

We conducted a retrospective review of patients who underwent EEEA to remove skull base tumors between January 2017 and February 2022. Eighteen patients who underwent the conventional approach between January 2017 and December 2019 were included in Group A. From 2020 onward, 15 patients who used a nasoseptal mucosal flap with in-situ sutures were included in Group B. The clinical data, imaging records and pathological records of these 33 patients were also collected in a complete review. This retrospective study was approved by the ethical committee of our institution. The written informed consent was provided by all the patients.

1.5.2 Inclusion criteria

1.5.2.1 Patients aged between 18 and 70 years old;

1.5.2.2 Patients performed by EEEA;

1.5.2.3. Patients with intraoperative grade 3 leaks as determined by the grading criteria for intraoperative CSF proposed by Esposito et al[5, 11] (as described in Table 1).

1.5.3 Exclusion criteria

1.5.3.1 Patients completed standard and enhanced pituitary MRI after 3 days postoperatively;

1.5.3.2 Follow-up time after discharge is less than 3 months.

1.5.4 Surgical techniques

The specific surgical steps for resection of skull base tumors via EEEA are described in detail in several studies[12-14], and our surgical approach is broadly similar to these steps, including preparation of the VP-NSF, harvest of an autologous fat and fascial lata flap, creation of the expanded corridor, occlusion of an appropriately sized bone window to expose the tumor, tumor resection, and skull base reconstruction. We prefer bilateral nostril expanded approach. Usually, the right nostril is used to hold the endoscope and an aspirator. To have a wide space, the right middle turbinate is resected. VP-NSF is got from the right nasal septum. The free nasoseptal mucosal flap is harvested from the left posterior 1/3 of the nasal septum.

Group A used the conventional multilayer repair technique involving autologous fat- artificial dura- fascia lata-VP-NSF. The relevant conventional repair methods have been more clearly introduced14.

Group B was treated with a multilayer repair technique including Surgiflo- an artificial dura-free nasoseptal mucosal flap- VP-NSF (Figure 1). While creating the expanded corridor stage, we harvested the nasoseptal mucosal flap, which was applied to perform in-situ suturing. We peeled the mucosa from the left posterior 1/3 of the nasal septum, which was approximately 2 cm*2 cm in size (Figure 2a). After adequate disinfection of the nasoseptal mucosal flap, the flap is extended and thinned using the fascia press (Figure 2b), which makes the flap easier to suture. After extension, the flap area increased by 1.5- to 2-fold (Figure 2c). Then, the flap was preserved in saline. Regarding skull base construction, we need to appropriately trim the nasoseptal mucosal flap to obtain the proper size and appropriate edges.

In the skull base reconstruction performed on Group B, the first step of repair involved filling the dead space with Surgiflo (SURGIFLOTM, Sydmarken 5, 2860 Soeborg, Denmark). Second, an artificial dura (Tyfmedical, Changping, Beijing, China) was inlayed into the subdural space (Figure 3a), and the edge of the artificial dura needed to crossover the edge of the defective dura by at least 5 mm to ensure complete coverage of the dural defect. Subsequently, we used an in-situ suture technique based on the nasoseptal mucosal flap to close the skull base defect. A 6-0 nonabsorbable suture (PROLENE; Ethicon, San Lorenzo, Puerto Rico, USA) was utilized to fix the flap and dura. In general, the first stitch was placed to fix the flap to the top right of the defect, and the second stitch was repeated on the top left (Figure 3b, c). The direction of puncture of the dura was always from the flap to the dura edge, and the needle crossed the mucosal flap from the external side to the internal side and the dura from the internal side to the external side (Figure 3d). Continuous dura suturing was performed from right to left between the first two stitches.

Thereafter, the other three sides were sutured in an intermittent manner (Figure 3e). We used an endoscopic needle holder (Xiaoshan, Hangzhou, China) that has a rotatable 30° upangled tip and can drive the needle at various angles. Even if the needle is clipped by the tip deep within the nasal cavity, the direction of the needle can be adjusted by rotating the holder rod with the right index finger. For knotting, we prefer to employ rotation and piston motion around the string to make a circle due to the narrow and deep space. The procedure is detailed in our surgery VIDEO. Afterward, fibrin glue (Porcine Fibrin Sealant Kit; Bioseal, Guangzhou, Guangdong, China) was sprayed over the entire surface of the skull base defect and the nasoseptal mucosal flap. Then, VP-NSF was used to cover the above structures (Figure 3f). Finally, iodoform gauze was used to support the repair materials.

1.5.5 Postoperative surveillance for CSF Leaks

All patients completed standard and enhanced pituitary MRI within 3 days postoperatively to assess whether the repair material and VP-NSF had migrated and whether intracranial pneumatization had occurred. Postoperative CSF leaks was determined by an anterior tilt test. We describe two situations based on our clinical experience. (1) The enhanced VP-NSF is displaced, and rhinorrhea of CSF is noted on the anterior tilt test. The patients will be treated by LD first. Unfortunately, the re-repair will be performed on condition that the CSF leaks is still observed during LD and after lying flat for 7 days. (2) The VP-NSF is attached on the closure, but CSF rhinorrhea is detected on the anterior tilt test. Bed rest will be prolonged to 7 days. If the CSF leaks did not disappear, the patients were treated as described in (1). (3) The VP-NSF was well attached to the bone, and no drainage was noted on the anterior tilt test. The patients were judged to have no postoperative CSF leaks when they were allowed to leave the bed and move around.

In fact, repair failure of CSF leaks is obvious and characterized by continuous water drainage from the nostrils. A small amount of a thicker, light blood-like drip is not considered to represent CSF leaks.

1.5.6 Statistical analysis

Because the continuous data in this article did not obey a Gaussian distribution, they were expressed as the mean ± standard deviation and compared by the Mann—Whitney test. Categorical data are expressed as frequencies and percentages and were compared by Fisher's exact test since there was no postoperative CSF leaks in Group B. A value of $p < 0.05$ was considered statistically significant. SPSS 25.0 was employed for data analysis.

Results

January 2017 to February 2022, 33 patients underwent EEEA for resection of skull base lesions, and all of them developed Esposito's grade 3 leaks. The demographic data, tumor pathology, and postoperative CSF leaks for these patients are detailed in Table 2.

Postoperative pathology showed 19 cases of craniopharyngioma, 11 cases of meningioma, and 1 case each of olfactory neuroblastoma, Latke's cyst, and grade II gangliogliomas. All patients were followed up for at least 3 months after discharge. Five (27.78%) cases of postoperative CSF leaks occurred in Group A. Three of the patients underwent re-repair. The other 2 patients received only lumbar drainage (LD), and no further CSF leaks was noted during the subsequent follow-up. In addition, one patient developed a postoperative intracranial infection, which was confirmed by CSF culture and later cured by antibiotics. No postoperative CSF leaks or intracranial infection was observed in Group B.

The results of the statistical analysis comparing the two groups are presented in Table 3. The differences between the two groups in terms of postoperative CSF leaks ($p=0.049$), postoperative bed rest time ($p<0.001$), total days of hospitalization ($p=0.011$) and whether autologous tissues were obtained from the thigh ($p<0.001$) were statistically significant. Re-repair ($p=0.150$), intracranial infection ($p=1.000$) and postoperative hospitalization cost ($p=0.055$) did not significantly differ between the two groups.

Discussion

In this study, we investigated the reliability and effectiveness of the in-situ suture technique based on the nasoseptal mucosal flap in reducing the incidence of CSF leaks after EEEA, and further analyzed the effect of this technique in reducing the rate of postoperative intracranial infection, bed rest, hospitalization cost, total hospitalization days, and avoidance of self-thigh extraction. The results showed that the in-situ suture technique offered significant advantages compared with the conventional method in reducing postoperative bed rest, the postoperative CSF leaks rate and total hospital stay and avoiding intraoperative extraction from the thigh. This finding suggests that the multilayer repair technique including a gel foam- artificial dura- free nasal septal mucosal flap- VP-NSF represents a safe, efficient and less invasive method of skull base reconstruction.

EEEA provides a more ideal approach to possess a clearer surgical field of the ventral aspect of the skull base. The indications for EEEA are broad and allow for the treatment of many midline skull base tumors and other paramedian line lesions, such as pituitary adenomas, meningiomas, craniopharyngiomas, and chordomas[15]. In contrast to the transcranial approach, it is difficult for the dura to be repaired seamlessly using the EEEA, and the bitten skull base bone is finely fragmented. Anatomical restoration cannot be performed, which leaves a skull base defect, and there is no scalp covering the defect, which increases the risk of postoperative CSF leaks. Postoperative CSF leaks induces some complications, such as intracranial infection and intracranial pneumatosis. The CSF leaks rate could be as high as 40%[16] in an endoscopic endonasal approach. Although a multilayer repair technique based on VP-NSF reduced this rate to 6.2%[17], the incidence of postoperative CSF leaks was still as high as 10% to 19.0% for EEEA with intraoperative grade 3 leaks[11, 18, 19]. The patients included in this study all underwent EEEA and had intraoperative grade 3 leaks. We found 5 cases (27.78%) of postoperative CSF leaks in the conventional group (Group A), but no postoperative CSF leaks was noted in the modified group (Group B). The difference ($p=0.049$) in the incidence of CSF between the two groups was statistically significant. This finding indicated the safety and efficiency of the in-situ suturing technique.

Current mainstream autografts include autologous fat, fascia lata, temporalis fascia, and rectus abdominis muscle[20]. Autologous fat and the fascia lata are the most commonly used autologous repair materials. Autologous fat grafts harvested from the abdomen or the thigh are generally employed to fill the subdural dead space and are also attached to the defect to supply support[8, 21]. The fascia lata represents a major material for repair when skull base defects are large or when secondary surgery is performed and there is no available VP-NSF. Both substances are easily accessible, have sufficient reserves, exhibit good autologous compatibility and are easy to handle[14, 20]. However, grafts may cause some side effects in patients, such as migration and necrosis of grafts, mass effect on surrounding structures and even relevant meningitis[22], and could also cause wound-related issues, such as hematoma formation, wound dehiscence, or infection at the donor site[23-25]. Patients with incisions in the lower extremities stayed in bed longer due to the fear of pain. In this article, we use Surgiflo to fill the dead space and a nasoseptal mucosal flap for watertight suturing. This method eliminated the need to excise autologous fat and fascia lata from the abdomen or thighs, thus avoiding complications associated with autografts and shortening the patient's postoperative recovery time. More importantly, it was demonstrated in Group B that satisfactory surgical results could be obtained by using the nasoseptal mucosal flap for in situ suturing.

To ensure that the grafts remain in-situ and minimize CSF pressure to prevent grafts from migrating, many surgeons use buttresses, including autologous bone fragments, alloplastic rigid materials and bioresorbable materials[19, 26]. However, the rigid buttress, which often takes the shape of a small strip, cannot completely cover the skull base defect and is only embedded between the dura and the skull without being secured by screws. Thus, this buttress can easily slip and loses its supporting role, even damaging the adjacent neurovascular structures[26]. In addition, rejection and infection may occur with allogeneic materials. Moreover, it is difficult and risky to remove the buttress that is tightly adhered to the surrounding tissues if reoperation is needed after several years due to tumor recurrence. We repaired the dural defect by suturing and knotting with the free flap instead of simply embedding a buttress. This method can provide sufficient resistance against many types of pressure changes from intradural or extradural while improving the watertightness of the repair. Fewer changes in the repair material position were noted on postoperative MRI in Group B patients. We performed this technique in 15 patients, and no CSF leaks was observed postoperatively.

To make this technique safe and convenient, some recommendations are provided here. First, the dura mater of the skull base must be protected. With the exception of the true base of the meningioma, cauterizing and biting the dura of the skull base of other lesions should be avoided whenever possible. This method will preserve a sufficient dural free margin for suturing. Second, after opening the dura, it was pulled to the sides to prevent the dural flap from obstructing the visual field. Again, a relatively blood-free surgical field is maintained throughout the procedure, which reduces obstruction to the surgical field and prevents accidental injury to important structures, such as the optic nerve, internal carotid artery, and pituitary gland, while also improving the accuracy of each stitch. In addition, the dura mater must be sutured from the inside out with the edge of the dura mater first picked up with a needle tip or suction device. This method ensures that the dura mater is kept away from neurovascular structures.

Furthermore, a large, relatively flat space is required to facilitate suturing. Finally, when establishing an enlarged approach, a more extensive opening of the pterygoid sinus and nasal septum is needed.

Limitations

There are still some limitations in our investigation. Free flaps are less sterile than fascial and adipose tissue and must be adequately sterilized before suturing. However, to date, no intracranial infections have been detected in any patients in Group B. Second, the deep and narrow space and the uneven skull base make suturing and knotting more difficult. Therefore, some special tools must be used to overcome this limitation. In addition, given that the field of view is two-dimensional, the greatest challenge is to distinguish the subtle differences between different depths. When the needle tip is vertically up or down, it is difficult to detect with the naked eye, requiring up and down movements as well as lighting and rotation of the suture needle for identification. Initially, it takes 8-15 minutes to close a stitch. However, after training, the whole process can be performed in 15-30 minutes. Furthermore, the major limitation of this study is the limited number of patients, and the power of the associated statistical results is limited.

Conclusion

The in-situ suture technique was initially applied and evaluated clinically. No patients exhibited postoperative CSF leaks. The number of surgical cases and the follow-up period should be increased in the future to observe and evaluate the long-term efficacy of this technique. In conclusion, this modified technique may represent a better repair option for skull base reconstruction.

Declarations

2.1 Ethical Approval and Consent to participate

Approval was granted by the Ethics Committee of the Second Affiliated Hospital of Nanchang University. The written informed consent was obtained from all individual participants included in the study.

2.2 Human and Animal Ethics

This study was performed in line with the principles of the Declaration of Helsinki. Animal Ethics is not applicable.

2.3 Consent for publication

The authors affirm that human research participants provided informed consent for publication of the images in Figure2 and 3.

2.4 Availability of supporting data

Not applicable.

2.5 Competing interests

The authors declare no conflicts of interest.

2.6 Funding

This study was supported by Natural Science Foundation of Jiangxi Province (20192BAB205077).

2.7 Authors' Contributions

Lei Wu and Guowen Hu contributed to the study conception and design. Material preparation, data collection and analysis were performed by Pingan Song, Shaoguang Li, Jiang Xu, Yuanyuan Xiong and Shigang Lv. The first draft of the manuscript was written by Pingan Song and Guowen Hu. Hua Guo and Lei Wu revised the manuscript. All authors read and approved the final manuscript. All authors agree to be accountable for all aspects of the work in ensuring that questions related to the accuracy or integrity of any part of the work are appropriately investigated and resolved.

2.8Acknowledgements

Not applicable.

2.9 Authors' information

2.9.1 The names of the authors: #Pingan Song[1], #Guowen Hu[1], Yuanyuan Xiong[1], Shigang Lv[1], Shaoguang Li[1], Jiang Xu[1], Hua Guo[1], Lei Wu[1]

1 Department of Neurosurgery, the Second Affiliated Hospital of Nanchang University

# Pingan Song and Guowen Hu contributed equally to this work.

2.9.2 Messages of institution at which the work was performed:

 Name: the Second Affiliated Hospital of Nanchang University;

 Address: No. 1 Minde Road, Donghu District, Nanchang City, Jiangxi Province; 330006 NanChang, China;

 Telephone: 0791-86120120, 0791-86311396;

2.9.3 E-mail address of the author responsible for correspondence: Lei Wu, doctorleiming@163.com.

References

1. Kassam A, Snyderman CH, Mintz A, Gardner P, Carrau RL (2005) Expanded endonasal approach: the rostrocaudal axis. Part I. Crista galli to the sella turcica. Neurosurg Focus 19:E3

2. Alalade AF, Ogando-Rivas E, Boatey J, Souweidane MM, Anand VK, Greenfield JP, Schwartz TH (2018) Suprasellar and recurrent pediatric craniopharyngiomas: expanding indications for the extended endoscopic transsphenoidal approach. J Neurosurg Pediatr 21:72–80.https://doi.org/10.3171/2017.7.PEDS17295
3. Powell M (2009) Microscope and endoscopic pituitary surgery. Acta Neurochir (Wien) 151:723–728.https://doi.org/10.1007/s00701-009-0297-2
4. Raza SM, Schwartz TH (2015) Multi-layer reconstruction during endoscopic endonasal surgery: how much is necessary? World neurosurgery 83:138–139.https://doi.org/10.1016/j.wneu.2014.07.004
5. Conger A, Zhao F, Wang X, Eisenberg A, Griffiths C, Esposito F, Carrau RL, Barkhoudarian G, Kelly DF (2018) Evolution of the graded repair of CSF leaks and skull base defects in endonasal endoscopic tumor surgery: trends in repair failure and meningitis rates in 509 patients. Journal of neurosurgery 130:861–875.https://doi.org/10.3171/2017.11.JNS172141
6. Hadad G, Bassagasteguy L, Carrau RL, Mataza JC, Kassam A, Snyderman CH, Mintz A (2006) A novel reconstructive technique after endoscopic expanded endonasal approaches: vascular pedicle nasoseptal flap. The Laryngoscope 116:1882–1886.https://doi.org/10.1097/01.mlg.0000234933.37779.e4
7. Wang EW, Zanation AM, Gardner PA, Schwartz TH, Eloy JA, Adappa ND, Bettag M, Bleier BS, Cappabianca P, Carrau RL, Casiano RR, Cavallo LM, Ebert CS, Jr., El-Sayed IH, Evans JJ, Fernandez-Miranda JC, Folbe AJ, Froelich S, Gentili F, Harvey RJ, Hwang PH, Jane JA, Jr., Kelly DF, Kennedy D, Knosp E, Lal D, Lee JYK, Liu JK, Lund VJ, Palmer JN, Prevedello DM, Schlosser RJ, Sindwani R, Solares CA, Tabaee A, Teo C, Thirumala PD, Thorp BD, de Arnaldo Silva Vellutini E, Witterick I, Woodworth BA, Wormald PJ, Snyderman CH (2019) ICAR: endoscopic skull-base surgery. International forum of allergy & rhinology 9:S145-s365.https://doi.org/10.1002/alr.22326
8. Xue H, Yang Z, Liu J, Wang X, Bi Z, Liu P (2021) Continuous dural suturing for closure of grade 3 leaks after tumor removal via an endoscopic endonasal approach. Neurosurgical review 44:373–380.https://doi.org/10.1007/s10143-019-01199-w
9. Omura K, Nomura K, Mori R, Ishii Y, Aoki S, Takeda T, Tochigi K, Tanaka Y, Otori N, Kojima H (2022) Optimal Multiple-Layered Anterior Skull Base Reconstruction Using a 360° Suturing Technique. Operative neurosurgery (Hagerstown, Md.) 22:e1-e6.https://doi.org/10.1227/ons.0000000000000013
10. Luo C, Liu X, Xie S, Hong T, Tang B (2022) Experience and modification of skull base reconstruction results in lower complications rates. Acta Neurochir (Wien) 164:1127–1133.https://doi.org/10.1007/s00701-021-05082-w
11. Esposito F, Dusick JR, Fatemi N, Kelly DF (2007) Graded repair of cranial base defects and cerebrospinal fluid leaks in transsphenoidal surgery. Operative neurosurgery (Hagerstown, Md.) 60:295–303; discussion 303 – 294.https://doi.org/10.1227/01.Neu.0000255354.64077.66
12. Kassam AB, Thomas A, Carrau RL, Snyderman CH, Vescan A, Prevedello D, Mintz A, Gardner P (2008) Endoscopic reconstruction of the cranial base using a pedicled nasoseptal flap. Neurosurgery

63:ONS44-52; discussion ONS52-43.https://doi.org/10.1227/01.neu.0000297074.13423.f5

13. Heng L, Zhang S, Qu Y (2020) Cross-reinforcing suturing and intranasal knotting for dural defect reconstruction during endoscopic endonasal skull base surgery. Acta Neurochir (Wien) 162:2409–2412.https://doi.org/10.1007/s00701-020-04367-w
14. Snyderman CH, Wang EW, Zenonos GA, Gardner PA (2020) Reconstruction after endoscopic surgery for skull base malignancies. Journal of neuro-oncology 150:463–468.https://doi.org/10.1007/s11060-020-03465-0
15. Oostra A, van Furth W, Georgalas C (2012) Extended endoscopic endonasal skull base surgery: from the sella to the anterior and posterior cranial fossa. ANZ J Surg 82:122–130.https://doi.org/10.1111/j.1445-2197.2011.05971.x
16. Gardner PA, Kassam AB, Thomas A, Snyderman CH, Carrau RL, Mintz AH, Prevedello DM (2008) Endoscopic endonasal resection of anterior cranial base meningiomas. Neurosurgery 63:36–52; discussion 52 – 34.https://doi.org/10.1227/01.Neu.0000335069.30319.1e
17. Coucke B, Van Gerven L, De Vleeschouwer S, Van Calenbergh F, van Loon J, Theys T (2022) The incidence of postoperative cerebrospinal fluid leakage after elective cranial surgery: a systematic review. Neurosurgical review 45:1827–1845.https://doi.org/10.1007/s10143-021-01641-y
18. Luginbuhl AJ, Campbell PG, Evans J, Rosen M (2010) Endoscopic repair of high-flow cranial base defects using a bilayer button. The Laryngoscope 120:876–880.https://doi.org/10.1002/lary.20861
19. Lee IH, Kim DH, Park JS, Jeun SS, Hong YK, Kim SW (2021) Cerebrospinal fluid leakage repair of various grades developing during endoscopic transnasal transsphenoidal surgery. PloS one 16:e0248229.https://doi.org/10.1371/journal.pone.0248229
20. Ein L, Sargi Z, Nicolli EA (2019) Update on anterior skull base reconstruction. Curr Opin Otolaryngol Head Neck Surg 27:426–430.https://doi.org/10.1097/MOO.0000000000000572
21. Lam K, Luong AU, Yao WC, Citardi MJ (2018) Use of Autologous Fat Grafts for the Endoscopic Reconstruction of Skull Base Defects: Indications, Outcomes, and Complications. American journal of rhinology & allergy 32:310–317.https://doi.org/10.1177/1945892418773637
22. Ludwig CA, Aujla P, Moreno M, Veeravagu A, Li G (2015) Intracranial fat migration: A newly described complication of autologous fat repair of a cerebrospinal fluid leak following supracerebellar infratentorial approach. International journal of surgery case reports 7c:1–5.https://doi.org/10.1016/j.ijscr.2014.12.008
23. Ringel B, Abergel A, Horowitz G, Safadi A, Zaretski A, Yanko R, Margalit N, Fliss DM (2021) Skull Base Reconstruction with Multilayered Fascia Lata: A Single-Center 17 Years Experience. Journal of neurological surgery. Part B, Skull base 82:e217-e223.https://doi.org/10.1055/s-0039-3402013
24. Shen M, Qiao N, Shou X, Chen Z, He W, Ma Z, Ye Z, Zhang Y, Zhang Q, Zhou X, Cao X, Zhao Y, Li S, Wang Y (2022) Collagen sponge is as effective as autologous fat for grade 1 intraoperative cerebral spinal fluid leakage repair during transsphenoidal surgery. Clinical neurology and neurosurgery 214:107131.https://doi.org/10.1016/j.clineuro.2022.107131

25. Di Vitantonio H, De Paulis D, Del Maestro M, Ricci A, Dechordi SR, Marzi S, Millimaggi DF, Galzio RJ (2016) Dural repair using autologous fat: Our experience and review of the literature. Surgical neurology international 7:S463-468.https://doi.org/10.4103/2152-7806.185777
26. Qi Q, Zhang Y, Wang J, Zhong H, Chen H, Wang C, Wang J, Cai X, Sun L, Ni S (2021) Deployment of a bioabsorbable plate as the rigid buttress for skull base repair after endoscopic pituitary surgery. Gland surgery 10:1010–1017.https://doi.org/10.21037/gs-20-642

Tables

Table 1

CSF leak grading system proposed by Esposito et al.

Grade of leak	Description of leak
Grade 0	Absence of CSF leak, confirmed by Valsalva maneuver
Grade 1	Small “weeping” leak, confirmed by Valsalva maneuver, without obvious or with only small diaphragmatic defect
Grade 2	Moderate CSF leak, with obvious diaphragmatic defect
Grade 3	Large CSF leak, typically created as part of EEEA through the supradiaphragmatic or clival dura for tumor access

Table 2
Clinical and demographic characteristics of patients.

	Group A	Group B	Total
	n = 18	n = 15	33
Gender			
Male	9	5	14
Female	9	10	19
Age	46.28 ± 11.28	41.53 ± 14.11	44.12 ± 12.66
Pathology			
Craniopharyngioma	11	8	19
Meningioma	5	6	11
Rathke's cleft cyst	1	0	1
Olfactory neuroblastoma	1	0	1
Grade Ⅱ ganglioglioma	0	1	1
Diameter of tumor	22.74 ± 9.34	24.43 ± 7.46	23.51 ± 8.45

Table 3
Comparison of postoperative indexes between group A and group B.

	Group A	Group B	P. Value
	n = 18	n = 15	
Re-repair	3(16.67%)	0	0.150
Intracranial infection	1(5.56%)	0	1.000
Postoperative CSF leakage	5(27.78%)	0	0.049
Incision of lower extremities	18(100.00%)	0	0.000
bed rest time (days)	10.78 ± 5.77	4.80 ± 1.32	0.000
Hospitalization days (days)	25.11 ± 14.17	17.60 ± 4.88	0.011
Hospitalization costs (CNY)	71464.72 ± 24895.96	59906.67 ± 7448.54	0.055

Figures

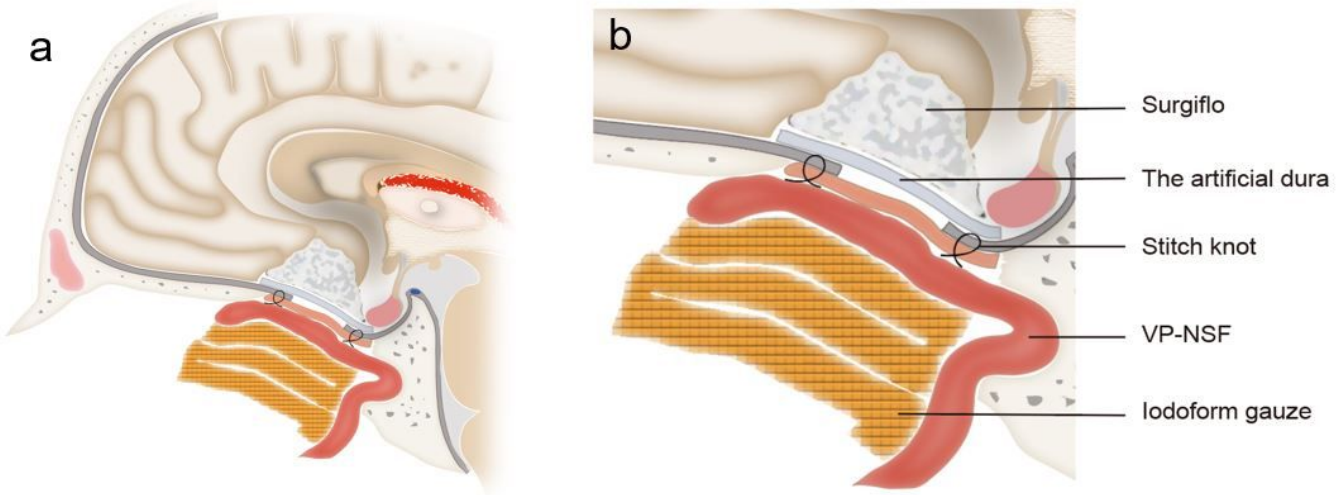

Figure 1

Schematic depiction of the sagittal position of in-situ suture technique.

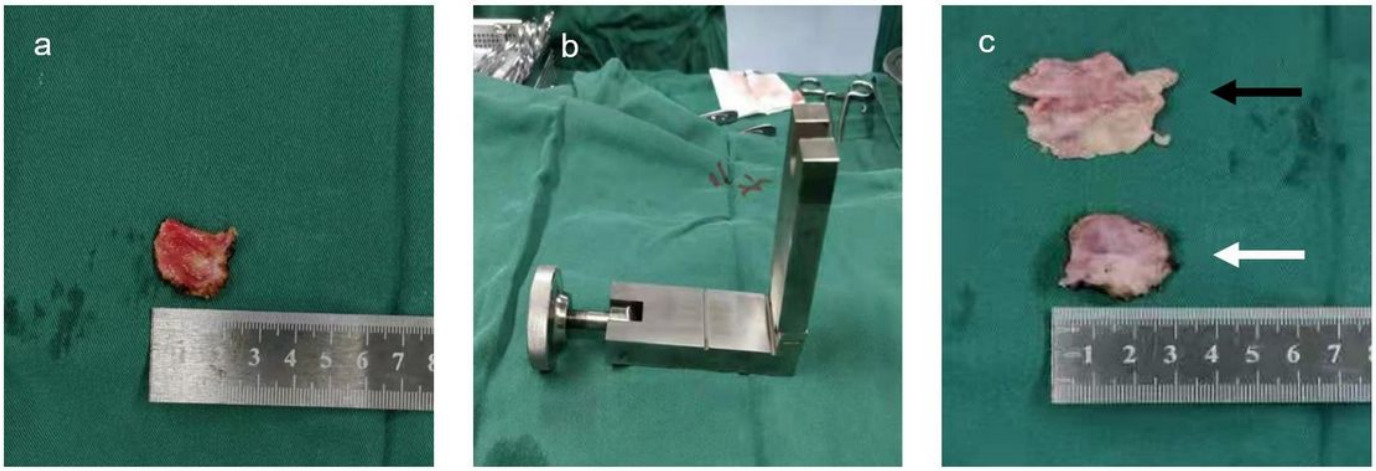

Figure 2

Create the nasoseptal mucosal flap and thin the flaps with a fascia press. (**a)** The size of the free mucosal flap taken from the rear 1/3 of the left septum mucosa is approximately 2 cm* 2 cm. (**b**) The nasoseptal mucosal flap was thinned and enlarged using the fascia press. (**c**) The size of the flaps will be enlarged by 1.5- to 2-fold. The black arrow represents the resected middle turbinate, and the white arrow refers to the free left septum mucosa flap.

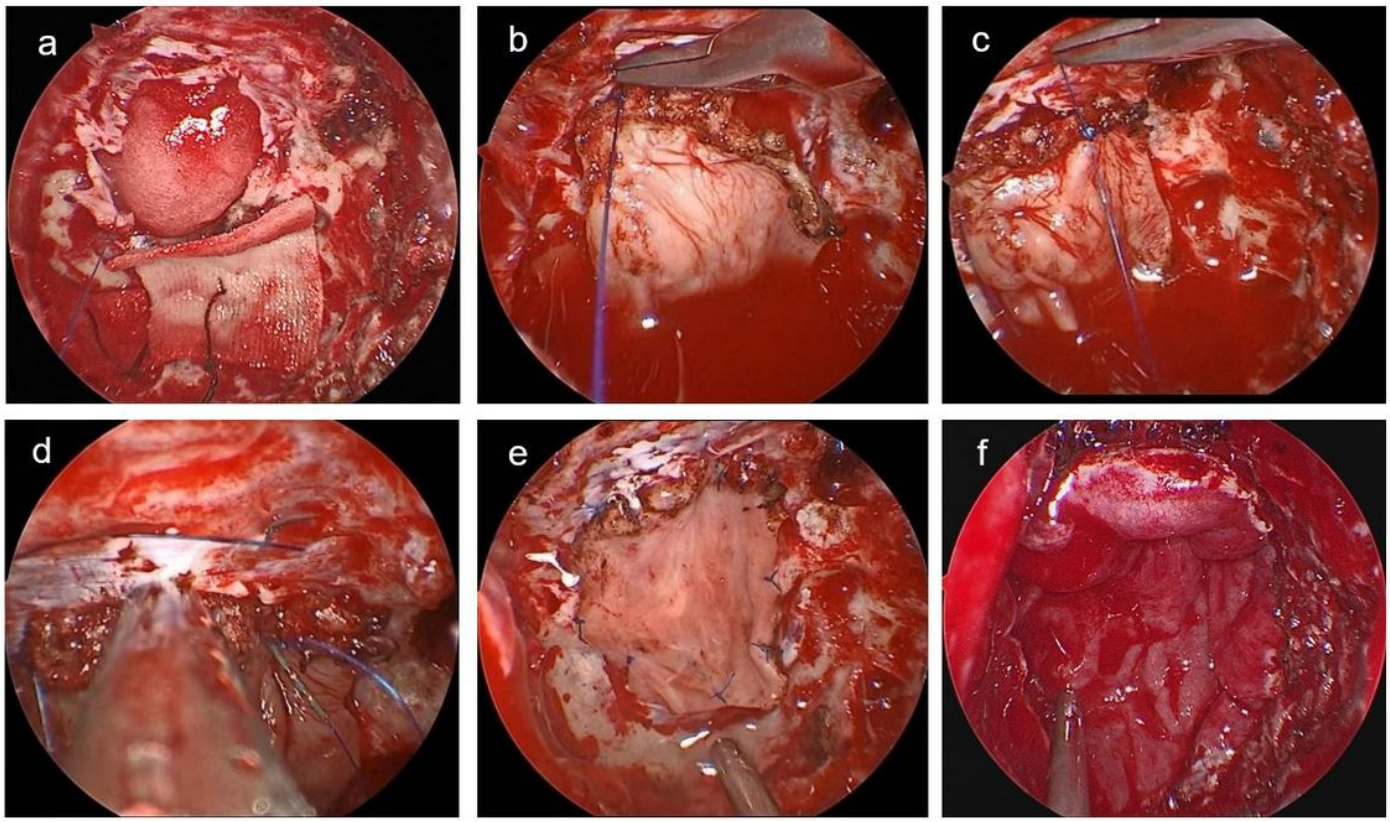

Figure 3

Steps of skull base reconstruction under endoscopic view. (a) The artificial dura was placed between the cerebrum and the dura. (b) The first stitch fixes the free mucosal flap to the top right of the dura defect. (c) The second stitch was placed at the top left. (d) The direction was always from the flap to the dural edge. (e) Continuous dural suturing was performed from right to left between the first two stitches, and then the other three sides were fixed in an intermittent manner. (f) The VP-NSF was deposited on the surface of the dural closure and skull bone.

Supplementary Files

This is a list of supplementary files associated with this preprint. Click to download.

- Procedureofinsitusuturetechnique.mp4
- Video.docx