Electrographic lead I and V5 monitoring could have detected a missed left-side pneumothorax intraoperatively.

Chihjen Lee, M.D. (chih-jen.lee@cshs.org)
Roya Yumul, M.D.
Colby Vongchaichinsri, M.D.
Kevin Tsai, M.D.
Lena Wang, M.D.

Case Report

Keywords: electrocardiogram, pneumothorax, nephrectomy, angina, dyspnea

Posted Date: August 8th, 2022

DOI: https://doi.org/10.21203/rs.3.rs-1934352/v1

Abstract

We present an EKG monitoring strategy to detect pneumothorax during high-risk surgery. In the literature, EKG changes and pneumothorax are well described. However, anesthesiologists only monitor lead II on a three-lead EKG system in the operating room. In our case, there was only a subtle change in lead II for a left-sided pneumothorax, which could have been easily missed. On the other hand, there was a marked QRS amplitude reduction and T wave flattening/inversion in lead I and V5. We recommend lead V5 be added to the continuous monitoring and lead I be periodically checked for surgeries known to potentially cause pneumothorax.

Case Description

57-year-old male with a history of thoracic aortic aneurysm and non-ST elevation myocardial infarction (NSTEMI) three months prior, underwent da Vinci robotic partial nephrectomy for a left renal mass. Preoperative laboratories including complete blood count, basic metabolic panel and coagulation were normal. EKG showed normal sinus rhythm, incomplete right bundle branch block, Left anterior fascicular block and left axis deviation at negative 44 degrees. Angiogram following the last episode of NSTEMI showed normal coronary arteries. Transthoracic echocardiogram showed ejection fraction of 64%, mild left ventricular hypertrophy, mild to moderate aortic regurgitation and normal pulmonary arterial pressure.

Intraoperative course was uneventful. Patient was induced and intubated with Fentanyl, Versed, Propofol, and Rocuronium. Anesthesia was maintained with Sevoflurane and Propofol infusion. Patient remained paralyzed with Rocuronium during surgery. Blood pressure, heart rate, oxygen saturation, end-tidal CO2 and peak airway pressure throughout surgery were all unremarkable. However, upon awakening and extubating of the endotracheal tube, patient became combative and complained of chest pain and shortness of breath. At that time, patient was breathing six liters of oxygen via a simple facial mask. Oxygen saturation was 96%. Respiratory rate was 22. Blood pressure was 147/89. Slight tachycardia at 97 was noted. Hydromorphone was initially given for agitation and pain. Patient felt comfortable and fell asleep.

Due to the history of NSTEMI, acute coronary syndrome was the first to rule out in the recovery room. Post-operative EKG showed new right superior axis at 268 degrees and markedly reduced R wave amplitude in lateral leads I and aVL, and precordial leads V2 through V6. Also noted were slight T wave inversion in V1, V2, and V2, and flattened T waves in leads 1, II, V4, V5 and V6. Voltage alternans were most visible in V2 to V6. These EKG findings were consistent with left-sided pneumothorax [3]. Stat chest X-ray was ordered, which revealed a large left-sided pneumothorax and a nearly total collapsed left lung. Troponin, complete blood count and basic metabolic panel were normal.

Chest tube was then urgently inserted, and the left lung was re-expanded. Post chest tube EKG showed restored voltages on lead I, aVL and V2 to V6, left anterior fascicular block and left axis deviation, all of which were similar to the preoperative EKG.

Discussion

Robotic nephrectomy has become a common surgical procedure in recent years. Perioperatively, pneumothorax is a rare but well-documented complication, which can potentially be life threatening if not recognized and treated promptly. However, due to the mechanical ventilation and general anesthesia, patient may not show any signs and symptoms of respiratory distress or hemodynamic changes during surgery. Also, intraoperative changes of blood pressure and heart rate are often attributed to many other factors, such as dehydration, blood loss, surgical stimulation, inadequate anesthesia depth or side effects of anesthesia medications.

Postoperative chest pain and dyspnea. In our patient, the pneumothorax was not diagnosed until after the surgery when the patient complained of chest pain and dyspnea upon awakening. Given the recent history of NSTEMI, acute coronary syndrome was the first to be ruled out. Therefore, a 12-lead EKG was ordered, which did not show ST-T changes suggestive cardiac ischemia. Instead, it showed marked reduction in voltage amplitude on lead I, aVL, and V2 through V6, suggesting left-sided pneumothorax. Since only lead II was monitored intraoperatively and it showed only subtle increase in negative voltage, pneumothorax was never suspected during surgery.

EKG change and pneumothorax. EKG changes due to pneumothorax have been well documented in the literature [1, 2, 4]. Depressed amplitude of QRS and right axis deviation are due to 2 factors:

1. Increased distance between the heart and the electrodes. The heart is rotated and displaced to the right due to increased intrathoracic pressure.

2. The newly formed air cavity between the heart and the surface electrodes could reduce electrical conductance as air is a poor electrical conductor.

Voltage alternans are associated with respiration cycles. The heart is displaced more to the left with each inspiration as more air gets into the right lung, so V4-6 showed bigger R waves with inspiration and smaller ones with expiration as the heart is displaced more to the right.

In our patient, the voltages on lead I, aVL and V2 through V6 were markedly diminished due to the insulating effect of CO_2 from pneumothorax on the left. Of note, the voltage on V1 was preserved, since V1 lead is placed to the right of the sternum. Our patient also presented with an extreme right superior EKG axis at 268 degree, which can be explained by the pre-existing left axis deviation and the newly diminished lateral lead amplitudes. After chest tube placement, the amplitude dramatically restored, and the EKG returned to near baseline.

Monitor other EKG leads. Retrospectively, the EKG changes could have been detected intraoperatively if lead I and lead V5 had been monitored. Routinely, anesthesiologists only monitor lead II due to the fact that lead II is the best lead for detecting rhythm abnormalities. Lead V5 is sometimes monitored to detect lateral wall ischemia. On the anesthesia monitor, lead I, II or III can be freely selected on the screen. We suggest that in a patient who is at risk of developing pneumothorax from a particular surgical procedure

like robotic nephrectomy, the baseline voltages of lead I, II and III should be documented and compared periodically during surgery. In addition, lead V5 should be monitored continuously.

Right sided pneumothorax. In the case of right sided surgery, e.g., right nephrectomy, the EKG changes due to right-sided pneumothorax could be different from the left-sided pneumothorax. One case reported increased voltages on lead II and flipping of V5 from positive to negative [5]. A second case reported amplitude diminution in lead I and aVR and flipping of V3 from negative to positive (poor progression). Also noted is q waves in lead II, III and aVF [6]. Another right pneumothorax also reported amplitude diminution of lead I and rotation of the heart (mostly upright V4 to biphasic V4) [7]. The carbon dioxide present in the right chest cavity might displace the heart towards left chest wall, causing the changes of voltage and axis. Rotation of the heart may affect the normal progression of QRS on precordial leads. One common finding in these case reports is diminished voltage in lead I.

Peak airway pressure. Although pneumothorax might cause an increase in peak airway pressure, however increased peak airway pressure can be attributed to many factors: Trendelenburg position, kinking of the anesthesia circuit, kinking of the endotracheal tube, right main stem intubation, and elevation of diaphragms due to insufflation of the abdominal cavity. Therefore, peak airway pressure increase alone is not diagnostic of pneumothorax.

Breath sound. Loss of breath sound on one side of the lung could be a sign of pneumothorax. However, due to the unique OR setting, the lungs could be difficult to auscultate due to the patient positioning, surgical draping, OR music or noise. In addition, right main stem intubation is a common cause of the loss of the breath sound on the left.

Positioning. Intraoperatively, the EKG monitoring is further complicated by the patient positioning. When the patient is placed in left lateral decubitus position (left side down), the position of the heart could be displaced or rotated. Therefore, the appearance of lead I, II, III, or V5 waveform could differ from that of the pre-operative twelve lead EKG [8]. It is important to document the new baseline EKG appearance after the position change. Our patient was placed in the right lateral decubitus position (right side down). Because of the support of the mediastinum, the position of the heart and the appearance of EKG waveforms do not change much. Any deviation from the new baseline after the positioning, either right or left lateral decubitus, should trigger an investigation accordingly.

Point Of Care Ultrasound. Lastly, Point Of Care Ultrasound (POCUS) has become an invaluable tool for anesthesiologists. It is portable, non-invasive, and readily available in the operating room setting. Loss of lung sliding and pulsing is a sensitive indicator for pneumothorax.

In conclusion, for surgeries with high risk of developing pneumothorax, we suggest anesthesiologists monitor lead V5 continuously and/or check lead I and lead III periodically. Voltage diminution and polarity flipping in Lead I and precordial leads could be the first sign of pneumothorax.

References

1. Baruch Klin, Itai Gueta, Haim Bibi, Shaul Baram, Ibrahim Abu-Kishk. Electrocardiographic changes in young patients with spontaneous pneumothorax: A retrospective study. Medicine (Baltimore). 2021 Jul 30;100(30): e26793. doi: 10.1097/MD.0000000000026793. Electrocardiographic changes in young patients with spontaneous pneumothorax: A retrospective study - PubMed (nih.gov)
2. R Krenke, J Nasilowski, T Przybylowski, R Chazan. Electrocardiographic changes in patients with spontaneous pneumothorax. J Physiol Pharmacol. 2008 Dec;59 Suppl 6:361 – 73. Electrocardiographic changes in patients with spontaneous pneumothorax - PubMed (nih.gov)
3. T. Kenzaka, Y. Yamazaki. Electrocardiographic findings in left-sided pneumothorax. QJM: An International Journal of Medicine, Volume 109, Issue 6, June 2016, Pages 421–422, https://doi.org/10.1093/qjmed/hcw009 Electrocardiographic findings in left-sided pneumothorax | QJM: An International Journal of Medicine | Oxford Academic (oup.com)
4. J W Kleine, J A Roorda. Pneumothorax during anesthesia with changes in ECG. Acta Anaesthesiol Belg. 1976;27(1):21–4. Pneumothorax during anesthesia with changes in ECG - PubMed (nih.gov)
5. Glenn B. Paige, MD; Kenneth Spalding, MD. Electrocardiographic Changes as the First Indicator of a Right Pneumothorax in an Anesthetized Child. Anesthesiology. November 1996, Vol. 85, 1200–1202. https://doi.org/10.1097/00000542-199611000-00032 Electrocardiographic Changes as the First Indicator of a Right Pneumothorax in an Anesthetized Child | Anesthesiology | American Society of Anesthesiologists (asahq.org)
6. Dimitrios Tsilakis, Athanasios Kranidis, Spyridon Koulouris, Antonis Manolis. ECG Changes Associated With Right-Sided Pneumothorax. HOSPITAL CHRONICLES 2007,2(3): 108–110 (PDF) ECG Changes Associated With Right-Sided Pneumothorax (researchgate.net)
7. Hiroyuki Yamamoto, Kazuhiro Satomi and Yoshiyasu Aizawa. Electrocardiographic manifestations in a large right-sided pneumothorax. BMC Pulm Med (2021) 21:101. https://doi.org/10.1186/s12890-021-01470-1 Electrocardiographic manifestations in a large right-sided pneumothorax (biomedcentral.com)
8. M. G. Adams and B. J. Drew, “Body position effects on the ECG,” Journal of Electrocardiology, vol. 30, no. 4, pp. 285–291, 1997. View at: Publisher Site

Declarations

1. There is no funding.
2. A written consent for publication is obtained from the patient.
3. There is no conflict of interests.

Figures

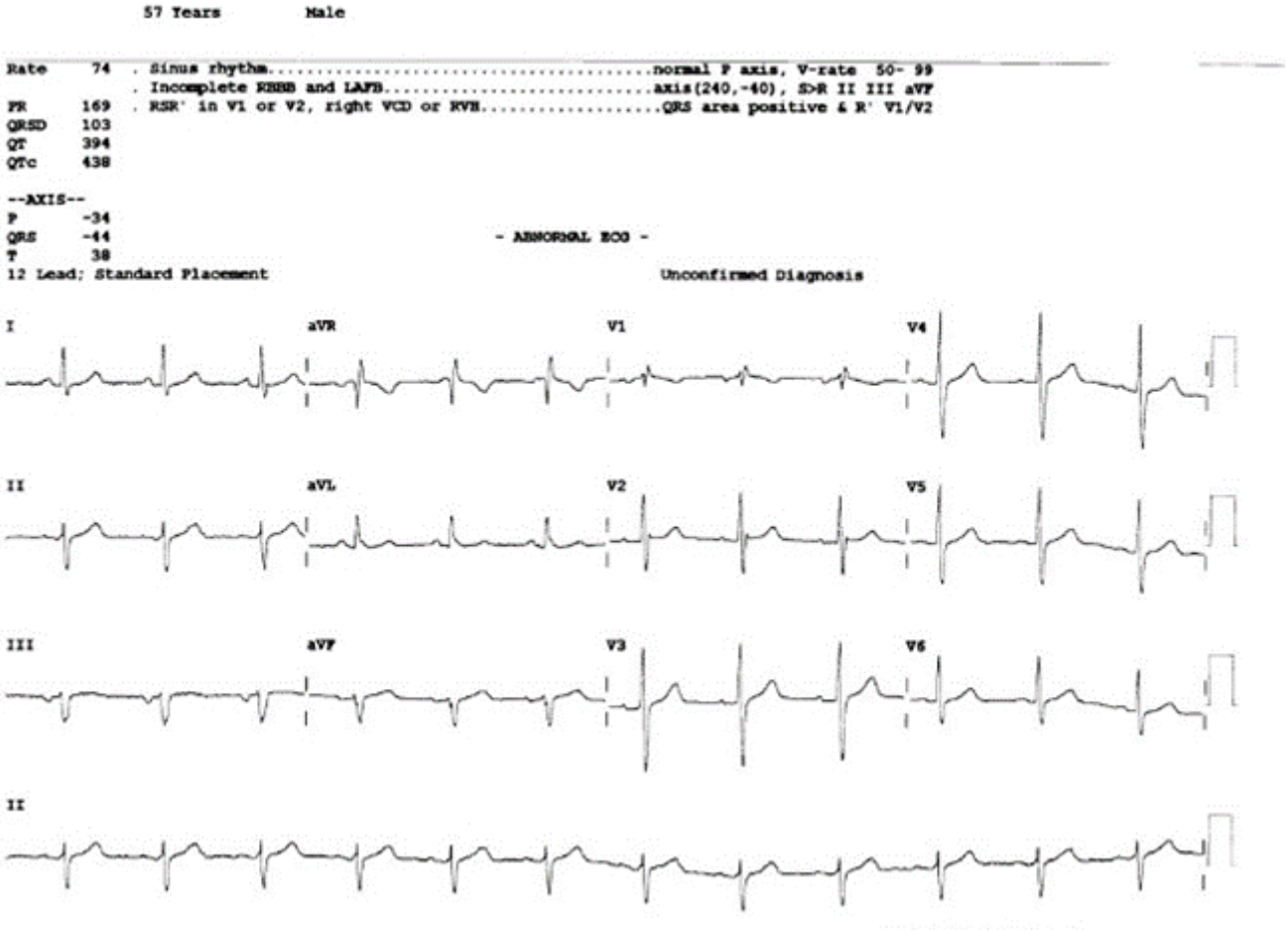

Figure 1

Preop EKG

Figure 2

Postop EKG

Figure 3

Post-op CXR

Figure 4

Post-Chest-tube EKG