CT Differential Diagnosis of COVID-19 and Non-COVID-19 in Symptomatic Suspects: A Practical Scoring Method

Lin Luo
The University of Hongkong-shenzhen hospital
Zhendong Luo
The University of Hongkong-Shenzhen Hospital
Yizhen Jia
The University of Hongkong-Shenzhen hospital
Cuiping Zhou
The University of Hongkong-Shenzhen hospital
Jianlong He
The Uinversity of Hongkong-Shenzhen hospital
Jianxun Lyu
The University of Hongkong-Shenzhen Hospital
Xinping Shen (szshenxinping@163.com)
Department of Radiology, The University of Hong Kong - Shenzhen Hospital,No.1, Haiyuan road Futian District, Shenzhen 518000, China

Research article

Keywords: Coronavirus infections, Pneumonia, Tomography, x-ray computed, Lung diseases

Posted Date: April 8th, 2020

DOI: https://doi.org/10.21203/rs.3.rs-19438/v1

Version of Record: A version of this preprint was published at BMC Pulmonary Medicine on May 7th, 2020. See the published version at https://doi.org/10.1186/s12890-020-1170-6.

Abstract

Background

Although typical and atypical CT image findings are reported in current studys, overlapping CT image features with viral pneumonia and other respiratory diseases also make difficulties on exclusion diagnosis. To explore a CT practical scoring system to differentia suspected COVID-19 in general hospital.

Methods

Thirty confirmed cases of COVID-19 and fourty-three cases of other etiology or clinical confirmed non-COVID-19 in a general hospital were included. The clinical data including age, sex, exposure history and laboratory parameters of all patients were collected. Seven positive signs (posterior part/ lower lobe predilection, bilateral involvement, rounded GGO, subpleural bandlike GGO, crazy-paving pattern, peripheral distribution, GGO +/- consolidation) from significant COVID-19 CT image features and four negative signs (only one lobe involvement, only central distribution, tree-in-bud sign, bronchial wall thickening) from other pneumonia significant image features were set. Scoring analysis of CT features were compared between the two groups (COVID-19 and non-COVID-19).

Results

Older age, symptoms of diarrhea, exposure history of Wuhan, lower level of white blood cell and lymphocyte count were significantly suggestive of COVID-19 rather than Non- COVID-19 ($p<0.05$). The receiver operating characteristic (ROC) curve of combined CT image features analysis revealed area under the curves (AUC) of the scoring system was 0.854. These cut-off values yielded a sensitivity of 56.67% and a specificity of 95.35% for Score>4, a sensitivity of 100% and a specificity of 23.26% for Score>0, and a sensitivity of 86.67% and a specificity of 67.44% for score>2.

Conclusions

With a simple and practical scoring system based on the CT image features, we can make a hierarchical diagnosis on COVID-19 and non-COVID-19 with different management suggestion.

Background

2019 novel coronavirus disease (COVID-19) has become a global viral pendemic and public health problem of international concern. According to the guideline of COVID-19 (Trial Version 7th) China[1], COVID-19 confirmed cases need to be refer to a designated hospital while suspected cases to be quarantined under medical surveillance. The medical care for quarantined patients and isolation for their closed contact people make it larger public health surveillance and response systems with a big medical burden. Chest CT with quick result could be positive prior to positive real-time fluorescence polymerase chain reaction (RT-PCR)[2-4]. Although typical and atypical CT image findings are reported in several

papers [5-15], overlapping CT image features with viral pneumonia and other respiratory diseases also make difficulties on exclusion diagnosis. We try to make a simply method to stratify strongly suspicious cases or strongly exclusive cases with different requirement to repeat RT-PCR. And, identification of exclusive cases may also seen to reduce the medical burden.

Methods

Patients

We retrospectively enrolled 30 cases of COVID-19 confirmed with WHO interim guidance and 43 cases of other etiology or clinical confirmed non-COVID-19 in a general hospital from Jan 10 to Feb 28, 2020. COVID-19 suspected cases with abnormal chest CT findings were included with following inclusive criterias[1]: (1) epidemiological exposure history within 14 days before the onset of symptoms – i) travel/residence history in Wuhan; ii) travel/residence history in Hubei not Wuhan; iii) exposure history to confirmed cases or community, respiratory symptoms related patient; iv) cluster onset; (2) presented with fever and/or respiratory symptoms within 7 days from CT examination; (3) Normal or low white blood cell count and lymphocyte count in early onset. All patients underwent high-resolution CT within 7 days before the onset of symptoms and in his first consultation to hospital. Exclusion criteria: (1) images with excessive motion artifact; (2) children and pregnant women.

The clinical data including age, sex, exposure history and laboratory parameters of all patients are summarised in Table 1.

Pathogenic evidence: nucleic acid test by RT-PCR was used to detect the new coronavirus in respiratory samples. All enrolled patients had final diagnoses by twice positive RT-PCR to confirmed COVID-19, more than or equal to twice negative RT-PCR (range 2-5 times) or at least one negative RT-PCR with other pathogen (mycoplasma pneumonia, Human immunodeficiency virus and influenza) confirmed or community-acquired pneumonia with resolved follow-up chest CT findings after treatment.

CT image data acquisition

CT scans were done ≤7 days after symptom onset on helical 64-slice CT GE (Lightspeed Ultra 16, USA; 1.25mm slice thickness; 1.5pitch; 120 kVP tube voltage; 100-200mAs tube current; sagittal and coronal reconstruction thickness, 3mm with 3-mm intervals) or Siemens (Somatom Definition AS, Germany; 1mm slice thickness; 1.2pitch; 120 kVP tube voltage; 100-200mAs tube current; sagittal and coronal reconstruction thickness, 3mm with 3-mm intervals; and a sharp reconstruction kernel)

CT image analysis

We summarized several significant COVID-19 CT image features by reviewing reported papers published or e-published of chest CT findings from COVID-19 outbreak in China recently in Table 2. And referring with other CT image signs in viral pneumonia[16; 17] or community-acquired pneumonia[16; 18], we set seven positive signs from significant COVID-19 image features and four negative signs from other

pneumonia significant image features as in Table 3 and Figure 1. Briefly, visual scores were defined as follows: score 1, positive significant COVID-19 image features; score -1, non-COVID-19 with viral pneumonia or community-acquired pneumonia image features. An overall score was reached by summing the eleven features score in Table 4.

Image analysis focused on the features of each patient, including (a) number of lobes involved, (b) lesions and distribution characteristics (e.g., peripheral distribution, central distribution, subpleural distribution, posterior distribution), (c) lesion patterns (e.g., ground glass opacification(GGO) with or without consolidation, crazy-paving pattern, the shape of GGO), (d) other signs in the lesion (e.g., Bronchial and/or Bronchiolar wall thickening), and (e) other findings (e.g., Tree-in-bud sign). Ground glass opacification was defined as hazy opacity that did not obscure underlying bronchial and vascular margins; consolidation was defined as opacification with obscuration of bronchial structures and pulmonary vessels [19](Fig. 1A, 1B). Crazy-paving pattern is ground-glass opacity superimposed with lines of reticular patterns [20](Fig. 1C). The rounded GGO is a round shape GGO in any plane (Fig. 1A). The subpleural bandlike GGO is a pronounced peripheral, subpleural distribution along with axial pleura(Fig.1D). Central (peribronchovascular) distribution was defined as typically around the bronchiolar vascular bundle and spared the subpleural surfaces. They are typically at least 5-10 mm away from the pleural surfaces[21]. (Fig. 1E) The tree-in-bud sign was defined as peripheral, small, centrilobular, and well-defined nodules of soft-tissue attenuation connecting to linear, branching opacities that have more than one contiguous branching site[22] (Fig. 1F).

CT images were reviewed retrospectively and independently by two cardiothoracic radiologists (A, with 25 years of experience, and B with 15 years of experience), who knew that patients had suspicious COVID-19 exposure history, but were blind any other laboratory or RT-PCR data. When discrepancy of image feature definition and diagnoses existed between the two radiologists, the final result was decided according to their consensus.

Statistical analysis

Continuous variables were presented as medians with interquartile ranges (IQR). Categorical variables were summarized as counts and percentages. Differences between the two groups (confirmed COVID-19 vs. confirmed non-COVID-19) were compared for continuous and categorical variables by Mann-Whitney U test and chi-squared test respectively. $P<0.05$ was considered as statistically significant. ROC curve was used to determine the cut-off value of COVID-19 prediction. The performance of each cut-off value was evaluated as sensitivity, specificity, positive and negative predictive values. All analyses were performed with MedCalc Statistical Software, version 18.11.3.

Results

Characteristics and clinical laboratory findings

This retrospective study included 73 patients, of which 30 were confirmed as COVID-19 positive by RT-PCR, and 43 were classified as non-COVID-19 who were finally confirmed by RT-PCR of COVID-19 negative and other pathogen positive or clinical treatment (Table 1). In this study, 37 were male (50.7%) and 36 were female (49.3%). There was no significant difference in gender between this two groups. 53.3% of COVID-19 group and 46.5% of non-COVID-19 group were female. Patients in COVID-19 group were significant older (median age 54 years, IQR 36-64, p<0.01) than those in non-COVID-19 group (median age 37 years, IQR 32-47). The majority of COVID-19 group had exposure history of Wuhan (n=24, 80%) while most patients(n=30, 69.8%) of non-COVID-19 group had no history of Hubei contact or cluster onset . Fever (61.6%) and cough (67.1%) were the most common symptoms presented in the majority of both groups. Only COVID-19 had 4 (13.3%) patients presented with diarrhea. In non-COVID-19 group, 3 patients (7%) and only 1 patient (2.3%) had symptoms of running/stuffy nose and chest pain respectively, which were not presented in COVID-19 group in our study. White blood cell count and lymphocyte count of all patients were within normal range. But the level of white blood cell count of COVID-19 (median 5.43g/L, IQR 4.25-6.12g/L) was significant lower (p<0.001) than non-COVID-19 group (median 7.67g/L, IQR 6.73-9.06g/L). The level of lymphocyte count in COVID-19 (median 1.32g/L,,IQR 1.08-1.69g/L) was also significant lower (p<0.001) than non-COVID-19 group (median 1.93g/L (IQR 1.54-2.64g/L).

CT imaging findings

High-resolution chest CT scans were performed for all 30 patients with COVID-19 and 43 patients with non-COVID-19. Selected chest CT image features were shown in Table 3. Selected chest CT image features were shown in Table 3. One of the most common image features shared by COVID-19 (n=27, 90%) and non-COVID-19 (n=39, 90.7%) group was GGO with or without consolidation (n=66, 90.4% in all patients). Posterior part or lower lobe predilection (n=66, 90.4% in all patients), which was another most common image feature, presented in 30 (100%) COVID-19 patients and in 36 (83.7%) non-COVID-19 patients. More cases in COVID-19 (n=29, 96.7%, p<0.01) group showed peripheral distribution compared with non-COVID-19(n=29, 67.4%) group. Crazy-paving pattern presented in 76.7% of COVID-19 and 32.6% of non-COVID-19. Bilateral lungs were involved in 60.0% of COVID-19 and 15% of non-COVID-19, respectively. Rounded GGO (n=8, 26.7%) and subpleural bandlike GGO (n=14, 46.7%) were not pretty common in COVID-19, but rarely seen in non-COVID-19 (Rounded GGO, n=1, 2.3%; subpleural bandlike GGO, n=2, 4.7%).

Of the 30 COVID-19 patients, 9 (30.0%) had only one lobe involvement, one (3.3%) had only central (peribronchovascular) distribution, one (3.3%) had bronchial wall thickening with no one presented tree-in-bud sign. In contrast, of the 43 non-COVID-19 patients, 25 (58.1%) had only one lobe involvement, 14 (32.6%) had only central (peribronchovascular) distribution, 11 (25.6%) had bronchial wall thickening and 6 (14.0%) presented tree-in-bud sign.

Based on the 11 CT image features listed in Table 3, we calculated the total score for each patient. The median score of COVID-19 group was 4 (IQR 2-5), which was significant higher (P<0.001) than non-COVID-19 group (median 2, IQR 0-2). The performance of our scoring system for the diagnosis of COVID-

19 is shown in Table 4. The receiver operating characteristic (ROC) curve of combined CT image features analysis revealed the area under the curves (AUC) of our scoring system was 0.854 (95%CI: 0.752 -0.926), p<0.001(Fig.2). The cut-off values yielded a sensitivity of 56.67% and a specificity of 95.35% for Score>4, a sensitivity of 100% and a specificity of 23.26% for Score>0, and a sensitivity of 86.67% and a specificity of 67.44% for Score>2 (Table 5).

Discussion

COVID-19 is a severe and easily transmissible infectious disease outbreaking all around the world. Chest CT examination plays a vital role in the initial and early diagnosis of COVID-19[7]. Positive chest CT can be presented before the initial positive RT-PCR. Given the varied isolation and treatment principles of suspected COVID-19 with epidemic history, it is important to focus on baseline CT findings that radiologists first encountered, differentiating non-COVID-19 from COVID-19 in the patients' first consultation to general hospital.

Reviewed the latest literatures about COVID-19, we have summarized 7 most common images features including ground-glass opacities with or without consolidation, peripheral distribution, posterior or lower lobe predilection, bilateral lungs affected, etc. as positive score point. Our study has showed the similar findings. There was no statistical difference between GGO with or without consolidation in COVID-19(90%) and non-COVID-19(90.7%), indicating that both viral infection including COVID-19 and bacterial infection might share the same pathology of alveolar damage filling with blood, pus, water or cells.[8; 23]. The small COVID-19 virus, 60-140nm in diameter[1], could go straight to the terminal alveoli which reasonable favour peripheral distribution while other much bigger pathogen wouldn't go through alveolar pore easily. In our study, peripheral distribution presented significant difference in 96.7% COVID-19 and in 67.4% non-COVID-19. There were also difference between COVID-19(100%) and non-COVID-19(83.7%) in posterior or lower lobe predilection due to the influence of gravity. There was no clear known reason for bilateral lungs affected in most COVID-19 reports but our study had similar finding in 60% COVID-19 comparing to 67.4% in non-COVID-19. Crazy-paving pattern was not a very common COVID-19 sign except Song et al[8] found 65% in his group. This sign was result from thickening of the interlobular septa which could be seen primarily in any airspace, interstitial, or mixed diseases[24]. Crazy-paving pattern was identified in more cases of COVID-19 (76.7%) than of non-COVID-19(32.6%) in our study. Rounded GGO was calculated in 2 papers with no specific reason [6; 7], and this positive finding presented in only 8 COVID-19(26.7%) cases and one non-COVID-19 case(2.3%) in our study. Rounded GGO as well as subpleural bandlike GGO are very conspicuous and characteristic sign at the first glance of the images of COVID-19. Although there was no explanation of these two signs, it could be easily detected; we took them as our positive scoring points.

Although several specific features of COVID-19 had already been identified by previous studies, those overlapping image features made it difficult to make a differentiat diagnosis of COVID-19 or non-COVID-19. In our design, we add some negative points to make a hierarchical diagnosis. Base on the fact that most of reported COVID-19 cases affected more than 2 lobes of the lungs, only one lobe affection was

taken as negative scoring point. Meanwhile single-lobe infection was reported in some community-acquired pneumonia[25]. It was found in 58.1% cases of Not-COVID-19 rather than 30% of COVID-19 in our study. Some progressive COVID-19 may affect central area from peripheral lung[14]. When the image showed only cenrtral (peribronchovascular) distribution, it indicated distal small airway wall destruction or peribronchovacular infection which was the similar reason of tree-in-bud pattern. Both of these two signs strongly indicated non-COVID-19 infection which were taken as distinguished negative scoring points.

Based on these typical image features of COVID-19 and other common non-COVID-19 pneumonia, a simple and practical scoring system has been established in our study. When being tested in our group of suspected COVID-19, the scoring system achieved good diagnosis performance with AUC=0.854 (95%CI: 0.752-0.926). Using score >4 as cut-off, it showed the high specificity of 95.35% (95%CI: 84.2% to 99.4%) and made only 2 patients false positive (false positive rate: 4.65%), it could be strongly suspected for COVID-19. For suspected cases with score>4, even negative results were shown for several times by RT-PCR, we still suggest that repeat RT-PCR test is necessary. If use score >0 as diagnostic cut-off the sensitivity is 100% with no false negative(0%) diagnosis of COVID-19, which means cases with score ≤ 0 are less likely to be COVID-19. We can exclude COVID-19 of these cases with more confidence and reduce the test times of RT-PCR. Patients with scores of 0-4 should be classified as suspected COVID-19 and be quarantined under medical surveillance followed by at least twice RT-PCR tests according to the suggestion of the newest edition of guideline.

There are several limitations in our study. First, analysis in our study was limited in one general hospital, but all cases had fulfilled the suspected COVID-19 criteria with exposure history, respiratory symptoms and normal or decrease white blood cell and lymphocyte count. Second, with small number of confirmed cases, we cannot set another group to verify the reliability of the scoring system. Future studies including more confirmed patients and multi-center studies would optimize the practical applicability of the scoring system and enable the verification of the reliability.

Conclusion

With exposure history and respiratory symptoms in this epidemic period, the present simple scoring system provide a rapid detection, which may allow better control of COVID-19 spread medical management as well as reduce the larger public health surveillance and response systems.

Abbreviations

COVID-19 2019 novel coronavirus disease

RT-PCR Reverse transcription-polymerase chain-reaction

GGO Ground glass opacification

Declarations

Acknowledgements

Not applicable.

Authors' contributions

LL, ZL and XS contributed to the design and implementation of the concept. JL, JH, ZL and CZ contributed in collecting and reviewing patients' clinical data. LL and XS contributed to the evaluation and the recording of the CT image features. YJ contributed in the statistical analysis of the data. All authors contributed to the writing and reviewing of the paper. All authors read and approved the final manuscript.

Funding

This study was supported by High Level-Hospital Program, Health Commission of Guangdong Province, China (No: HKUSZH201901026). The funders had no role in the study design, data collection and analysis, decision to publish, or preparation of the work.

Availability of data and materials

The datasets analyzed during the current study available from the corresponding author on reasonable request.

Ethics approval and consent to participate

Due to the retrospective design of the study and there was minimal to no risk or benefit to enrolled patients. Institutional Review Board approval and an informed consent was waived by the Ethics Committees of the University of Hongkong-Shenzhen Hospital.

Competing interests

The authors declare that they have no competing interests.

Consent for publication

Not applicable.

References

1 Guidlines for the diagnosis and treatment of coronavirus 2019 (COVID-19) infection by the national health commission (trial version 7), March 4, 2020, National Health Commision of the People's Republic of China website.

2 Xie X, Zhong Z, Zhao W, Zheng C, Wang F, Liu J (2020) Chest CT for Typical 2019-nCoV Pneumonia: Relationship to Negative RT-PCR Testing. Radiology. 10.1148/radiol.2020200343:200343

3 Fang Y, Zhang H, Xie J et al (2020) Sensitivity of Chest CT for COVID-19: Comparison to RT-PCR. Radiology. 10.1148/radiol.2020200432:200432

4 Ai T, Yang Z, Hou H et al (2020) Correlation of Chest CT and RT-PCR Testing in Coronavirus Disease 2019 (COVID-19) in China: A Report of 1014 Cases. Radiology. 10.1148/radiol.2020200642:200642

5 Kanne JP (2020) Chest CT Findings in 2019 Novel Coronavirus (2019-nCoV) Infections from Wuhan, China: Key Points for the Radiologist. Radiology. 10.1148/radiol.2020200241:200241

6 Bernheim A, Mei X, Huang M et al (2020) Chest CT Findings in Coronavirus Disease-19 (COVID-19): Relationship to Duration of Infection. Radiology. 10.1148/radiol.2020200463:200463

7 Chung M, Bernheim A, Mei X et al (2020) CT Imaging Features of 2019 Novel Coronavirus (2019-nCoV). Radiology. 10.1148/radiol.2020200230:200230

8 Song F, Shi N, Shan F et al (2020) Emerging Coronavirus 2019-nCoV Pneumonia. Radiology. 10.1148/radiol.2020200274:200274

9 Pan F, Ye T, Sun P et al (2020) Time Course of Lung Changes On Chest CT During Recovery From 2019 Novel Coronavirus (COVID-19) Pneumonia. Radiology. 10.1148/radiol.2020200370:200370

10 Zu ZY, Jiang MD, Xu PP et al (2020) Coronavirus Disease 2019 (COVID-19): A Perspective from China. Radiology. 10.1148/radiol.2020200490:200490

11 Pan Y, Guan H, Zhou S et al (2020) Initial CT findings and temporal changes in patients with the novel coronavirus pneumonia (2019-nCoV): a study of 63 patients in Wuhan, China. Eur Radiol. 10.1007/s00330-020-06731-x

12 Shi H, Han X, Jiang N et al (2020) Radiological findings from 81 patients with COVID-19 pneumonia in Wuhan, China: a descriptive study. Lancet Infect Dis. 10.1016/s1473-3099(20)30086-4

13 Xu X, Yu C, Qu J et al (2020) Imaging and clinical features of patients with 2019 novel coronavirus SARS-CoV-2. Eur J Nucl Med Mol Imaging. 10.1007/s00259-020-04735-9

14 Xu YH, Dong JH, An WM et al (2020) Clinical and computed tomographic imaging features of Novel Coronavirus Pneumonia caused by SARS-CoV-2. J Infect. 10.1016/j.jinf.2020.02.017

15 Guan WJ, Ni ZY, Hu Y et al (2020) Clinical Characteristics of Coronavirus Disease 2019 in China. N Engl J Med. 10.1056/NEJMoa2002032

16 Koo HJ, Lim S, Choe J, Choi SH, Sung H, Do KH (2018) Radiographic and CT Features of Viral Pneumonia. Radiographics 38:719-739

17 Franquet T (2011) Imaging of pulmonary viral pneumonia. Radiology 260:18-39

18 Franquet T (2018) Imaging of Community-acquired Pneumonia. J Thorac Imaging 33:282-294

19 Hansell DM, Bankier AA, MacMahon H, McLoud TC, Muller NL, Remy J (2008) Fleischner Society: glossary of terms for thoracic imaging. Radiology 246:697-722

20 Lee CH (2007) The crazy-paving sign. Radiology 243:905-906

21 Murata K, Khan A, Herman PG (1989) Pulmonary parenchymal disease: evaluation with high-resolution CT. Radiology 170:629-635

22 Minault Q, Karol A, Veillon F, Venkatasamy A (2018) Tree-in-bud sign. Abdom Radiol (NY) 43:3188-3189

23 Chong S, Kim TS, Cho EY (2010) Herpes simplex virus pneumonia: high-resolution CT findings. Br J Radiol 83:585-589

24 Hochhegger B, Schumacher Neto R, Marchiori E (2016) Crazy-paving pattern. J Bras Pneumol 42:76

25 Ishiguro T, Yoshii Y, Kanauchi T et al (2018) Re-evaluation of the etiology and clinical and radiological features of community-acquired lobar pneumonia in adults. J Infect Chemother 24:463-469

Tables

Table 1 The clinical data including age, sex, exposure history and laboratory parameters of all the collected patients

Parameter	All patients N=73	RT-PCR confirmed COVID-19 N=30	Laboratory or clinical confirmed not COVID-19 N=43	Test statistic	P value
Gender				0.329	0.566
Male	37 (50.7)	14 (46.7)	23 (53.5)		
Female	36 (49.3)	16 (53.3)	20 (46.5)		
Age(y)	41 (33-55.5)	54 (36-64)	37 (32-47)	3.091	0.002*
Exposure History				34.717	<0.001*
Wuhan contact	29 (39.7)	24 (80.0)	5 (11.6)		
Hubei (not Wuhan) contact	10 (13.7)	2 (6.7)	8 (18.6)		
Not Hubei contact or Cluster onset	34 (46.6)	4 (13.3)	30 (69.8)		
Symtoms					
Fever	45 (61.6)	22 (73.3)	23 (53.5)	2.943	0.086
Cough	49 (67.1)	17 (56.7)	32 (74.4)	2.523	0.112
Sputum production	19 (26.0)	5 (16.7)	14 (32.6)	2.318	0.128
Running/stuffy nose	3 (4.1)	0 (0.0)	3 (7.0)	2.183	0.264
Fatigue	8 (11.0)	2 (6.7)	6 (14.0)	1.016	0.314
Muscle ache/myalgia	15 (20.5)	7 (23.3)	8 (18.6)	0.242	0.623
Diarrhea	4 (5.5)	4 (13.3)	0 (0.0)	7.450	0.006*
Chest pain	1 (1.4)	0 (0.0)	1 (2.3)	1.068	0.301
Sore throat	10 (13.7)	2 (6.7)	8 (18.6)	2.307	0.129
Headache	8 (11.0)	3 (10.0)	5 (11.6)	0.048	0.826
Laboratory Investigation					
White-cell count(10^{-9}g/L) (normal range 3.89-9.93)	6.81 (5.40-8.37)	5.43 (4.25-6.12)	7.67 (6.73-9.06)	-4.547	<0.001*
Neutrophil percentage(%) (normal range 44.0-72.0)	64.45 (57.70-73.45)	64.80 (61.35-73.38)	64.45 (55.38-73.70)	0.908	0.364
Neutrophil count(10^{-9}g/L) (normal range 2.01-7.42)	4.21 (3.30-5.96)	3.46 (3.00-4.32)	4.92 (3.75-7.09)	-3.295	0.001*
Lymphocyte percentage(%) (normal range 20.0-45.0)	26.15 (18.05-31.08)	25.25 (17.58-31.03)	26.75 (18.55-32.55)	-0.423	0.673
Lymphocyte count(10^{-9}g/L) (normal range 1.06-3.61)	1.70 (1.28-2.36)	1.32 (1.08-1.69)	1.93 (1.54-2.64)	-3.667	<0.001*

Table 2 significant COVID-19 CT image features by reviewing reported papers published or e-published of chest CT findings from COVID-19 outbreak in China recently

	GGO+ consolidation	peripheral/ subpleural distribution	posterior lobe/ lower predilection	bilateral involvement	Crazy-paving pattern	Rounded GGO	more than 2 lobes affected	Central distribution
Kann et al[5]	86%	33%	-	76%	19%	-	-	-
Bernheim et al[6]	91%	63%	-	73%	6%	65%	62%	-
Chung et al[7]	86%	33%	-	76%	19%	33%	71%	-
Song et al[8]	<59%	86%	80%	86%	75%	-	91%	10%
Pan F et al[9]	75%	54%	-	42%	25%	-	58%	-
Zu et al[10]	(+++)	(+++)	(+++)	(+++)	(++)	-	-	-
Pan YY et al[11]	85.70%	-	-	-	-	-	69.7%	-
Shi et al[12]	65%	54%	-	79%	-	-	-	-
Xu X et al[13]	72%	51%	-	59%	12%	-	73%	-
Xu YH et al[14]	75%	<96.4%	-	>53.6%	75%	-	-	-
Guan et al[15]	56.40%	-	-	51.80%	-	-	-	-

GGO=Ground glass opacification

Table 3 Selected chest CT image features and Scores analysis

	CT parameter	All patients N=73	RT-PCR confirmed COVID-19 N=30	Laboratory or clinical confirmed not COVID-19 N=43	c^2 statistic	P-value
Positive +1	Posterior part/ lower lobe predilection	66 (90.4)	30 (100.0)	36 (83.7)	7.923	0.005*
	Bilateral involvement	33 (45.2)	18 (60.0)	15 (34.9)	4.500	0.034*
	Rounded GGO	9(12.3)	8 (26.7)	1 (2.3)	10.226	0.001*
	Subpleural bandlike GGO	16 (21.9)	14 (46.7)	2 (4.7)	18.228	<0.001*
	Crazy-paving pattern	37 (50.7)	23 (76.7)	14 (32.6)	13.755	<0.001*
	Peripheral distribution	58 (79.5)	29 (96.7)	29 (67.4)	9.245	0.002*
	GGO +/- consolidation	66 (90.4)	27 (90.0)	39 (90.7)	0.010	0.921
Negative -1	Only one lobe involvement	34 (46.6)	9 (30.0)	25 (58.1)	5.623	0.018*
	Only Central(peribronchovascular) distribution	15 (20.5)	1 (3.3)	14 (32.6)	9.245	0.002*
	Tree-in-Bud sign (centrilobular nodules)	6 (8.2)	0 (0.0)	6 (14.0)	6.723	0.010*
	Bronchial wall thickening	12 (16.4)	1 (3.3)	11 (25.6)	7.572	0.006*
Total Score median(IQR)		2 (1-4)	4 (2-5)	2 (0-2)	4.637	<0.001

GGO=Ground glass opacification

Table 4. Discriminative performance of prediction for COVID-19

Variable	AUC	SE	P-value	95%CI
Combined CT Score	0.854	0.045	<0.001*	0.752 to 0.926

Table 5. Prediction performance of COVID-19 with different cut-off values

Cut-off	**TP**	**FP**	**TN**	**FN**	**Sensitivity**	**Specificity**	**PPV**	**NPV**
>4	17	2	41	13	56.67 (37.4 to 74.5)	95.35 (84.2 to 99.4)	89.5 (67.9 to 97.2)	75.9 (67.6-82.7)
>2	26	14	29	4	86.67 (69.3 to 96.2)	67.44 (51.5 to 80.9)	65.0 (54.2-74.5)	87.9 (74.0-94.9)
>0	30	33	10	0	100.0 (88.4 to 100.0)	23.26 (11.8 to 38.6)	47.6 (43.5-51.7)	100.0(-)

Table 6. Discriminative performance of prediction for COVID-19

Variable	AUC	SE	P-value	95%CI
Combined CT Score	0.854	0.045	<0.001*	0.752 to 0.926

Figures

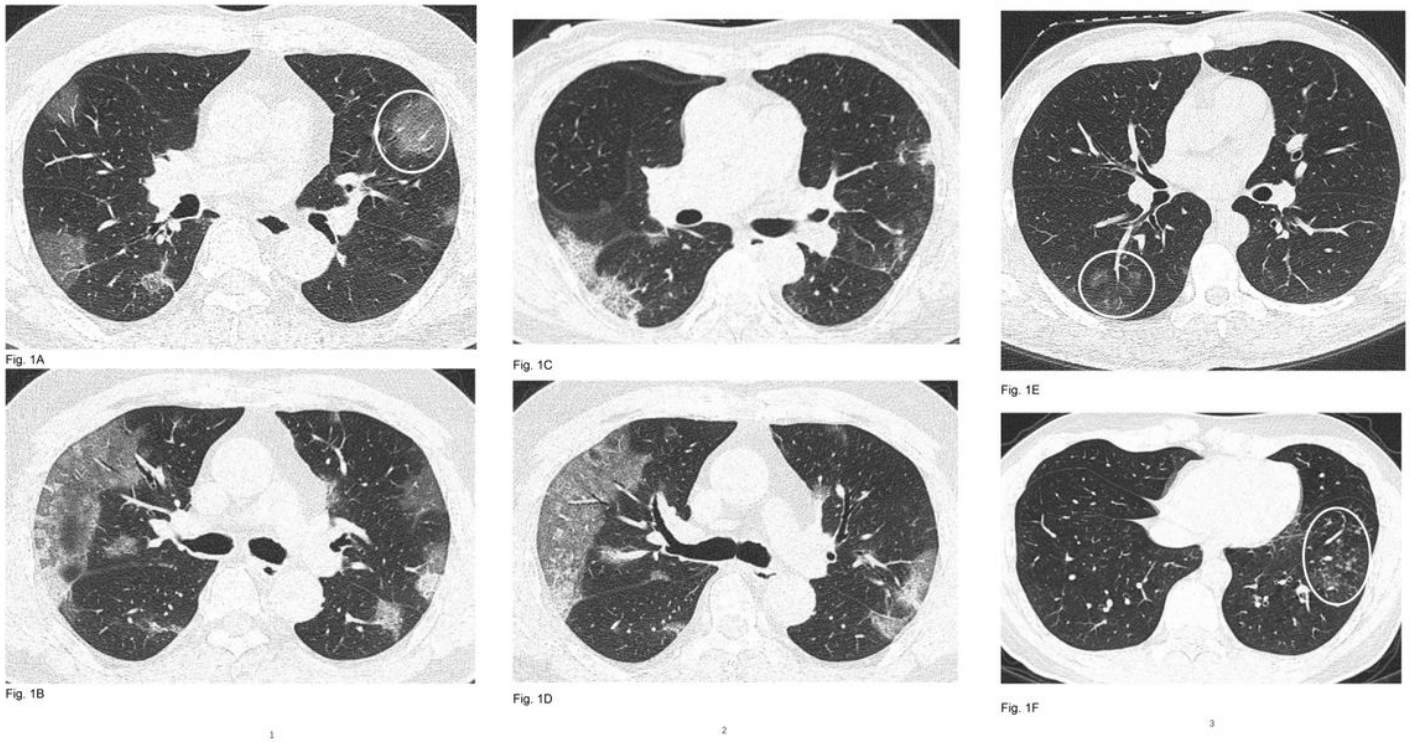

Figure 1

Fig. 1A Pure GGO and Rounded GGO (circle) Fig. 1B Mix GGO and consolidation Fig. 1C Crazy-paving pattern Fig. 1D Subpleural bandlike areas of GGO Fig. 1E Central (peribronchovascular) distribution (circle) Fig. 1F Tree-in-bud sign(circle)

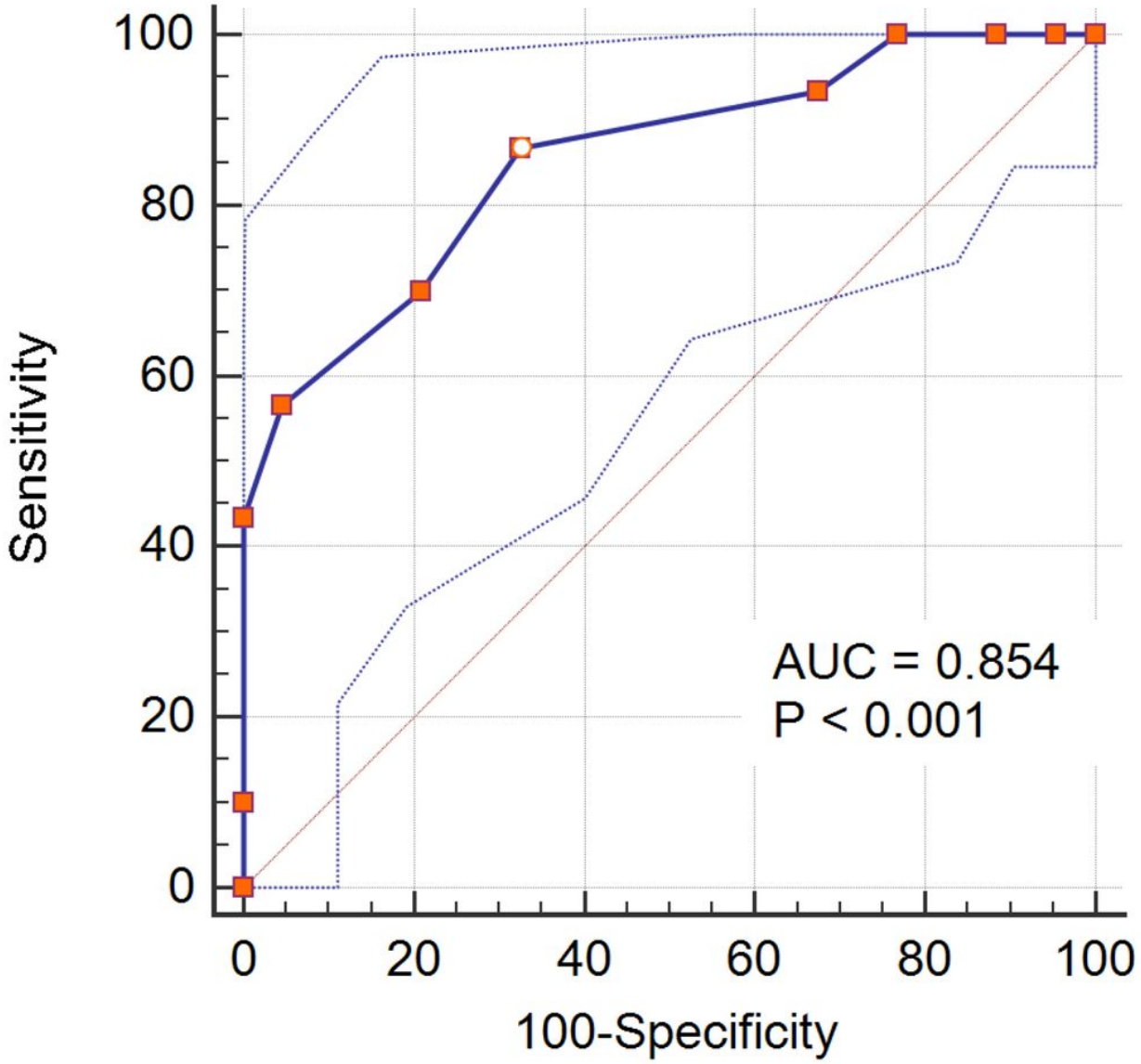

Figure 2

ROC curve for COVID-19 prediction