High resolution computed tomography for the diagnosis of 2019 novel coronavirus (2019-nCoV) pneumonia: a study from multiple medical centers in western China

Hong-Wei Li
Department of Radiology, the Third Hospital of Mianyang·Sichuan Mental Health Center
Li-Hua Zhuo
Department of Radiology, the Third Hospital of Mianyang·Sichuan Mental Health Center
Gao-Wu Yan
Department of Radiology, Suining Central Hospital
Ji-Sheng Wang
Department of Radiology, the Third Hospital of Mianyang·Sichuan Mental Health Center
Guo-Ping Huang
Department of Radiology, the Third Hospital of Mianyang·Sichuan Mental Health Center
Jia-Bing Li
Department of Radiology, the Third Hospital of Mianyang·Sichuan Mental Health Center
Fang-Zhang
Department of Radiology, the Third Hospital of Mianyang·Sichuan Mental Health Center
Yong-Jun Long
Department of Radiology, the Third Hospital of Mianyang·Sichuan Mental Health Center
Li-Hua Deng
Department of Radiology, the First People's Hospital of Neijiang
Li-Ping Su
Department of Radiology, Affliated Yongchuan Hospital of Chongqing Medical University
Hong-Chao Yao
Department of Radiology, the Third Hospital of Mianyang·Sichuan Mental Health Center
Sushant-Kumar Das
Department of Radiology, Affliated Hospital of North Sichuan Medical College
Yong Li
Department of Radiology, Suining Central Hospital
Han-Feng Yang
Department of Radiology, Affliated Hospital of North Sichuan Medical College
Yong Du (duyong1236@163.com)
Department of Radiology, Affliated Hospital of North Sichuan Medical College

Research Article

Keywords: High resolution computed tomography, HRCT, 2019 novel coronavirus, 2019-nCoV, Pneumonia, COVID-10

Posted Date: March 26th, 2020

DOI: https://doi.org/10.21203/rs.3.rs-19499/v1

Version of Record: A version of this preprint was published at Annals of Translational Medicine on September 1st, 2020. See the published version at https://doi.org/10.21037/atm-20-5731.

Abstract

Objective: To evaluate the role of high-resolution computed tomography (HRCT) in the diagnosis of 2019 novel coronavirus (2019-nCoV) pneumonia and to provide experience in the early detection and diagnosis of 2019-nCoV pneumonia.

Methods: 72 patients confirmed to be infected with 2019-nCoV from multiple medical centers in western China were retrospectively analyzed, including epidemiologic characteristics, clinical manifestations, laboratory findings and HRCT chest features.

Results: All patients had lung parenchymal abnormalities on HRCT scans, which were mostly multifocal in both lungs and asymmetric in all patients, and were mostly in the peripheral or subpleural lung regions in 52 patients (72.22%), in the central lung regions in sixteen (22.22%), and in both lungs, with "white lung "manifestations in four (5.56%). Subpleural multifocal consolidation was predominant abnormality in 38 patients (52.78%). Ground-glass opacity was seen in 34 patients (47.22%). Interlobular septal thickening was found in 18patients, of which eight had only generally mild thickening with no zonal predominance. Reticulation was seen in 8 patients (11.11%), in all of whom it was mild and randomly distributed. In addition, both lungs of 28 patients had two or three CT imaging features. Out of these 72 patients, 36 were diagnosed as early stage, 32 patients as progressive stage and 4 patient as severe stage pneumonia. Moreover, the diagnostic accuracy of HRCT features combined with epidemiological history was not significantly different from the detection of viral nucleic acid (all $P > 0.05$).

Conclusion: The HRCT features of 2019-nCoV pneumonia are characteristic to a certain degree, which when combined with epidemiological history yield high clinical value in the early detection and diagnosis of 2019-nCoV pneumonia.

Authors Hong-Wei Li, Li-Hua Zhuo, Gao-Wu Yan contributed equally to this work.

Introduction

An outbreak of novel coronavirus (2019-nCoV) from Wuhan, Hubei Province, has spread to the entire China, since late December 2019 (1). Due to similar clinical manifestations and CT features as viral pneumonia, it is easy to misdiagnose the disease in its early phase. The causative agent of the pneumonia is confirmed to be a novel coronavirus (2019-nCoV) of the same lineage from the coronavirus causing severe acute respiratory syndrome (SARS), but with significantly different genetic characteristics from that of SARSr-CoV and MERSr-CoV (2,3). A series of studies have demonstrated that coronavirus can be transmitted not only from animal to human, but also from human to human (4–8). Respiratory droplet transmission and contact transmission, which is the main route of transmission, cause rapid transmission with higher incidence rate. For such communicable infection which is spreading rapidly, accurate and early diagnosis is very crucial for appropriate treatment so as to save lives and control the epidemic. At present, the diagnosis of the disease mainly depends on the detection of viral nucleic acid (9). However, due to sampling errors, the sensitivity for diagnosis of the disease is unstable and the

nucleic acid test is time-consuming. Furthermore, the reports about 2019-nCoV pneumonia mainly refer to epidemiologic characteristics, clinical manifestations, laboratory findings and treatment outcomes of the patients.

High-resolution computed tomography (HRCT) plays a central and important role in the evaluation and diagnosis of focal lung disease, which could detect the lesion and indicate if it was virus-derived infection (10). However, to the best of our knowledge, few existing studies have evaluated the diagnostic values HRCT combined with epidemiological history. Therefore, the purpose of this study was to evaluate HRCT diagnostic values for 2019-nCoV pneumonia combined with epidemiological history and provide imaging evidence for clinical diagnosis and appropriate treatment.

Materials And Methods

Patient population

This study was approved by the institutional review board of the Third Hospital of Mianyang, Suining Central Hospital, Affliated Hospital of North Sichuan Medical College, First People's Hospital of Neijiang and Affliated Yongchuan Hospital of Chongqing Medical University. Written informed consent was obtained from each patients. The study included 72 consecutive patients (30 women and 42 men; mean age 51.74 years; age range: 23–78 years) confirmed to have 2019-nCoV infection, who had undergone HRCT of the chest at our five hospitals. The patients were categorized as per the severity of the disease into early stage (n = 36), progressive stage (n = 32) and severe stage (n = 4) using the guidelines for Imaging diagnosis of novel Coronavirus (1st edtion 2020) (11). Patient demographic characteristics are shown in Table 1.

HRCT imaging protocol and Image analysis

High-resolution CT scans were obtained on a variety of scanners, including Siemens 16/128 slices CT, GE 128 slices CT. Image acquisition were acquired using following parameters: 2~4mm section thickness; 20~40mAs; 120 ~150kV. Multi-plane reconstruction (MPR) technology was used. The HRCT features were analyzed by two radiologists with 10 or more years of experience in reading pulmonary CT. Both of them were blinded to the results of detection of viral nucleic acid.

Epidemiological criteria and Detection of viral nucleic acid

The epidemiological criteria to define a suspected case were as follow: history of travel to Wuhan city or direct contact with patients from Wuhan who had symptoms of lower respiratory illness (e.g. cough, breathing difficulties), within 14 days before illness onset; history of fever or symptoms of lower respiratory illness and close contact with patients confirmed with 2019-nCoV infection (12). Respiratory specimens were tested for 2019-nCoV pneumonia using Real-time fluorescence polymerase chain

reaction (RT-PCR), including nasal and pharyngeal swabs, sputum, bronchial aspirates and bronchoalveolar lavage fluid.

Statistical analyses

Statistical analysis was performed with SPSS (Version 23.0, IBM Corp, USA). Categorical variables were expressed as number (%). The diagnosis accuracy between HRCT features combined with epidemiological history and the first detection of viral nucleic acid was compared using χ^2 test or Fisher's exact test. $P<0.05$ was considered statistically significant.

Results

Baseline characteristics

By 7th Feb 2020, 72 patients who had undergone HRCT of the chest at our five institutions were confirmed to have 2019-nCoV infection. 10 (13.89%) of the 2019-nCoV-infected patients were aged 19–39 years, 40 (55.56%) were aged 40–59 years and 22 (30.56%) were aged over 60 years, no children or adolescents were infected. The median age of the patients was 51.74 years, age range from 23 to78 years. The clinical and demographic characteristics of the patients are summarized in Table 1.

Majority of the infected patients were men (42 [58.33%] of 72); less than quarter had underlying diseases (16 [22.22%]), including hypertension (6 [8.33%]), diabetes (2 [2.78%]), and cardiovascular disease (8 [11.11%]). Common symptoms at onset of 2019-nCoV pneumonia were fever (68 [94.44%] of 72 patients), cough (56 [77.78%]) and fatigue or myalgia (18 [25.00%] of72); less common symptoms were sputum production (16 [22.22%]), headache (6 [8.33%] of 72) and diarrhea (2 [2.78%] of 72). Laboratory studies of the patients on admission showed leucopenia (white blood cell count less than 4×10^9 /L; 20 [27.78%] of 72 patients)，lymphopenia (lymphocyte count $<1.0 \times 10^9$ /L; 44 [61.11%] patients) and elevated C-reactive protein (C-reactive protein count >10 mg/L; 36 [50.00%] patients). Out of these 72 patients, 36 were diagnosed as early stage, 32 patients as progressive stage and 4 patient as severe stage. Figures 1, 2 and 3 show the representative HRCT appearance on images of three cases confirmed as early stage, progressive stage, severe stage, respectively.

CT imaging findings

All patients had lung parenchymal abnormalities on HRCT scans (Fig.1–6), which were mostly multifocal in both lungs and asymmetric in all patients, and were mostly in the peripheral or subpleural lung regions in 52 patients (72.22%) (Fig. 1–2), in the central lung regions in sixteen (22.22%), and in both lungs, with "white lung "manifestations in four (5.56%) (Fig. 3). The CT imagine features mainly include consolidation, ground-glass opacity (GGO), interlobular septal thickening, centrilobular nodules and reticulation. Subpleural multifocal consolidation was predominant abnormality in 38 patients (52.78%)

(Fig. 4). Ground-glass opacity was seen in 34 patients (47.22%) (Fig.5). Interlobular septal thickening was found in 18 (25.00%) patients, of which eight had only generally mild thickening with no zonal predominance. Reticulation was seen in 8 patients (11.11%), in all of whom it was mild and randomly distributed (Fig. 6). In addition, both lungs of 28 patients had two or three CT imaging features.

The overall extent of abnormalities was less than 25% of the lung parenchyma in 38 patients, 25–50% in 30, 50–75% in 4, and no one had more than 75% abnormalities. CT manifestations were divided into early stage, progressive stage, severe stage and absorption stage according to the Guidelines for Imaging Diagnosis of novel Coronavirus (1st edtion 2020). Table 2 summarizes the high-resolution CT findings.

Comparison of the diagnosis accuracy between HRCT features and RT-PCR

All of the cases were proven 2019-nCoV pneumonia patients by Real-time fluorescence polymerase chain reaction. The detection rate of the first nucleic acid test was 88.89%, while combination of two tests was 91.67%, combination of three tests was 97.22%, and combination of four tests was 100%. The diagnostic accuracy of HRCT features combined with epidemiological history was not significantly different from the diagnosis by the detection of viral nucleic acid (all P >0.05). Comparison of diagnostic accuracy of HRCT features combined with epidemiological history with that of the first detection of viral nucleic acid is shown in Table 3.

Discussion

Since the outbreak of the new coronavirus pneumonia (2019-nCov) epidemic, the number of deaths caused by new coronavirus pneumonia has been increasing as the number of daily diagnoses has continued to increase (13). Therefore, how to diagnose the disease accurately and quickly is crucial for appropriate treatment so as to save lives and control the epidemic.

The results of the present study demonstrated that the fact the diagnosis accuracy HRCT features combined with epidemiological history is similar to the detection of viral nucleic acid. The detection of viral nucleic acid is considered gold standard for the diagnosis of 2019-nCoV pneumonia (9). However, there are following disadvantages: first, the nucleic acid test is time-consuming, and if it is negative, repeated sampling may be necessary, which would prolong the diagnostic time and increase chance of the further spread of the virus; second, although the specificity of the nucleic acid test is high, there is a certain false negative rate. The above shortcomings are difficult to cope with the large number of close contacts and family watchers.

For chest HRCT examination, although it lacks the specificity for viral pneumonia and may appear “different diseases with same imaging features”, typical HRCT features combined with epidemiological history held high good sensitivity similar to the detection of viral nucleic acid. Authors acknowledge that the chest CT cannot replace nucleic acids to confirm the diagnosis of new coronavirus pneumonia.

However, in the face of conditions where nucleic acid testing conditions are not allowed in the epidemic area, and a large number of suspected cases cannot be diagnosed, chest HRCT examination combined with epidemiological history can be used as a powerful supplementary method to carry out leak detection and make up for defects, so as to find more suspected cases and close contacts in early phase, so that they could be isolated, observed and treated as soon as possible.

According to the Guidelines for Imaging Diagnosis of novel Coronavirus (1st edition 2020) (11)our study cases were classified as early stage (n = 36), progressive stage (n = 32) and severe stage (n = 4). In early stage imaging findings, lesions were mostly distributed in the peripheral or sub-pleural lung and generally do not involve the whole lung segment. At the same time, the lesions were always multifocal in both lungs, rare single focus, which commonly manifest as ground glass opacity, with or without interlobular septal thickening, and rarely as small and limited consolidation range. When the disease was in the progressive stage, the distribution of lesions was increased and involved multiple lobes, mostly located in sub-pleural region of the lungs. Some of the lesions were enlarged with increased density, irregular, fan-shaped or wedge-shaped, with unclear boundaries, showing bilateral asymmetry. If treatment was delayed or treated inappropriately, diffuse lesions can be seen in both lungs, with a few”white lung “manifestations. The range of lesions increased by 50% within 48 hours, and the lesions were mainly consolidation, with ground glass opacity, air bronchogram, and multiple cable- like shadows.

Moreover, our study showed 10 [13.89%]) of the 2019-nCoV-infected patients were aged 19–39 years, 40 (55.56%) were aged 40–59 years and 22 (30.56%) were aged over 60 years. However, no children or adolescents were infected. Author acknowledge that this results might be misleading and may be due to the fact that the children have few opportunities to go out and have less chance of contacting the source of infection; therefore, the probability of infection is low.

The study have several limitations. First, the sample size in our study was relatively small and there were no cases of children. Second, we did not review follow-up CT imaging. Third, we did not count false positive cases of CT imaging, as these cases were not included in this study.

In conclusion, the HRCT features of 2019-nCoV pneumonia are characteristic to assess scope and type of lesions, which when combined with epidemiological history yield high clinical value for the diagnosis of 2019-nCoV pneumonia.

Declarations

Competing Interests statement

All authors declare that they have no competing interests.

Author Contributions

DU Y, Li HW and Yan GW designed the study. Zhuo LH, Wang JS, Deng LH, Su LP, Li JB□Das SK and Yao HC performed examinations and collected the date. Long YJ, Zhang F, Li Y ,Yang HF and Huang GP contributed to the analysis and supervised the report. Li HW, Sushant KD and Zhuo LH wrote this paper together. Li HW., Yan GW, and DU Y revised the paper.

Ethical approval and informed consent

This study was approved by the Institutional Review Board of the Third Hospital of Mianyang, Suining Central Hospital, Affliated Hospital of North Sichuan Medical College, First People's Hospital of Neijiang and Affliated Yongchuan Hospital of Chongqing Medical University. Written informed consent was obtained from each patients. All patients had given written consent for this study.

References

1. Zhu et al. A Novel Coronavirus from Patients with Pneumonia in China, 2019. N Engl J Med. doi: 10.1056/NEJMoa2001017 (2020). [Epub ahead of print]
2. Paraskevis D. et al. Full-genome evolutionary analysis of the novel corona virus (2019-nCoV) rejects the hypothesis of emergence as a result of a recent recombination Infect Genet Evol. 79:104212. doi: 10.1016/j.meegid.2020.104212 (2020). [Epub ahead of print]
3. Yin et al. MERS, SARS and other coronaviruses as causes of pneumonia. Respirology. 23: 130-137. doi:10.1111/resp.13196 (2018).
4. Li et al. Early Transmission Dynamics in Wuhan, China, of Novel Coronavirus-Infected Pneumonia.N Engl J Med. doi: 10.1056/NEJMoa2001316 (2020). [Epub ahead of print]
5. Carlos et al. Novel Wuhan (2019-nCoV) Coronavirus. Am J Respir Crit Care Med. doi: 10.1164/rccm.2014P7(2020).[Epub ahead of print]
6. Wu et al. Real-time tentative assessment of the epidemiological characteristics of novel coronavirus infections in Wuhan, China, as at 22 January 2020. Euro Surveill. doi: 10.2807/1560-7917.ES.2020.25.3.2000044(2020).
7. Gralinski et al. Return of the Coronavirus: 2019-nCoV. Viruses. 24;12(2). pii: E135. doi: 10.3390/v12020135□2020□.
8. Nishiura et al. The Extent of Transmission of Novel Coronavirus in Wuhan, China, 2020. J Clin Med. 24;9(2). pii: E330. doi: 10.3390/jcm9020330(2020).
9. Corman et al. Detection of 2019 novel coronavirus (2019-nCoV) by real-time RT-PCR. Euro Surveill. 25(3). doi: 10.2807/1560-7917.ES.2020.25.3.2000045(2020).
10. Chung et al. CT Imaging Features of 2019 Novel Coronavirus (2019-nCoV). CT Imaging Features of 2019 Novel Coronavirus (2019-nCoV)(2020)
11. Li HG, Xu HB,et Guidelines for Imaging Diagnosis of novel Coronavirus (1st edtion 2020). https://www.cmtopdr.com/post/detail/c1c25295-9a92-48fe-a58d-c97e334173f7(2020)

12. Guidelines for Diagnosis and Treatment of novel Coronavirus (5th edtion). http://www.chinacdc.cn/jkzt/crb/zl/szkb_11803/jszl_11815/202002/t20200205_212256.html(2020)
13. Wei-jie Guan, Zheng-yi Ni, Yu Hu, Wen-hua Liang, Chun-quan Ou, Jian-xing He, et al.Clinical characteristics of 2019 novel coronavirus infection in China. medRxiv 2020.02.06.20020974; doi: https://doi.org/10.1101/2020.02.06.20020974(2020)

Tables

Table 1. Baseline characteristics of 2019-nCoV pneumonia patients

Baseline characteristics	Variables
Patients (n)	72
Age (years)	51.74 ± 11.64
Age stage (0~18, 19~39, 40~59, 60~100)	0/10/40/22
Gender (M /F)	42/30
Underlying diseases (n, %)	
Hypertension	8.33% (6/72)
Diabetes	2.78% (2/72)
Cardiovascular disease	11.11% (8/72)
Common symptoms (n, %)	
Fever	94.44% (68/72)
Cough	77.78% (56/72)
Fatigue or myalgia	25.00%(18/72)
Less common symptoms (n, %)	
Sputum production	22.22% (16/72)
Headache	8.33% (6/72)
Diarrhoea	2.78% (2/72)

Table 2. Features on initial chest HRCT on 72 patients

HRCT features	n	%
Anatomic distribution		
Peripheral regions	52	72.22
Central regions	16	22.22
Peripheral and central regions	4	5.56
Zonal predominance		
Upper/lower/full	16/34/22	/
Single /both	8/64	/
Predominant density		
Consolidation	38	52.78
Ground-glass opacity	34	47.22
Associated finding		
Reticulation	8	11.11
Interlobular septal thickening	18	25
Centrilobular nodules	10	13.89
Other features		
Mediastinal lymphadenopathy	0	0
Pleural thickening	10	13.89
Pleural effusion	6	8.33

HRCT = High resolution computed tomography

Table 3. Comparison of the diagnosis accuracy between HRCT features and the detection of viral nucleic acid

The first RT-PCR test	HRCT combined with epidemiological history	χ^2	*P* value
88.89% (64/72)	80.56% (58/72)	0.18	0.67
Combination of two RT-PCR test	**HRCT combined with epidemiological history**	**χ^2**	***P* value**
91.67% (66/72)	80.56% (58/72)	0.81	0.37
Combination of three RT-PCR test	**HRCT combined with epidemiological history**	**χ^2**	***P* value**
97.22% (70/72)	80.56% (58/72)	1.23	0.27
Combination of four RT-PCR test	**HRCT combined with epidemiological history**	**χ^2**	***P* value**
100% (72/72)	80.56% (58/72)	/	/

Figures

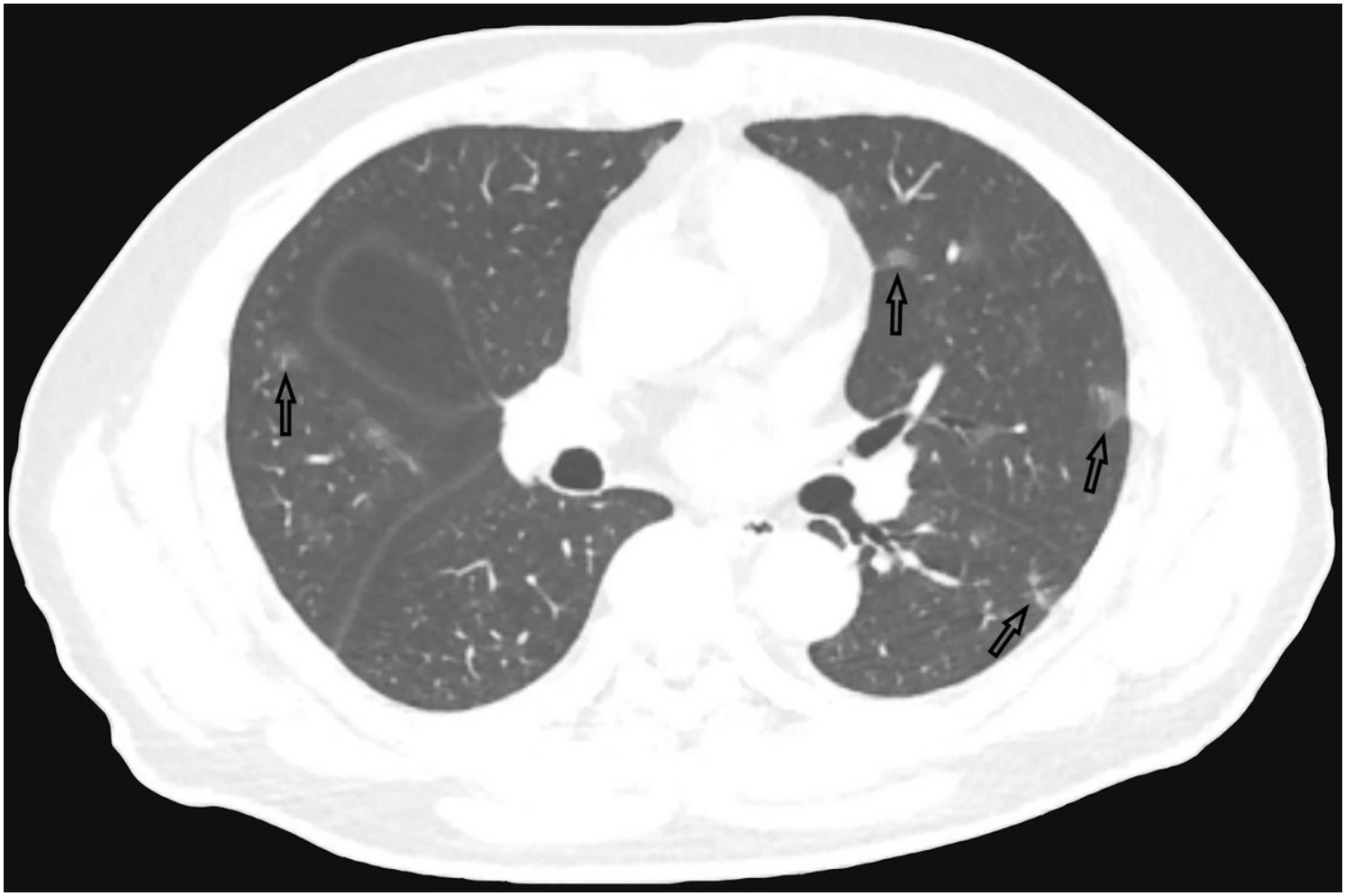

Figure 1

Early stage: HRCT scan of a 49 year-old man shows irregular, fan-shaped and patchy or round like lesions lesions are mostly distributed in the peripheral or subpleural lung, which manifest as ground glass opacity (GGO, arrows).

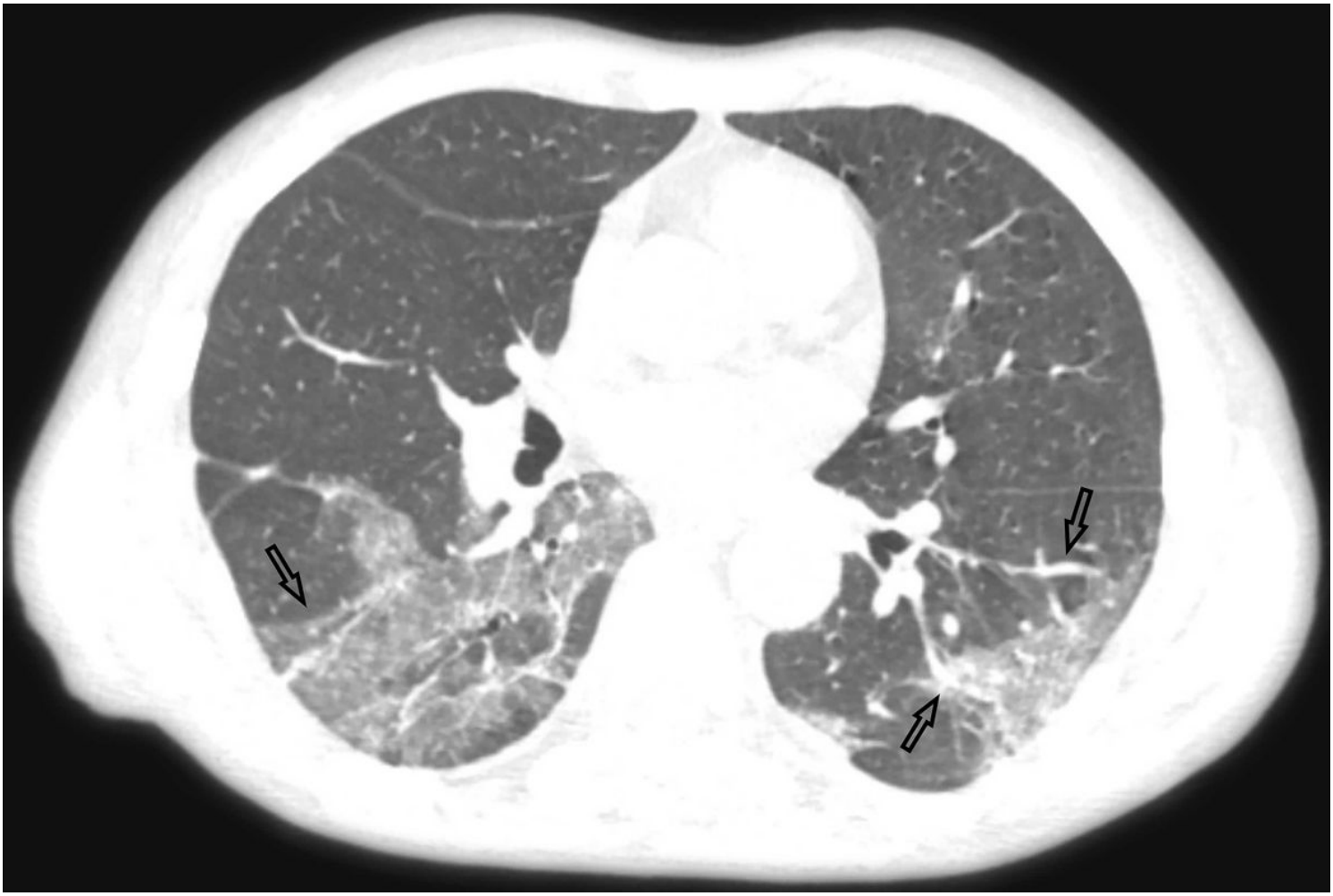

Figure 2

Progressive stage: HRCT scan of a 52 year-old man shows the distribution of lesions involve multiple lobes, most located in subpleural lung, which is fan-shaped or wedge shape. Bronchovascular bundle thickening or subpleural multifocal consolidation were seen in the lesions (arrows).

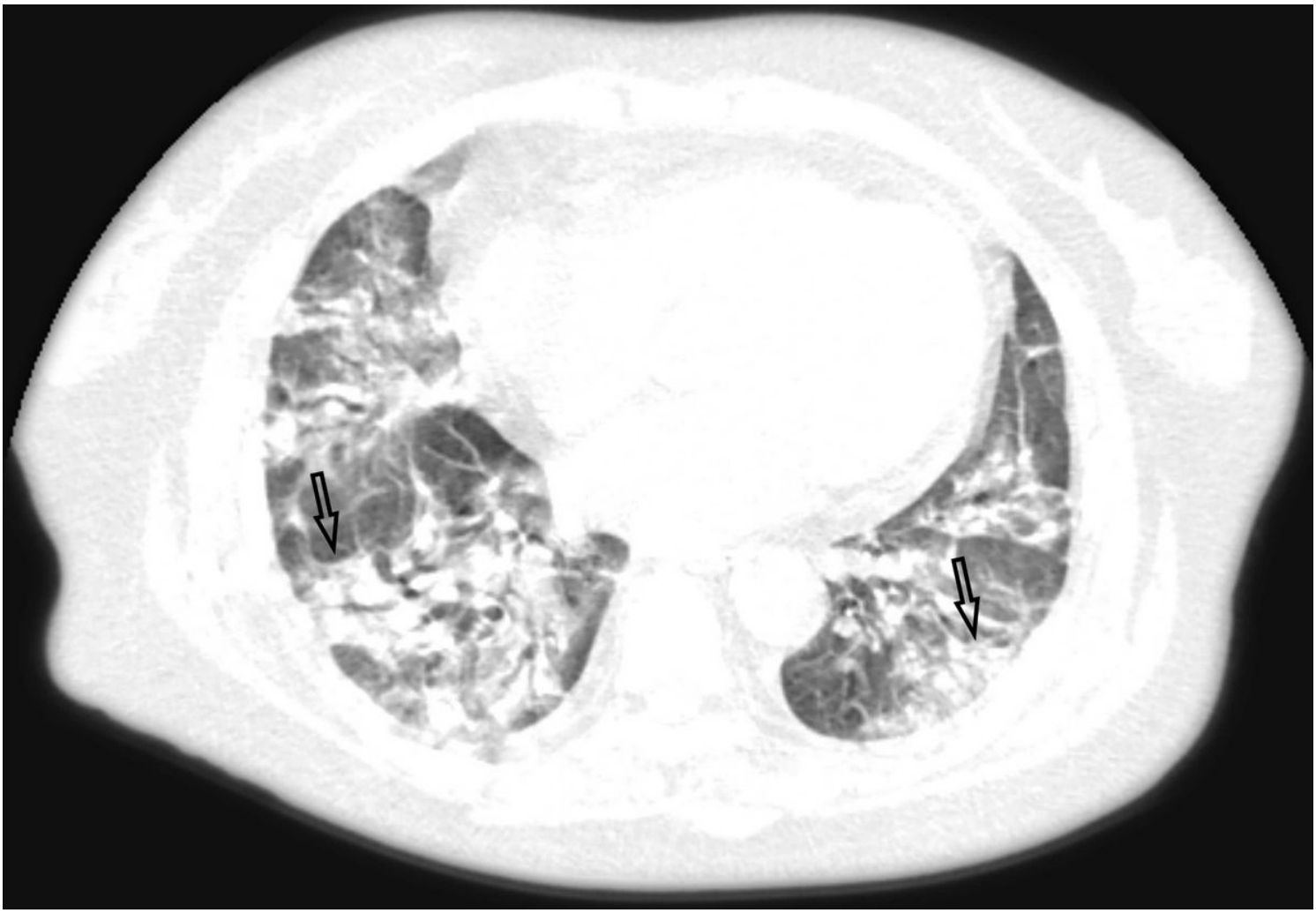

Figure 3

Severe stage: high-resolution CT scan of 59 year-old woman shows diffuse lesions can be seen in both lungs, with a few"white lung"manifestations.

Figure 4

HRCT scan of a 65 year-old woman shows area of multifocal consolidation and ground-glass opacity involve multiple lobes, mostly located in subpleural lung (arrows).

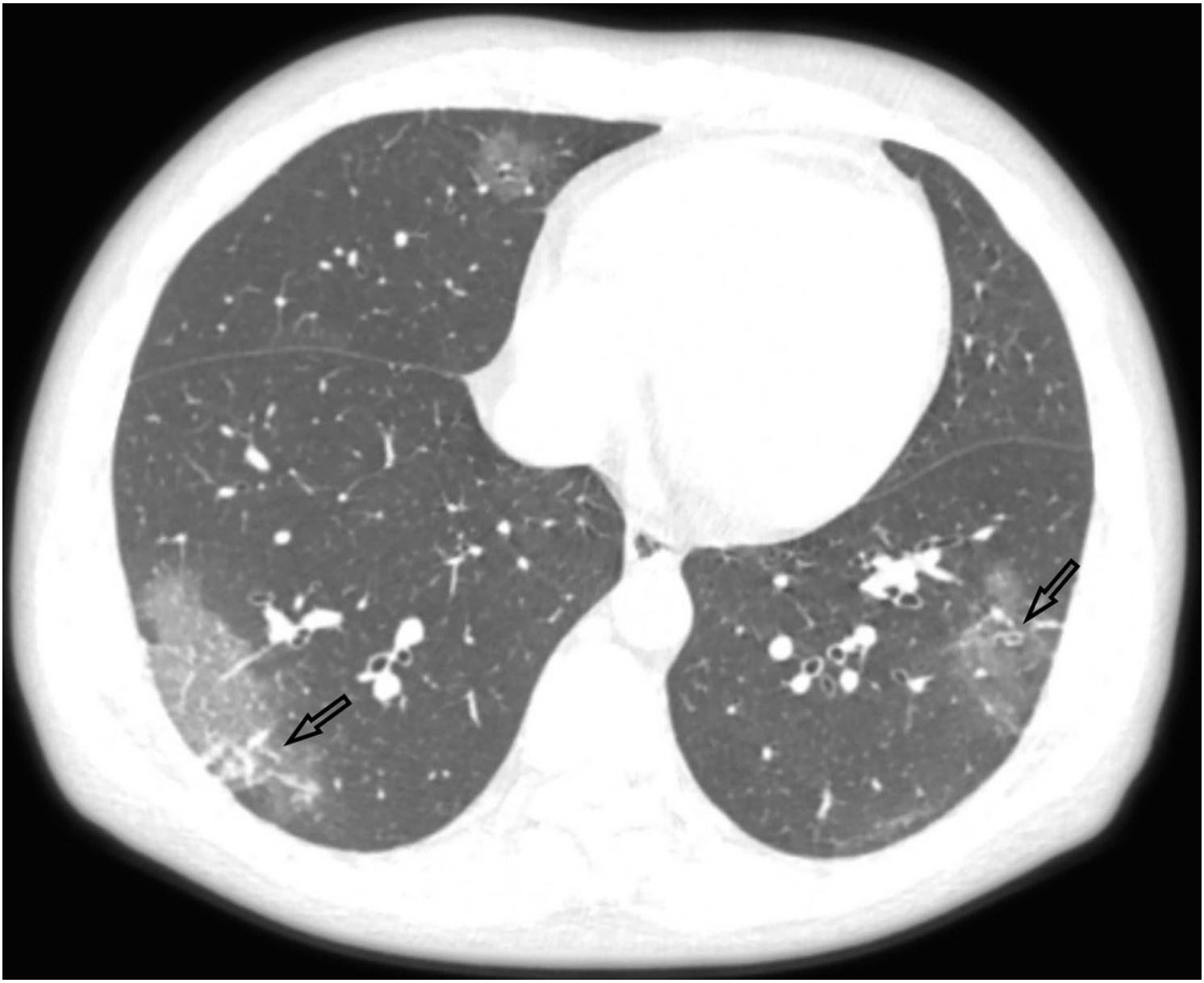

Figure 5

HRCT scan of a 38 year-old man shows ground glass opacity (GGO) mostly in the peripheral or subpleural lung. Vessel and bronchial wall thickening can be seen in posterior aspects of both lungs (arrows).

Figure 6

HRCT of a 42 year-old man scan shows area of ground-glass opacity (GGO) and reticulation in periphery of left lower lobe. Also seen are a few small nodules (arrows).