Clinical effect on the alveolar bone of maxillary molar after rapid maxillary expansion: a systematic review and meta-analysis

Bowen Zhang
Department of Orthodontics, School and Hospital of Stomatology, Cheeloo College of Medicine, Shandong University & Shandong Key Laboratory of Oral Tissue Regeneration & Shandong Engineering Laboratory

Mengqiao Wang
Department of Orthodontics, School and Hospital of Stomatology, Cheeloo College of Medicine, Shandong University & Shandong Key Laboratory of Oral Tissue Regeneration & Shandong Engineering Laboratory

Fenglu Zhao
Department of Orthodontics, School and Hospital of Stomatology, Cheeloo College of Medicine, Shandong University & Shandong Key Laboratory of Oral Tissue Regeneration & Shandong Engineering Laboratory

Zijie Zhang
Department of Orthodontics, School and Hospital of Stomatology, Cheeloo College of Medicine, Shandong University & Shandong Key Laboratory of Oral Tissue Regeneration & Shandong Engineering Laboratory

Fulan Wei (weifl@sdu.edu.cn)
Department of Orthodontics, School and Hospital of Stomatology, Cheeloo College of Medicine, Shandong University & Shandong Key Laboratory of Oral Tissue Regeneration & Shandong Engineering Laboratory

---

Research Article

Keywords: Alveolar bone loss, Maxillary expansion, Meta-analysis, Orthodontics, Systematic review

Posted Date: February 16th, 2021

DOI: https://doi.org/10.21203/rs.3.rs-197503/v1

Abstract

Background

This study assessed the effects of rapid maxillary expansion (RME) on alveolar bone cortical thickness and vertical bone level of maxillary first molar.

Material and methods

PubMed, Web of Science, Cochrane Central Register of Controlled Trials (CENTRAL), Scopus and a manual search in reference lists of the included studies were searched up to November 2020. The data extraction and risk of bias assessment were performed independently by two authors. Review Manager 5 was used for quantitative analysis.

Results

Eight studies were selected for the systematic review, and six studies were statistically selected in meta-analysis. The thickness of the distal buccal alveolar bone was significantly reduced of both left (MD 0.53;95% CI:0.15–0.90) and right (MD 0.61;95% CI:0.28–0.94) sides of the maxillary first molar after RME. The same was true for the left (MD 0.63;95% CI:0.28–0.98) and right (MD 0.63;95% CI:0.36–0.91) sides of the mesial buccal side. And the vertical distance between the cusp tip and the buccal alveolar crest increased significantly after RME (SMD − 0.92;95% CI: -1.20–0.64). However, the study of palatal cortical thickness of maxillary first molar needs more clinical trials because of its high heterogeneity (left: I^2 = 92%; right: I^2 = 86%).

Conclusions

According to current studies, RME can reduce the buccal cortical thickness of maxillary first molars and increase vertical bone loss. More research is needed to determine the stability of the results. However, it is advisable to evaluate the alveolar bone before treatment.

Background

Maxillary transverse deficiency is a kind of common malocclusion in clinical orthodontic. The patients often show the symptoms of dental crowding, posterior crossbite and so on. [1] For patients with maxillary transverse deficiency, maxillary expansion is a standard treatment. This technology was first proposed by Angell in the 1860s. [2] It expands the middle palatal suture by applying lateral force against the teeth and the alveolar bone around the teeth. [3] However, the rapid maxillary expansion device is loaded on maxillary first molars and premolars. During RME, massive orthodontic forces are transmitted

to the alveolar bone through the teeth. [4] So, some undesirable effects may occur in the related teeth and their supporting tissues, including marginal bone loss, tipping of maxillary teeth, bending of the alveolar bone, reduction of buccal bone thickness, and periodontal damages. [5–10]

For the sake of defining the change of alveolar bone after RME, computed tomography was used in studying basal bone changes after RME for the first time. [11] It could show all anatomical structures and assess the buccal and palatal bone thickness through the superposition of multiple planes. [12] Besides, compared with computed tomography, cone-beam computed tomography (CBCT) has higher resolution and lower radiation dose, which is widely used in dentistry. [13]

At present, there are many reports about the changes in the buccal and palatal cortex after rapid maxillary expansion. Still, there are some differences in the methods of measurement and research results. [6,7,14–19] Up to now, there is only one systematic review which has limited statistics on this issue, but no relevant meta-analysis has been published. The purpose of this study is to assess existing literature, performing an updated systematic review, meta-analysis to evaluate and compare the effect on the cortex of molar alveolar bone after RME.

Materials And Methods

Protocol and registration

This systematic review protocol was registered under the PROSPERO register with the number CRD42021228114 (www.crd.york.ac.uk/prospero).

Search strategy

An extensive electronic search was conducted through databases including PubMed, Web of Science, Scopus, and Cochrane Central Register of Controlled Trials (CENTRAL) by the specific search strategy-((maxillary expansion OR rapid maxillary expansion OR RME OR palatal expansion OR rapid palatal expansion OR RPE) AND (alveolar bone OR periodontal)). On this basis, we personalized the retrieval strategy of each database. Besides, we also searched the grey literature in databases. The search strategy of each database was reported in Table 1. Also, the related journals were searched manually. There was no language restriction during the literature search

Two researchers independently completed the literature search. Full articles selected from the abstract were independently evaluated by the two researchers. Finally, the two researchers discussed their results to reach the same agreement.

Criteria for included studies

Studies were included by following selection criteria-Participants, intervention, comparison, outcome, study design (PICOS) format.

(1) Participants (P): Patients diagnosed with transverse maxillary deficiency; Original human studies.

(2) Intervention (I): RME protocol with hass or hyrax application.

(3) Comparison (C): Buccal or palatal bone thickness or marginal bone level of maxillary first molar before treatment.

(4) Outcome (O): The changes of the buccal or palatal alveolar bone thickness or marginal bone level evaluated by CBCT.

(5) Study design (S): Randomized controlled trial, retrospective studies and prospective study.

Moreover, the studies were also excluded as follows: (1) Double publications with the same data; (2) Studies involving subjects with craniofacial anomalies, systemic diseases, previous surgery or another orthodontic intervention; (3) Literature with incomplete data description.; (4) Review articles, case reports, descriptive studies or abstracts.

Risk of bias assessment

We adopted the assessment system created and modified by Saltaji [20] and Yi [21] for risk of bias assessment, which assessed the risk of bias based on four aspects as following: study design, study measurements, statistical analysis and baseline information (Table 2). [22]

Statistical analysis

Review Manager (RevMan5.3; Nordic Cochrane Centre, Cochrane Collaboration, Copenhagen, Denmark) was used for quantitative analysis. The mean differences (MD) with their correspondent 95% confidence intervals (95% CI) were chosen as the treatment effects for the analysis of buccal and palatal cortex thickness and the standardized mean differences (SMD) with their 95% CI were chosen for the analysis of buccal marginal bone level. For studies with high heterogeneity($I^2 > 50\%$), we adopted the random effect model. Otherwise, the fixed-effect model was used. The study with $P < 0.05$ was found to be statistically significant. To explore the stability of the research results, a sensitivity analysis was carried out by omitting relevant studies.

Results

Study selection and description

Figure 1 reports the PRISMA flow diagram describing the selection process. Eight studies met [6, 7, 15–19, 23] the inclusion criteria, and six were selected [7,15–19] for the meta-analysis: their main characteristics are listed in Table 3.

Risk of bias assessment

The results of the risk of bias assessment are shown in Table 4. In the eight included studies, two studies took a low risk of bias, and the other six studies took a medium risk of bias. Among the six articles for quantitative analysis, one took the low risk, and four took the medium risk.

Data analysis

Six studies reported the buccal and palatal cortex thickness or buccal marginal bone level of molar alveolar bone after RME. The feasible data was statistically analyzed to judge the influence of RME for alveolar bone. For the measurement of buccal marginal bone level, the left and right data in two studies [15, 19] were combined by Formula from the Cochrane Handbook. [24]

The results of the meta-analysis are listed in Fig. 2–4. The results showed that the thickness of the distal buccal alveolar bone was significantly reduced of both left (MD 0.53;95% CI:0.15–0.90) and right (MD 0.61;95% CI:0.28–0.94) sides of the maxillary first molar after RME. The same was true for the left (MD 0.63;95% CI:0.28–0.98) and right (MD 0.63;95% CI:0.36–0.91) sides of the mesial buccal side. In addition, the thickness of the palatal bone cortex was increased of both left (MD -0.70;95% CI: -1.68-0.27) and right (MD -0.66;95% CI: -1.42-0.11) maxillary first molars after RME. But because of the considerable heterogeneity (left: I^2 = 92%; right: I^2 = 86%), we adopted the random effect model, and the results were not statistically significant. And subgroup analysis was not possible because of insufficient literature. Therefore, no further discussion would be made in the following analysis.

As for the buccal marginal bone level (vertical distance between the cusp tip and the buccal alveolar crest), the loss of alveolar bone increased significantly after RME (SMD − 0.92;95% CI: -1.20–0.64).

The remaining two studies were not selected for the meta-analysis [6, 23] because of the lack of comparability of data. Garib et al. [6] found that RME reduced the thickness of the buccal alveolar bone and increased the thickness of palatal alveolar bone of posterior maxillary teeth. Brunetto et al. [23] found that reduction of alveolar bone height was detected after RME.

Sensitivity analysis

As for the measurement of buccal cortex thickness, Ballanti et al. [16] used hass appliance, while the other two studies in meta-analysis applied hyrax appliance. In another group of the measurement of buccal marginal bone level, the left and right data in two studies [15, 19] were combined. Therefore, we did a sensitivity analysis by omitting the studies separately. The results are shown in Table 5, which made no change.

Discussion

RME is a conventional treatment for the patients with maxillary transverse deficiency, but during the process of treatment, some undesired effects may also occur, among which alveolar bone absorption is very common. This systematic review and meta-analysis were to explore the changes of alveolar bone thickness and vertical height after RME. As far as we know, Giudice et al. [25] conducted a systematic

review of the relevant contents but did not carry out a quantitative analysis. And there was also a comparison of buccal alveolar bone loss between mini-implant assisted rapid palatal expansion and conventional rapid palatal expansion, but without statistical analysis of effect of RME separately. [26] So, this is the first meta-analysis to evaluate the change in alveolar bone after RME. The results showed that RME could reduce the alveolar buccal bone thickness and marginal bone level of the retention teeth.

In this meta-analysis, after comprehensive studies retrieval and quality evaluation, a total of 8 articles are selected, 6 of which are statistically analyzed, and the remaining two items are only descriptive analysis due to the differences in methodology and data statistics. All the included literature was of medium or above quality.

According to the statistical results of this study, RME can lead to a decrease of buccal alveolar bone thickness and vertical bone level of maxillary first molars (Fig. 2,4). In the assessment of the buccal alveolar bone thickness of maxillary first molars, one study used hass appliance, [16] and the other two used hyrax appliances. [15, 17] However, previous studies [6] have shown that the effects of hass appliance and hyrax appliance on the buccal cortical thickness of molars were the same, and the results were not significantly affected after the sensitivity analysis.

As for the vertical bone level of the edge, two studies measured the left and right molars respectively, [15, 19] while the other two articles combined measurement of bilateral molars. [7, 18] Therefore, according to the Cochrane Handbook, we combined the left and right side data of the two items [15, 19] respectively, and then the sensitivity analysis was carried out. The results showed that there was no noticeable impact. The consistent results seemed to indicate the robustness of the meta-analysis results.

In the statistical study of palatal alveolar bone thickness of maxillary first molar, due to the high heterogeneity, no further discussion was made. Because of the massive difference and lack of relevant studies, the accuracy of the results needs more experimental research.

In each study, the confounding factors such as the activation scheme and appliance retention time may have an impact on the research results, which were slightly different. However, in the meta-analysis of buccal alveolar bone thickness and marginal vertical bone level of maxillary first molars, their influence may not affect the results because of the low heterogeneity between studies.

Finally, although the extensive search was performed, only six studies were selected for the meta-analysis. Because of the small number of included studies, the statistical capacity was insufficient, and the funnel plots of publication bias assessment were not carried out. Thus, the results of this systematic review should be considered with caution. Further high-quality original research is needed to draw more stable conclusions.

In clinical treatment, in order to increase the orthodontic force and reduce the occurrence of periodontal adverse reactions in the process of maxillary expansion, the method of increasing anchorage such as micro implant is often adopted in the process of clinical treatment.[27] In addition, buccal cortical

osteotomy and palatal suture osteotomy can also be used to reduce the resistance of bone in the process of maxillary expansion, so as to increase the success rate of maxillary expansion and reduce the damage of periodontal supporting tissue.[28]

However, when using RME in clinical practice, it is better to evaluate the alveolar bone level of patients to determine whether it is sufficient for RME treatment. In addition, it is suggested that patients with rapid maxillary expansion should be followed up to regularly monitor the changes of alveolar bone, so as to minimize the side effects of rapid maxillary expansion.

Conclusion

According to limited evidence, RME can lead to a decrease of buccal cortical thickness and vertical bone level of alveolar bone in maxillary first molar. However, due to the lack of included studies, these statements are not inclusive. So, these results should be evaluated with caution. More high-quality clinical studies are needed to determine the relevant conclusions further.

Abbreviations

CBCT: cone-beam computed tomography; CCT: clinical controlled trials; CI: Confidence interval; MD: mean differences; RCT: randomized controlled trials; RME: rapid maxillary expansion; SMD: standardized mean differences.

Declarations

Acknowledgements

Not applicable.

Authors' contributions

B.Z. and M.W. conducted literature retrieval, quality evaluation and statistical analysis; B.Z. and F.Z. designed the study; M.W. and Z.Z. wrote the manuscript; F.W. revised the draft and final manuscript. All authors read and approved the final article.

Funding

This study was supported by the National Natural Science Foundation of China (no.81771030 and 82071080).

Availability of data and materials

The summary of data extraction in this study is available upon request to the corresponding author.

Ethics approval and consent to participate

Not applicable.

Consent for publication

Not applicable.

Conflict of interest

The authors have declared that no conflict of interest exists.

Author details

[1]Department of Orthodontics, School and Hospital of Stomatology, Cheeloo College of Medicine, Shandong University & Shandong Key Laboratory of Oral Tissue Regeneration & Shandong Engineering Laboratory for Dental Materials and Oral Tissue Regeneration, No.44-1 Wenhua Road West, Jinan 250012, Shandong, China.

References

1. McNamara JA. Maxillary transverse deficiency. Am J Orthod Dentofacial Orthop. 2000;117:567–70.
2. Haas AJ. Rapid expansion of the maxillary dental arch and nasal cavity by opening the midpalatal suture. Angle Orthod. 1961;31:73–90.
3. Greenbaum KR, Zachrisson BU. The effect of palatal expansion therapy on the periodontal supporting tissues. Am J Orthod. 1982;81:12–21.
4. Langford SR, Sims MR. Root surface resorption, repair, and periodontal attachment following rapid maxillary expansion in man. Am J Orthod. 1982;81:108–15.
5. Baysal A, Karadede I, Hekimoglu S, Ucar F, Ozer T, Veli I, Uysal T. Evaluation of root resorption following rapid maxillary expansion using cone-beam computed tomography. Angle Orthod. 2012;82:488–94.
6. Garib DG, Henriques JF, Janson G, de Freitas MR, Fernandes AY. Periodontal effects of rapid maxillary expansion with tooth-tissue-borne and tooth-borne expanders: a computed tomography evaluation. Am J Orthod Dentofacial Orthop. 2006;129:749–58.
7. Rungcharassaeng K, Caruso JM, Kan JY, Kim J, Taylor G. Factors affecting buccal bone changes of maxillary posterior teeth after rapid maxillary expansion. Am J Orthod Dentofacial Orthop. 2007;132:428.e1-8.
8. Starnbach H, Bayne D, Cleall J, Subtelny JD. Facioskeletal and dental changes resulting from rapid maxillary expansion. Angle Orthod. 1966;36:152–64.
9. Schuster G, Borel-Scherf I, Schopf PM. Frequency of and complications in the use of RPE appliances—results of a survey in the Federal State of Hesse, Germany. J Orofac Orthop. 2005;66:148–61.
10. Erverdi N, Okar I, Kucukkeles N, Arbak S. A comparison of two different rapid palatal expansion techniques from the point of root resorption. Am J Orthod Dentofacial Orthop. 1994;106:47–51.

11. Timms DJ, Preston CB, Daly PF. A computed tomographic assessment of maxillary induced by rapid expansion—a pilot study. Eur J Orthod. 1982;4:123–7.
12. Parks ET. Computed tomography applications for dentistry. Dent Clin North Am. 2000;44:371–94.
13. Mah JK, Danforth RA, Bumann A, Hatcher D. Radiation absorbed in maxillofacial imaging with a new dental computed tomography device. Oral Surg Oral Med Oral Pathol Oral Radiol Endod. 2003;96:508–13.
14. Gönüldaş RS, Özsoy OP, Pamukçu H, Kural F. Comparison of Dentofacial and Periodontal Effects of Rapid and Semi-rapid Maxillary Expansion. Meandros Med Dent J. 2017;18:33–46
15. Baysal A, Uysal T, Veli I, Ozer T, Karadede I, Hekimoglu S. Evaluation of alveolar bone loss following rapid maxillary expansion using cone-beam computed tomography. Korean J Orthod. 2013;43:83–95.
16. Ballanti F, Lione R, Fanucci E, Franchi L, Baccetti T, Cozza P. Immediate and post-retention effects of rapid maxillary expansion investigated by computed tomography in growing patients. Angle Orthod. 2009;79:24–9.
17. Gunyuz Toklu M, Germec-Cakan D, Tozlu M. Periodontal, dentoalveolar, and skeletal effects of tooth-borne and tooth-bone-borne expansion appliances. Am J Orthod Dentofacial Orthop. 2015;148:97–109.
18. Lemos Rinaldi MR, Azeredo F, Martinelli de Lima E, Deon Rizzatto SM, Sameshima G, Macedo de Menezes L. Cone-beam computed tomography evaluation of bone plate and root length after maxillary expansion using tooth-borne and tooth-tissue-borne banded expanders. Am J Orthod Dentofacial Orthop. 2018;154:504–16.
19. Pangrazio-Kulbersh V, Jezdimir B, de Deus Haughey M, Kulbersh R, Wine P, Kaczynski R. CBCT assessment of alveolar buccal bone level after RME. Angle Orthod. 2013;83:110–6.
20. Saltaji H, Major MP, Altalibi M, Youssef M, Flores-Mir C. Long-term skeletal stability after maxillary advancement with distraction osteogenesis in cleft lip and palate patients. Angle Orthod. 2012;82:1115–22.
21. Yi J, Li M, Li Y, Li X, Zhao Z. Root resorption during orthodontic treatment with self-ligating or conventional brackets: a systematic review and meta-analysis. BMC Oral Health. 2016;16:125.
22. Lagravere MO, Major PW, Flores-Mir C. Long-term skeletal changes with rapid maxillary expansion: a systematic review. Angle Orthod. 2005;75:1046–52.
23. Brunetto M, Andriani Jda S, Ribeiro GL, Locks A, Correa M, Correa LR. Three-dimensional assessment of buccal alveolar bone after rapid and slow maxillary expansion: a clinical trial study. Am J Orthod Dentofacial Orthop. 2013;143:633–44.
24. Cumpston M, Li T, Page MJ, Chandler J, Welch VA, Higgins JP, Thomas J. Updated guidance for trusted systematic reviews: a new edition of the Cochrane Handbook for Systematic Reviews of Interventions. Cochrane Database Syst Rev. 2019;10:ED000142
25. Lo Giudice A, Barbato E, Cosentino L, Ferraro CM, Leonardi R. Alveolar bone changes after rapid maxillary expansion with tooth-born appliances: a systematic review. Eur J Orthod. 2018;40:296–

303.

26. Copello FM, Marañón-Vásquez GA, Brunetto DP, Caldas LD, Masterson D, Maia LC, Sant'Anna EF. Is the buccal alveolar bone less affected by mini-implant assisted rapid palatal expansion than by conventional rapid palatal expansion?-A systematic review and meta-analysis. Orthod Craniofac Res. 2020;23:237–49.
27. Ludwig B, Baumgaertel S, Zorkun B, Bonitz L, Glasl B, Wilmes B, Lisson J. Application of a new viscoelastic finite element method model and analysis of miniscrew-supported hybrid hyrax treatment. Am J Orthod Dentofacial Orthop, 2013, 143(3): 426–435.
28. Gallagher V, Gallagher C, Sleeman D. Surgically assisted rapid palatal expansion for management of transverse maxillary deficiency. J Ir Dent Assoc. 2002;48(1):18–21.

Tables

Table 1 Search strategy of databases.

Database of Published Trials	Search strategy	Result
PubMed	((((((maxillary expansion) OR (rapid maxillary expansion)) OR (RME)) OR (palatal expansion)) OR (rapid palatal expansion)) OR (RPE)) AND ((alveolar bone) OR (periodontal))	575
Web of science	maxillary expansion OR rapid maxillary expansion OR RME OR palatal expansion OR rapid palatal expansion OR RPE AND alveolar bone OR periodontal	656
Scopus	(("maxillary expansion" OR "rapid maxillary expansion" OR "RME" OR "palatal expansion" OR "rapid palatal expansion" OR "RPE") AND ("alveolar bone" OR "periodontal"))	568
Cochrane Central Register of Controlled Trials	((maxillary expansion) OR (rapid maxillary expansion) OR (RME) OR (palatal expansion) OR (rapid palatal expansion) OR (RPE)) AND ((alveolar bone) OR (periodontal))	53

Databases of Grey Literature	Search strategy	Result
Open Grey	(("maxillary expansion" OR "rapid maxillary expansion" OR "RME" OR "palatal expansion" OR "rapid palatal expansion" OR "RPE") AND ("alveolar bone" OR "periodontal"))	1
National Technical Information Service	((((((maxillary expansion) OR (rapid maxillary expansion)) OR (RME)) OR (palatal expansion)) OR (rapid palatal expansion)) OR (RPE)) AND ((alveolar bone) OR (periodontal))	0

Table 2 Risk of bias assessment form

Study Design (11√)
1. Objective – clearly defined (√)
2. Population – adequately described (√)
3. Sample size – considered adequate (√)
4. Selection criteria – clearly described (√), adequate (√)
5. Randomization or consecutive selection – stated (√)
6. Follow-up length – clearly described (√)
7. Timing – prospective design (√)
8. Type of Study – RCT (3√), CCT (2√), Cohort study (√)
Study measurements (3√)
9. Measurement method – appropriate (√)
10. Blinding – stated (√)

11. Reliability – Described (√)

Statistical Analysis (4√)

12. Dropouts – accounted (√)

13. Statistical analysis – appropriate (√)

14. Presentation of data – exact P-value (√), variability measures (SD or CI) stated (√)

Baseline (1√)

15. Datum line situation: – two groups were calibrated and most consistent (√)

Maximum score = 19

Table 3 Main characteristics of studies included in the systematic review. RME, rapid maxillary expansion; RCT, randomized controlled trial

Studies	Study design	Sample size	Mean age	Application	Result
Baysal (2012)	Retrospective study	20 patients (9 males and 11 females)	males: 13.97 ± 1.17 years; females: 13.53 ± 2.12 years	Hyrax	The decrease in buccal alveolar bone thickness was statistically significant for the middle levels of the left and right segment. The vertical alveolar height decreased immediately after the expansion period.
Ballanti (2009)	Prospective study	17 patients (7 males and 10 females)	11.2 years (range, 8 to 14 years)	Hass	The alveolar bone thickness corresponding to the mesial and distal roots of the right first molar and the mesial root of the left first molar was a significant decrease. The palatal bone plates thickness of both first molars was significantly increased.
Garib (2006)	RCT	Group 1: 4 patients (4 males) Group 2: 4 patients (4 males)	Group 1: 12.4 years (11.4-13.6 years) Group 2: 12.6 years (11.5-13.9 years)	Group 1: Hass Group 2: Hyrax	RME reduced the buccal bone plate thickness of supporting teeth 0.6 to 0.9 mm and increased the palatal bone plate thickness 0.8 to 1.3 mm. RME caused a significant reduction of alveolar crest level on the buccal aspect of the supporting teeth.
Toklu (2015)	RCT	13 patients (5 males and 8 females)	14.3±2.3 years	Hyrax	There were treatment changes in the hyrax group. Statistically significant decreases were found in the right and left first molar buccal bone thicknesses, whereas significant increases were noted in the first molar palatal bone thicknesses.
Brunetto (2013)	RCT	33 patients (15 males and 18 females)	9 years	Hass	A significant increase in the means related to bone height was detected by measurements distance between the buccal cusp tip and the most occlusal point of the buccal alveolar crest.
Rungcharassaeng (2007)	Prospective study	30 patients (17 males and 13 females)	13.8±1.7 years	Hyrax	The buccal marginal bone level was significant decreases after RME.
Rinaldi (2017)	RCT	18 patients (7 males and 11 females)	11.1±1.25	Hyrax	The consequence of rapid maxillary expansion using the hyrax was alveolar bone resorption.
Kulbersh (2012)	Prospective study	12 patients (6 males and 6 females)	12.6 years	Hyrax	Buccal bone loss in the vertical dimension only showed significance in the right molar.

Table 4 Risk of bias assessment of included studies

Study ID	Study design								Study measurements			Statistical analysis			Baseline	Total
	1	**2**	**3**	**4**	**5**	**6**	**7**	**8**	**9**	**10**	**11**	**12**	**13**	**14**	**15**	
Baysal (2012)	√	√	×	√×	×	√	×	√	√	×	√	√	√	√√	√	12
Ballanti (2009)	√	√	×	√√	×	√	√	√	√	×	√	×	√	√√	√	13
Garib (2006)	√	√	×	√√	√	√	√	3√	√	×	√	×	√	√√	√	16
Toklu (2015)	√	√	×	√×	√	√	√	3√	√	√	√	×	√	√√	√	16
Brunetto (2013)	√	√	×	××	√	√	√	3√	√	×	×	×	√	√√	√	14
Rungcharassaeng (2007)	√	√	≠	××	√	√	√	√	√	×	√	×	√	√√	√	12.5
Rinaldi (2017)	√	√	×	√×	√	√	√	3√	√	×	×	×	√	√√	√	14
Kulbersh (2012)	√	√	×	××	×	√	√	√	√	×	√	×	√	√√	√	11

√ = 1point; ≠ = 0.5point; × = 0point

Table 5 Sensitivity analysis.

	a	b	c	d	e
Exclusion of Ballanti et al. [16]	0.71(0.26-1.16)	0.73(0.31-1.16)	0.74(0.33-1.14)	0.67(0.36-0.99)	
Exclusion of Baysal et al. [15]					-0.87 (-1.21--0.52)
Exclusion of Kulbersh et al. [19]					-1.02 (-1.34--0.71)

a. Distal buccal bone thickness of left maxillary first molar;

b. Distal buccal bone thickness of right maxillary first molar;

c. Mesial buccal bone thickness of left maxillary first molar;

d. Mesial buccal bone thickness of right maxillary first molar;

e. Buccal marginal bone level of maxillary first molar.

Figures

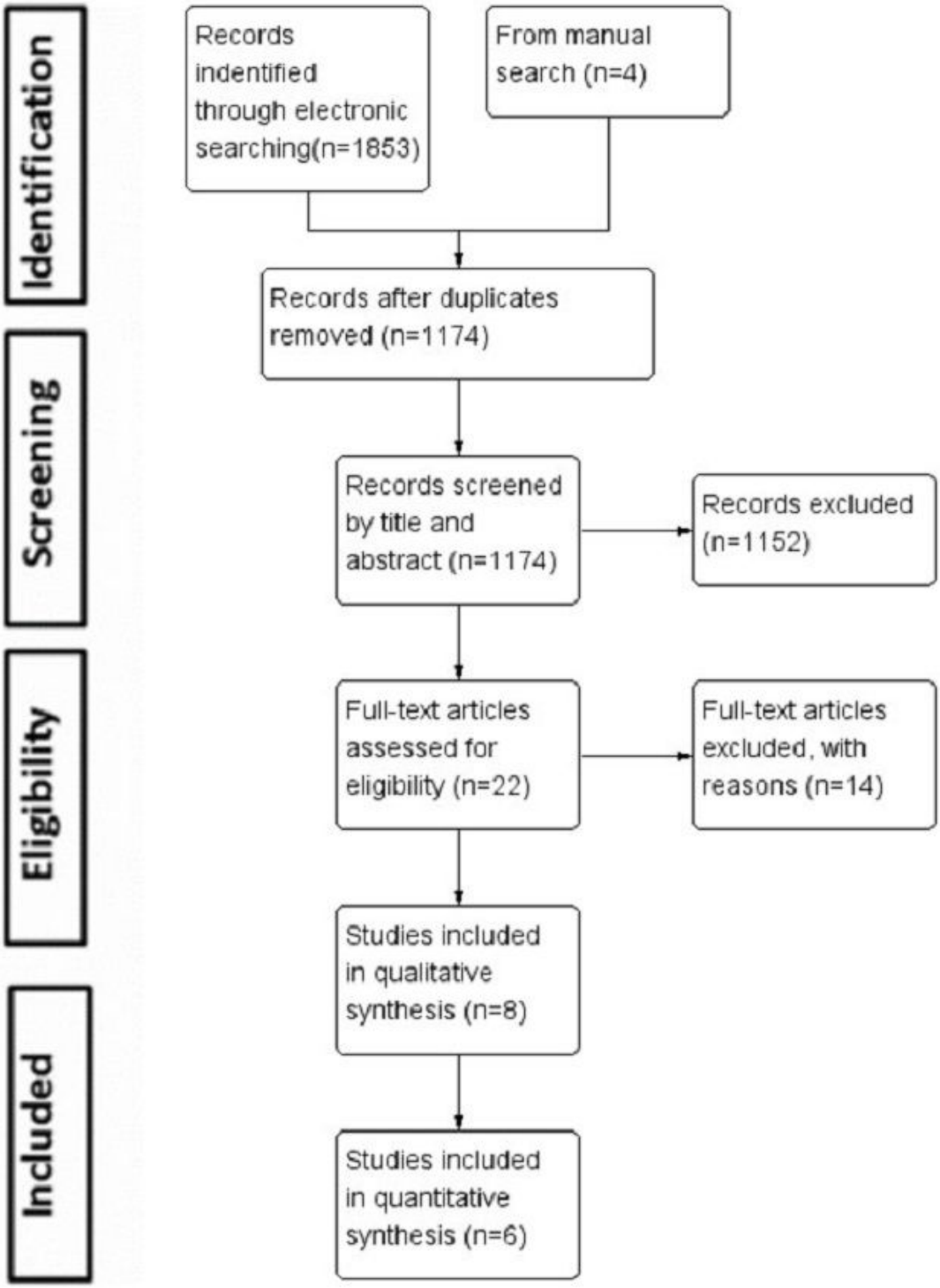

Figure 1

Flow diagram of literature search.

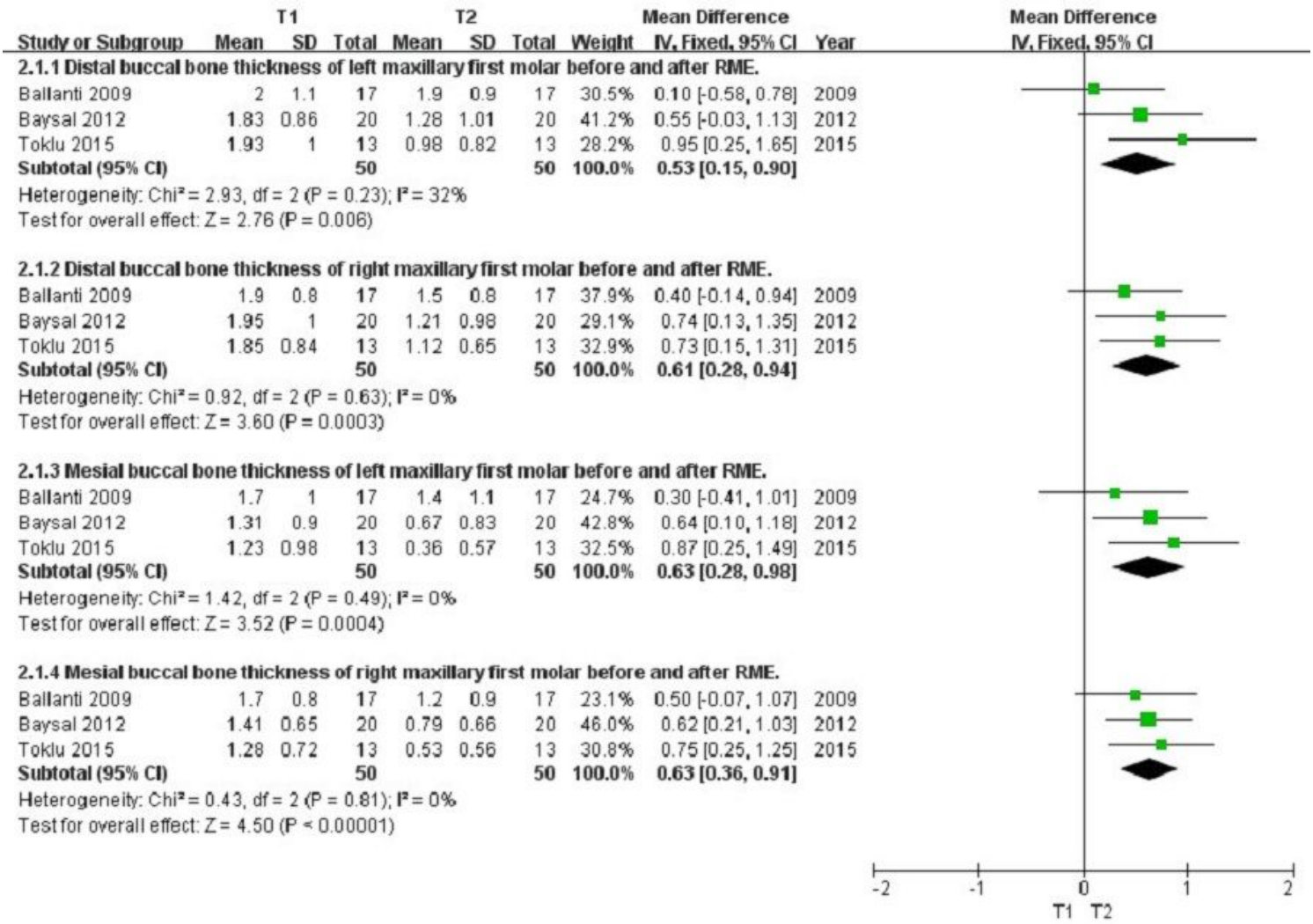

Figure 2

Distal and mesial buccal bone thickness of maxillary first molar before and after RME.

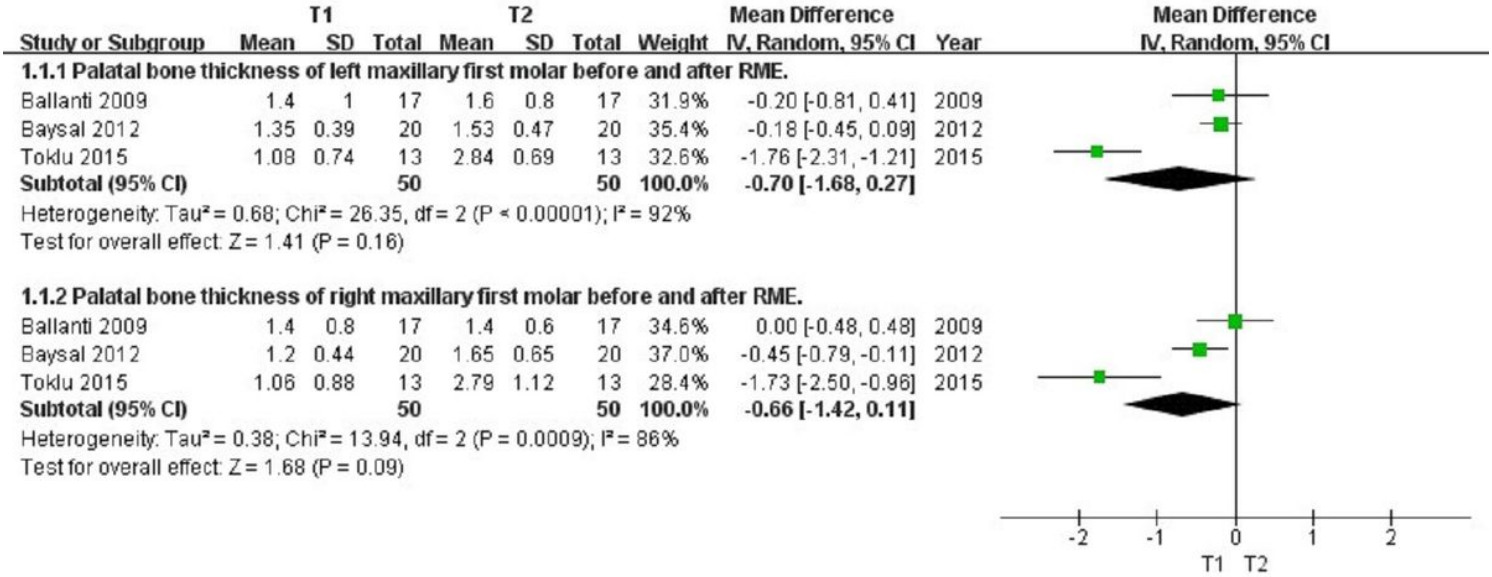

Figure 3

Palatal bone thickness of maxillary first molar before and after RME.

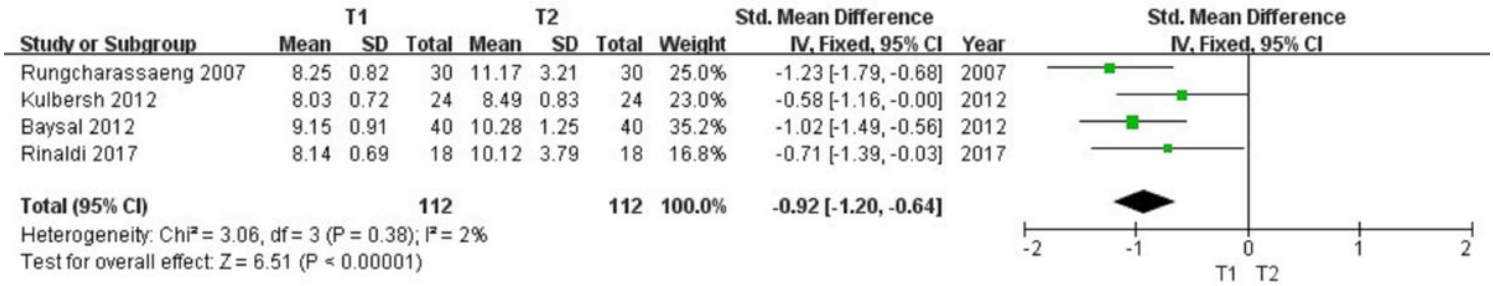

Figure 4

Buccal marginal bone level of maxillary first molar before and after RME.