The efficacy of anterior superior iliac spine (ASIS) as reference for anatomical axis of femur in Unicompartmental knee arthroplasty

Yan Yan
China Japan Friendship School of Clinical Medicine, Peking University https://orcid.org/0000-0002-9187-9318

Lu Feifan
China-Japan Friendship School of Clinical Medicine, Peking University

Cheng Chongjie
Peking Union Medical College

Zhang Qidong
China-Japan Friendship Hospital

Wang Weiguo
China-Japan Friendship Hospital

Guo Wanshou (13622118722@sina.cn)

Research article

Keywords: unicompartmental knee arthroplasty, femoral alignment, ASIS, anatomical axis, mechanical axis

Posted Date: April 1st, 2020

DOI: https://doi.org/10.21203/rs.3.rs-19830/v1

Abstract

Purpose We aim to figure out the deviation of using ASIS as the reference for femoral anatomical axis (AA) in unicompartmental knee arthroplasty (UKA) and the degree of angle between AA and actual mechanical axis (MA) in the coronal plane for patients with medial compartment knee osteoarthritis (KOA).

Patients and Methods Between December 2017 to December 2019, a total of 120 consecutive knees (104 patients) with severe medial compartment KOA were included in this study. The weight-bearing full-length radiographs of included knees were analyzed using Picture Archiving Communication System (PACS). The lines of AA, operation AA (oAA) and MA were identified. Angles between AA and oAA (Angle 1), AA and MA (Angle 2) were measured on the radiographs. Symbol “+” and ”-” were attached with angles between AA and oAA to describe the situation when oAA lies in the lateral or medial side of AA. The statistical analysis was done using SPSS Version 23.0. A p values 0.05 were considered to be significant.

Results: The deviation angle between AA and oAA in the coronal plane (Angle 1) was (0.91±1.08)° (-2.61°-3.04°). The angle between AA and MA in the coronal plane (Angle 2) was (6.26±1.01 °° (3.95°-8.93°). No significant differences of Angle 1 and Angle 2 were found between sexes. For knees with partial thickness cartilage loss (PTCL) (n=39) and full thickness cartilage loss (FTCL) (n=81), Angle 1 was statistically significantly different in the 120 knees (0.61°vs.1.05°;p=0.035). While the Angle 2 for knees with PTCL and FTCL was (6.13±0.80)° (4.83°-7.99°, p=0.326) and (6.32±1.09)° (3.95°-8.93°, p=0.326), respectively.

Conclusion A mean deviation angle of 0.91° was identified between AA and oAA, the value of which could be larger in knees with FTCL. ASIS may not be a reliable reference for AA of femur in UKA patients. And an adjustment of at most 1.0°of varus angle may help achieve better coronal alignment.

1. Introduction

As a main cause of lower limb pain and disability worldwide, knee osteoarthritis (KOA) has great impacts on the quality of patients’ life and brings heavy burden for public health system[1, 2]. Unicompartmental knee arthroplasty (UKA) is an effective treatment for end-stage, symptomatic unicompartmental knee osteoarthritis. It’s demonstrated that postoperative alignment of implant in lower limb will significantly affect the outcome and survivorship of UKA[3, 4]. Although a recent study claimed that most of the orthopedic operators were liable to use intramedullary (IM) rod in femur while making the vertical tibial saw cut[5], there still exists controversy in the field of reference determine the alignment in lower limb. It’s recommended to use intramedullary technique for femoral bone preparation in Oxford UKA (Oxford unicompartmental knee, OUKA; Biomet, Bridgend, UK). The new Oxford UKA manual guidance pointed out that the IM rod was inserted from the point where anatomical axis (AA) cross the surface of distal femur towards ASIS[6, 7]. Represented by the IM rod, the operation AA (oAA) was determined in order to further

find the direction of femoral mechnical axis (MA), which was especially important to the osteotomy of tibia[8].

However, the use of an IM guide for standardized femoral preparation does not always guarantee accuracy of implant positioning and alignment in clinical practice. Considering the differences existing in the anthropometry of patients' femoral shaft, it may lead to severe coronal malalignment. What's more, can the ASIS act as a reliable reference for the AA of femur? That's an issue that needs to be addressed. And if there really exist constant deviation in the angle between AA and the IM line, we may reconsider the predetermined angle for the determination of MA. Nevertheless, few researches about the issue above was available. Thus the purpose of our study was to figure out the accuracy of using ASIS as the reference for femoral AA in UKA and the degree of angle between AA and MA in the coronal plane for patients with medial KOA.

2. Patients And Methods

The present study was approved by the institutional review board. We examined the prospective database of China-Japan Friendship Hospital to identify consecutive patients undergoing medial phase 3 Oxford UKA via a minimally invasive approach with microplasty instruments by one surgeon (Wanshou GUO).

The indications for UKA were severe knee pain involving the medial compartment and considerable difficulty in walking and performing daily activities. Radiographs demonstrated medial loss of articular cartilage is evidenced by a narrow medial joint width. The other indications were an intact anterior cruciate ligament (ACL), varus deformity of < 15°, flexion contracture of < 15°, and an intact lateral compartment. The preoperative diagnosis was osteoarthritis in all patients. Informed consent was obtained from all individual participants included in the study.

The preoperative weight-bearing anteroposterior (AP) and lateral, and full length radiographs including ASIS were available. Care was taken to ensure that each patient stood with his or her patellae facing forward to minimize rotational variation among AP radiographs. Preoperative weighted AP radiographs of target patients was checked using Picture Archiving Communication System (PACS, FIRSTECH, Hefei, Anhui, China) by two separated authors (Yan YAN and Chongjie CHENG) to identify knees with OA in the medial compartment. Kellgren-Lawrence Grading Scale was used to assess the conditions of knees. Only knees with rating of grade 3 or 4 were enrolled in this study. UKAs carried for spontaneous necrosis of the knee (SONK), according to radiological or histological diagnosis, or that fail to fulfil other indication for UKA such as: a functionally normal ACL, a functionally normal medial collateral ligament, intact full-thickness lateral cartilage and a patellofemoral joint (PFJ) with no lateral grooving and bone loss, were excluded from the analysis. Knees with any deformity such as post-fracture or osteotomy influencing the femoral shaft morphology were also excluded from our study. In addition, knees without weight-bearing full length radiographs including ASIS were excluded. Between December 2017 to December 2019, a total of 120 consecutive knees (104 patients) with medial compartment KOA were identified and included in this study. Patient details are described in Table 1.

Table 1
Patient demographic

	Value, mean ± SD (range)
Age (years)	67.6 ± 8.6 (47–85)
Gender (knees)	Male: 23; Female: 97
BMI (kg/m²)	26.5 ± 3.4 (17.5–36.1)
Side	Left: 57; Right: 63
Cartilage loss in medial compartment	PTCL:39; FTCL: 81
BMI: body mass index; SD: standard deviation; PTCL: partial thickness cartilage loss; FTCL: full thickness cartilage loss.	

The full length alignment radiographs of included knees were analyzed using PACS by two authors (Yan YAN and Chongjie CHENG) individually. In order to determine the MA of femur, a line was drawn from the center of the femoral head to the center of the knee. The center of femoral head was identified using Mose circle while the center of the femoral condyles in the plane of the deepest point of the intercondylar notch was defined as the center of the knee (Fig. 1). The femoral AA was drawn as a line connecting the midpoint of the shaft just inferior to the level of the less trochanter and the midpoint of the shaft 10 cm proximal to knee joint (Fig. 2). The oAA was defined as the line connecting the point of ASIS and the entrance point of IM rod. The point of ASIS could be easily located in full length alignment radiograph. While the entrance point of IM rod was identified as the point where the AA intersects the surface of distal femur (Fig. 3). The angles between AA and oAA (Angle 1), AA and MA (Angle 2) were measured on the radiographs by two individual examiners (Yan YAN and Chongjie CHENG). Symbol “+” and ”-” attached to angles between AA and oAA were used to describe the situation when oAA lies in the lateral or medial side of AA. The statistical analysis was done using SPSS Version 23.0. A p values <0.05 were considered to be significant.

3. Results

A total of 120 knees (104 patients) were analyzed. The deviation angle between AA and oAA in the coronal plane (Angle 1) was (0.91 ± 1.08)° (-2.61° at minimum, 3.04° at maximum, Table 2). Among all the included knees, 17 out of them were associated with angles symbolized by “-”, indicating that the line of oAA appeared in the medial side of AA. While the oAA line of rest 103 knees lied in the lateral side of AA. The angle between AA and MA in the coronal plane (Angle 2) was (6.26 ± 1.01)° (3.95° at minimum, 8.93°at maximum, Table 2).

The Angle 1 for knees of male patients (n = 23) was (1.04 ± 1.15)° (-1.93° at minimum, 2.79° at maximum, p = 0.526, Table 2). When it comes to knees of female patients (n = 97), the value of Angle 1 was (0.88 ± 1.07)° (-2.61° at minimum, 3.04° at maximum, p = 0.526, Table 2). The Angle 2 for knees of male and

female patients was (6.28 ± 0.94)° (4.59° at minimum, 8.38° at maximum, p = 0.894, Table 2) and (6.25 ± 1.03)° (3.95° at minimum, 8.93°at maximum, p = 0.894, Table 2), respectively.

The Angle 1 for knees with PTCL (n = 39) was (0.61 ± 1.14)° (-2.40° at minimum, 2.77° at maximum, p = 0.035, Table 2). While the value of Angle 1 in knees with FTCL (n = 97) was (1.05 ± 1.03)° (-2.61° at minimum, 3.04° at maximum, p = 0.035, Table 2). The angle 2 for knees with PTCL and FTCL was (6.13 ± 0.80)° (4.83° at minimum, 7.99° at maximum, p = 0.326, Table 2) and (6.32 ± 1.09)° (3.95° at minimum, 8.93°at maximum, p = 0.326, Table 2), respectively.

Table 2
The value of Angles measured on enrolled knees

Factor	Angle 1* (degree)	Angle 2* (degree)
All knees (n = 120)	0.910 ± 1.08 (-2.61-3.04)	6.26 ± 1.01 (3.95–8.93)
Knees of male patients (n = 23)	1.04 ± 1.15 (-1.93-2.79)	6.28 ± 0.94 (4.59–8.38)
Knees of female patients (n = 97)	0.88 ± 1.07 (-2.61-3.04)	6.25 ± 1.03 (3.95–8.93)
p-value	0.526	0.894
Knees with PTCL (n = 39)	0.61 ± 1.14 (-2.40-2.77)	6.13 ± 0.80 (4.83–7.99)
Knees with FTCL (n = 81)	1.05 ± 1.03 (-2.61-3.04)	6.32 ± 1.09 (3.95–8.93)
p-value	0.035	0.326

Angle 1: angle between anatomical axis and operation anatomical axis in the coronal plane; Angle 2: angle between anatomical axis and mechanical axis in the coronal plane; PTCL: partial thickness cartilage loss; FTCL: full thickness cartilage loss.

4. Discussion

The main finding of the present study was that there exists a deviation angle of (0.91 ± 1.08)° (-2.61° at minimum, 3.04° at maximum) between AA and oAA in the coronal plane in knees with severe medial compartment OA. While the value for knees with PTCL and FTCL was (0.61 ± 1.14) ° (-2.40° at minimum, 2.77° at maximum, p = 0.035) and (1.05 ± 1.03)° (-2.61° at minimum, 3.04° at maximum, p = 0.035) on average, respectively. To our knowledge, this is the first study performed to show the specific numerical value of coronal deviation between AA and oAA in knees with severe KOA according to our search result.

OUKA heralded the biggest advance in modern-day UKA with a market share of over 66% according to the annual report from the National Joint Registry (NJR) in the United Kingdom[9]. Until 1998, The Oxford UKA has been updated to the third generation. In 2012, new microplasty instruments were introduced for OUKA, making the surgery more reliable and reproducible[8, 10, 11]. The microplasy operation technique of the phase 3 OUKA firstly proposed the method of using ASIS as reference for anatomical axis of femur

in UKA[7], which showed great superiority in femoral alignment[12] and was later accepted by most of surgeons engaged in UKA operation. Before this, surgeons used to take the center of femoral head as the reference for MA so as to guide the resection of tibia in UKA. And the position deviation of femoral prosthesis during UKA is as high as 32% previously[13, 14].

Although many surgeons have reported acceptable to good outcomes of OUKA with microplasty instruments, few research was conducted to examine the efficacy of ASIS as reference for AA of femur until now. Previously, several studies reported various accuracy of femoral IM technique ranging from 85 to 96% in the normal range in total knee arthroplasty (TKA)[15–18]. An image-based research by Wu explored the accuracy of the method above and found that the shaft AA was significantly different from the clinical AA with a deviation angle of 0.8°in 100 patients[19]. However, only patients with unilateral femoral or tibial nonunions or malunions were included in his study. In 2019, Yang et al. reported an average angle of 0.96°between femoral IM guide rod and femoral AA in the coronal plane according to Intraoperative X-ray films of 50 OUKA patients (50 knees)[20]. But, no further analysis was conducted to obtained deviation angle of different subgroup in this paper. Considering that most of the candidates for UKA are patients with severe OA in medial compartment of the knee, the cartilage loss of which will undoubtedly affect the accuracy of lower extremity alignment with this method.

In our study, a mean deviation angle (Angle 1) of 0.91° was identified between AA and oAA, indicating that the oAA was approximately 0.91° vagus when compared against the actual AA coming through the middle of femoral shaft in the coronal plane. This is a considerable value of deviation in that the alignment of lower limb would be significantly affected by inaccurate resection of proximal tibia. With incorrect implantation of prosthesis, it' difficult to balance the flexion gap and extension gap, which may result in aseptic loosing, dislocation of bearing and impaired survivorship of implantation[3, 4]. Adjustment of at most 1.0°of varus angle may help to achieve better coronal alignment according to our study. While the angle between AA and MA (Angle 2) was consistent with the range reported in previous research (5–7°). In addition, it's obvious that there was no significant difference between knees of male and female patients when considering Angle 1 and Angle 2 ($p > 0.05$). However, the degree of cartilage loss in knees with OA was related to different outcomes. The Angle 1 for knees with PTCL ($n = 39$) was 0.61° on average (-2.40° at minimum, 2.77° at maximum, $p = 0.035$). While the mean value of Angle 1 in knees with FTCL ($n = 97$) was 1.05° (-2.61° at minimum, 3.04° at maximum, $p = 0.035$). With a p value of 0.035, we have confidence to say that the deviation angle between AA and oAA was significantly larger in knees with FTCL when compared against PTCL knees. That's to say, the degree of cartilage loss in knees was associated with deviation of alignment. FTCL was identified only when "bone to bone " abrasion was observed in the radiographs of medial compartment of knee[21]. In knees with FTCL, bone defect, deformity and dislocation appeared to a variety of degree, all of which will influence the accuracy of alignment. While knees with PTCL were free of severe bone defect, with which the anatomic landmarks of femur and pelvis were more reliable. The result reminded us that more attention must be paid when performing UKA on knees with FTCL because of greater deviation in alignment.

In general, a mean deviation angle of 0.91° was identified between AA and oAA, the value of which could be especially larger in knees with FTCL rather than those with PTCL. The Oxford group recommended that the force line of femoral prosthesis should be parallel to the MA of the lower extremities[7]. However, our study demonstrated that the IM rod in the femoral bone marrow is not completely located in the AA of the femur in the coronal position, but closer to the medial femoral cortex. With a deviation angle of 0.91°, ASIS may not be a reliable reference for AA of femur in UKA patients. Thus we recommended an adjustment of at most 1.0°of varus angle of intramedullary rod to help achieve better coronal alignment. What's more, although the Oxford group agreed that UKA should only be performed on patients with FTCL in medial compartment of the knee[22], an amount of surgeons performed UKA on KOA patients with PTCL. Due to our results, the deviation between oAA and AA was especially significant in FTCL patients with a mean value of 1.05°. So we suggested orthopedic operators to assess the joint space between femur and tibia on pre-operative radiographs carefully and figure out the deviation angle in advance. Necessary adjustment must be made with the direction of IM rod prudently.

Inevitably, there are some limitations in our study. First, the number of patients was restricted and only patients with medial KOA who have underwent UKA was enrolled. Therefor, our results may only apply to medial KOA patients, especially on making pre-operation plans of UKA. Secondly, all the participants were Chinese. There exist varieties of anatomical differences between Chinese and other races, including height, weight, length of the femur, femoral anterior condyle, femoral posterior condyle and tibial torsion angle. Therefore, cautions should be applied when interpreting the results in this study. Thirdly, all the results were obtained from measurement of the X-ray radiographs. The lack of three-dimensional images means that the findings was reliable only in the coronal plane. Lastly, the entry point of the IM rod was defined as the point at which the AA intersects the surface of the distal femur. In fact, the Oxford group recommended a hole situated approximately 1 cm anterior to the insertion of the posterior cruciate ligament and 2–3 mm lateral to the medial wall of the intercondylar notch to be used as the entry point[7]. Therefore, the results should not be simply applied in operations without prudence.

5. Conclusion

A mean deviation angle of 0.91° was identified between AA and oAA, the value of which could be larger in knees with FTCL. ASIS may not be a reliable reference for AA of femur in UKA patients. And we recommended a adjustment of at most 1.0°of varus angle to help achieve better coronal alignment.

Abbreviations

ASIS: anterior superior iliac spine; KOA: knee osteoarthritis; UKA: unicompartmental knee arthroplasty; IM: intramedullary; OUKA: Oxford unicompartmental knee arthroplasty; AA: anatomical axis; oAA: operation anatomical axis; MA: mechanical axis; AP: anteroposterior; PACS: picture archiving communication system; SONK: spontaneous necrosis of the knee; PTCL: partial thickness cartilage loss; FTCL: full thickness cartilage loss; ACL: anterior cruciate ligament; PFJ: patellofemoral joint; BMI: body mass index; SD: standard deviation; NJR: national joint registry; TKA: total knee arthroplasty;

Declarations

Acknowledgements

Not applicable.

Authors' contributions

Y-Y and FF-L contributed to the conception and design. WS-G and QD-Z did the interpretation. Y-Y and CJ-C did the data collection and analysis. Y-Y wrote the article. QD-Z and WG-W did the final approval of the version to be submitted.

Funding

This study was funded by National Natural Science Foundation of China (grant number 81703896, 81673776), Beijing municipal science and technology commission (grant number Z171100001017209), and the Capital Health Research and Development of Special (grant number 2016-2-4062). The Fund's role is to provide review and publishing costs.

Availability of data and materials

Not applicable.

Ethics approval and consent to participate

All procedures performed in studies involving human participants were in accordance with the ethical standards of the institutional and/or national research committee and with the 1964 Helsinki declaration and its later amendments or comparable ethical standards.

Consent for publication

The subjects gave consent for any form of information about themselves to be published in Journal of Orthopaedic Surgery and Research.

Competing Interests

The authors declare that they have no conflict of interests.

Author details

1 China-Japan Friendship School of Clinical Medicine, Peking University, No.2 Yinghua East Street, Beijing 100029, China. 2 Peking Union Medical College, Dongcheng District, Beijing 100029, China. 3 Department of Orthopedic Surgery, China-Japan Friendship Hospital, No.2 Yinghua East Street, Beijing,100029, China.

References

[1]. Hunter, D.J. and S. Bierma-Zeinstra, Osteoarthritis. Lancet, 2019. 393(10182): p. 1745-1759.

[2]. Martel-Pelletier, J., et al., Osteoarthritis. Nat Rev Dis Primers, 2016. 2: p. 16072.

[3]. □□□□, □□□□□□□□□□□□□□□□□. □□□□□□□□□(□□□), 2013. 7(04): □443-447□.

[4]. Kang, K.T., et al., Preservation of femoral and tibial coronal alignment to improve biomechanical effects of medial unicompartment knee arthroplasty: Computational study. Biomed Mater Eng, 2018. 29(5): p. 651-664.

[5]. Jung, W.H., et al., The accuracy of the extramedullary and intramedullary femoral alignment system in total knee arthroplasty for varus osteoarthritic knee. Knee Surg Sports Traumatol Arthrosc, 2013. 21(3): p. 629-35.

[6]. Hurst, J.M. and K.R. Berend, Mobile-bearing unicondylar knee arthroplasty: the Oxford experience. Orthop Clin North Am, 2015. 46(1): p. 113-24.

[7]. Morris M J , et al. Unicompartmental Knee Replacement With New Oxford Instruments. Operative Techniques in Orthopaedics, 2012, 22(4):189-195.

[8]. Dunn, A.S., S.C. Petterson and K.D. Plancher, Unicondylar knee arthroplasty: intramedullary technique. Clin Sports Med, 2014. 33(1): p. 87-104.

[9]. NJR Online Annual Report 2016; 2016.

[10]. Zhao, D., et al., [Effect of accuracy of phase 3 Oxford prosthesis positioning on short-term effectiveness of unicompartmental knee arthroplasty]. Zhongguo Xiu Fu Chong Jian Wai Ke Za Zhi, 2018. 32(12): p. 1518-1523.

[11]. Xu, T., et al., Mid-term results of Oxford phase-3 medial unicompartmental knee arthroplasty for medial arthritis in Chinese patients. ANZ J Surg, 2017. 87(4): p. 287-290.

[12]. Tu, Y., et al., Superior femoral component alignment can be achieved with Oxford microplasty instrumentation after minimally invasive unicompartmental knee arthroplasty. Knee Surg Sports Traumatol Arthrosc, 2017. 25(3): p. 729-735.

[13]. Kim, J.G., et al., The radiological parameters correlated with the alignment of the femoral component after Oxford phase 3 unicompartmental knee replacement. J Bone Joint Surg Br, 2012. 94(11): p. 1499-505.

[14]. Clarius, M., et al., Correlation of positioning and clinical results in Oxford UKA. Int Orthop, 2010. 34(8): p. 1145-51.

[15]. Catani, F., et al., Navigation-assisted total knee arthroplasty in knees with osteoarthritis due to extra-articular deformity. Knee Surg Sports Traumatol Arthrosc, 2012. 20(3): p. 546-51.

[16]. de Kroon, K.E., S. Houterman and R.P. Janssen, Leg alignment and tibial slope after minimal invasive total knee arthroplasty: a prospective, randomized radiological study of intramedullary versus extramedullary tibial instrumentation. Knee, 2012. 19(4): p. 270-4.

[17]. Cates, H.E., et al., Intramedullary versus extramedullary femoral alignment systems in total knee replacement. Clin Orthop Relat Res, 1993(286): p. 32-9.

[18]. Bono, O.J., et al., Femoral Intramedullary Alignment in Total Knee Arthroplasty: Indications, Results, Pitfalls, Alternatives, and Controversies. J Knee Surg, 2020. 33(1): p. 12-14.

[19]. Wu, C.C., Is clinical measurement of anatomic axis of the femur adequate? Acta Orthop, 2017.

Figures

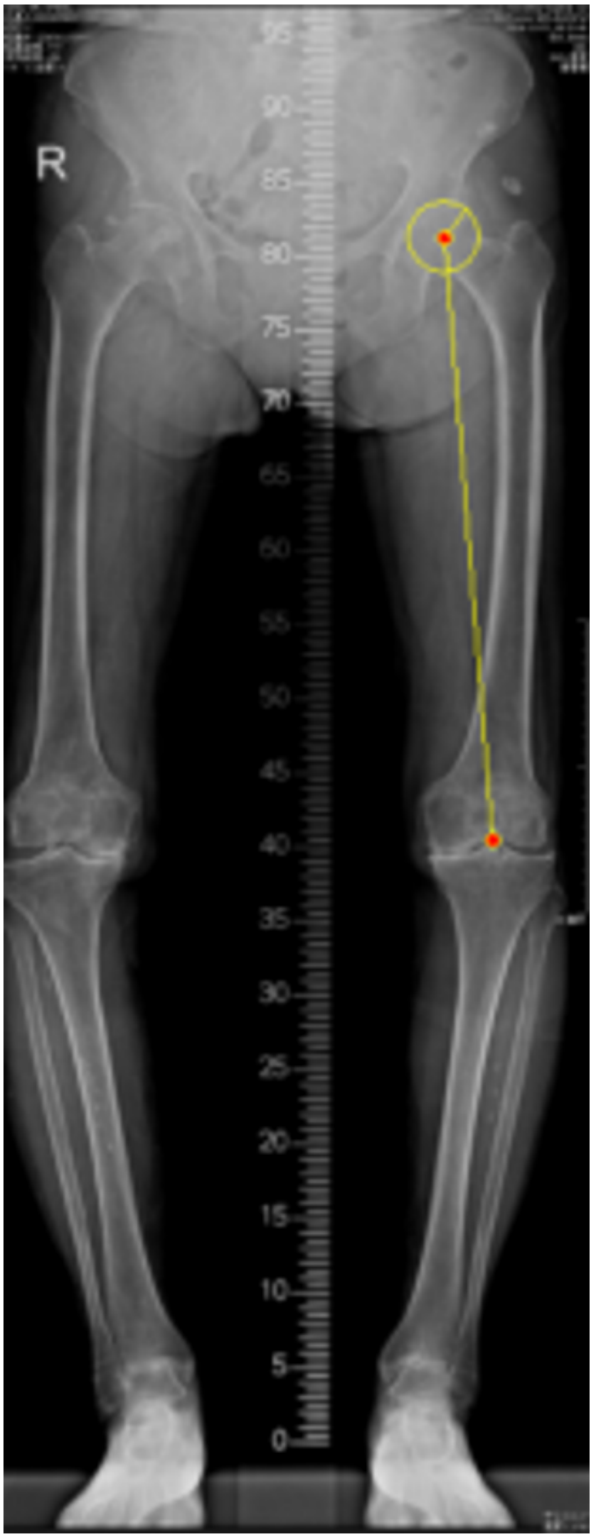

Figure 1

MA was defined as the line connecting the center of the femoral head the deepest point of femoral intercondylar notch.

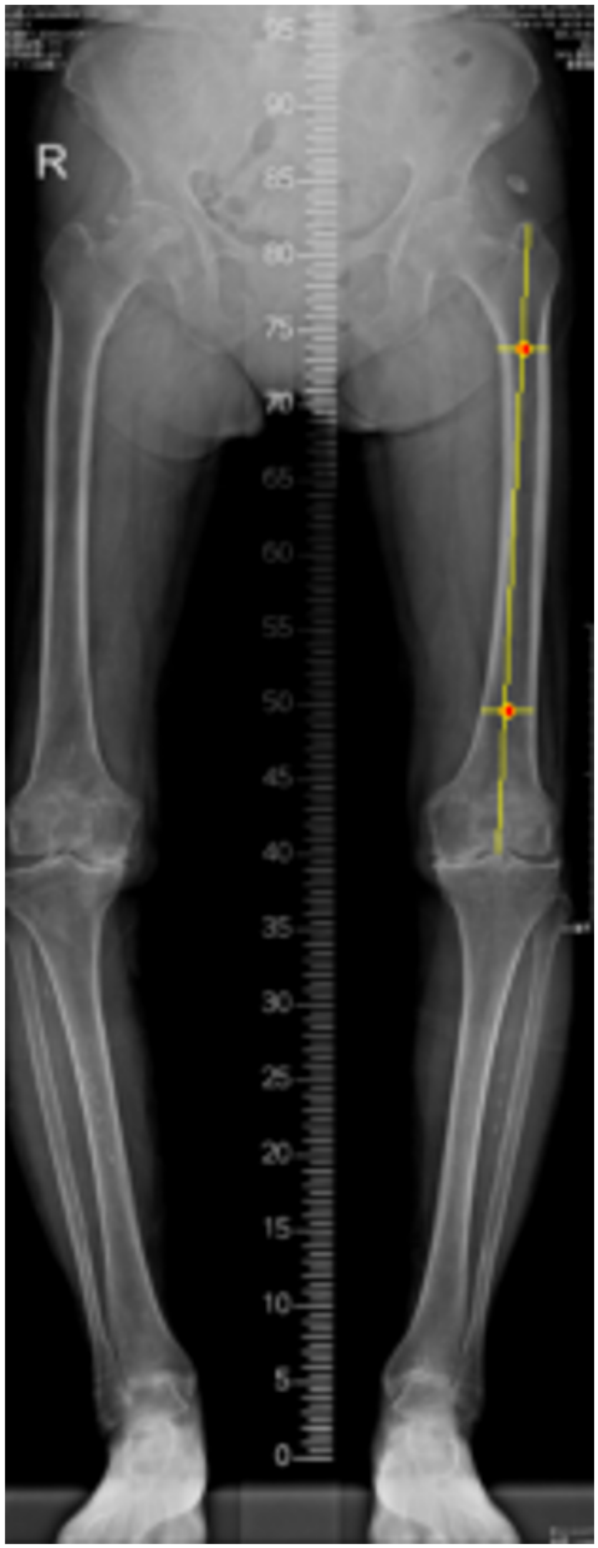

Figure 2

AA was defined as the line connecting the midpoint of the shaft just inferior to the level of the less trochanter and the midpoint of the shaft 10 cm proximal to the the knee joint.

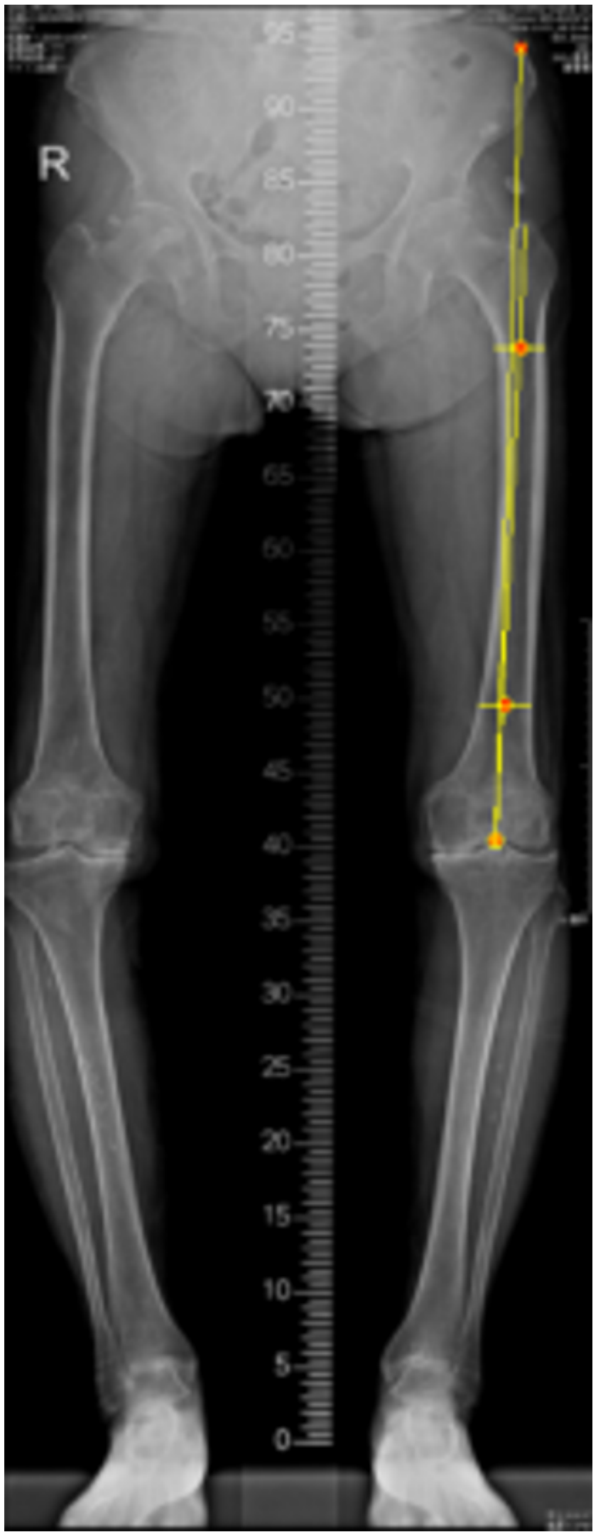

Figure 3

oAA was defined as the line connecting the point of ASIS and the point where the AA intersects the surface of distal femur.