Percutaneous Endoscopic Unilateral Laminotomy and Bilateral Decompression under 3D Real-Time Image-Guided Navigation for Spinal Stenosis in Degenerative Lumbar Kyphoscoliosis Patient: An Innovative Preliminary Study

Tsung-Yu Ho
China Medical University Hospital
Chung-Wei Lin
China Medical University Hospital
Chien-Chun Chang (ccchangmd@gmail.com)
China Medical University Hospital https://orcid.org/0000-0003-2571-9284
Hsien-Te Chen
China Medical University Hospital
Yen-Jen Chen
China Medical University Hospital
Yuan-Shun Lo
China Medical University Hospital
Pan-Hsuan Hsiao
China Medical University Hospital
Po-Chen Chen
Ministry of Health and Welfare, Changhua Hospital
Chih-Sheng Lin
National Chiao Tung University College of Biological Science and Technology
Hsi-Kai Tsou
Taichung Veterans General Hospital

Technical note

Keywords: Navigation, Spinal stenosis, Lumbar spine, Endoscopic surgery, Kyphoscoliosis, Decompression alone

Posted Date: April 1st, 2020

DOI: https://doi.org/10.21203/rs.3.rs-20115/v1

Abstract

Background

The aim of this study is to report a new method of percutaneous endoscopic decompression under 3D real-time image-guided navigation for spinal stenosis in degenerative kyphoscoliosis patients without instability or those who could not endure major surgery due to multiple comorbidities. Decompression along using endoscope for kyphoscoliosis patient is technical demanding and may result in unnecessary bone destruction leading to further instability. With 3D real-time image-guided navigation, we could improve the accuracy of surgery and maintain the spinal stability as preoperative condition. This is the first study which reports on treating spinal stenosis in patients with degenerative kyphoscoliosis using percutaneous endoscope under 3D real-time image-guided navigation.

Methods

In this study, we presented four cases. All patients were over 70 years old with variable degrees of kyphoscoliosis and multiple comorbidity who could not endure major spine fusion surgery. Percutaneous endoscopic unilateral laminotomy and bilateral decompression under 3D real-time image-guided navigation were successfully performed. Intraoperative photos demonstrating this technique are also provided

Results

All patients were successfully treated with percutaneous endoscopic laminotomy with under 3D real-time image-guided navigation. Post-operative X ray and MRI were arranged and revealed sufficient decompression without any unnecessary bone destruction. All preoperative neurological symptoms improved postoperatively. There is no surgery-related complication such as inadequate decompression, dural tear, iatrogenic neurological injury, uncontrolled epidural hemorrhage, unnecessary bone destruction with further instability.

Conclusions

To the best of our knowledge, this is the first preliminary study of percutaneous endoscopic laminotomy under O-arm navigation with successful outcomes. The innovative technique serves as a promising solution in treating spinal stenosis patients with lumbar kyphoscoliosis and multiple comorbidities.

Background

With aging of the population, spinal stenosis with degenerative kyohoscoliosis has become an increasingly common condition. Lumbar spinal stenosis with or without degenerative spondylolisthesis is a pathologic condition that is often observed in the geriatric population, which is the spinal canal narrowing with soft tissue and bone surrounding, and may present with clinical symptoms such as radicular leg pain or neurogenic claudication.[1, 2]

Previous randomized controlled trials show that the patients with degenerative spondylolisthesis and spinal stenosis treated surgically have greater improvement in pain and function than patients treated non-surgically.[3, 4] Various studies have evaluated the efficacy of decompression along versus decompression with fusion for this condition, but the results are still conflicting.[5–9] Decompression alone have shown similar results in clinical outcomes compared to decompression with fusion in certain groups of patients.[5, 7, 9] Open discectomy with laminotomy or laminectomy alone has been considered as standard treatment for lumbar spinal stenosis without

instability during the last decades.[10] Percutaneous endoscopic decompression which features less tissue disruption and small incisions serves as a solution to these patients. However, decompression alone using endoscope for kyphoscoliosis patient is technically demanding and may result in unnecessary bone destruction leading to further instability.

Considerable advances in 3D real-time image navigation have changed the nature of spine surgery.[11, 12] With the assistance of 3D real-time image navigation, the depth and location of endoscope trocar, high speed burr and relevant anatomy could be instantly demonstrated on the monitor during endoscopic operation. The risk of inadequate decompression, dural tear, iatrogenic neurological injury, uncontrolled epidural hemorrhage, unnecessary bone destruction with further instability could be thus limited. This is the first study reporting endoscopic decompression surgery under 3D real-time image navigation to treat degenerative kyphoscoliosis patients.

The purpose of this study is to describe a novel method which combined percutaneous endoscopic surgery and 3D real-time image navigation. The preliminary result shows adequate and precise decompression without leading to further instability when treating spinal stenosis in degenerative kyphoscoliosis patients.

Methods

1. Patient Enrollment

Four kyphoscoliosis patients diagnosed with lumbar spinal stenosis between March 2017 and January 2018 were enrolled in this study. The participants included four women with an average age of 80.25 years (range, 73–86 years). The average Body Mass Index (BMI) was 24.58 (range, 19.94–28.36). The affected levels ranged from L2-S1. As for the degree of spinal deformity, data were summarized in Table 1 According to Schwab Classification.[13]

Table 1
Profiles of Patient with Kyphoscoliosis

	Case 1	Case 2	Case 3	Case 4
Age	73	86	82	80
Gender	Female	Female	Female	Female
BMI	28.36	23.37	19.94	26.63
Comorbidities	Diabetes Mellitus Chronic Kidney Disease StageIII Chronic Obstructive Pulmonary Disease	Paroxysmal atrial fibrillation Hypertension Diabetes Mellitus Chronic Kidney Disease StageII	Chronic Kidney Disease StageIII Dementia	Hypertension Diabetes Mellitus Congestive Heart Failure
Schwab Classification for Adult Spinal Deformity				
Type and Location of Deformity	TypeV Lumbar Major Curve	TypeV Lumbar Major Curve	TypeV Lumbar Major Curve	TypeV Lumbar Major Curve
Lordosis Modifier: Sagittal Cobb angle from T12 to S1	20.36 degrees	20.31 degrees	21.14 degrees	21.6 degrees
Subluxation Modifier: Frontal of Sagittal Plane (Anterior or Posterior), Maximum Value	++ Frontal subluxation 16 mm (> 7 mm)	+Frontal subluxation 6 mm (1–6 mm)	++ Frontal subluxation 9.4 mm (> 7 mm)	+ Frontal subluxation 5.53 mm (1–6 mm)
Global Balance Modifier: Sagittal Offset from Posterior Superior Corner S1	Positive: 7.98 cm	Positive: 7.13 cm	Positive: 7.01 cm	Positive: 4.63 cm

2. Navigation System And Instruments

The O-arm/StealthStation system (Medtronic Inc., Minneapolis, MN, USA), a 3D real-time image-guided navigation system, is popular for its ability to provide automated registration with intraoperative, postpositioning computed tomography (CT). With SureTrak® II Universal Tracker (Medtronic Inc., Minneapolis, MN, USA) attached to the endoscope instrument, the depth and position of the endoscopic working channel could be observed in real-time fashion on the O-arm/StealthStation system monitor.

The Vertebris® Spine Endoscope systems (Richard and Wolf, Knittlingen, Germany) features high-resolution endoscope with a 6.9 × 5.6 mm diameter and a 4.1 mm intra-endoscopic working channel. The angle of vision is 25°. The working sleeve has an 8.0 mm outer diameter and a beveled opening, both of which enable visual and working fields creation in an area without a clear, anatomically preformed cavity.

Surgitron, a high-voltage bipolar probe (Ellman Innovations, New York, USA), is well-known for pinpoint coagulation in a wet field with simultaneously minimal burning or charring of soft tissue. The thermos-coagulation device aims to maximized hemorrhage control and thus improves the visibility of operative field.

3. Surgical Technique

3.1 Patient Preparation

The surgery is conducted under general anesthesia. The patient is positioned prone on a well cushioned and supportive radiolucent table with the abdomen hanging free. Bilateral knees are flexed to over 90 degrees as possible for the opening of interlaminar space. Back skin is then well prepared and draped.

3.2 Reference Pin Insertion and Image Acquisition

First, we make a small incision over the iliac crest. We insert the reference pin through the cannula, and use an impactor to nail the pin into the bone until the tap cap bottoms out on the cannula. Then we remove the tap cap and cannula from the pin, place the spine reference on the pin and rotate the assembly to lock the frame in place.

The spinal segment of interest is scanned using the O-arm navigation and the images are automatically registered to the Stealth Station. All the navigational instruments are registered.

3.3 3D Real-time Image-navigated Percutaneous Endoscopic Decompression

Interlaminar approach is chosen. The skin incision is made under O-arm navigation, which is under the spinal laminal junction. A dilator, 7.0 mm in outer diameter, is bluntly inserted to the edge of the interlaminar window. Then, an operative sleeve with a beveled opening is directed towards the ligamentum flavum. After attaching the SureTrak® II Universal Tracker to the Vertebris® Spine Endoscope (Fig. 3), we could insert the endoscope into the working channel (Fig. 3).

After introduction of the endoscope, the bony boundaries of superior lamina, inferior lamina and facet joint are identified and the soft tissues are removed with bipolar probe, punch and forceps. To broaden the working space, 3–4 mm of bone around superior and inferior lamina is removed with diamond burr. The depth and location of the bony landmark could be well visualized through the O-arm navigation system. The facet joint is carefully protected from damage with the aid of O-arm navigation system, which prevents the spinal column from instability. Not until the cranial, caudal, medial, and lateral border of the operative field are well prepared respectively should the ligamentum flavum being opened. A lateral window of approximately 4–6 mm is made on the ligamentum flavum. The neural structures and epidural fat tissues are exposed. The perineural membrane is dissected from the neural structure carefully under direct visualization. The operating sleeve with beveled opening could be turned and used as a nerve hook. With the joystick technique, the hypertrophic ligamentum flavum can be removed in either direction by controlling endoscope. Finally, epidural bleeding during is checked and well-controlled by Surgitron bipolar probe. The whole procedure is done safely and effectively under precise O-arm navigation (Fig. 4).

4. Outcome Evaluation

As the clinical outcome evaluation, the Oswestry Disability index (%) (ODI), Visual analogue scale (VAS) and image studies were documented at the initial visit and at 1 month, 6 months and 12 months post-operatively.

Results

Without unnecessary bone destruction, the spinal stenosis is successfully decompressed through endoscopic surgery. Intraoperative blood loss is minimal, which is less than 10 ml. The Hemovac drainage is removed on post-operative day 1, and both the endoscopic insertion wound and the reference pin insertion wound are about 8 mm-1cm (Fig. 5). All patients could stand and walk freely on a walker with less pain and numbness on postoperative day 1. The hospital stay is within 3 days. The efficacy of decompression is confirmed by MRI at 12 months follow-up post-operatively (Fig. 2). The follow-up X-ray performed at 12 months post-operatively showed no progress of the scoliosis (Fig. 1). As shown in Table 2, the mean ODI (%) are 85 (range 82.5–90) at initial visit, 35.875 (range 25–51) at 1 month post-operatively, 26.875 (range 22.5–35) at 6 months post-operatively and 22.5 (range 17.5–30) at 12 months post-operatively. The mean VAS score are 9 (range 8–10) at initial visit, 2.25 (range 2–3) at 1 month post-operatively, 1.75 (range 1–2) at 6 months post-operatively and 0.25 (range 0–1) at 12 months post-operatively. There is no surgery-related complication such as inadequate decompression, dural tear, iatrogenic neurological injury, uncontrolled epidural hemorrhage, unnecessary bone destruction with further instability.

Table 2
Patient Clinical Results

			Pre-OP		**Post-OP**					
	Diagnosis	Operation Level	ODI	VAS	ODI 1 Month	VAS 1 Month	ODI 6 Month	VAS 6 Month	ODI 12 Month	VAS 12 Month
Case 1	Kyphoscoliosis with Spinal Stenosis L3-L4	L3/L4	87.5	9	25	3	22.5	1	17.5	1
Case 2	Kyphoscoliosis with Spinal Stenosis L3/L4/L5	L4/L5	82.5	10	35	2	25	2	20	0
Case 3	Kyphoscoliosis with Spinal Stenosis L2/L3/L4	L2/L3/L4	90	9	51	2	25	2	22.5	0
Case 4	Kyphoscoliosis with Spinal Stenosis L3/L4	L3/L4	80	8	32.5	2	35	2	30	0

VAS Visual Analogue Scale, ODI Oswestry Disability index, Pre-OP Preoperative, Post-OP Postoperative

Discussion

To the best of our knowledge, this study is the first clinical study utilizing the technique of percutaneous endoscope with O-arm navigation to treat spinal stenosis with kyphoscoliosis patients. The advantages of this innovative technique are high precision with promising decompression effect, minimal invasive surgery with little soft tissue damage, and preservation of original spinal stability.

Recent studies have suggested that nonsurgical treatment may not be as effective.[14, 15] The current medical evidence continues to support the role of surgery over non-operative therapies for symptomatic stenosis patients associated with spondylolisthesis.[16] The prospective, randomized, multicenter Spine Patient Outcomes Research Trial (SPORT) also suggests that patients who are treated surgically present with a significantly greater improvement in pain, function, satisfaction, and self-rated progress over eight years compared to patients treated non-operatively.[17–19]

A recent systematic review and meta-analysis has demonstrated that in patients whose primary complain are radiculopathy with an underlying biomechanically stable spine, decompression surgery alone with a less invasive technique may be sufficient. Decompression with fusion does not appear to be more effective than decompression alone when considering pain relief, walking ability, or disability status.[20]

The gold standard method of the decompression of lumbar spinal stenosis is laminectomy with or without lateral recess and foraminal decompression. A laminectomy removes the entire lamina and the underlying ligamentum flavum, while a laminotomy removes only a small bone window from the lamina, unilaterally or bilaterally, which could be accomplished through minimally invasive surgery, such as percutaneous endoscope technique.[21, 22] Minimally invasive decompression plays an important role for geriatric patients. For patients with lumbar spinal stenosis, age alone should not prevent them from surgical intervention if otherwise indicated, because outcomes have been shown to be similar to those in the younger demographics.[23]

The original treatment plan for our patients was open surgery and correction of scoliosis with long fusion to sacrum (in order to avoid fusion above the apex of curve) with laminectomy and foraminal decompression. However, the adverse effect of long fusion brings certain early perioperative complications in old age patients with multiple comorbidities.[24] Therefore, decompression alone using percutaneous endoscope is a reasonable alternative. Decompression alone with laminectomy may lead to further instability. However, with accurate O-arm guided navigated decompression, unnecessary destruction with further instability could be successfully avoided. With this novel technique, we could overcome abnormal anatomical challenges and broaden the available stabilization options in the spinal surgery.[25, 26] Decompression alone in old patients with multiple comorbidities is difficult to achieve adequate decompression without unnecessary bony destruction causing instability. O-arm navigation provides a new option for this kind of patients (Table 1). With O-arm navigation, this technique could be applied in even more complicated cases, protect the surgical team from cumulative fluoroscopic radiation exposure particularly in the elderly or immunocompromised patients, as well as in patients with multiple comorbidities.[27]

The study has some limitations. Frist, there are limited number of patients and the lack of control group. Second, there is only short term follow-up, lacking long-term follow-up data. However, the purpose of this study is to emphasize the feasibility and safety of this novel method. Decompression alone using endoscope under O-arm navigation could be considered in patients with multiple comorbidities who could not endure major surgery and surgery-related hazardous complication. Additional clinical studies using this minimal invasive technique would be required to support our preliminary clinical results.

Conclusions

To the best of our knowledge, this is the first preliminary study of percutaneous endoscopic laminotomy under O-arm navigation with successful outcomes. Percutaneous endoscopic laminotomy under O-arm navigation is a minimal invasive procedure compared to open posterior surgery, such as decompression surgery plus fusion

surgery, with no unnecessary bone and soft tissue destruction, smaller cosmetic wound, shorter hospitalized duration, but similar treatment effects. We believe this novel technique is promising for spinal stenosis patients with lumbar kyphoscoliosis and multiple comorbidities.

Abbreviations

BMI: Body Mass Index; 3D: Three-Dimensional; AP: Anteroposterior; CT: Computed Tomography; MRI: Magnetic Resonance Imaging; T2WI: T2-Weighted Image; ODI: Oswestry Disability Index (%); VAS: Visual Analogue Scale

Declarations

Acknowledgments

None

Fundings

The authors received no specific funding for this work.

Availability of data and materials

The datasets used and analyzed during the current study are available from the corresponding author on reasonable request.

Authors ' contributions

HTC, YJC and CCC participated in the design of the study. CCC was responsible for performing the clinical procedures. TYH and CWL contributed to manuscript drafting. CWL, YSL and PHH contributed to data collection. CWL, CSL, PCC and HKT contributed to manuscript editing. All authors read and approved the final manuscript.

Ethics approval and consent to participate

This research did not increase the risk and economic burden of patients, the patients' rights were fully protected, and the project design was conducted in line with scientific and ethical principles. This study was approved by the Institutional Review Board (CMUH107-REC2-173). All participants in this study have provided informed written consent prior to enrollment.

Consent for publication

Not applicable

Competing interests

The authors declare that they have no competing interests.

Author details

[1]Department of Orthopedic Surgery, China Medical University Hospital, China Medical University, Taichung City, Taiwan (R.O.C.) [2]Department of Sports Medicine, College of Health Care, China Medical University, Taichung City,

Taiwan (R.O.C.) [3]Spine Center, China Medical University Hospital, China Medical University, Taichung City, Taiwan (R.O.C.) [4]Biological Science and Technology, National Chiao Tung University, Hsinchu City, Taiwan (R.O.C.) [5]Ph.D. Degree program of Biomedical Science and Engineering, National Chiao Tung University, Hsinchu City, Taiwan (R.O.C.) [6]Department of Orthopedic Surgery, School of Medicine, China Medical University, Taichung City, Taiwan (R.O.C.) [7]Section of Orthopaedic Surgery, Department of Surgery, Ministry of Health and Welfare, Changhua Hospital, Changhua County, Taiwan (R.O.C.) [8]Functional Neurosurgery Division, Neurological Institute, Taichung Veterans General Hospital, Taichung City, Taiwan (R.O.C.) [9]Department of Rehabilitation, Jen-Teh Junior College of Medicine, Nursing and Management, Miaoli County, Taiwan (R.O.C.)

References

1. Weinstein JN, Tosteson TD, Lurie JD, Tosteson AN, Blood E, Hanscom B, Herkowitz H, Cammisa F, Albert T, Boden SD *et al*: **Surgical versus nonsurgical therapy for lumbar spinal stenosis**. *The New England journal of medicine* 2008, **358**(8):794-810.
2. Davis N, Hourigan P, Clarke A: **Transforaminal epidural steroid injection in lumbar spinal stenosis: an observational study with two-year follow-up**. *British journal of neurosurgery* 2017, **31**(2):205-208.
3. Peul WC, van Houwelingen HC, van den Hout WB, Brand R, Eekhof JA, Tans JT, Thomeer RT, Koes BW, Leiden-The Hague Spine Intervention Prognostic Study G: **Surgery versus prolonged conservative treatment for sciatica**. *The New England journal of medicine* 2007, **356**(22):2245-2256.
4. Weinstein JN, Lurie JD, Tosteson TD, Hanscom B, Tosteson ANA, Blood EA, Birkmeyer NJO, Hilibrand AS, Herkowitz H, Cammisa FP *et al*: **Surgical versus Nonsurgical Treatment for Lumbar Degenerative Spondylolisthesis**. *New England Journal of Medicine* 2007, **356**(22):2257-2270.
5. Ahmad S, Hamad A, Bhalla A, Turner S, Balain B, Jaffray D: **The outcome of decompression alone for lumbar spinal stenosis with degenerative spondylolisthesis**. *Eur Spine J* 2017, **26**(2):414-419.
6. Austevoll IM, Gjestad R, Brox JI, Solberg TK, Storheim K, Rekeland F, Hermansen E, Indrekvam K, Hellum C: **The effectiveness of decompression alone compared with additional fusion for lumbar spinal stenosis with degenerative spondylolisthesis: a pragmatic comparative non-inferiority observational study from the Norwegian Registry for Spine Surgery**. *Eur Spine J* 2017, **26**(2):404-413.
7. Chang W, Yuwen P, Zhu Y, Wei N, Feng C, Zhang Y, Chen W: **Effectiveness of decompression alone versus decompression plus fusion for lumbar spinal stenosis: a systematic review and meta-analysis**. *Arch Orthop Trauma Surg* 2017, **137**(5):637-650.
8. Ghogawala Z, Dziura J, Butler WE, Dai F, Terrin N, Magge SN, Coumans JV, Harrington JF, Amin-Hanjani S, Schwartz JS *et al*: **Laminectomy plus Fusion versus Laminectomy Alone for Lumbar Spondylolisthesis**. *N Engl J Med* 2016, **374**(15):1424-1434.
9. Forsth P, Olafsson G, Carlsson T, Frost A, Borgstrom F, Fritzell P, Ohagen P, Michaelsson K, Sanden B: **A Randomized, Controlled Trial of Fusion Surgery for Lumbar Spinal Stenosis**. *N Engl J Med* 2016, **374**(15):1413-1423.
10. Li X, Han Y, Di Z, Cui J, Pan J, Yang M, Sun G, Tan J, Li L: **Percutaneous endoscopic lumbar discectomy for lumbar disc herniation**. *Journal of clinical neuroscience : official journal of the Neurosurgical Society of Australasia* 2016, **33**:19-27.
11. Lin CW, Chang CC, Chen HT, Chen YJ, Lin CS, Hsu HC, Tsou HK: **3D Real-Time Image-Guided Navigation Spine Corpectomy with Ultrasonic Bone Cutter: Technical Note**. *World neurosurgery* 2020, **135**:197-204.

12. Baaj AA, Beckman J, Smith DA: **O-Arm-based image guidance in minimally invasive spine surgery: technical note**. *Clin Neurol Neurosurg* 2013, **115**(3):342-345.
13. Terran J, Schwab F, Shaffrey CI, Smith JS, Devos P, Ames CP, Fu KM, Burton D, Hostin R, Klineberg E *et al*: **The SRS-Schwab adult spinal deformity classification: assessment and clinical correlations based on a prospective operative and nonoperative cohort**. *Neurosurgery* 2013, **73**(4):559-568.
14. Ammendolia C, Stuber K, de Bruin LK, Furlan AD, Kennedy CA, Rampersaud YR, Steenstra IA, Pennick V: **Nonoperative treatment of lumbar spinal stenosis with neurogenic claudication: a systematic review**. *Spine* 2012, **37**(10):E609-616.
15. Friedly JL, Comstock BA, Turner JA, Heagerty PJ, Deyo RA, Sullivan SD, Bauer Z, Bresnahan BW, Avins AL, Nedeljkovic SS *et al*: **A randomized trial of epidural glucocorticoid injections for spinal stenosis**. *The New England journal of medicine* 2014, **371**(1):11-21.
16. Resnick DK, Watters WC, 3rd, Sharan A, Mummaneni PV, Dailey AT, Wang JC, Choudhri TF, Eck J, Ghogawala Z, Groff MW *et al*: **Guideline update for the performance of fusion procedures for degenerative disease of the lumbar spine. Part 9: lumbar fusion for stenosis with spondylolisthesis**. *Journal of neurosurgery Spine* 2014, **21**(1):54-61.
17. Lurie JD, Tosteson TD, Tosteson A, Abdu WA, Zhao W, Morgan TS, Weinstein JN: **Long-term outcomes of lumbar spinal stenosis: eight-year results of the Spine Patient Outcomes Research Trial (SPORT)**. *Spine* 2015, **40**(2):63-76.
18. Pearson A, Blood E, Lurie J, Abdu W, Sengupta D, Frymoyer JW, Weinstein J: **Predominant leg pain is associated with better surgical outcomes in degenerative spondylolisthesis and spinal stenosis: results from the Spine Patient Outcomes Research Trial (SPORT)**. *Spine* 2011, **36**(3):219-229.
19. Pearson A, Blood E, Lurie J, Tosteson T, Abdu WA, Hillibrand A, Bridwell K, Weinstein J: **Degenerative spondylolisthesis versus spinal stenosis: does a slip matter? Comparison of baseline characteristics and outcomes (SPORT)**. *Spine* 2010, **35**(3):298-305.
20. Omidi-Kashani F, Hasankhani EG, Ashjazadeh A: **Lumbar spinal stenosis: who should be fused? An updated review**. *Asian spine journal* 2014, **8**(4):521-530.
21. Alimi M, Hofstetter CP, Pyo SY, Paulo D, Hartl R: **Minimally invasive laminectomy for lumbar spinal stenosis in patients with and without preoperative spondylolisthesis: clinical outcome and reoperation rates**. *Journal of neurosurgery Spine* 2015, **22**(4):339-352.
22. Nerland US, Jakola AS, Solheim O, Weber C, Rao V, Lonne G, Solberg TK, Salvesen O, Carlsen SM, Nygaard OP *et al*: **Minimally invasive decompression versus open laminectomy for central stenosis of the lumbar spine: pragmatic comparative effectiveness study**. *Bmj* 2015, **350**:h1603.
23. Aleem IS, Rampersaud YR: **Elderly patients have similar outcomes compared to younger patients after minimally invasive surgery for spinal stenosis**. *Clinical orthopaedics and related research* 2014, **472**(6):1824-1830.
24. Cho KJ, Suk SI, Park SR, Kim JH, Kim SS, Lee TJ, Lee JJ, Lee JM: **Short fusion versus long fusion for degenerative lumbar scoliosis**. *European spine journal : official publication of the European Spine Society, the European Spinal Deformity Society, and the European Section of the Cervical Spine Research Society* 2008, **17**(5):650-656.
25. Schouten R, Lee R, Boyd M, Paquette S, Dvorak M, Kwon BK, Fisher C, Street J: **Intra-operative cone-beam CT (O-arm) and stereotactic navigation in acute spinal trauma surgery**. *Journal of clinical neuroscience : official journal of the Neurosurgical Society of Australasia* 2012, **19**(8):1137-1143.

26. Ammirati M, Salma A: **Placement of thoracolumbar pedicle screws using O-arm-based navigation: technical note on controlling the operational accuracy of the navigation system**. *Neurosurgical review* 2013, **36**(1):157-162; discussion 162.
27. Li X, Zhang F, Zhang W, Shang X, Han J, Liu P: **A new method to precisely control the depth of percutaneous screws into the pedicle by counting the rotation number of the screw with low radiation exposure: technical note**. *European spine journal : official publication of the European Spine Society, the European Spinal Deformity Society, and the European Section of the Cervical Spine Research Society* 2017, **26**(3):750-753.

Figures

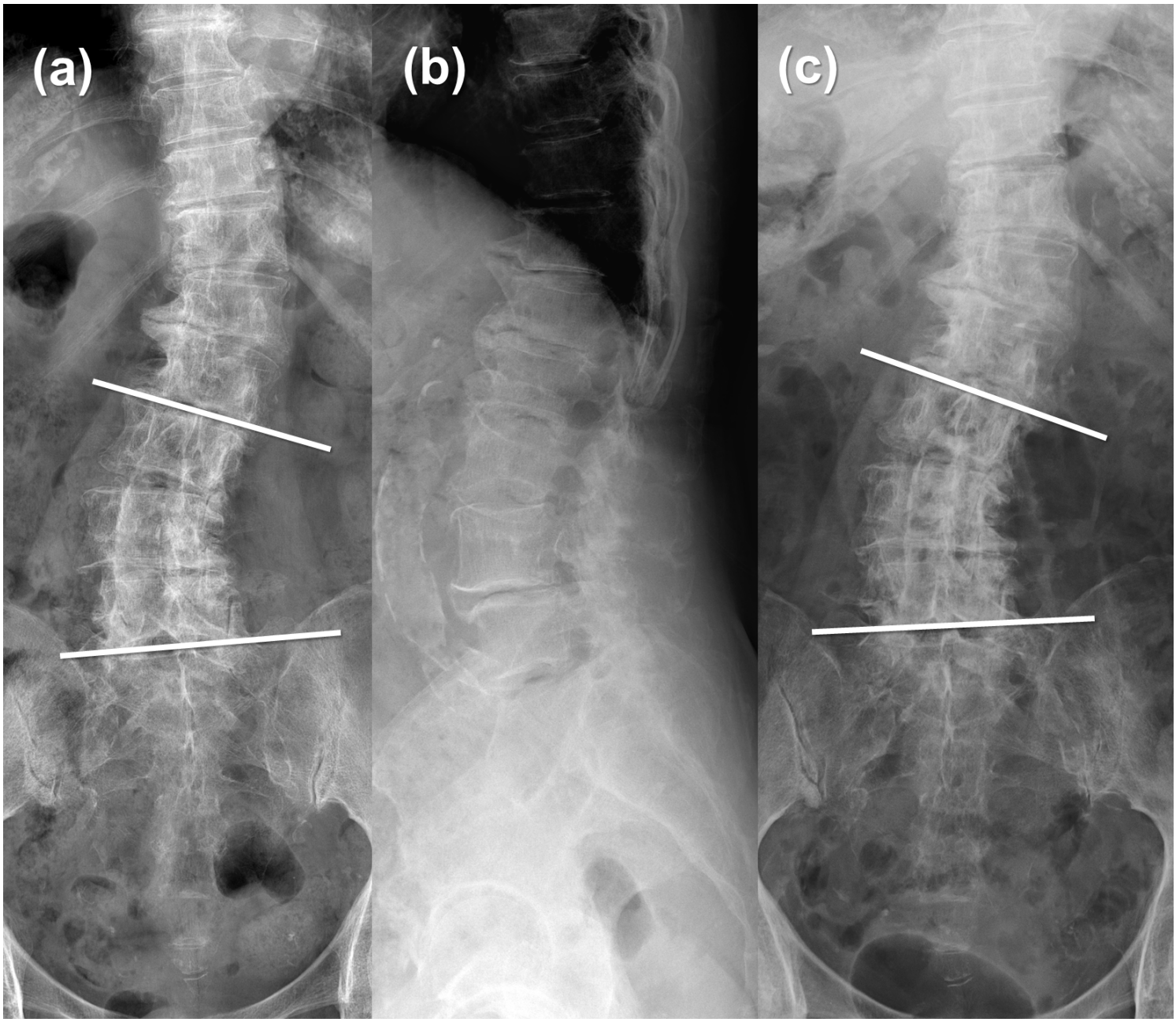

Figure 1

(a) Preoperative AP X-ray shows 21.85° Cobb angle scoliosis from L3-L5. (b) Preoperative lateral X-ray reveals mild spondylolisthesis over L4-L5. (c) Postoperative AP X-ray shows 21.84° Cobb angle scoliosis from L3-L5. (a)(c) Serial images demonstrate no progression of the scoliosis.

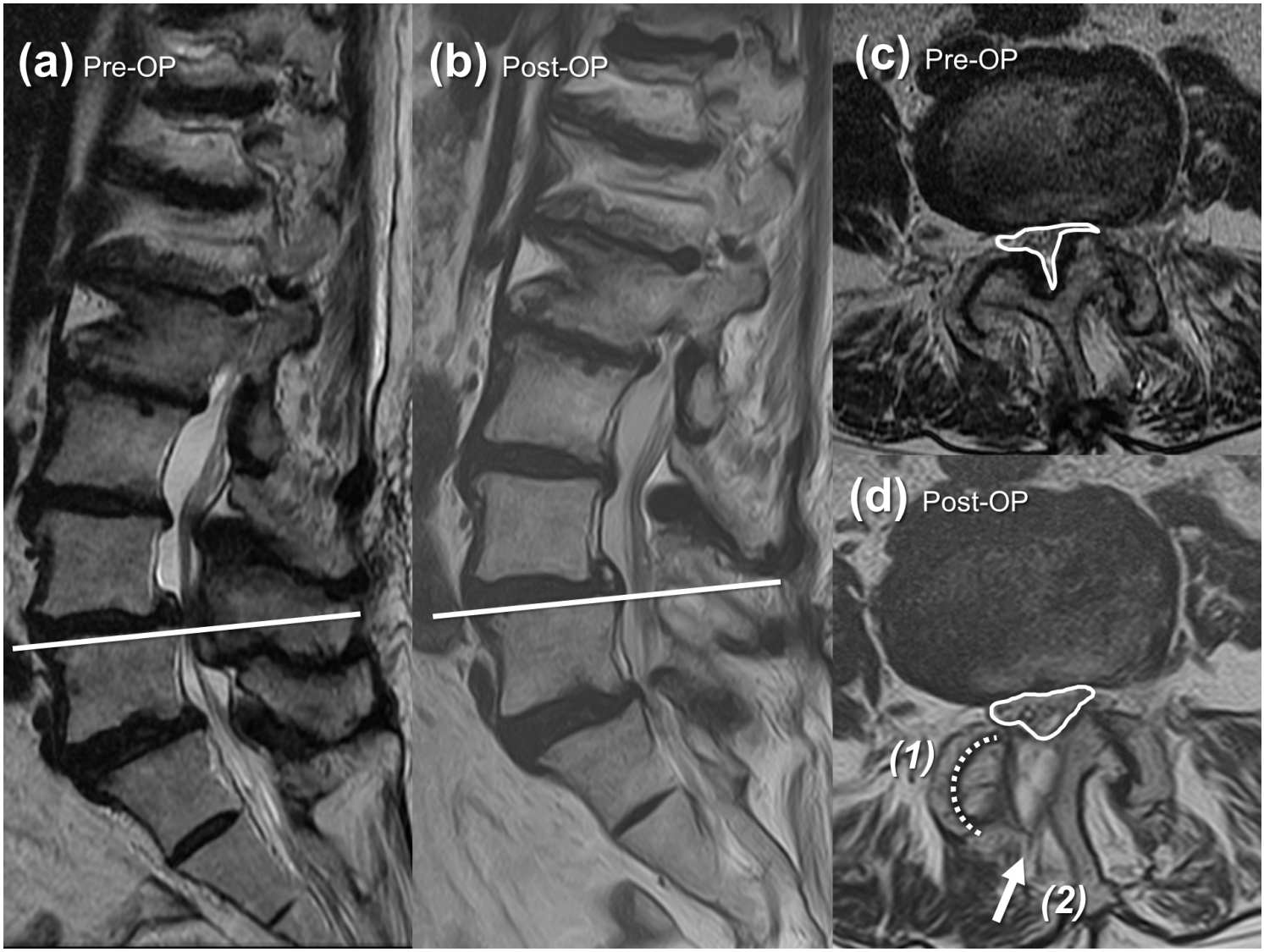

Figure 2

(a) Preoperative sagittal section of T2WI MRI shows severe stenosis over L4-L5. (b) Postoperative sagittal section of T2WI MRI shows stenosis being relieved with intact posterior elements. The decompression level (White line) on axial section of T2WI MRI is shown in (c) and (d). Comparing (c) preoperative and (d) postoperative T2WI axial section MRI, dura sac cross-sectional area increases significantly after endoscopic laminotomy at L4-5 under O-arm navigation (1) without any facet joints damage, via (2) interlaminar approach.

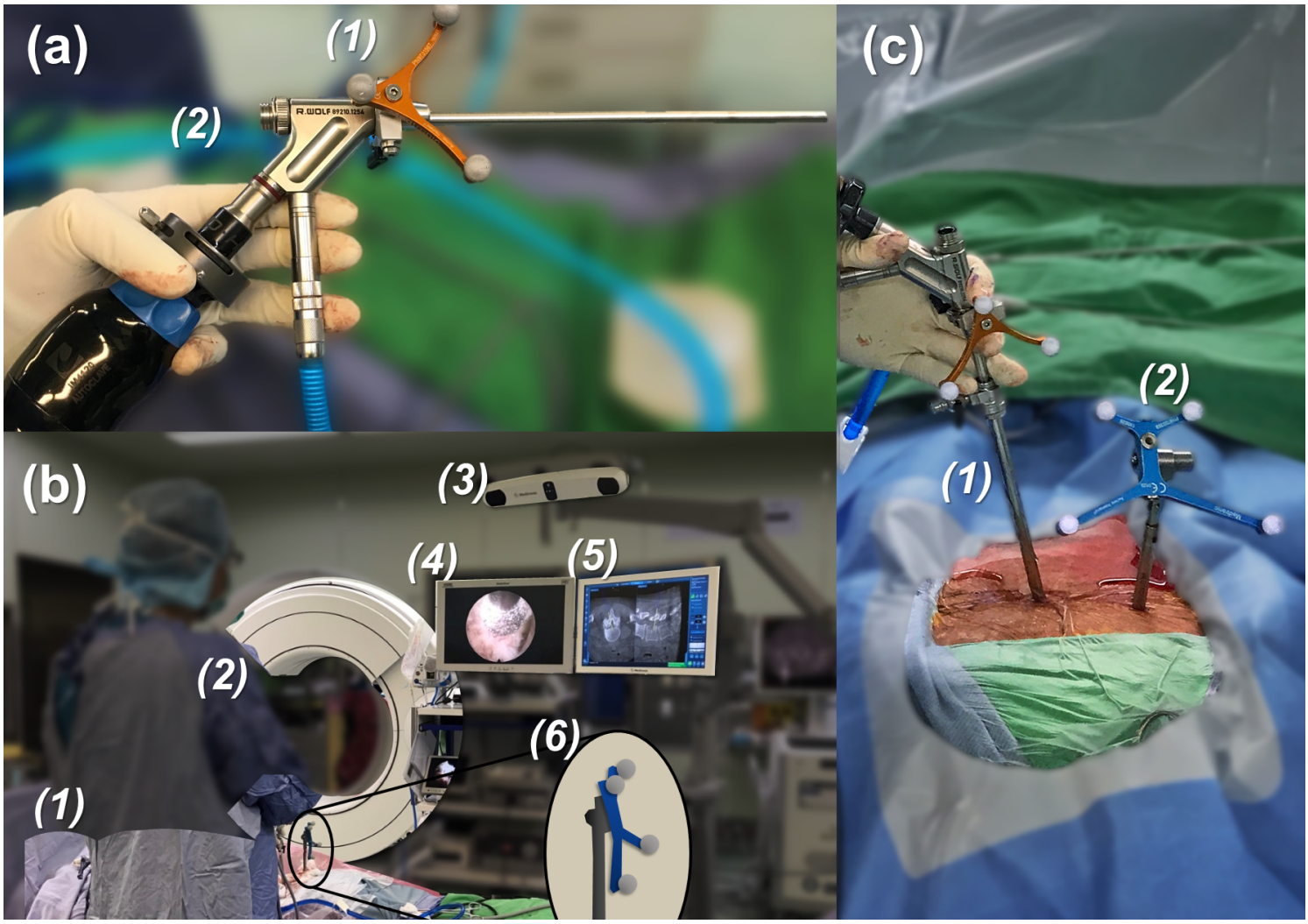

Figure 3

(a) Intraoperative photo shows the attachment of (1) SureTrak® II Universal Tracker, Small Passive Fighter to the (2) Vertebris® Spine Endoscope. (b) Photos reveals the setting of surgery, including (1) patient positioning, (2)(3) O-arm setting, (4) endoscope monitoring, (5) navigation monitoring and (6) reference pin position. (c) Photo shows the relative position of (1) the endoscope in the sleeve, and (2) the percutaneous reference pin (in the area over the iliac crest).

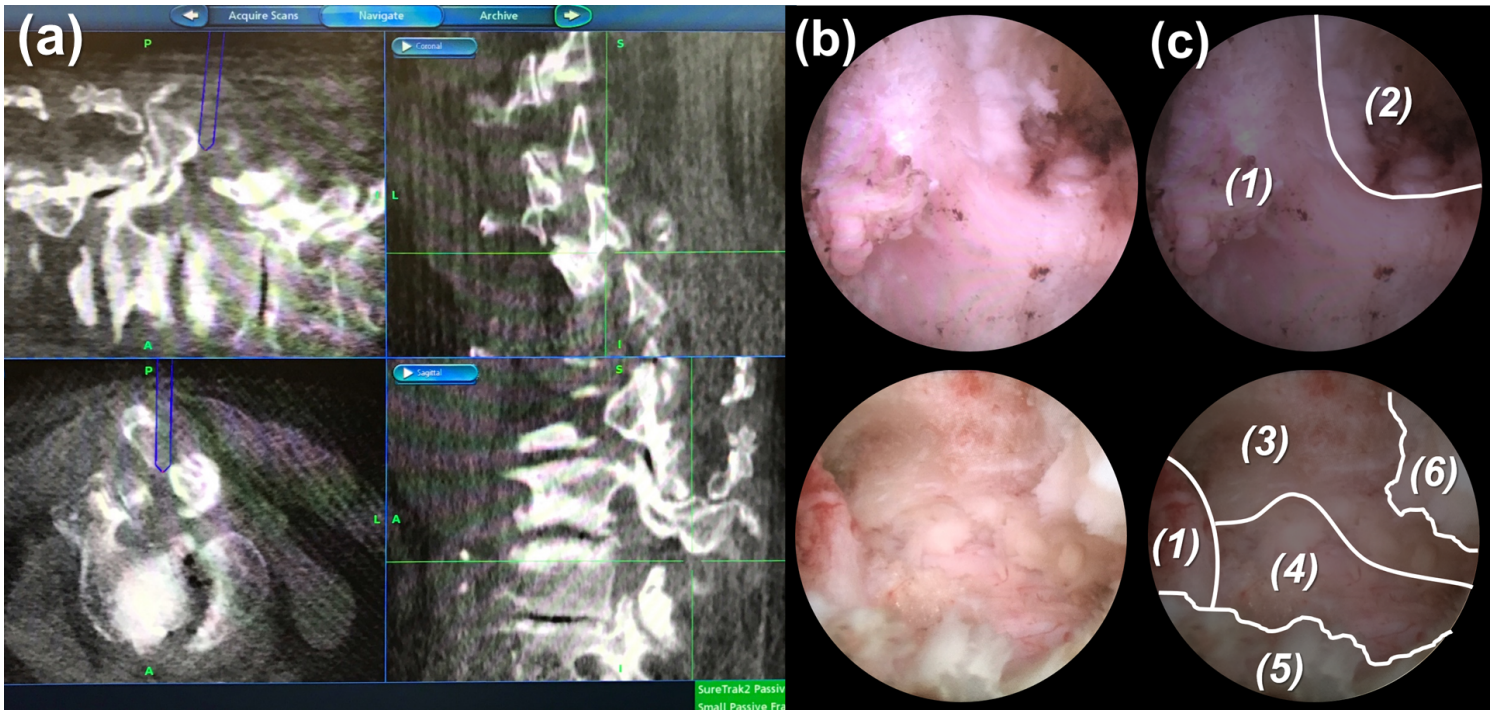

Figure 4

Surgeon performs endoscopic laminotomy under precise O-arm navigation. Intraoperative photos show (a) O-arm navigation images (b) Endoscopic images and (c) its introduction: (1) base of spinous process, (2) interlaminar space, (3) right side lateral recess, (4) dura, (5) left side lateral recess, (6) ligamentum flavum.

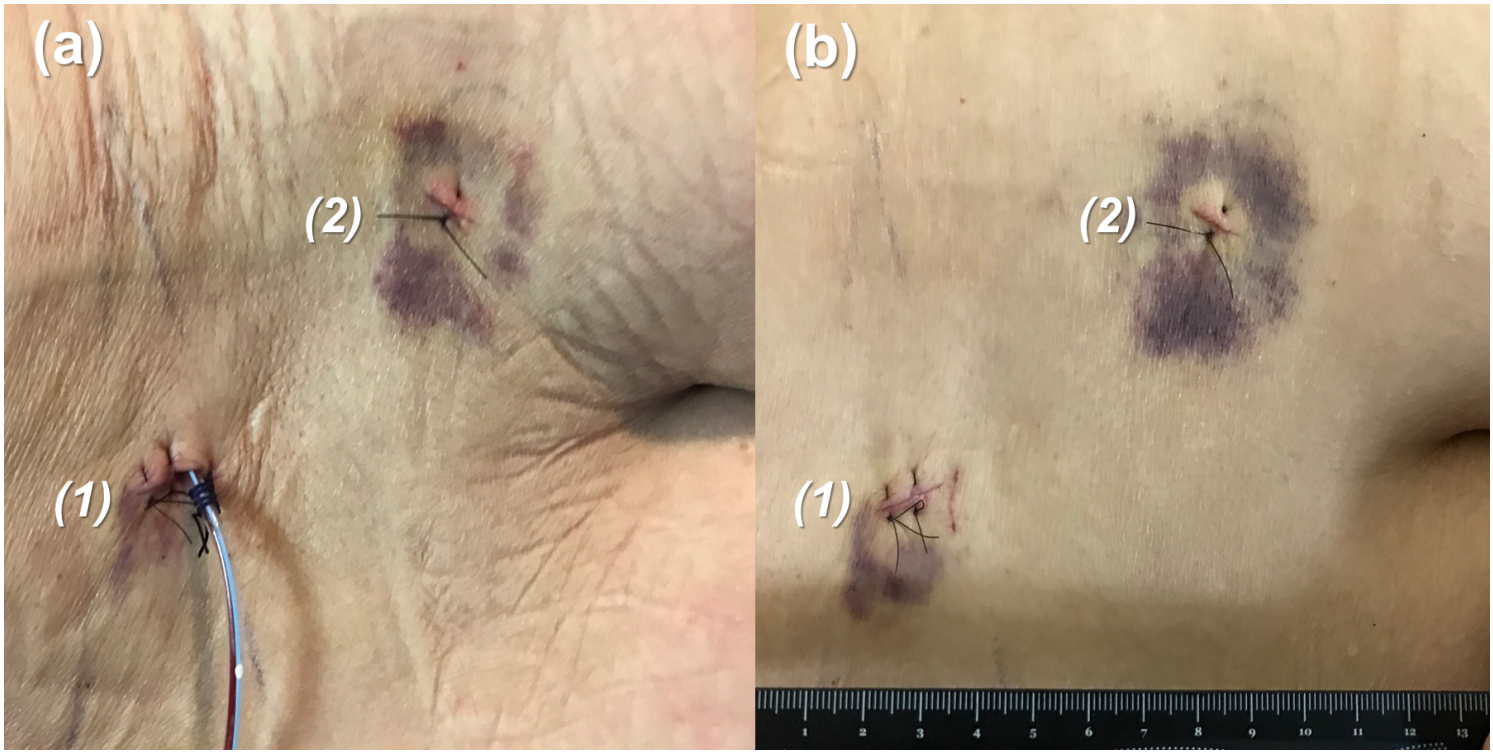

Figure 5

(a) Photos of surgical wounds on postoperative day 1 shows a Hemovac drainage in the endoscope insertion wound; (b) both (1) the endoscope insertion wound and (2) the percutaneous reference pin insertion wound are

about 1cm.

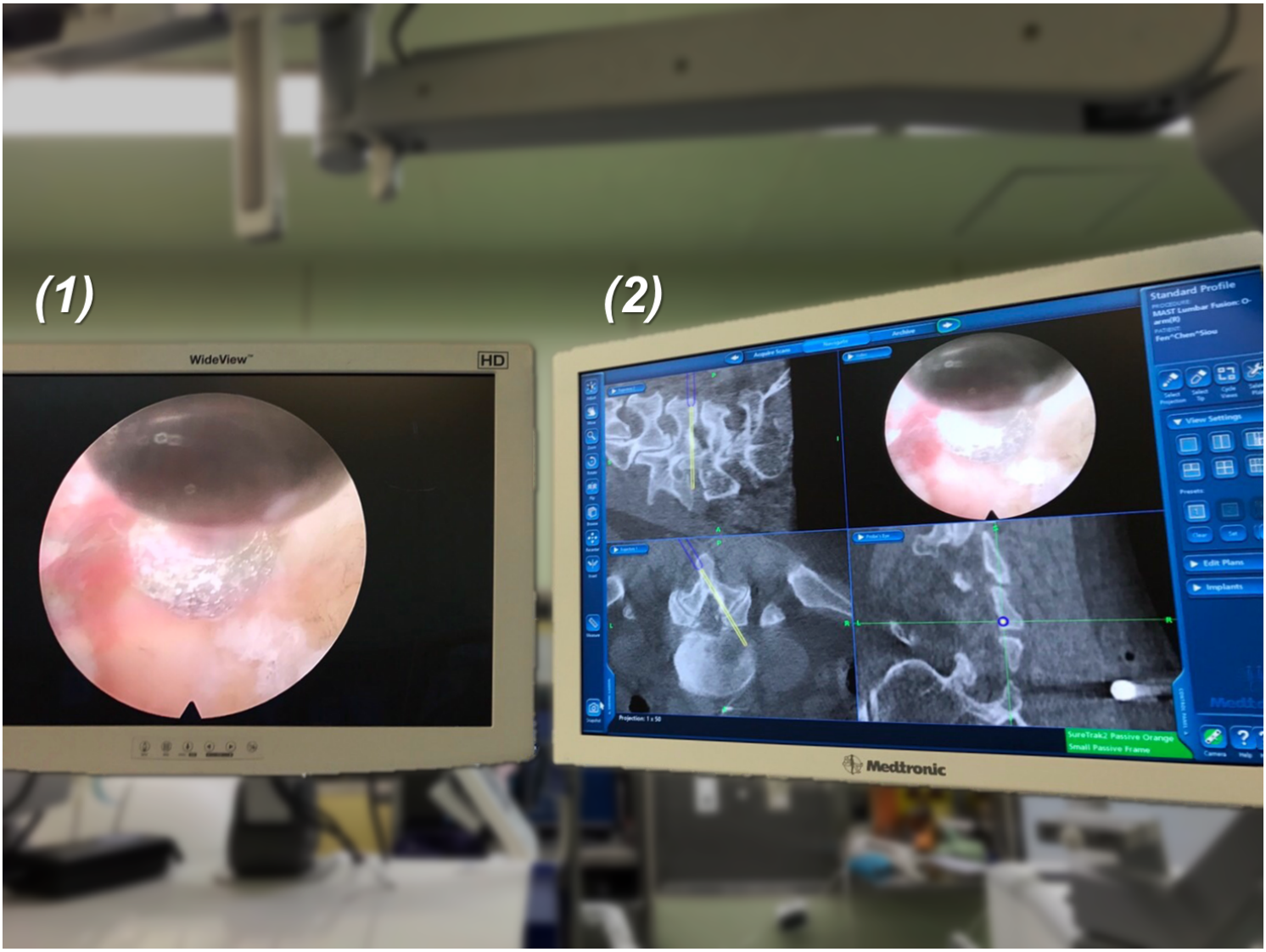

Figure 6

Combining (1) Endoscopic images and (2) O-arm navigation images, the trajectory of the burr is navigated. The depth of burr could be adjusted precisely during laminotomy under 3D real-time O-arm navigation.