The concept of a cementless isoelastic monoblock cup made of highly cross-linked polyethylene infused with vitamin E: Clinical outcome and radiological analyses of migration and wear using EBRA at mid-term follow-up

Yama Afghanyar (yafghanyar@joho.de)
St. Josefs Hospital Wiesbaden

Sebastian Joser
St. Josefs Hospital Wiesbaden

Jonas Tecle
St. Josefs Hospital Wiesbaden

Philipp Drees
Johannes Gutenberg Universitat Mainz

Jens Dargel
St. Josefs Hospital Wiesbaden

Philipp Rehbein
St. Josefs Hospital Wiesbaden

Karl Philipp Kutzner
St. Josefs Hospital Wiesbaden

Research article

Keywords: Total hip arthroplasty, cementless acetabular cup, vitamys, EBRA, migration, wear

Posted Date: April 10th, 2020

DOI: https://doi.org/10.21203/rs.3.rs-20410/v1

Version of Record: A version of this preprint was published on January 23rd, 2021. See the published version at https://doi.org/10.1186/s12891-021-03981-8.

Abstract

Background

The newest generation of cementless titanium coated, isoelastic monoblock cup with vitamin E-blended highly cross-linked polyethylene (HXLPE) has been introduced to the market in 2009. Aim of the present study was to obtain mid-term data including the analyses of migration and wear.

Methods

The present prospective study investigated 101 primary total hip arthroplasty (THA) cases in 96 patients at a single institution. Patients were allowed full weight-bearing on the first day postoperatively. Harris hip score (HHS) as well as pain and satisfication on visual analogue scale (VAS) were assessed during a mean follow-up of 79.0 months. Migration and wear were assessed using Einzel-Bild-Roentgen-Analyse (EBRA) software. Additionally, radiological alterations in the acetabular bone and complications were documented.

Results

At mid-term follow-up (mean 79.0 months (range: 51.8 – 101.7)), HHS was 91.1 (range 38.0 – 100.0), satisfaction on VAS was 9.6 (range 6.0 – 10.0), rest pain on VAS was 0.2 (range 0.0 – 4.0), and load pain on VAS was 0.6 (range 0.0 – 9.0). Mean migration was 0.86 mm (range: 0.0 – 2.56) after 24 months and 1.34 mm (range: 0.09 – 3.14) after 5 years. Mean annual migration rate was 0.22 (range: -0.24 – 1.34) at 5 years. Mean total wear was 0.4 mm (range: 0.03 – 1.0) at 5 years. The mean annual wear rate was 0.06 mm per year (range: 0.0 – 0.17). Radiographic analysis showed osteolysis in none of the cases and no revision surgeries had to be performed.

Conclusion

The concept of vitamin-E blended HXLPE in cementless isoelastic monoblock cups prevents osteolysis, aseptic loosening and the need of revision surgery at mid-term. Values for cup migration and wear stay well below the benchmarks which are considered predictive for potential future failure.

Background

Total Hip Arthroplasty (THA) is one of the most frequent operations worldwide [1]. The most challenging requirement in THA is a long implant survival. Aseptic loosening of the components is one of the most prevalent causes for revision surgery [2, 3]. In the last decades, a substantial effort has been made to avoid or prolong aseptic loosening and mechanical failure of the implants, and this will remain a major challenge in the future [4–7].

The concept of a cementless monoblock cup was initially introduced in 1983 [4, 8] with the RM Classic cup (Mathys Ltd., Bettlach, Switzerland) (Fig. 1a). It was made of ultra-high-molecular-weight

polyethylene (UHMWPE) coated by titanium. In contrast to modular cementless acetabular components, which are composed of a titanium shell and a separate inlay in various shapes and materials, in the monoblock design titanium particles are bonded directly to the polyethylene. Therefore it avoids the potential problem of backside wear reported with modular designs. The thin titanium coating in itself conveys no structural stiffness which allows the cup to remain isoelastic compared to bone, potentially preventing stress-shielding and bone resorption. In addition to the titanium coating for primary bone fixation, two pegs provided rotational stability [9]. 20 years follow-up revealed a survival rate of 94.4% for aseptic loosening as endpoint [4]. However, despite the excellent survival rate, excentric wear and osteolysis were the main reasons for the need of revision surgery, mostly between 14 and 16 years after implantation [4, 8]. For patients with congenital dysplasia, the cup survival rate after 20 years was 100% [4].

The second generation was introduced in 2002 and called RM Pressfit cup (Fig. 1b). It was also made of UHMWPE but has been modified by removing the 2 pegs. However, in the long-term, the lifetime of both generations of monoblock cups was limited by wear and oxidative degeneration of the UHMWPE [4, 10].

The RM Pressfit vitamys cup, being the third generation of the monoblock concept, has been introduced to the market in 2009 (Fig. 1c). To improve the properties, a new generation of highly cross-linked polyethylene has been developed, which is protected from oxidation by the antioxidant vitamin E [11–13]. This new generation of polythylene promises significantly lower wear rates [2, 11–14]. However, previous studies have also shown that vitamin E-stabilized HXLPE has similar wear properties to HXLPE without vitamin E, but has improved fatigue strength and is protected from oxidative destruction [11, 15–18].

Regarding the development of osteolysis, which is known to be induced by wear of the PE and potentially causes loosening and implant failure, Dumbleton et al. defined a threshold of 0.1 mm per year, below which osteolysis is rarely observed [19].

Another major indicator for late aseptic loosening is the early migration of the cup. Several studies, using “Einzel-Bild-Roentgen-Analyse” (EBRA) [20] measurements, reported an implant migration of > 2 mm during the first 2 years being an established risk factor for implant failure, by interfering osteointegration [6, 21–25].

The primary aim of this study was to analyse clinical and radiological outcome of the newest generation monoblock vitamin E-blended HXLPE cup in a mid-term follow-up. Particularly, the migration pattern and wear was analyzed in order to identify potentially undesireable results at an early stage.

Methods

The present prospective study investigated 101 primary THA cases in 96 patients at a single institution between March 2010 and September 2011. All procedures performed were in accordance with the 1964 Helsinki Declaration. Ethical approval was obtained (FF 154/2017). All patients gave their verbal and written permission to participate prior to inclusion.

The inclusion criteria were age between 20 and 85 years and being a candidate for primary THA. The foremost diagnosis was primary osteoarthrosis with 93.1% (n = 94). Other indications were 3% (n = 3) femoral head necrosis, 2% (n = 2) secondary osteoarthrosis, 1% (n = 1) fracture and 1% (n = 1) congenital dysplasia. Surgery was performed in 63 women and 38 men with a median age of 70.6 years (range: 50–84). Five patients were treated bilateral simultanously. The mean body mass index was 27.5 kg/m² (range: 19.3–41.5 kg /m²) (Table 1).

Table 1
– Patient demographics

	Female **Mean (range)**	**Male** **Mean (range)**	**Total** **Mean (range)**
Number of hips, n	63	38	101
Age, years	70.3 (50.7–84.0)	67.9 (51.0–84.3)	69.4 (50.7–84.3)
BMI, kg/m²	27.3 (19.3–39.1)	27.9 (20.2–41.5)	27.5 (19.3–41.5)
Diagnosis, n (%) Primary osteoarthrosis Secondary osteoarthrosis Femoral head necrosis Femoral neck fracture Congenital dysplasia			94 (93.1%) 2 (2.0%) 3 (3.0%) 1 (1.0%) 1 (1.0%)

In all cases, the RM Pressfit vitamys cup (Mathys Ltd., Bettlach, Switzerland) was used (Fig. 1c). The body of the cup is made of highly-crosslinked UHMW-PE (HXLPE) stabilized with vitamin E [5, 11, 18]. The titanium coating was developed to maintain the natural elastic properties of isoelastic polyethylene and to promote secondary stability [8, 11, 18]. Primary stability is achieved by equatorial pressfit. Optionally, up to four screws can be inserted into predefined holes in case of insufficient acetabular coverage or in soft or sclerotic bone. The RM Pressfit vitamys cup was combined with different kinds of femoral components (Nanos, Smith&Nephew (33.7%); twinSys, Mathys (27.7%); optimys, Mathys (17.8%); Metha, B.Braun/Aesculap (12.8%); Mayo, Zimmer (3.0%); Marathon, Smith&Nephew (3.0%); ProxyPlus, Smith&Nephew (2.0%)) and a 28 mm ceramic head in all cases.

All surgeries were performed using a minimally invasive, antero-lateral approach in standardized surgical technique [26]. The operations were performed by experienced consultant surgeons and the mean duration of surgery was 56.4 minutes (range 30.0–93.0). All patients started physiotherapy and were allowed full weight-bearing ambulation on the first day postoperatively.

The clinical and radiological follow-up included a maximum of 6 timepoints: preoperative, 6 weeks, 6 months, 12 months, 2 years and 5 years.

Complications and adverse events during surgery and during the follow-up were documented.

For clinical examination, the Harris Hip Score (HHS) as well as rest pain and load pain on visual analogue scales (VAS) were evaluated before surgery and during follow-up. HHS serves to assess the functional result of the treatment [27]. The outcome was considered excellent if the HHS was between 90 and 100, good if between 80–89, average if between 70 and 79, and poor if lower than 70 [27, 28].

The radiological evaluation of osseointegration and migration of the cup was carried out on standardized anterior-posterior radiographs of the pelvis. Lucent lines and osteolysis were analyzed according to Engh et al. [29] defined in the zones described by DeLee and Charnley [30] (Fig. 2a). Heterotopic ossifications were documented according to Brooker [31].

At mid-term follow-up, a retrospective evaluation of the radiographs using “Einzel-Bild-Roentgen-Analyse” (EBRA) was performed by one observer in order to analyse the migration pattern and detect potential wear of the polyethylene. The methology, using a software, was originally developed by Krismer et al. [20]. Basically, migration is being investigated in two orientations: horizontally (x-axis = cupx) and vertically (y-axis = cupy). Decreasing values in the horizontal direction imply medial migration, whereas increasing values in the horizontal direction imply lateral migration. In turn, increasing values in y-direction refer migration in cranial or proximal direction, hence in upward direction and decreasing y-values signify distal movement. The overall accuracy of EBRA is validated to be within 1 mm [21]. Radiographs are only accepted by the EBRA software if all reference lines can be located accurately. Loosening was defined as total migration increase of 0.5 mm per year [32, 33]. Total cup migration was claculated as the vector summation of x and y-axis migration by the following formula using Pythagoras law:

$$\text{cupT} = \sqrt{cupx^2 + cupy^2}.$$

Besides migration, wear rate was calculated using pelvic radiographs and EBRA software. A frame drawn from tangents to prominent pelvic structures defined the position of the pelvis. From the digitized points, the software calculated the best-fit circle for the femoral head or the best fitting ellipse for the contrast wire and the distances from each digitized coordinate of the implant [34]. The displacement of the head center was calculated relative to the cup center in the frontal plane (transverse and longitudinal axis) and the wear rate for each subgroup was calculated in each time interval between radiographic examinations [34].

Statistical analysis

Data were described by mean (range). For the comparison of HHS and pain scores on VAS preoperative vs. 5 years a Wilcoxon signed-rank test (2-sided) for paired data was used. A p value < 0.05 was considered as indication for difference. All statistical analyses were performed using SAS Enterprise Guide 7.13 (SAS Institute Inc., Cary, USA).

Results

After 5 years, 12 patients are known to be deceased with the investigated implants in situ. At mid-term, 4 cases were lost to follow-up. In 4 cases only a clinical follow-up could be obtained. Thus, 81 cases with complete clinical and radiological data could be analyzed (Fig. 3). The mean follow-up time was 79.0 months (range: 51.8–101.7).

None of the patients required a cup related revision because of aseptic loosening, nor for mechanical failure or any other reason after 5 years.

Intraoperatively two (2%) fissures of the femur were observed. Both of them healed uneventfully after cerclage wiring. 99 patients (98%) did not show intraoperative complications. During the early postoperative period, there were four hematomas, one femoral nerve palsy and one superficial infection which was treated successfully by antibiotic therapy. During follow-up, in 2 patients a periprosthetic fractures of the femoral component occurred, due to trauma, without any involvement of the acetabular component. No cup specific complications were observed.

The mean range of motion increased from a preoperative value of 92° flexion (range: 50–120) to 114° (range: 85–130). The clinical outcome is shown in Table 2.

Table 2
Clincal outcome over time

FU	Mean	SD	Min	Median	Max
VAS rest pain (pts)	5.0	3.3	0.0	5.0	10.0
Pre-OP	1.1	1.0	0.0	1.0	3.0
6–12 weeks	0.2	0.3	0.0	0.1	0.7
6 months	0.5	1.2	0.0	0.0	8.0
12 months	0.1	0.3	0.0	0.0	2.0
24 months	0.2	0.7	0.0	0.0	4.0
5 years					
VAS load pain (pts)	7.7	2.2	1.0	8.0	10.0
Pre-OP	1.5	1.4	0.0	1.0	4.0
6–12 weeks	0.6	0.6	0.0	0.8	1.4
6 months	1.1	1.7	0.0	0.0	8.0
12 months	0.3	0.5	0.0	0.0	2.0
24 months	0.6	1.7	0.0	0.0	9.0
5 years					
VAS satisfaction (pts)	1.7	2.0	0.0	1.0	8.0
Pre-OP	8.8	0.8	7.3	9.0	10.0
6–12 weeks	9.5	0.5	9.0	9.4	10.0
6 months	9.2	1.4	2.0	10.0	10.0
12 months	9.7	0.5	8.0	10.0	10.0
24 months	9.6	0.9	6.0	10.0	10.0
5 years					
Harris Hip Score (pts)	49.9	15.0	9.0	52.0	95.0
Pre-OP	83.1	10.4	64.0	85.0	99.0
6–12 weeks	91.8	4.0	86.0	91.0	96.0
6 months	91.1	11.6	45.0	96.0	100.0
12 months	95.2	5.6	75.0	97.0	100.0
24 months	94.0	9.9	38.0	97.0	100.0
5 years					
Flexion (°)	92.4	12.1	50.0	90.0	120.0
Pre-OP	101.0	13.8	65.0	100.0	130.0
6–12 weeks	109.0	13.9	85.0	115.0	120.0
6 months	116.3	12.0	85.0	120.0	130.0
12 months	120.2	9.4	95.0	120.0	130.0
24 months	113.7	10.9	85.0	115.0	130.0
5 years					

Before surgery, the HHS was rated with an average of 49.9 points (range: 9.0–95.0). At mid-term follow-up, the mean HHS was 94.0 points (range: 38.0–100).

Mean rest pain on VAS decreased from preoperatively 5.0 (range: 0–10) to 0.2 at mid-term and mean load pain on VAS decreased from preoperatively 7.7 (range: 1.0–10.0) to 0.6 (range: 0.7–9.0). Satisfaction on VAS increased from 1.7 (range: 0.0–8.0) to 9.5 (range: 0.9–10.0) after 5 years.

The radiographic results at mid-term follow-up are presented in Table 3.

Table 3
Radiological outcome over time

	5 years Frequency (n)	Percent (%)
Inclination	0	0.0
<30°	1	1.2
30–34°	2	2.5
35–39°	7	8.6
40–44°	28	34.6
45–49°	36	44.4
50–54°	7	8.6
>54°		
Lucent lines	81	100.0
No	0	0.0
Yes		
Osteolysis	81	100.0
No	0	0.0
Yes		
Heterotopic Ossification	74	91.4
No	7	8.6
Yes	6	7.4
Brooker I	1	1.2
Brooker II-III	0	0.0
Brooker IV		

One patient showed a lucent line during follow-up, in zone 2 and partly in zone 1 (Fig. 2b). Not a single patient presented with osteolysis of the acetabulum after 5 years. Heterotopic bone formation was presented in 8.6% (n = 7) of the patients. Six patients (7.4%) showed Brooker I and one patient (1.2%) showed Brooker II.

The mean number of radiographs available for EBRA evaluation was 3.74 (range 2.0–5.0) per patient and 42 patients contributed to the EBRA analysis at mid-term follow-up.

Mean cup migration at 12 months was 0.80 mm (range: 0.00–2.81), at 24 months 0.86 mm (range: 0.00–2.56) and at mid-term follow-up 1.34 mm (range: 0.09–3.14). The migration rate per year decreased from 0.36 mm per year (range: -3.55–4.02) at 12 months to 0.22 mm per year (range: -0.24–1.34) at 5 years.

Mean total wear was 0.18 mm (range: 0.00–0.78) at 12 months and 0.28 mm (range: 0.00–0.68) at 24 months. At mid-term follow-up the total wear, again, increased slightly to 0.40 mm (range: 0.03–1.00). Mean annual wear rate was 0.06 mm per year after 5 years (Table 4).

Table 4
EBRA measurements of total migration and total wear at each follow-up

	Months	N	Mean	SD	Median	Min	Max
Total Migration (mm)	0	44	0.00	0.00	0.00	0.00	0.00
	3	36	0.34	0.41	0.23	0.00	2.07
	12	50	0.80	0.71	0.56	0.00	2.81
	24	48	0.86	0.62	0.70	0.00	2.56
	60	42	1.34	0.63	1.26	0.09	3.14
Total migration rate (mm/year)	3	30	2.26	2.67	1.29	0.00	11.53
	12	48	0.63	1.00	0.43	3.55	4.02
	24	45	0.17	0.34	0.17	1.01	1.23
	60	42	0.22	0.25	0.16	0.24	1.34
Total wear (mm)	0	44	0.00	0.00	0.00	0.00	0.00
	3	36	0.11	0.12	0.06	0.00	0.54
	12	50	0.18	0.17	0.15	0.00	0.78
	24	48	0.28	0.17	0.26	0.00	0.68
	60	42	0.40	0.24	0.32	0.03	1.00
Total wear rate (mm/year)	3	36	0.61	0.70	0.38	0.00	2.72
	12	50	0.17	0.15	0.13	0.00	0.67
	24	48	0.09	0.05	0.09	0.00	0.26
	60	42	0.06	0.04	0.05	0.00	0.17

Discussion

The aim of the present study was to assess the mid-term clinical and radiological outcome and in particular to investigate the migration and wear rate of the third generation of a cementless isoelastic monoblock cup with vitamin E blended HXLPE. At mid-term follow-up almost no cup-related complications could be observed and none of the investigated implants required revision surgery. Radiologically, no direct signs of cup loosening were obvious and in none of the cases osteolysis could be observed. Clinical outcome and patient satisfaction resulted in very high scores.

Early migration is considered a predictor of aseptic loosening [5, 35], as a mean cup migration of more than 2 mm in the first 2 years has previously been shown to correlate significantly with aseptic loosening in the long-term [21–25, 33]. The present investigation resulted in a mean total migration of 1.34 mm at 5 years. Furthermore, at 2 years a mean migration of 0.86 mm was seen, which is far below the above mentioned 2 mm limit. Additionally loosening was defined as an overall migration increase of 0.5 mm per year [32, 33]. Our results demonstrated a migration rate of 0.22 mm per year at 5 years, which, again, is below the defined threshold for aseptic loosening.

To date, only few previous publications can be found regarding the newest generation of the investigated cup. Wyatt et al.[5] also analyzed cup migration, however, only few EBRA measurements (n = 13) could be included. They found a mean migration of 1.5 mm at 5 years, which can be confirmed by the present study. The majority of migration occurred within the first 12 weeks after surgery, thus, the authors

concluded it can be explained just by the initial cup seating and all components can be considered stable thereafter [5]. The present study also shows that migration stagnates at 1–2 years postoperatively and subsequently in most cases secondary stabilization occurs. After the first 2 years and the onset of secondary stability, only slight further migration could be observed.

The cause of migration can be both, inadequate initial fixation with insufficient primary stability or the subsequent loss of fixation during follow-up [33, 35]. Both scenarios might indicate an increased risk of failure. In contrast, however, it has been shown that minor migration over years often remains asymptomatic [6, 35]. In the present study clinical results are excellent and no signs of failure were detected, despite minor continuous migration. Longer-term follow up will have to confirm these findings in the future.

Wyss et al.[6] investigated the second generation of the isoelastic monoblock cup (RM Pressfit, Mathys Ltd., Bettlach, Switzerland) in a mid-term follow-up. Almost the same results were found, as compared to the present study. However, in contrast to the present investigation, all surgeries were performed using a transgluteal approach, patients were only alowed partial weight bearing and flexion was initially limited to 70° [6]. It is obvious that the occurance of migration and subsequent loosening might reflect the quality of operative technique – particularly the reaming process- and implant selection [33]. Studies have also shown a correlation between cup inclination and cup diameter with early migration [22]. However, also the postoperative treatment protocol is likely to have an impact on early migration. In the present study, all surgeries were performed using the minimally-invasive anterolateral approach, theoretically making the cup positioning more challenging, potentially affecting migration. It is remarkable, that similar results are achieved in the present study compared to the investigation by Wyss et al.[6], although the postoperative treatment protocol is far more aggressive.

Besides migration, polyeythelene wear is also an indicator of aseptic loosening of endoprosthetic components, by causing osteolysis of the acetabular and femoral bone stock. Thus, this aspect has additionally been taken into account in the present investigation.

It has been reported that oxidation of polyethylene particles is a factor inducing osteolysis [11, 29, 36, 37]. Therefore, it is of major interest to further improve UHMWPE in order to decrease wear and potentially increase the lifetime of acetabular components.

Previous in-vitro studies have already demonstrated that vitamin E blended HXLPE improves fatigue strength and protects against oxidative damage [11, 15, 17, 18]. The protection of HXLPE with vitamin E leads to excellent oxidation resistance [11, 13, 15, 38], which potentially leads to a reduction of wear. Beck et al. reported, that the wear rate of vitamin E-blended HXLPE is at least seven times lower than the wear rate of the standard gamma-sterilized UHMWPE [11]. This, by decreasing wear rate and oxidative degeneration potentially results in less osteolysis, which in turn might lead to decreased rates of aseptic loosening and failure.

Early studies found that osteolysis is rarely observed in THA patients with wear below the threshold of 0.1 mm per year [19]. In the present investigation, annual wear rates are at 0.06 mm per year and thus far below this benchmark. Moreover, Dumbleton et al. found that below a rate of 0.05 mm per year, osteolysis will practically not occur [19]. Earlier studies using the second generation of the isoelastic monoblock cup, showed slightly higher annual wear rates, compared to the present results. Wyss et al.[6] found 0.09 mm per y and Lafon et al.[7] found 0.07 mm per y. Rochcongar et al. recently performed a prospective randomized controlled study comparing RM Pressfit cup (UHMWPE) to RM Pressfit vitamys cup (HXLPE/VitE) and confirmed that wear rates over the first three years following surgery were lower for the HXLPE blended with vitamin-E [2]. This might directly affect the need of late revision surgery. Engh et al. compared cross-linked (HXLPE) and non-cross-linked (UHMWPE) polyethylene and showed that lower wear occurred in the cross-linked group and fewer revision surgeries were necessary [39].

At mid-term follow-up, no adverse events occurred and none of the investigated cups showed signs of failure, making not a single revision surgery necessary. A sclerotic line in zone 2 can be found in some of the patients at the dome of the cup, without containing the risk of subsequent loosening. This is most probably because of the aspheric design of the cup with flattening of the dome. Osteointegration seems to be complete and stable in zone 1 and zone 3 in those cases.

Moreover, encouraging clinical results, with marked improvements in functionality and activity level, confirm earlier studies [2, 4–7, 9, 10, 14, 18] and strongly support the concept of a cementless isoelastic monoblock cup with vitamin-E blended HXLPE.

Some limitations to the present study have to be acknowledged. First is the mid-term follow-up of 5 years. Although only long-term results should be considered valid regarding the investigation of implant survival, early evaluation of radiological alterations, migration and wear, however, is helpful to identify future undisirable results. Early migration analysis using EBRA has been established in several studies providing a reference to long-term survival [5, 6, 35]. Second the method used to measure migration and wear lacks some accuracy in comparison to radiostereometric analysis (RSA) [34]. Measured wear might be greater than when using RSA, for example, due to a probable plastic cup deformation affecting the shape of the contrast wire [21, 34]. Nevertheless, the need to implant markers intraoperatively restricts the usage of RSA significantly and would have caused intense cost and effort.

Another limitation of this study is the EBRA software failing to evaluate all radiographs. The image requirements for EBRA measurement are quite challenging, leading to a high rate of radiographs which are not accepted by the EBRA software. However, with included data of 42 patients at mid-term follow-up, to our knowledge, no equivalent high number has been analyzed so far in previous studies. As several radiographs were taken at different time points within the follow-up period, the mean migration and wear results are highly reliable.

Conclusion:

The present study confirms that the concept of vitamin-E blended HXLPE in cementless isoelastic monoblock cups prevents osteolysis, aseptic loosening and the need of revision surgery at mid-term. Values for cup migration and wear stay well below the benchmarks which are considered predictive for future failure. Long-term data will have to confirm these findings.

Abbreviations

HXLPE: Highly cross-linked polyethylene; UHMWPE: Ultra-high-molecular-weight polyethylene; THA: total hip arthroplasty; HHS: Harris hip score; VAS: Visual analogue scale; EBRA: Einzel-Bild-Roentgen-Analyse; RSA: Radiostereometric analysis

Declarations

Ethics approval and consent to participate:

All procedures performed were in accordance with the 1964 Helsinki Declaration. Ethical approval was obtained (FF 154/2017) from the Ethics Commission of the state medical association Hessen, Frankfurt, Germany (“Ethik-Kommission bei der Landesärztekammer Hessen”). All patients gave their verbal and written permission to participate prior to inclusion. This study was funded by Mathys Ltd., Bettlach, Switzerland. KPK and PR serve as instructors for Mathys Ltd., Bettlach, Switzerland. PR also serves as medical advisor. All other authors declare that they have no competing interests.

Consent for publication

Not applicable

Availability of data and material

The dataset generated and/or analysed during the current study are not publicly available due to the high volume of data but are available from the corresponding author on reasonable request.

Competing interests

KPK and PR serve as instructors for Mathys Ltd., Bettlach, Switzerland. PR also serves as medical advisor. All other authors declare that they have no competing interests.

Funding

This study was funded by Mathys Ltd., Bettlach, Switzerland. Mathys covered costs incurred for the execution of the study, including radiographs and statistical analysis.

Authors' contributions

All authors contributed to the study conception and design. Material preparation, data collection and analysis were performed by YA, JT, SJ and PR. The first draft of the manuscript was written by YA and KPK. JD, PD and PR were also major contributors in writing the manuscript. All authors commented on previous versions of the manuscript. All authors read and approved the final manuscript.

Acknowledgements:

The present study contains data obtained as part of the dissertation thesis of JT.

We thank Dominik Pfluger (numerics data GmbH) and Marion Roethlisberger for supporting statistical analysis.

References

1. Learmonth ID, Young C, Rorabeck C. The operation of the century: total hip replacement. Lancet. 2007;370:1508–19.
2. Rochcongar G, Buia G, Bourroux E, Dunet J, Chapus V, Hulet C. Creep and Wear in Vitamin E-Infused Highly Cross-Linked Polyethylene Cups for Total Hip Arthroplasty: A Prospective Randomized Controlled Trial. JBJS. 2018;100. .
3. Callaghan JJ, Liu SS, Firestone DE, Yehyawi TM, Goetz DD, Sullivan J, et al. Total hip arthroplasty with cement and use of a collared matte-finish femoral component: nineteen to twenty-year follow-up. JBJS. 2008;90:299–306.
4. Ihle M, Mai S, Pfluger D, Siebert W. The results of the titanium-coated RM acetabular component at 20 years: A term follow-up of an uncemented primary total hip replacement. 2008;:1284.
5. Wyatt M, Weidner J, Pfluger D, Beck M. The RM Pressfit vitamys: 5-year Swiss experience of the first 100 cups. Hip Int. 2017;27:368–72.
6. Wyss T, Kägi P, Mayrhofer P, Nötzli H, Pfluger D, Knahr K. Five-year Results of the Uncemented RM Pressfit Cup Clinical Evaluation and Migration Measurements by EBRA. J Arthroplasty. 2013;28:1291–6. doi:.
7. Lafon L, Moubarak H, Druon J, Rosset P. Cementless RM. Pressfit® Cup. A clinical and radiological study of 91 cases with at least four years follow-up. Orthop Traumatol Surg Res. 2014;100:225–9.
8. Pakvis D, Biemond L, van Hellemondt G, Spruit M. A cementless elastic monoblock socket in young patients: a ten to 18-year clinical and radiological follow-up. Int Orthop. 2011;35:1445–51.
9. Hooper N, Sargeant H, Frampton C, Hooper G. Does a Titanium-coated Polyethylene Press-fit Cup Give Reliable Midterm Results? Clin Orthop Relat Res. 2015;473:3806–10. doi:.
10. Erivan R, Eymond G, Villatte G, Mulliez A, Myriam G, Descamps S, et al. RM Pressfit® cup: good preliminary results at 5 to 8 years follow-up for 189 patients. Hip Int. 2016;26:386–91.
11. Beck M, Delfosse D, Lerf R, Becker R, French G. Oxidation prevention with Vitamin E in a HXLPE isoelastic monoblock pressfit cup: preliminary results. Springer; 2012. p. 21–31.

12. Oral E, Muratoglu OK. Vitamin E diffused, highly crosslinked UHMWPE: a review. Int Orthop. 2011;35:215–23.
13. Oral E, Wannomae KK, Hawkins N, Harris WH, Muratoglu OK. α-Tocopherol-doped irradiated UHMWPE for high fatigue resistance and low wear. Biomaterials. 2004;25:5515–22.
14. Scemama C, Anract P, Dumaine V, Babinet A, Courpied JP, Hamadouche M. Does vitamin E-blended polyethylene reduce wear in primary total hip arthroplasty: a blinded randomised clinical trial. Int Orthop. 2017;41:1113–8.
15. Lerf R, Zurbrügg D, Delfosse D. Use of vitamin E to protect cross-linked UHMWPE from oxidation. Biomaterials. 2010;31:3643–8.
16. Bracco P, Oral E. Vitamin E-stabilized UHMWPE for total joint implants: a review. Clin Orthop Relat Res. 2011;469:2286–93.
17. Halma J, Senaris J, Delfosse D, Lerf R, Oberbach T, van Gaalen S, et al. Edge loading does not increase wear rates of ceramic-on-ceramic and metal-on-polyethylene articulations. J Biomed Mater Res Part B Appl Biomater. 2014;102:1627–38.
18. Halma J, Eshuis R, Vogely HC, van Gaalen S, de Gast A. An uncemented iso-elastic monoblock acetabular component: preliminary results. J Arthroplasty. 2015;30:615–21.
19. Dumbleton JH, Manley MT, Edidin AA. A literature review of the association between wear rate and osteolysis in total hip arthroplasty. J Arthroplasty. 2002;17:649–61.
20. Krismer M, Bauer R, Tschupik J, Mayrhofer P. EBRA: a method to measure migration of acetabular components. J Biomech. 1995;28:1225–36.
21. Ilchmann T, Markovic L, Joshi A, Hardinge K, Murphy J, Wingstrand H. Migration and wear of long-term successful Charnley total hip replacements. J Bone Jt Surg Br. 1998;80:377–81.
22. Kostakos AT, Macheras GA, Frangakis CE, Stafilas KS, Baltas D, Xenakis TA. Migration of the trabecular metal monoblock acetabular cup system. J Arthroplasty. 2010;25:35–40.
23. Stocks G, Freeman M, Evans S. Acetabular cup migration. Prediction of aseptic loosening. J Bone Joint Surg Br. 1995;77:853–61.
24. Wilkinson J, Gordon A, Stockley I. Experiences with the Plasmacup–early stability, wear, remodelling, and outcome. Int Orthop. 2003;27:16-9.
25. Wroblewski B, Siney P, Fleming P. The principle of low frictional torque in the Charnley total hip replacement. J Bone Joint Surg Br. 2009;91:855–8.
26. Pfeil J, Siebert W, editors. Minimally Invasive Surgery in Total Hip Arthroplasty. Heidelberg: Springer Verlag; 2010.
27. Harris WH. Traumatic arthritis of the hip after dislocation and acetabular fractures: treatment by mold arthroplasty: an end-result study using a new method of result evaluation. JBJS. 1969;51:737–55.
28. Marchetti P, Binazzi R, Vaccari V, Girolami M, Morici F, Impallomeni C, et al. Long-term results with cementless Fitek (or Fitmore) cups. J Arthroplasty. 2005;20:730–7.

29. Engh CA Jr, Claus AM, Hopper RH Jr, Engh CA. Long-term results using the anatomic medullary locking hip prosthesis. Clin Orthop Relat Res. 2001;393:137–46.
30. DeLee J, Charnley J. Radiological demarcation of cemented sockets in hip arthroplasty. Clin Orthop Relat Res. 1976;121:20–32.
31. Brooker AF, Bowerman JW, Robinson RA, Riley LH Jr. Ectopic ossification following total hip replacement: incidence and a method of classification. JBJS. 1973;55:1629–32.
32. Wilkinson J, Hamer A, Elson R, Stockley I, Eastell R. Precision of EBRA-Digital software for monitoring implant migration after total hip arthroplasty. J Arthroplasty. 2002;17:910–6.
33. Stoeckl B, Brabec E, Wanner S, Krismer M, Biedermann R. Radiographic evaluation of the Duraloc cup after 4 years. Int Orthop. 2005;29:14–7.
34. Ilchmann T, Mjöberg B, Wingstrand H. Measurement accuracy in acetabular cup wear: three retrospective methods compared with Roentgen stereophotogrammetry. J Arthroplasty. 1995;10:636–42.
35. Krismer M, Stöckl B, Fischer M, Bauer R, Mayrhofer P, Ogon M. Early migration predicts late aseptic failure of hip sockets. J Bone Joint Surg Br. 1996;78:422–6.
36. Ingham E, Fisher J. The role of macrophages in osteolysis of total joint replacement. Biomaterials. 2005;26:1271–86.
37. Willert H-G, Bertram H, Buchhorn GH. Osteolysis in alloarthroplasty of the hip. The role of bone cement fragmentation. Clin Orthop Relat Res. 1990;:108–21.
38. Kurtz S, Dumbleton J, Siskey R, Wang J, Manley M. Trace concentrations of vitamin E protect radiation crosslinked UHMWPE from oxidative degradation. J Biomed Mater Res Part A An Off J Soc Biomater Japanese Soc Biomater Aust Soc Biomater Korean Soc Biomater. 2009;90:549–63.
39. Engh CA Jr, Hopper RH Jr, Huynh C, Ho H, Sritulanondha S, Engh CA. A prospective, randomized study of cross-linked and non–cross-linked polyethylene for total hip arthroplasty at 10-year follow-up. J Arthroplasty. 2012;27:2–7.

Figures

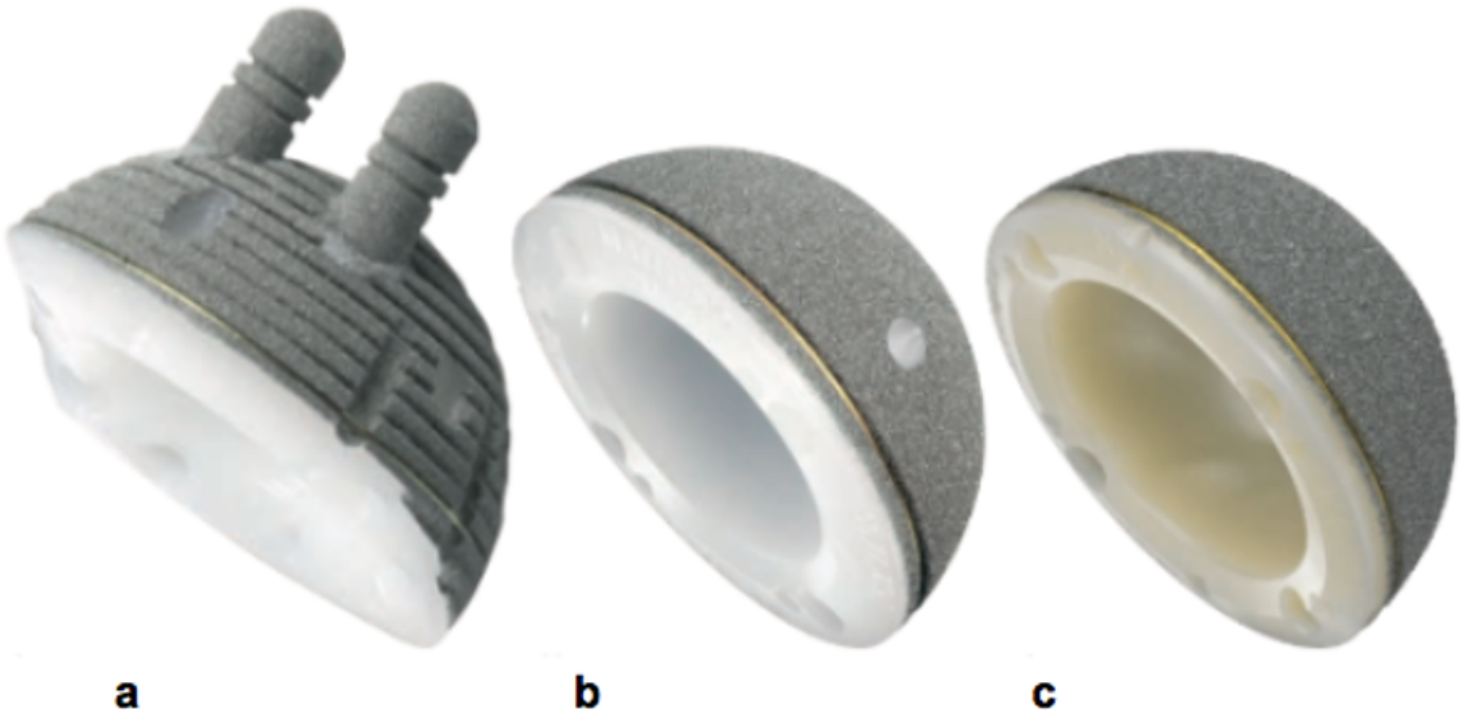

Figure 1

1a: RM Classic cup; 1b: RM Pressfit cup; 1c: RM Pressfit vitamys cup

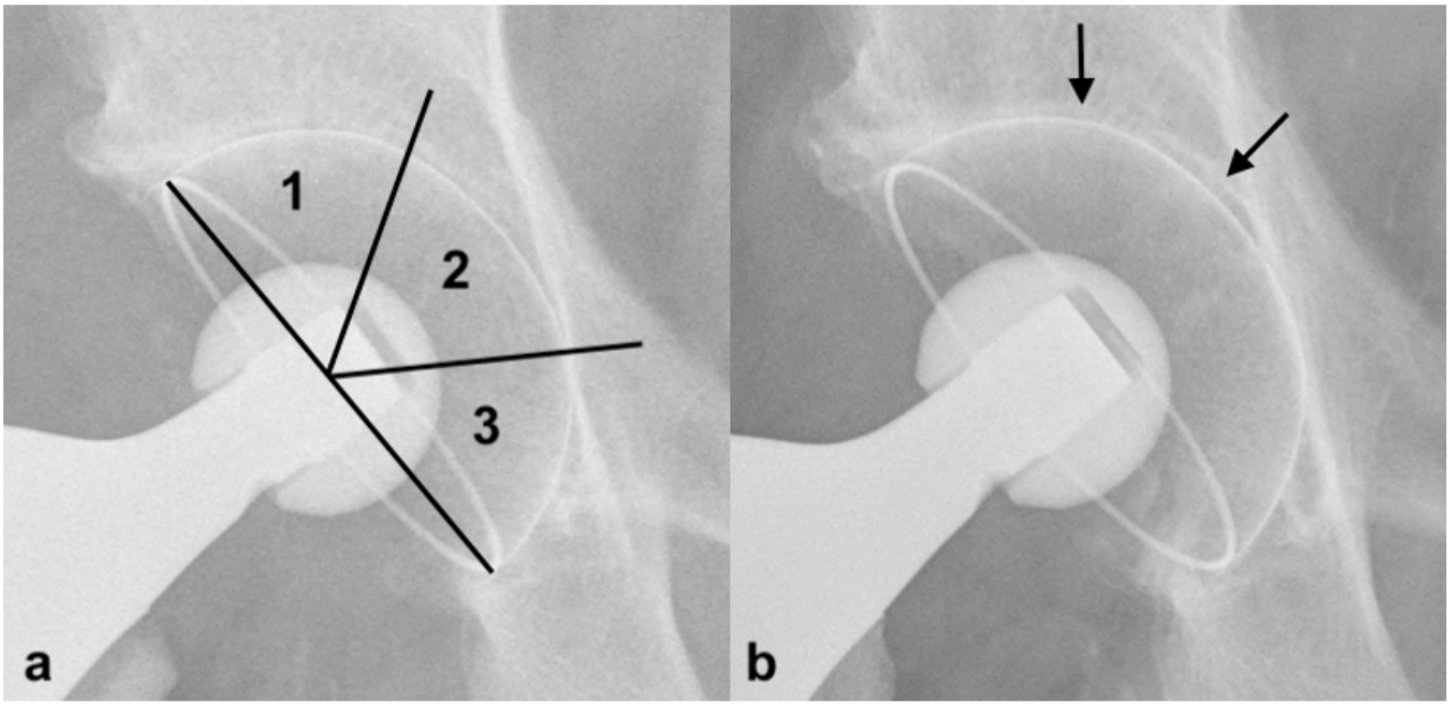

Figure 2

Radiographs of a RM Pressfit vitamys cup (Mathys Ltd. Bettlach, Switzerland) directly postoperative (a) and at 5 year follow-up (b). The patient (89-year-old male) showed signs of a sclerotic line in Zone 1 and

2.

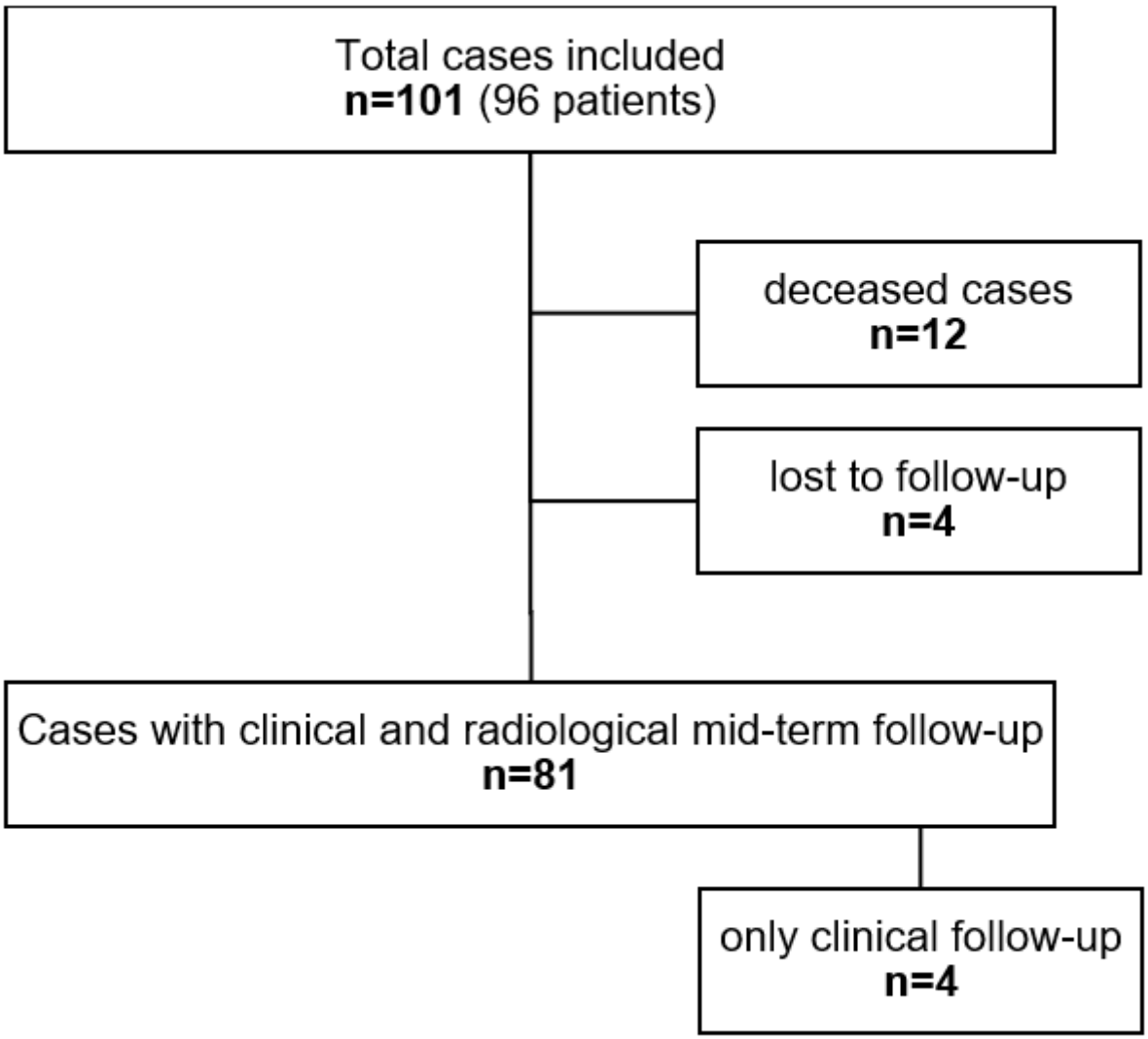

Figure 3

Flow-diagram of follow-up