Hemiarthroplasty for the Management of unstable femoral intertrochanteric fractures in elderly patients over 75 years old: a retrospective matched comparative study

Juncheng Ge
China-Japan Friendship Hospital https://orcid.org/0000-0002-1627-6373
Jinhui Ma
China-Japan Friendship Hospital
Bailiang Wang (Wang_orthopaedic@126.com)
Yu Zhou
China-Japan Friendship Hospital
Debo Yue
China-Japan Friendship Hospital
Wei Sun
China-Japan Friendship Hospital
Wanshou Guo
China-Japan Friendship Hospital
Weiguo Wang
China-Japan Friendship Hospital
Qidong Zhang
China-Japan Friendship Hospital

Research article

Keywords: Femoral intertrochanteric fractures, intertrochanteric fractures, PFNA, Proximal Femoral Nail Antirotation, Hemiarthroplasty, Elderly patients

Posted Date: April 29th, 2020

DOI: https://doi.org/10.21203/rs.3.rs-20822/v1

Abstract

Background

To compare and analyze the therapeutic effect of Proximal Femoral Nail Antirotation and hemiarthroplasty on intertrochanteric fracture.

Methods

45 patients with intertrochanteric fractures (17 males and 28 females) admitted to our hospital from January 2016 to January 2018 were collected. The mean age was 84.82 ± 0.73 years. All injuries were caused by falls during daily activities. Patients were divided into two groups according to the surgical method: the first group was the hemiarthroplasty group, referred to as the hemiarthroplasty group, with a total of 22 patients, and the average length of hospital stay was 13.09 ± 5.03 days. According to the improved Evans-Jensen classification [5], there were 1 cases of III, 9 cases of IV, and 12 cases of V12.The second group was the Proximal Femoral Nail Antirotation group, and the average length of hospital stay was 13.09 ± 6.97 days. According to the Evans-Jensen classification, 1 patient was III, 16 patients were IV, and 6 patients were V.

Results

Intraoperative blood loss was higher in the The Proximal Femoral Nail Antirotation group than in the hemiarthroplasty group(P=0.034).In the postoperative recovery of the two groups, the time from operation to partial weight-bearing of the hemiarthroplasty group was shorter than that of the PFNA group□p□0.000 □, and the postoperative HHS of the hemiarthroplasty group was also better than the latter (p □0.0005). In terms of total cost during hospitalization, the Hemiarthroplasty group was less than the PFN group(p □ 0.017). One year after surgery, the mortality rate increased to 34% in the PNFA group and 9% in the hemiarthroplasty group(P = 0.038), which was statistically significant.

Conclusion

Hemiarthroplasty for intertrochanteric fractures in the elderly can reduce intraoperative blood loss, achieve early recovery, improve survival rates, and reduce the economic burden on patients

Background

Intertrochanteric fracture is a common type of hip fracture(1). The patients are mostly elderly, and the risk and severity of fracture may increase with age.In recent years, with the aging population becoming more and more serious, the fracture rate caused by osteoporosis has also increased(2).After osteoporosis, bone trabecular thinning, sparse arrangement and partial fracture, bone cortex thinning and bone strength

decreasing, the violent action of low energy can cause fracture(3), and once the intertrochanteric fracture occurs, comminuted fracture is easy to occur, resulting in instability at the fracture end.

The classification of intertrochanteric fracture is based on the morphology of the fracture, gradually formed the understanding of the fracture "stability". Evans's study(4), first published in 1949, divided trochanteric fractures into two main types based on fracture line orientation and whether fracture stability could be achieved and maintained through closed reduction and bone traction. In 1975, Jensen improved the Evans typing(5), namely, Evans-Jensen typing (Fig. 1), which was adopted by most scholars who studied intertrochanteric fractures in the future. This classification system believed that the fracture stability decreased with the increase of the number of comminuted fractures between the lesser trochanter and the greater trochanter. The classification of type I and type □, for stable fractures □ ~ □ for unstable fracture. Because these patients are mostly elderly patients, most of them are associated with chronic diseases. After fracture, long-term lying in bed can cause pressure sores, falling pneumonia, urinary tract infection, pulmonary embolism and other complications, and even death in severe cases. Moreover, long-term lying in bed will further aggravate the loss of bone mass, making patients with osteoporosis worse and forming a vicious cycle. Therefore, most researchers believe that patients with unstable intertrochanteric fractures and osteoporosis who can endure surgery should be treated with surgery as soon as possible, so that patients can go to the ground at an early stage, recover their activities and self-care ability earlier, and reduce various complications caused by long-term bed rest(6, 7).

At present, the surgical treatment methods for unstable intertrochanteric fractures include internal fixation and femoral head replacement, among which internal fixation includes dynamic hip screw, proximal femoral nail and proximal femoral locking plate. At present, there is still no unified conclusion on which surgical method can achieve the best curative effect. Studies have reported the application of proximal femoral intramedullary nails in the treatment of intertrochanteric fractures in patients with osteoporosis(8).As a classic treatment method, artificial femoral head replacement is also used in the treatment of unstable intertrochanteric fractures in patients with osteoporosis(9). In the treatment, bone cement type artificial femoral head replacement is often used, and the prosthesis is firmly fixed in the medullary cavity with the immediate mechanical fixation of bone cement, which also achieves good clinical results. Therefore, for complicated unstable fractures, it is of great significance to select appropriate surgical methods to promote early recovery, shorten bed time, reduce disability rate and mortality, and reduce postoperative complications.

Materials And Methods

Study population.

45 patients with intertrochanteric fractures (17 males and 28 females) admitted to our hospital from January 2016 to January 2018 were collected. The mean age was 84.82 ± 0.73 years. All injuries were caused by falls during daily activities. Patients were divided into two groups according to the surgical

method: the first group was the hemiarthroplasty group, referred to as the hemiarthroplasty group, with a total of 22 patients, and the average length of hospital stay was 13.09 ± 5.03 days. According to the improved Evans-Jensen classification, there were 1 cases of III, 9 cases of IV, and 12 cases of V12.The second group was the PFNA group, and the average length of hospital stay was 13.09 ± 6.97 days. According to the Evans-Jensen classification, 1 patient was III, 16 patients were IV, and 6 patients were V. The data of patients in the two groups, such as gender, age, assessment score of admission daily living ability, length of stay, fracture to operation time and fracture type composition, are shown in the following table:

Inclusion and exclusion criteria.

Inclusion criteria : the clinical symptoms and imaging findings of the medical history were consistent with intertrochanteric fractures, Evans-Jensen classification type III or above, unstable intertrochanteric fractures elderly patients over 65 years old who could walk independently before injury, and the surgical indications were clear. Exclusion criteria : patients with severe cardiopulmonary insufficiency and other complications, who could not tolerate the operation; patients with severe bleeding and coagulation dysfunction; patients with surgical site infection; patients who had severe lower limb mobility disorder and could not walk normally before the injury.

Surgical methods.

After admission, all patients received traction fixation of lower limbs before surgery, and the relevant preoperative examination was improved. Through the assessment of the patients' physical condition, related complications were treated by consultation of internal medicine or related departments. After adequate preoperative preparation, the surgery was performed by the same group of experienced orthopedic surgeons under general anesthesia or combined lumbar and epidural anesthesia.

hemiarthroplasty groups.

After the patient was in the lateral position, a posterolateral incision was made on the affected side of the hip joint, layer by layer incision was made to expose the joint capsule and the fracture, and the joint capsule was cut open to avoid damage to the joint capsule as much as possible. Femoral neck osteotomy was performed at the back of the femoral neck to expose the femoral head, then the femoral head was removed, the size of the trochanteric was retained, the broken bone mass of the trochanteric fracture was reduced, and the attachment point of the gluteus medius muscle was preserved. With the pulp cavity file, the pulp cavity reaming was performed, then the appropriate lengthened femoral stem prosthesis was selected, and finally the bone cement and lengthened stem prosthesis were inserted. After the bone cement solidified, the femoral head prosthesis test model was used to select the appropriate femoral head prosthesis, then the shaft and the femoral head prosthesis were fixed, and the trochanteric fracture block was fixed with Kirschner wire tension belt or steel wire, and then the joint was reset.Finally, the range of motion and stability of the joint were tested. If the surgical results were satisfactory, the wound was rinsed and the incision closed layer by layer. (Fig. 2)

PFNA group.

After the patient is supine, fix the traction frame. The uninjured side outreaches, the affected limb flexes after traction, the pronation, the adduction, under the fluoroscopy adjustment to the satisfactory position. The proximal greater trochanter of the affected limb was incised through a straight incision about 4-6cm long, the skin, subcutaneous and deep fascia were incised, the gluteus medius muscle was obtuse separated, the tip of the greater trochanter was palpable, After lifting the greater trochanter by Steinmann Pin, the fracture was repositioned under fluoroscopy until satisfactory. The guide wire was inserted at the apex of the greater trochanter with the reduction maintained, the proximal medullary cavity was enlarged, and the proximal intramedullary nail was inserted. The positions were adjusted below the X-ray line, followed by the upper proximal anti-rotation blade and the distal locking nail. After the fracture reduction and internal fixation position were checked to be satisfactory, the incision was cleaned and sutured layer by layer.

Perioperative management.

Low molecular weight heparin (LMWH) was routinely applied to prevent deep venous thrombosis (DVT). Prophylactic antibiotics should be applied half an hour before skin incision, and antibiotics should be used 3–5 days after surgery. On the first day after the operation, semi-supine position was feasible according to the general condition of the patient, and the patient was instructed to perform lower limb activities on the bed to exercise the muscle strength of the lower limb. Depending on the patient's recovery, it is important to determine when the patient should be able to move under partial weight.

Statistical indicators.

Operative time, Intraoperative blood loss, Hemoglobin concentration at admission,Hemoglobin concentration on the third day after surgery postoperative complications, The difference in hemoglobin concentration before and after surgery Postoperative partial weight-bearing time, Postoperative Harris score (10), Discharge daily living ability evaluation score and Total cost during hospitalization of the patients in the two groups were recorded respectively.

Statistical processing.

SPSS 25.0 statistical software was used. Measurement data were represented by `x ± s, and two independent samples t-test was used for inter-group comparison. The χ2 test was used to compare the enumeration data sets. $P < 0.05$ was considered statistically significant.

Results

Comparison of intraoperative conditions

There was no significant difference in the operation time between the two groups, while the intraoperative blood loss in the hemiarthroplasty group was less than that in

the PFNA group (P=0.034), and the intraoperative blood transfusion rate (the percentage of intraoperative blood transfusion patients in the group) in the hemiarthroplasty group was less than that in the PFNA group. By comparing the hemoglobin concentrations of the two groups at the time of admission and on the third day after surgery, no statistical difference was found in the changes in hemoglobin concentrations between the two groups. The results are shown in Table 2.

Table 1
Demographic data of Hemiarthroplasty group group and PFNA group.

	PFNA group	Hemiarthroplasty group	P value	t/χ2
Age (years)	85.04 ± 5.20	84.59 ± 4.68	0.453	0.307
Gender (male/female, n)	11/12	6/16	0.155	2.021
Length of stay (days)	13.09 ± 6.97	13.09 ± 5.02	0.998	0.002
Fracture to operation time (days)	3.30 ± 2.20	4.64 ± 2.63	0.072	1.845
Evans-Jensen classification (n)	III: 1 IV: 16 V: 6	III: 1 IV: 9 V: 12	0.487	4.449
Admission daily living ability assessment score	32.17 ± 10.20	33.41 ± 8.07	0.656	0.449

Table 2
Comparison of intraoperative conditions between the two group

	PFNA group	Hemiarthroplasty group	t/χ2	P value
The operation time(min)	107.07 ± 151.05	94.52 ± 22.11	0.458	0.649
Intraoperative blood loss (ml)	558.70 ± 342.99	363.64 ± 241.613	2.196	0.034
Hemoglobin concentration at admission(g/L)	106.04 ± 16.20	103.32 ± 18.65	0.524	0.603
Hemoglobin concentration on the third day after surgery(g/L)	95.63 ± 13.62	92.86 ± 16.21	0.520	0.606
The difference in hemoglobin concentration before and after surgery(g/L)	11.18 ± 20.60	10.09 ± 14.06	0.201	0.842
The intraoperative blood transfusion rate(%)	74	50	—	—

Postoperative recovery and discharge status

In the postoperative recovery of the two groups, the time from operation to partial weight-bearing of the hemiarthroplasty group was shorter than that of the PFNA group(p=0.000), and the postoperative HHS of the hemiarthroplasty group was also better than the latter (p 0.0005). In terms of total cost during hospitalization, the Hemiarthroplasty group was less than the PFN group(p 0.017). However, there was no significant difference in daily living ability score at discharge. The results are shown in Table 3.

Table 3
Comparison of postoperative recovery between the two groups.

	PFNA group	Hemiarthroplasty group	t value	P value
After surgery to partial weight bearing time(d)	7.47 ± 4.12	2.86 ± 0.83	5.149	0.000
HHS before discharge	80.39 ± 5.20	84.50 ± 3.86	2.997	0.005
Daily living ability score at discharge	37.17 ± 14.37	42.95 ± 16.80	1.242	0.221
Total cost during hospitalization()	93672.86 ± 18842.88	77069.41 ± 24936.72	2.492	0.017

Table 4
Complications and death of the patient one year after surgery

	PFNA group	Hemiarthroplasty group	χ2	P
Number of deaths 6 months after Surgery(n)	5(21%)	1(4%)	2.877	0.09
Number of deaths 1 year after Surgery(n)	8(34%)	2(9%)	4.294	0.038
implant-unrelated complications(n)	2	1	0.311	0.577
Implant-related complications(n)	4	2	0.670	0.413

Comparison of death and complications in patients one year after surgery

The mortality rate was 21% in the PFNA group and 4% in the hemiarthroplasty group, showing no statistical difference. One year after surgery, the mortality rate increased to 34% in the PNFA group and 9% in the hemiarthroplasty group(P = 0.038), which was statistically significant. One year after the operation, there were 2 cases of implant-unrelated complications and 4 cases of implant-related complications in the PFNA group. In the hemiarthroplasty group, there were 1 case of implant-unrelated complications complications and 2 cases of implant-related complications, which were not statistically significant.

Discussion

Intertrochanteric fractures often occur in the combination of osteoporosis in the elderly, as older patients often merge many medical conditions such as cardiovascular system, respiratory system, urinary system disease, if for intertrochanteric fractures without effective treatment as early as possible, often leads to various complications, these complications are likely to quality of life in elderly patients, and even a threat to life. Conservative treatment is mainly bed traction. Although conservative treatment avoids the impact of surgery on patients, long-term bed rest of elderly patients will lead to a series of complications, such as lung and urinary tract infection, lower limb deep vein thrombosis, pulmonary embolism, etc., and long-term braking will aggravate osteoporosis, muscle atrophy, joint stiffness, etc. If not effective braking traction, fracture healing may result in hip varus, malunion, lower limb shortening, etc. In a word, conservative treatment for elderly patients with intertrochanteric fracture of the femur, its advantages are not greater than its long-term disadvantages. At present, surgical treatment has become a priority treatment method for elderly intertrochanteric fractures. The incidence of complications and length of hospital stay of surgical treatment for intertrochanteric fractures are far lower than that of conservative treatment. Currently, the main surgical methods for intertrochanteric fractures are internal fixation and hemiarthroplasty.

PFNA is the most commonly used internal fixation technique. PFNA is developed on the basis of Proximal Femoral Nail (PFN) for patients with osteoporosis, which makes up for the deficiency of PFN and reduces the rate of screw resection in patients with osteoporosis(11). Compared with other internal fixation methods, PFNA has advantages of short operative time, small trauma, low blood loss and fast postoperative recovery(12–14).Some scholars believe that PFNA is suitable for most senile osteoporotic intertrochanteric fractures(15). PFNA fixation of intertrochanteric fractures has significant advantages in mechanical principle and anti-rotation function (16), which is currently the most widely used fixation method. However, with the increase in the number of cases of PFNA surgery, the number of cases of fixation failure is also gradually increasing. Some studies have shown that PFNA treatment for intertrochanteric fractures has a failure rate of 5%~30%(17, 18). The reasons for failure may be related to the patient's bone density, fracture type, surgical skills, internal fixation selection, postoperative functional exercise, etc. When internal fixation fails, most orthopedic surgeons resort to arthroplasty. However, this kind of secondary surgery is not a small burden for patients, either physically or financially. With the development of artificial joint replacement technology, more and more reports have been reported on the direct treatment of intertrochanteric fractures. Artificial joint replacement mainly includes total hip replacement and hemiarthroplasty. In view of the elderly's activity level and surgical trauma, arthroplasty for elderly patients with intertrochanteric fractures is mostly hemiarthroplasty, and bipolar femoral head replacement is more commonly used. Compared with total hip replacement, hemiarthroplasty has the advantages of short operation time, less bleeding and less cost. However, patients with pure femoral head replacement may suffer from discomfort caused by acetabular wear. Some scholars prefer total hip replacement as a revision operation after failure of internal fixation(19).Some scholars believe that there is no significant difference between the two in postoperative complications, length of hospital stay, degree of hip pain and mortality (20).Cement-type hemiarthroplasty and reconstruction of proximal

femoral structure can obtain immediate bone tissue and joint stability, which is conducive to the rapid recovery of patients and the reduction of disability rate and mortality, especially for unstable fractures. Some scholars also believe that joint replacement surgery is long, the amount of blood loss, postoperative infection and dislocation and other complications are high. A randomized prospective study of Stappaerts(21) compared the efficacy of internal fixation with artificial joint replacement: 90 patients aged ≥ 70 with fresh unstable intertrochanteric fractures, 47 with internal fixation, and 43 with artificial joint replacement. After 3 months of follow-up, there was no significant difference in operative time, mortality, and complications between the two groups, but the hemiarthroplasty group had more blood transfusion, while the internal fixation group had 11 cases of severe fracture displacement and collapse, requiring a second operation, while the hemiarthroplasty group only had 1 case requiring a second operation. Leonardsson(22) reported that 450 patients over 70 years of age with intertrochanteric fractures from 1995 to 1997 were randomly divided into the internal fixation group and the hemiarthroplasty group. After 10 years of follow-up, the failure rate of the internal fixation group was 45.6%, while that of the hemiarthroplasty group was 8.8%. They believed that the primary replacement could provide long-term reliable fixation effect for displaced intertrochanteric fractures.

In this study, hemiarthroplasty group of patients with intraoperative blood loss and rate of intraoperative blood transfusions are lower than PFNA group, the author thinks that with the continuous development of joint replacement technology, orthopedic surgeons to improve surgical skills in order to shorten the operation time, as well as sufficient preoperative preparation and intraoperative reduce bleeding, traditional ideas think hemiarthroplasty blood loss than PFNA may change. In terms of operation time, no significant statistical difference was found between the two in this study. Previous studies suggested that hemiarthroplasty would take longer than PFNA operation time. Considering that most patients with intertrochanteric fractures are old, the extension of operation time may increase the risk brought by the operation. However, with the development of artificial joint replacement, the time of hemiarthroplasty performed by experienced orthopedic surgeons is even shorter than that of PFNA. Therefore, the idea that longer duration of joint replacement surgery brings higher surgical risk to patients deserves further investigation.

In terms of functional recovery after operation, the advantages of artificial femoral head in the treatment of intertrochanteric fractures are more obvious. The time from the end of the operation to the movement of the patients under partial load was significantly shorter in the displacement group than in the PFNA group ($P < 0.01$).Artificial femoral head prosthesis, especially bone cement prosthesis, can penetrate into bone trabeculae, strengthen cancellous bone and obtain better endurance performance. After the bone cement solidifies, the two form micro-locking fixation, so as to strengthen the bone strength and achieve stable bone support. In addition, in patients with osteoporosis, the fixation strength can be increased to obtain immediate mechanical stability, reduce local stress and load early. The tolerance of doctors' technical deviation and bone quality is improved, and PFNA defects such as poor stability, fracture of prosthesis and difficult bone growth are avoided. Getting out of bed early after surgery can prevent various complications caused by long-term bed-rest in the elderly, so that the quality of life of the elderly can be significantly improved. In addition, complications after femoral head replacement are relatively

few, thus avoiding the harm of the second operation on the patients. PFNA, on the other hand, has a higher rate of surgical failure, complications and surgical failure often require secondary surgery or salvage joint replacement, but it can not bring or bring greater benefits. Elderly patients may die of surgical complications such as pulmonary embolism caused by deep vein thrombosis and pneumonia caused by long-term bed rest. Harris scores in both groups at discharge,hemiarthroplasty group was higher than PFNA group, indicating that the hemiarthroplasty group was superior to the PFNA group in terms of the degree of hip pain relief and the degree of hip movement improvement. However, considering the problems of acetabular wear and other aspects in hemiarthroplasty, long-term postoperative follow-up is still needed to compare the improvement degree of objective feelings of patients in the hip caused by these two surgical methods, which is a deficiency of this study.

In conclusion, our study indicates that the hemiarthroplasty performed by doctors with mature joint replacement technology for such patients has relatively less intraoperative blood loss than PFNA for intertrochanteric fractures. In terms of operation time, although there was no significant statistical difference, the average operation time of the hemiarthroplasty group in this study was relatively short, which may be more obvious with the expansion of sample size. In terms of postoperative recovery, for elderly patients, early underground activities are crucial to reduce complications and improve the quality of life of patients. The movement time of partial weight-bearing patients in the hemiarthroplasty group was earlier than that in the PFNA group, and the Harris score of hip joints in the hemiarthroplasty group before discharge was also higher than that in the PFNA group. Therefore, for elderly patients with three or more intertrochanteric fractures, hemiarthroplasty can shorten the length of hospitalization and recovery time, and reduce the economic burden of such patients(23, 24).

Conclusion

Hemiarthroplasty for intertrochanteric fractures in the elderly can reduce intraoperative blood loss, achieve early recovery, improve survival rates, and reduce the economic burden on patients.

Abbreviations

PFNA: Proximal Femoral Nail Antirotation; HHS: Harris hip score; LMWH: Low molecular weight heparin; DVT: Deep venous thrombosis

Declarations

Acknowledgements

This study was supported by the ethics committee of China-Japan Friendship Hospital, the medical record information system of China-Japan Friendship Hospital and the follow-up system of patient service center..

Authors’ contributions

GJC, MJH, ZY were involved in the survey, methodology, data collation, and preparation of the original draft.GJC was involved in the formal analysis, data collation and preparation of the original draft.The original draft was prepared by GJC and MJH.MJH and WBL perform data validation.WBL, YDB, GWS, WWG, SS, and ZQD contribute to surgical guidance.The WBL edited and reviewed the manuscript.All authors read and approved the final manuscript.

Funding

This research was funded by the Beijing Natural Science Foundation（No. 7204301）and China-Japan Friendship Hospital project (No. 2018-1-QN-9).

Availability of data and materials

The datasets used/or analyzed during the current study are available from the corresponding author on reasonable request.

Ethics approval and consent to participate

This study was approved by the medical ethics committee of China-Japan Friendship Hospital. All procedures conducted in the study comply with the ethical standards of our institutional ethics committee. All participants in the study received informed consent.

Competing interests

The authors declare that they have no competing interests.

References

1. Kazemian GH, Manafi AR, Najafi F, Najafi MA. Treatment of intertrochanteric fractures in elderly highrisk patients: dynamic hip screw vs. external fixation. Injury. 2014;45(3):568–72.
2. Joshi D, Dhamangaonkar AC, Ramawat S, Goregaonkar AB. Predictors of iatrogenic lateral wall fractures while treating intertrochanteric fracture femur with the dynamic hip screw system in Indian patients. European journal of orthopaedic surgery traumatology: orthopedie traumatologie. 2015;25(4):677–82.
3. Bhattacharya A, Watts NB, Dwivedi A, Shukla R, Mani A, Diab D. Combined Measures of Dynamic Bone Quality and Postural Balance–A Fracture Risk Assessment Approach in Osteoporosis. Journal of clinical densitometry: the official journal of the International Society for Clinical Densitometry. 2016;19(2):154–64.
4. Evans EM. The treatment of trochanteric fractures of the femur. The Journal of bone joint surgery British volume. 1949;31b(2):190–203.
5. Jensen JS, Michaelsen M. Trochanteric femoral fractures treated with McLaughlin osteosynthesis. Acta Orthop Scand. 1975;46(5):795–803.

6. Xu Z, Zhang M, Yin J, Ren L, Zeng Y. Redisplacement after reduction with intramedullary nails in surgery of intertrochanteric fracture: cause analysis and preventive measures. Arch Orthop Trauma Surg. 2015;135(6):751–8.
7. Wang XK, Ye JD, Gu FS, Wang AG, Zhang CQ, Tian QQ, et al. Numerical simulation research to both the external fixation surgery scheme of intertrochanteric fracture and the healing process, and its clinical application. Biomed Mater Eng. 2014;24(1):625–32.
8. Sehmisch S, Rieckenberg J, Dresing K. [Stabilization of unstable intertrochanteric fractures with the proximal femoral nail]. Operative Orthopadie Traumatologie. 2013;25(1):63–83. quiz – 4.
9. Kim Y, Moon JK, Hwang KT, Choi IY, Kim YH. Cementless bipolar hemiarthroplasty for unstable intertrochanteric fractures in octogenarians. Acta Orthop Traumatol Turc. 2014;48(4):424–30.
10. Harris WH. Traumatic arthritis of the hip after dislocation and acetabular fractures: treatment by mold arthroplasty. An end-result study using a new method of result evaluation. The Journal of bone joint surgery American volume. 1969;51(4):737–55.
11. Goffin JM, Pankaj P, Simpson AH, Seil R, Gerich TG. Does bone compaction around the helical blade of a proximal femoral nail anti-rotation (PFNA) decrease the risk of cut-out?: A subject-specific computational study. Bone joint research. 2013;2(5):79–83.
12. Mallya S, Kamath SU, Madegowda A, Krishnamurthy SL, Jain MK, Holla R. Comparison of radiological and functional outcome of unstable intertrochanteric femur fractures treated using PFN and PFNA-2 in patients with osteoporosis. European journal of orthopaedic surgery traumatology: orthopedie traumatologie. 2019;29(5):1035–42.
13. Wang W, Zhai S, Han XP, Cui Y. [Comparative study of proximal femoral nail anti-rotation and dynamic hip screw in the unstable intertrochanteric fractures in the elderly]. Zhonghua yi xue za zhi. 2018;98(5):357–61.
14. Yu W, Zhang X, Zhu X, Yu Z, Xu Y, Zha G, et al. Proximal femoral nails anti-rotation versus dynamic hip screws for treatment of stable intertrochanteric femur fractures: an outcome analyses with a minimum 4 years of follow-up. BMC Musculoskelet Disord. 2016;17:222.
15. Makki D, Matar HE, Jacob N, Lipscombe S, Gudena R. Comparison of the reconstruction trochanteric antigrade nail (TAN) with the proximal femoral nail antirotation (PFNA) in the management of reverse oblique intertrochanteric hip fractures. Injury. 2015;46(12):2389–93.
16. Huang Y, Zhang C, Luo Y. A comparative biomechanical study of proximal femoral nail (InterTAN) and proximal femoral nail antirotation for intertrochanteric fractures. Int Orthop. 2013;37(12):2465–73.
17. Wirtz C, Abbassi F, Evangelopoulos DS, Kohl S, Siebenrock KA, Kruger A. High failure rate of trochanteric fracture osteosynthesis with proximal femoral locking compression plate. Injury. 2013;44(6):751–6.
18. Streubel PN, Moustoukas MJ, Obremskey WT. Mechanical failure after locking plate fixation of unstable intertrochanteric femur fractures. J Orthop Trauma. 2013;27(1):22–8.

19. Cho CH, Yoon SH, Kim SY. Better functional outcome of salvage THA than bipolar hemiarthroplasty for failed intertrochanteric femur fracture fixation. Orthopedics. 2010;33(10):721.
20. Fan L, Dang X, Wang K. Comparison between bipolar hemiarthroplasty and total hip arthroplasty for unstable intertrochanteric fractures in elderly osteoporotic patients. PloS one. 2012;7(6):e39531.
21. Stappaerts KH, Deldycke J, Broos PL, Staes FF, Rommens PM, Claes P. Treatment of unstable peritrochanteric fractures in elderly patients with a compression hip screw or with the Vandeputte (VDP) endoprosthesis: a prospective randomized study. J Orthop Trauma. 1995;9(4):292–7.
22. Leonardsson O, Sernbo I, Carlsson A, Akesson K, Rogmark C. Long-term follow-up of replacement compared with internal fixation for displaced femoral neck fractures: results at ten years in a randomised study of 450 patients. The Journal of bone joint surgery British volume. 2010;92(3):406–12.
23. Lee YK, Ha YC, Chang BK, Kim KC, Kim TY, Koo KH. Cementless bipolar hemiarthroplasty using a hydroxyapatite-coated long stem for osteoporotic unstable intertrochanteric fractures. J Arthroplast. 2011;26(4):626–32.
24. Henzman C, Ong K, Lau E, Seligson D, Roberts CS, Malkani AL. Complication Risk After Treatment of Intertrochanteric Hip Fractures in the Medicare Population. Orthopedics. 2015;38(9):e799–805.

Figures

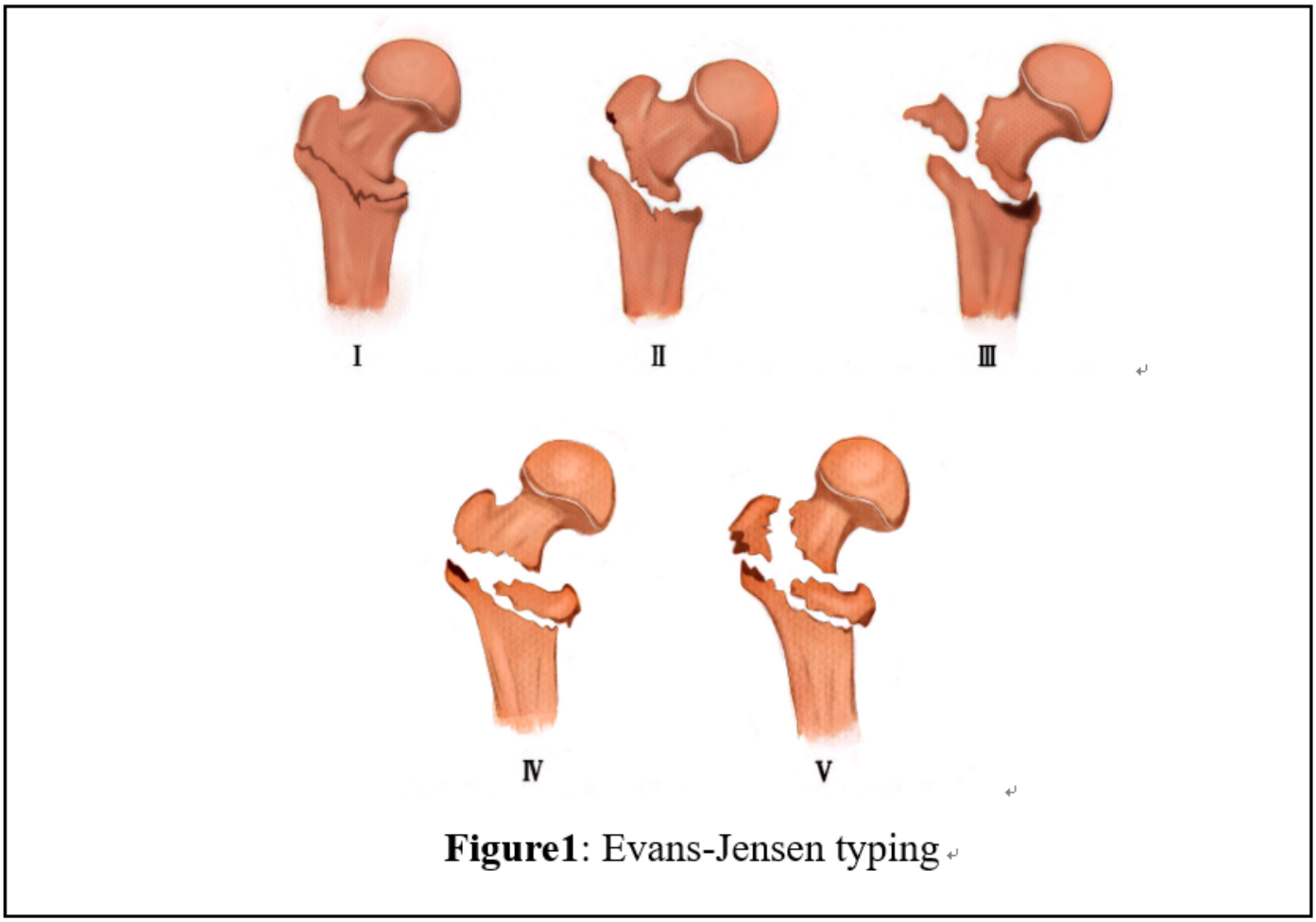

Figure 1

Evans-Jensen typing

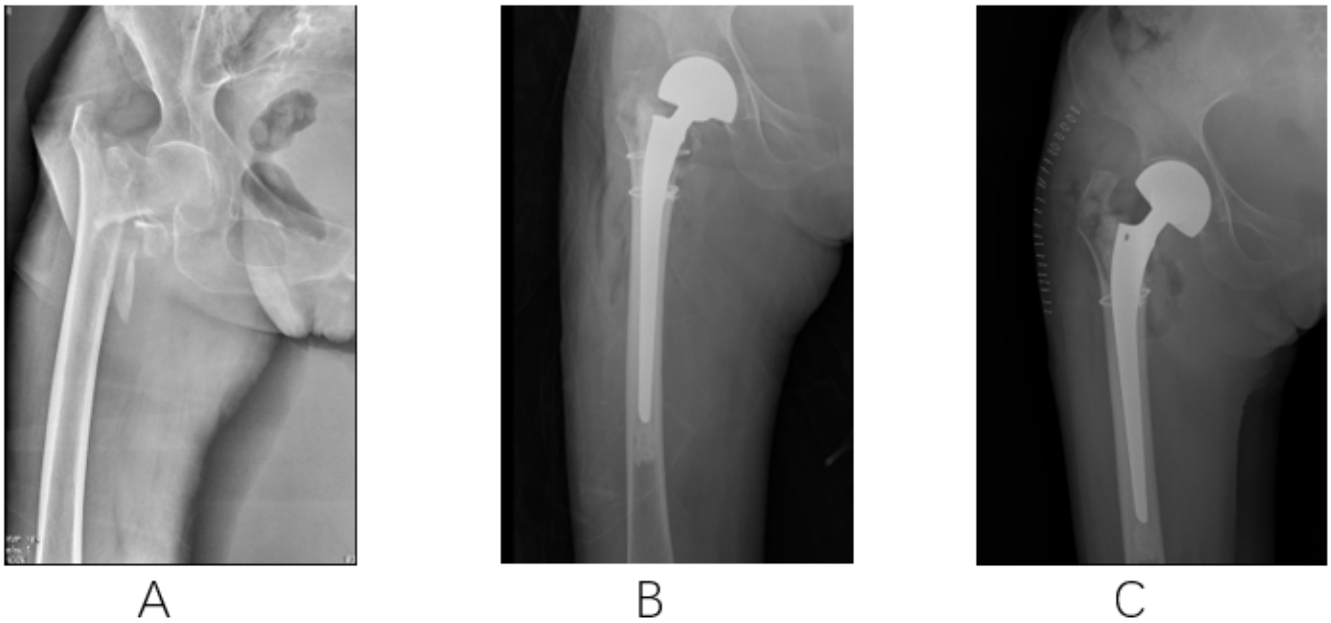

Figure 2

The above three pictures are all from an 83-year-old female patient with intertrochanteric fracture. A: the patient fell and caused the right intertrochanteric fracture. B shows good joint stability after hemiarthroplasty. C.:The patient was reexamined one year after surgery and the prosthesis had good function.