The multicenter study of Chest HRCT imaging characteristics of 2019 Novel Coronavirus (COVID-19) Pneumonia

Zhehao Lyu
the first affiliated hospital of Harbin Medical University

Meiji Ren
you'an hospital of beijing

Lian-Ming Wu
Shanghai Jiao Tong University School of Medicine Affiliated Renji Hospital

Yuxin Yang
the 6th hospital of XinJiang Province

Yi-Bo Lu
the 4th hospital of Nanning

Li Li
you'an hospital of beijing

Xiaoming Gong
Wuhan University Zhongnan Hospital

Zhiyan Lu
Wuhan University Zhongnan Hospital Medical Imaging Centre

Hongjun Li (lihongjun0113@126.com)
You'An hospital of Beijing

Research article

Keywords: Pneumonia, viral, Diagnosis, Computer-Assisted, Diagnostic Imaging

Posted Date: April 16th, 2020

DOI: https://doi.org/10.21203/rs.3.rs-20837/v1

Abstract

Background: In December 2019, a cluster of patients with pneumonia of unknown cause was linked to a seafood wholesale market in Wuhan, China. A novel coronavirus was detected, capable of infecting humans, on 6 January 2020 and termed COVID-19. By 16 February 2020, there were 51857 confirmed cases with 2019-nCoV (COVID-19) pneumonia in 25 countries. COVID-19 can also lead to acute respiratory distress syndrome (ARDS).

Methods: 149 patients with 2019 Novel Coronavirus (COVID-19)pneumonia(68 males, 81 females, ages 1-89)from 6 research centers in China were diagnosed with positive 2019 Novel Coronavirus(COVID-19)nucleic acids antibodies. And their high-resolution computed tomography(HRCT) imaging datas were evaluated.

Results: 136/149(91.3%)patients had a clear history of exposure to Wuhan. Fever (122/149, 81.9%)and cough(83/149, 55.7%)were the most common symptoms. The main imaging characteristics within 4 days of onset included 30(20.13%) cases of pure ground glass opacities (P<0.05), 38(25.50%) cases of GGO with reticulation(P<0.01), 12(8.05%) cases of consolidation(P<0.01). In the 5-8 days group, the main imaging features included 71(47.65%) cases of pGGO(P<0.05), 69(46.31%) cases of GGO with reticulation(P<0.01). In the 9-12 days group, the main feature was 85(57.04%) cases with GGO with reticulation(P<0.01). In the group of 13-16 days group, the main imaging characteristics included 48(32.21%) cases of GGO with reticulation(P < 0.01), 34(22.82%) cases of consolidation(P<0.01).

Conclusion: Patients infected with COVID-19 pneumonia show more chest CT characteristics within 5-8 days after the onset of disease. The main manifestations included pGGO, GGO with reticulation, consolidation and GGO with consolidation.

Background

In December 2019, a cluster of patients with pneumonia of unknown cause was linked to a seafood wholesale market in Wuhan, China. A novel coronavirus was detected, capable of infecting humans, on 6 January 2020 [1, 2] and termed COVID-19[1]. By 16 February 2020, there were 51857 confirmed cases with 2019-nCoV (COVID-19) pneumonia in 25 countries[3]. COVID-19 can also lead to acute respiratory distress syndrome (ARDS)[4, 5]. In this retrospective case series, a review of chest CT findings of 149 patients with Novel Coronavirus (COVID-19) infection from six research centers in China was reviewed, focusing on observing the imaging characteristics of different timepoints of the disease and explore its evolution rules.

Methods

Our institutional review board waived written informed consent for this retrospective case series, which evaluated unidentified data without potential risks to patients.

Patients and Diagnostic and Cure Criteria of COVID-19 Pneumonia

From January 18, 2020 to February 16, 2020, 149 patients diagnosed with COVID-19 pneumonia admitted to 6 hospitals in six provinces of China underwent chest CT examinations. Based on the preliminary diagnosis and treatment protocols from the National Health Commission of the People's Republic of China, the diagnostic criteria of COVID-19 pneumonia were: 1. epidemiological history - travel/residence history in Wuhan or exposure history to fevered patients with respiratory symptoms from Wuhan within 14 days before the onset of illness; 2. clinical manifestations - fever, cough, imaging characteristics of pneumonia, and/or normal or decreased white blood cells count or decreased lymphocyte count and 3. laboratory diagnosis - real-time fluorescence polymerase chain reaction revealed positive detection of COVID-19 in throat swabs or lower respiratory tract (7, 8). The patients with confirmed COVID-19 pneumonia were hospitalized and isolated for treatment. The discharge criteria were: 1. afebrile for greater than 3 days; 2. respiratory symptoms significantly improved and 3. improvement in the radiological abnormalities on chest CT; and 4. two consecutive negative COVID-19 nucleic acid detection at least 24 h apart[6].

CT Review

In addition to age and gender, the clinical information collected also includes onset time and symptoms and Wuhan exposure history. Three chest radiologists with about 7 to 30 years of experience independently reviewed the images and reached consensus. CT images were assessed for the presence and distribution of parenchymal abnormalities, including pure ground-glass opacity (pGGO), which were defined as a hazy increase in lung attenuation with no obscuration of the underlying vessels; GGO with reticulation; GGO with consolidation, which was defined as an area of opacification obscuring the underlying vessels in GGO; consolidation; air bronchogram(s); lymphadenopathy, which was defined as a lymph node > 1 cm in short-axis diameter; subpleural line; bronchiectasis; pleural effusion; pericardial effusion and cavity. The radiologist identified a CT lesion of the chest in each patient and a lesion occupying one lung segment was counted as one lesion. Each side of the pleural effusion counts as 1 lesion, the pericardial effusion counts as 1 lesion, and the enlarged lymph nodes count as 1 lesion.

Statistical Analysis

Statistical analyses were performed using IBM SPSS Statistics Software (version 23; IBM, New York, USA). Quantitative data were presented as mean ± standard deviation (minimum-maximum) and the counting data were presented as the percentage of the total unless otherwise specified. The comparison of discrete variables between groups was performed using the Pearson 2 test. Correlation analysis between two groups was performed using rank correlation. All analyses were considered significant at p values of less than 0.05.

Result

1. Patient Characteristics

A total of 149 patients (68 males and 81 females) were included in this study. The ages ranged from 1–89 years old (Table 1). The age of patients in main pattern of lesion respectively were 48 ± 15.3 years old for pGGO, 51 ± 15.0 years old for GGO with reticulation, 49 ± 15.3 years old for GGO with consolidation, 51 ± 16.5 years old for Consolidation (Table 1). The most common symptoms were fever (81.9%) and cough (55.7%) (Table 1). A total of 338 lung CT scans were performed on all selected patients. Each patient underwent an average of 2 ± 1 CT scans (range: 1–4) with an average interval of 4 days (range: 1–16 days). The number of patients in each timepoints respectively were 45 (30.2%), 78 (52.3%), 74 (50.0%), 53 (35.6%) (Table 1) .

Table 1
Patients Characteristics

Gender	
Male	68(45.6%)
Female	81(54.4%)
Age (years)	
Range	1–89
The Age of Patients in Main Pattern of Lesion(years)	
Pure GGO	48 ± 15.3
GGO with reticulation	51 ± 15.0
GGO with consolidation	49 ± 15.3
Consolidation	51 ± 16.5
Exposure History	
Recent Travel to Wuhan OR Exposure to Infected Patient	136(91.3%)
Unknown Exposure	13(8.7%)
Symptoms	
Fever	122(81.9%)
Cough	83(55.7%)
Myalgia or Fatigue	49(32.9%)
Phlegm	35(23.5%)
Headache	23(15.4%)
Pharyngalgia	20(13.4)
Diarrhoea	9(6.0%)
The Number of Patients in Each Timepoints	
Within 4 days	45(30.2%)
5–8 days	78(52.3%)
9–12 days	74(50.0%)
13–16 days	53(35.6%)

2. Imaging Characteristics Of Chest CT

In the chest CT data collected within 4 days of onset group, the number of lesions in the S10 segment of the lungs and the S6 segment of left lung was the largest. The main imaging features included 30 (20.13%) cases of pure ground glass opacities. The statistical results show that there was a statistical difference with the 5–8 days group ($P < 0.05$). 38 (25.50%) cases of GGO with reticulation showed statistical differences with the 9–12 days group (P 0.01). 46 (30.87%) cases of GGO with consolidation and 12 (8.05%) cases of consolidation. The statistical results showed statistically significant differences from the 9–12 days group and the 13–16 days group ($P < 0.01$). There were 28 (18.79%) cases of air bronchogram and 13 (8.72%) cases of subpleural line. Other secondary signs included bronchiectasis in 8 (5.37%) cases, pleural effusion in 8 (5.37%) cases, lymphadenopathy in 2 (1.34%) cases, and no pericardial effusion or cavities (Table 2–3) .

Table 2
Longitudinal dynamic chest CT imaging feature Changes in Patients with Coronavirus 2019-nCoV Pneumonia,No. of segments (%)

			No. of Segments (%) Disease onset to CT within first 4 Days	No. of Segments at 5–8 Days	No. of Segments at 9–12 Days	No. of Segments at 13–16 Days
Left	**Upper**	**S1 + S2**	30(6.5%)	53(6.1%)	65(6.3%)	40(5.5%)
		S3	18(3.9%)	30(3.4%)	35(3.4%)	20(2.8%)
		S4	21(4.5%)	40(4.5%)	50(4.8%)	33(4.6%)
		S5	21(4.5%)	45(5.1%)	56(5.4%)	34(4.7%)
	Lower	**S6**	34(7.3%)	58(6.6%)	65(6.3%)	48(6.6%)
		S7 + S8	27(5.8%)	45(5.1%)	53(5.1%)	36(5.0%)
		S9	23(4.9%)	51(5.8%)	68(6.6%)	46(6.3%)
		S10	36(7.7%)	62(7.0%)	71(6.9%)	51(7.0%)
Right	**Upper**	**S1**	23(4.9%)	42(4.8%)	47(4.5%)	39(5.3%)
		S2	29(6.2%)	52(5.9%)	58(5.6%)	45(6.2%)
		S3	20(4.3%)	36(4.1%)	43(4.2%)	29(4.0%)
	Middle	**S4**	22(4.7%)	48(5.5%)	54(5.2%)	44(6.1%)
		S5	27(5.8%)	49(5.6%)	47(4.5%)	40(5.5%)
	Lower	**S6**	27(5.8%)	61(7.0%)	71(6.9%)	48(6.6%)
		S7	18(3.8%)	39(4.5%)	51(4.9%)	41(5.7%)
		S8	22(4.7%)	39(4.5%)	53(5.1%)	35(4.8%)
		S9	32(6.9%)	55(6.3%)	65(6.3%)	46(6.3%)
		S10	34(7.3%)	69(7.9%)	81(7.8%)	50(6.9%)
the Number of Segments at Presentation and at Evolution						
Presentation				1970(63.5%)		
Evolution				1134(36.5%)		

Table 3
Longitudinal dynamic chest CT imaging feature Changes in Patients with Coronavirus 2019-nCoV Pneumonia,No. of patients (%)

	Disease onset to CT Features at first 4 Days	Features at 5–8 Days	Features at 9–12 Days	Features at 13–16 Days
Opacification				
Normal	3(2.0%)	2(1.3%)	0(0.0%)	2(1.3%)
Pure GGO	30(20.1%)	71(47.7%)	49(32.9%)	34(22.8%)
GGO with reticulation	38(25.5%)	69(46.3%)	85(57.0%)	48(32.2%)
GGO with consolidation	46(30.9%)	78(52.4%)	81(54.4%)	53(35.6%)
Consolidation	12(8.1%)	34(22.8%)	41(27.5%)	34(22.8%)
Air bronchogram	28(18.8%)	57(38.3%)	54(36.2%)	29(19.5%)
subpleural line	13(8.7%)	27(18.1%)	29(19.5%)	22(14.8%)
Other Feature				
Bronchiectasis	8(5.4%)	19(12.8%)	21(14.1%)	18(12.1%)
Pleural effusion	8(5.4%)	9(6.0%)	12(8.1%)	7(4.7%)
pericardial effusion	0(0.00%)	3(2.0%)	1(0.7%)	1(0.7%)
lymphadenopathy	2(1.3%)	3(2.0%)	4(2.7%)	1(0.7%)
Cavity	0(0.0%)	0(0.0%)	0(0.0%)	0(0.0%)

In the group of 5–8 days after onset, the number of lesions in the S10 segment of the lungs and S6 segment of the right lung was the largest. The main imaging features included 71 (47.65%) cases of pGGO ($P < 0.05$), 69 (46.31%) cases of GGO with reticulation ($P < 0.01$), 78 (52.35%) cases GGO with consolidation, 34 (22.82%) cases of consolidation, 57 (38.26%) cases of air bronchogram, 27 (18.12%) cases of subpleural line. Other secondary signs included bronchiectasis in 19 (12.75%) cases, pleural effusion in 9 (6.04%) cases, lymphadenopathy in 3 (2.01%) cases, pericardial effusion in 3 (2.01%) cases, and no cavities (Table 2–3) .

In the 9–12 days group, the number of lesions in the S10 segment of the lungs and S6 segment of the right lung was the largest. The main imaging features included 49 (32.89%) cases of pGGO. There were 85 (57.04%) cases of GGO with reticulation, and the statistical results showed that they were statistically different from the other three groups ($P < 0.01$). 81 (54.36%) cases of GGO with consolidation, and 41 (

27.52%) cases of consolidation (P < 0.01), 54 (36.24%) cases of air bronchogram, 29 (19.46%) cases of subpleural line. Other secondary signs included 21 (14.09%) cases of bronchiectasis, 12 (8.05%) cases of pleural effusion, 8 (5.37%) cases of lymphadenopathy, 1 (0.67%) case of pericardial effusion, and no cavities (Table 2–3) .

In the group of 13–16 days after onset, the number of lesions in the S10 segment of the lungs and the right lower lobe of S6 segment was the largest. The main imaging features included 34 (22.82%) cases of pGGO, and 48 (32.21%) cases of GGO with reticulation (P < 0.01), 53 (53.57%) cases of GGO with consolidation, 34 (22.82%) cases of consolidations (P < 0.01), and 29 (19.46%) cases of air bronchogram, 22 (14.77%) cases of subpleural line. Other secondary signs included bronchiectasis in 18 (12.08%) cases, pleural effusion in 7 (4.70%) cases, lymphadenopathy in 1 (0.67%) case, pericardial effusion in 1 (0.67%) case, and no cavities (Table 2–3) .

In our case, a total of 4 patients had no manifestations of chest CT at the first examination. One patient had pGGO on chest CT on the 5th day of admission and the other three patients had no change in chest CT during the stay in hospital. In addition, we also calculated the time from the patient's symptoms to the first manifestation of chest CT imaging, 31 (21.2%) cases of which were 0 days, 50 (34.3%) were 1–4 days, 59 (40.4%) were 5–8 days, 4 (2.7%) were 9–12 days and 2 (1.4%) cases were 13–16 days (Table 4). The total number of lung segments in the course of presentation was 1970 (63.5%), and the evolution was 1134 (36.5%).

Table 4
Days during the onset and initial imaging findings,No. of patients (%)

Days during the onset and initial imaging findings	No. of patients
0 days	31 (21.2%)
1–4 days	50 (34.3%)
5–8 days	59 (40.4%)
9–12 days	4 (2.7%)
13–16 days	2 (1.4%)

Discussion

The imaging findings of COVID-19 pneumonia and other viral pneumonias do have some imaging features in common. The imaging performance also changes with the progress of the disease. Our study selected six representative sites covering China from north to south, randomly collected patient data, and eventually collected a total of 149 patients. The smallest host was only 1 year old and the oldest was 89. We found that older patients or those with underlying diseases such as heart disease or diabetes have

more severe imaging findings than others, and this requires further research. The most common onset of COVID-19 pneumonia patients is fever and cough, which is consistent with other reports[7, 8].

In view of the unique advantages of chest CT in chest imaging and its high spatial resolution, it helps radiologist to evaluate the patients' condition in a more detailed and comprehensive way and to provide a strong basis for the patient's clinical process. We recommend COVID-19 pneumonia patients to use high-resolution CT scan. Our research shows that the predominant sites of COVID-19 pneumonia are the posterior basal and dorsal segments of the lower lobes. In all of our cases, only peripheral or peripheral mixed central types were seen, which is sufficient to remind us of the development of COVID-19 pneumonia. It may gradually infiltrate from the outer zone of both lungs. Our data shows that the most severely affected lung segments in the four periods are the left lower lobe S10 (36 / 7.7%), the right lower lobe S10 (69 / 7.9%), and the right lower lobe S10 (81 / 7.8%), S10 segment of the right lower lobe (50 / 6.9%), S10 segment of the right lower lobe (81 / 7.8%). The number of lung segments involved in the presentation period is higher than the evolution period (Table 2).

The main imaging characteristics of COVID-19 pneumonia are pGGO, GGO with reticulation, GGO with consolidation, and consolidation[7, 8], which is consistent with our research (Fig. 1). COVID-19 pneumonia is basically similar to other viral pneumonia, and we try to reveal its evolution through continuous investigation. Our study found that the pGGO was most commonly found within 5–8 days of onset, and it was statistically different from the 4 days before onset ($P < 0.05$). This is different from previous studies[9]. We assume that the statistics we include are pGGO and the interference factors such as a little reticulation or consolidation are excluded. Another reason is that the patient's imaging performance may have a certain delay after the clinical onset. In this set of data, the imaging onset time of 50 patients (34.3%) occurred after 1–4 days of symptoms, and 59 (40.4%) occurred after 5–8 days. The latest cases showed imaging performance after second weeks of symptoms (Table 4). We believe that these results can better reveal the evolution of the disease (Fig. 2).

The imaging findings of COVID-19 pneumonia mainly involve the interstitial lung tissue[7–9]. In addition to pGGO, the most common signs included pGGO with reticulation, GGO with consolidation and subpleural lines. The pGGO with reticulation (81 / 54.36%) reached the highest peak in 8–12 days, and it was statistically different from the other three groups ($P < 0.01$). These interstitial changes are also called Crazy-paving pattern[7]. In addition, consolidation of varying sizes is also commonly seen with air bronchogram. Among them, the number of consolidation within 4 days was the smallest (12 / 8.05%), and it was statistically different from the other three groups. It reached the maximum within 9–12 days (41 / 27.52%). The gradual involvement is more likely from interstitial lung tissue to parenchyma and reveals the process of gradual absorption and prognosis of lesions. All the imaging characteristics can be observed at the same time in the chest CT in one patient (Fig. 3–4) .

COVID-19 pneumonia also has some other non-specific manifestations, which are different from previous report[7]. Lymphadenopathy and pleural effusion were found in our cohort. In addition, a small number of

patients can see mild bronchiectasis and a small amount of pericardial effusion. No cavity-like lesions were found, which was helpful to distinguish it from S. aureus pneumonia.

Our study has the following limitations: We did not score the patients based on their age, comorbidities, etc. In addition, there are still some patients without any CT findings, which needs further study. Due to there is no specific treatment for this disease, our follow-up observation of patients remains to be seen. Follow-up investigation will be reflected in subsequent research.

Conclusion

Chest CT scans of patients with COVID-19 pneumonia can help clinicians to better evaluate the disease process, and also help to understand the development of the disease. The main imaging manifestation of COVID-19 pneumonia is that the interstitial changes gradually change to the consolidation. The most common patterns of COVID-19 pneumonia on chest CT images are pure GGO, GGO with reticulation, GGO with consolidation and consolidation, with prominent distribution in the S10 and S6 segments of the lungs. Consolidation lesions could be served as a marker of disease progression or more severe disease.We infer that the extent of lesion involvement peaks about a week after the patient's clinical symptoms appear, which needs to be taken seriously by clinicians and be prepared for symptomatic treatment as soon as possible.

Abbreviations

2019-nCoV (COVID-19): 2019-novel coronavirus; ARDS: acute respiratory distress syndrome; pGGO: pure ground glass opacities; GGO: ground glass opacities; HRCT: high-resolution computed tomography

Declarations

Authors' Contributions

ZL and MR contributed equally to this paper. HL and ZL are both corresponding authors of this paper. ZL and MR: acquisition of data, analysis and interpretation of data, drafting the manuscript. LW: acquisition of data, analysis and interpretation of data. YY, YL, LL, XG, ZL, HL: acquisition of data and interpretation of data. ZL and MR: conception and design, analysis and interpretation of data, modifying and revising the manuscript. All the authors read and approved the final manuscript.

Ethics approval and consent to participate

Both the review boards of the First Affiliated Hospital of Harbin Medical University and the You'An Hospital of Capital Medical University waived written informed consent for this retrospective case series, which evaluated unidentified data without potential risks to patients.

Consent for publication

Not applicable.

Availability of data and materials

The datasets used and/or analysed during the current study are available from the corresponding author on reasonable request. These patients have not been reported in any other submission by us or anyone else.

Competing interests

The authors declare that they have no competing interests.

Funding

The study was supported by a grant from National natural science foundation of China (General Program; Grant No.81771806) and National natural science foundation of China (Key Program; Grant No.61936013) . The funders had no role in the study design, data collection and analysis, decision to publish, or preparation of the manuscript.

Acknowledgements

We’d like to express our sincere thanks to all those who have lent our hands in the course of our writing this paper. First of all, We'd like to take this opportunity to show my sincere gratitude to our supervisors, Hongjun Li and Zhiyan Lu, who have given us so much useful advices on our writing and has tried their best to improve our paper. Secondly, We’d like to express our gratitude to our teammates who offered each other references and information on time.

Authors' Information

1. Department of Radiology, the First Affiliated Hospital of Harbin Medical University Harbin, 150001, China; lvzhehao1992@126.com (Zhehao Lyu)

2. Imaging Center, Beijing You'an Hospital, Capital Medical University, Beijing, 100069, China; renmeiji0611@126.com (Meiji Ren); 15001017169@139.com (Li Li) ; lihongjun00113@126.com (Hongjun Li)
3. Department of Radiology, Zhongnan Hospital Affiliated to Wuhan University, wuhan, 430071, China; luzhiyan@whu.edu.cn (Zhiyan Lu) ;15172734978@163.com (Xiaoming Gong)
4. Department of Radiology, Ren Ji Hospital, School of Medicine, Shanghai Jiao Tong University, Shanghai 200127, China; wlmssmu@126.com (Lian-Ming Wu)
5. The Sixth People's Hospital of Xinjiang Uygur Autonomous Region, Xinjiang, 830001 China; yangyuxin6068@163.com (Yuxin Yang)
6. Department of Radiology, the Fourth People's Hospital of Nanning, Nanning 530023, China; 13768415203@139.com (Yi-Bo Lu)

References

1. Li Q, Guan X, Wu P, et al. Early Transmission Dynamics in Wuhan, China, of Novel Coronavirus-Infected Pneumonia. The New England journal of medicine 2020. doi: .
2. Zhu N, Zhang D, Wang W, et al. China Novel Coronavirus Research I T. A Novel Coronavirus from Patients with Pneumonia in China, 2019. The New England journal of medicine 2020. doi: .
3. World Health Organization. Novel coronavirus (2019-nCoV). Situation report 27. Geneva, Switzerland: World Health Organization; 2020. 78_2 Published on February 17, 2020.
4. Huang C, Wang Y, Li X, et al. Clinical features of patients infected with 2019 novel coronavirus in Wuhan, China. Lancet 2020.doi:.
5. Graham RL, Donaldson EF, Baric RS. A decade after SARS: strategies for controlling emerging coronaviruses. Nat Rev Microbiol. 2013;11(12):836–48. doi:.
6. National Health Commission of the People's Republic of China
Diagnosis and treatment protocols of pneumonia caused by a novel coronavirus (trial version 3) 8fpdf Published on January 22, 2020.
National Health Commission of the People's Republic of China. Diagnosis and treatment protocols of pneumonia caused by a novel coronavirus (trial version 3). 8fpdf Published on January 22, 2020.
7. Michael C, Adam B, Xueyan M, et al. CT Imaging Features of 2019 Novel Coronavirus(2019-nCoV).Radiology.2020Feb.
8. Song F, Shi N, Shan F, et al. Emerging Coronavirus 2019-nCoV Pneumonia. Radiology.2020 Feb 06; :200274. DOI: .
9. Pan F, Ye T, Sun P, et al. Time Course of Lung Changes On Chest CT During Recovery From 2019 Novel Coronavirus (COVID-19) Pneumonia. Radiology.2020 Feb 13; :200370. DOI: .

Figures

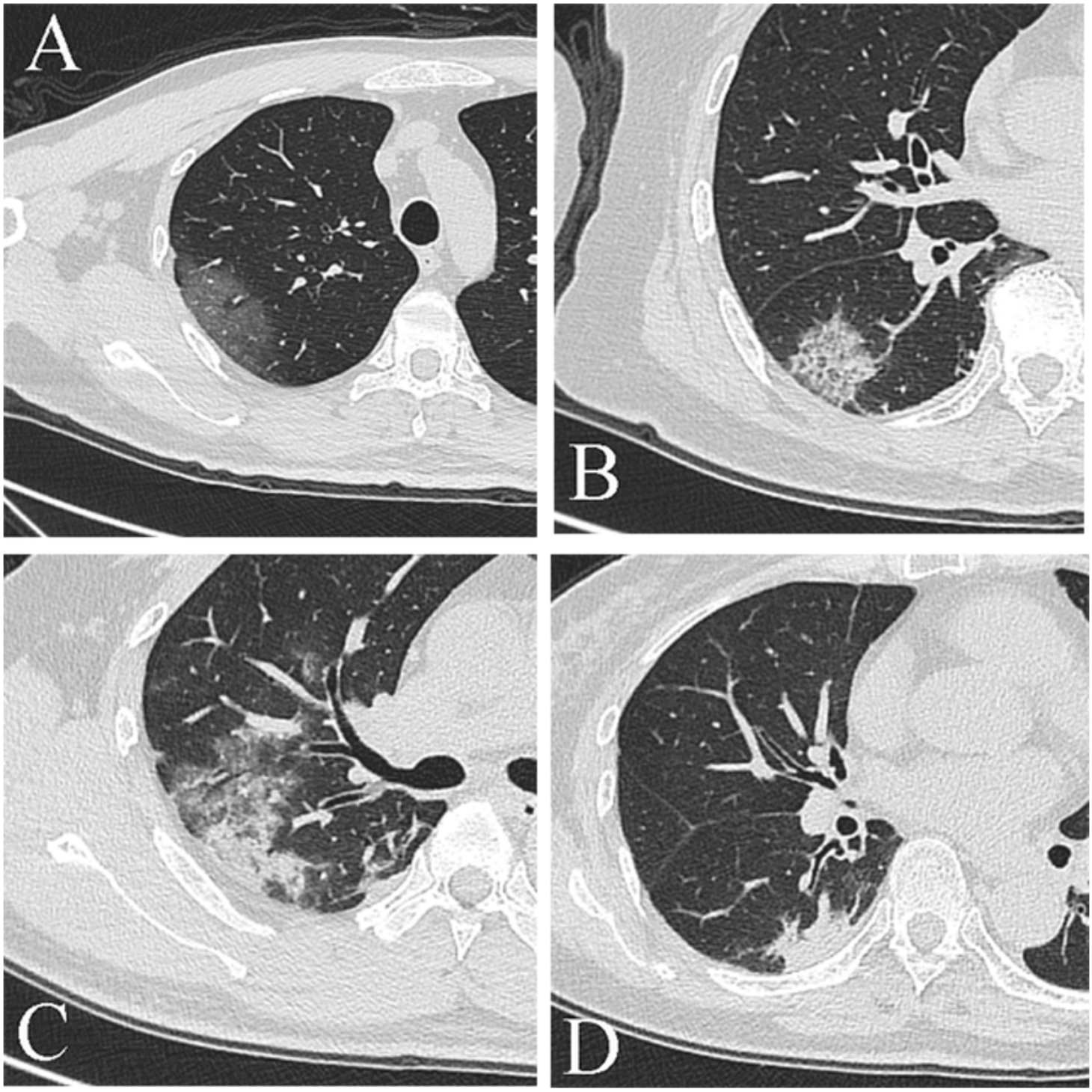

Figure 1

Chest CT findings of COVID-19 pneumonia on transaxial images. A. pGGO; B. GGO with reticulation; C. GGO with consolidation; D. Consolidation

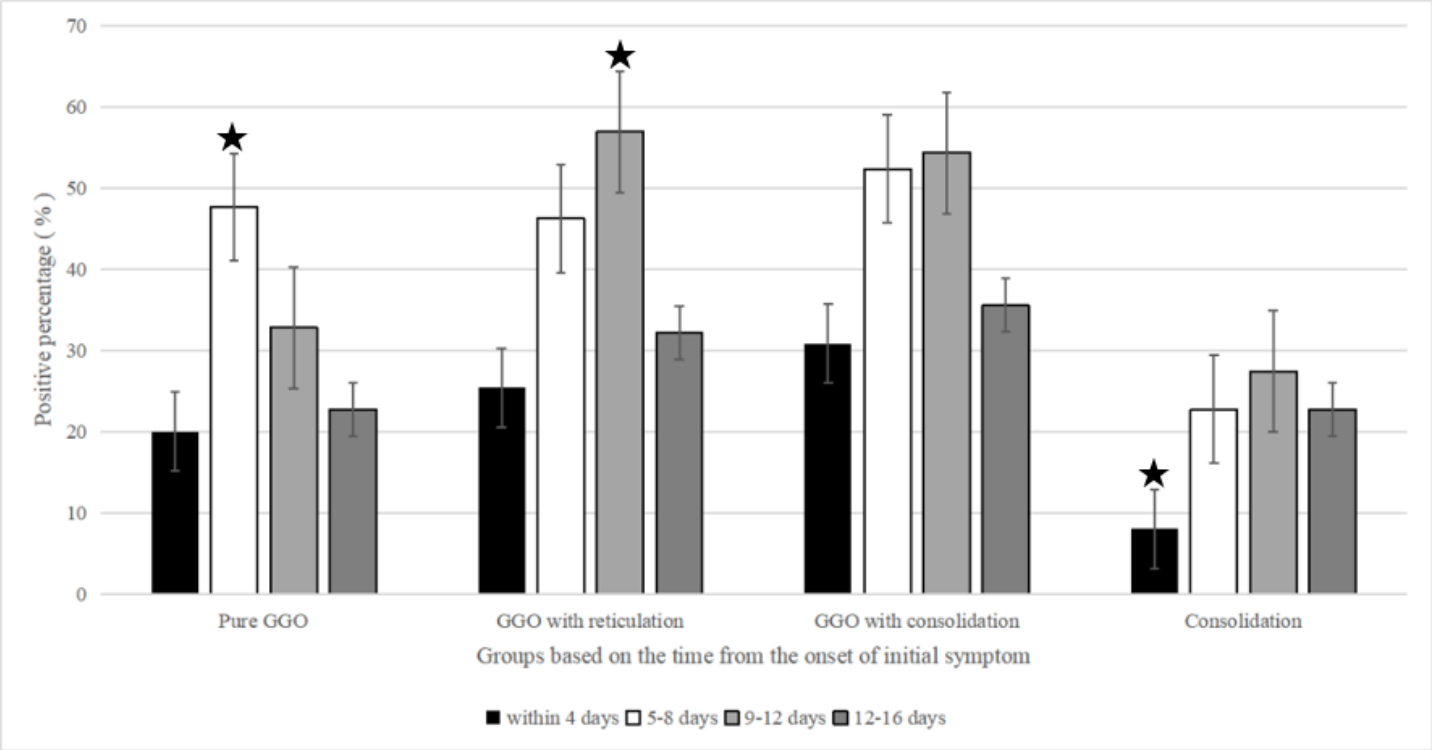

Figure 2

Changes in the proportions of patients with pGGO, GGO with reticulation GGO with consolidation and consolidation as a function of stage. (A star represents the difference is considered significant)

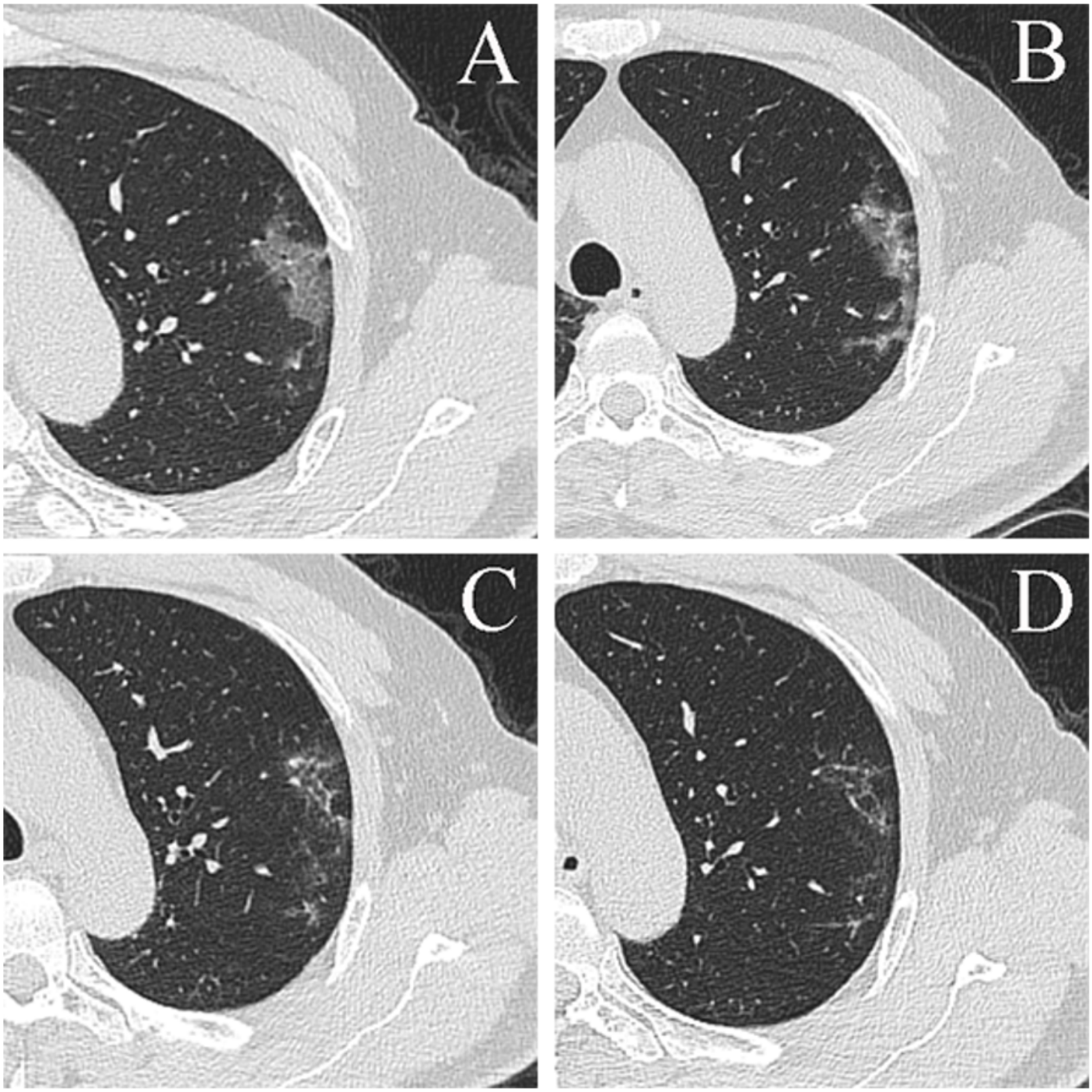

Figure 3

A 40-50 year old male patient. A. Chest CT showed pGGO in the left upper lobe 4 days after the onset of the disease. Partial reticulation was seen. B. Chest CT showed the lesion gradually turned to GGO with consolidation after 8 days. C. The lesion was gradually absorbed after 11 days with some fibrous stripes left; D. After 15 days, the absorption was basically complete with some pGGO left.

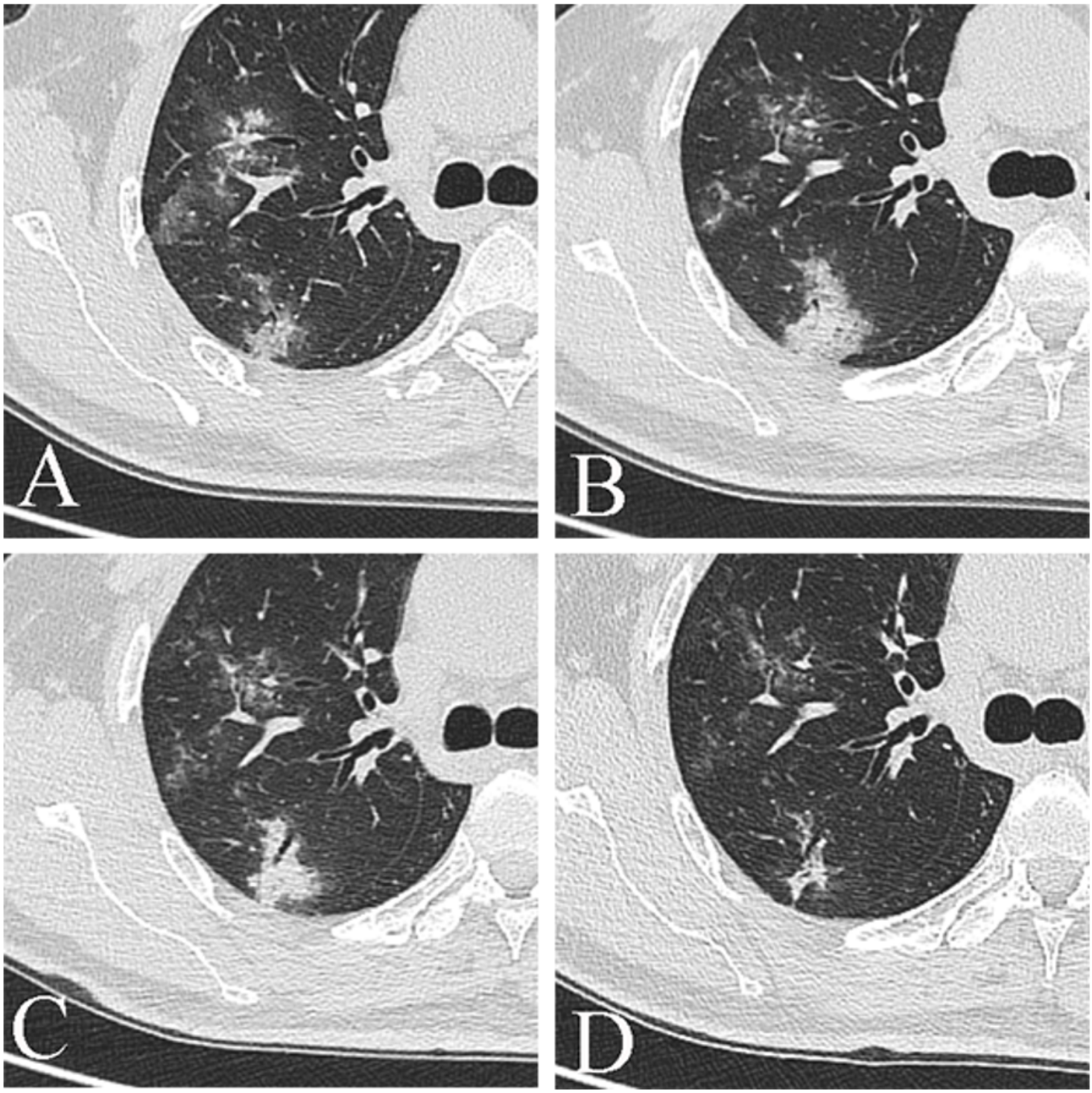

Figure 4

Same patient as Fig.3. A. Chest CT showed pGGO, GGO with consolidation, and consolidation at the same time in the right upper lobe 4 days after the onset; B. Chest CT showed GGO with consolidation gradually converted to consolidation after 8 days, and air bronchogram can be observed; C. After 11 days, it can be seen that the consolidation is still present, and the bronchus is slightly thickened. D. After 15 days, the lesions were gradually absorbed with small patchy GGO and consolidation left.