Minimal evisceration combined with orbital implantation

Haitao Zhang
Guangdong Pharmaceutical University
Shuhao Shen
Guangdong Pharmaceutical University
Jiajun Yang
Guangdong Pharmaceutical University
Zhe Xu (oculistxuzhe@163.com)
Guangdong Pharmaceutical University https://orcid.org/0000-0001-7915-4755

Research article

Keywords: Minimal evisceration technique, Implant, Surgical damage, Complication, Cosmetic outcome

Posted Date: April 23rd, 2020

DOI: https://doi.org/10.21203/rs.3.rs-20857/v1

Abstract

Background: To evaluate the minimal evisceration technique, which aims to reduce surgical damage and complications and achieve better cosmetic outcomes.

Methods: Eighty patients were enrolled from January 2013 to January 2019. All of the patients underwent a minimal evisceration and hydroxyapatite (HA) implant procedure, including making a lateral incision on the sclera only, transecting the optic nerve, and placing an HA implant behind the posterior sclera in the muscular cone. The implant was covered by two layers of the sclera. The main outcome measures were surgery time, blood loss, days of hospitalization, time interval for placement of prosthesis after surgery, complications, such as implant extrusion or exposure, enophthalmos, conjunctival sac stenosis, and cosmetic outcome.

Results: All of the patients received minimal evisceration combined with an orbital implant. The average surgery time was 30 min, blood loss was 3 ml, days of hospitalization were 3, and the time interval for placement of the prosthesis after surgery was 4 week. No complications were recorded. The cosmetic appearance and implant mobility were satisfactory.

Conclusions: This technique has advantages such as less damage, fast recovery, good effects and fewer complications. It appears to be a perfect modification for anophthalmic socket reconstruction.

Background

For several ophthalmic and facial diseases, such as phthisis bulbi, glaucoma, and traumatic injury, eye evisceration, or enucleation appears to be one of the possible options to ensure an acceptable better facial appearance and pain relief.[1] Evisceration is a surgical technique involving removal of the intraocular contents while leaving the sclera and extraocular orbital anatomy intact. This technique was first introduced by Bear in 1817.[2] Lose of orbital volume induces enophthalmos after eye evisceration or enucleation, which seriously affects the facial appearance and is difficult to repair.[3] Until now, various techniques and modifications have been developed that allow placement of a large implant and avoidance of the risk of implant exposure or extrusion as well as providing a better cosmetic effect.[2, 4–6] However, there are many disadvantages currently used surgery techniques, such as long surgery time, extensive operation damage, large amount of blood loss, long hospitalization times, slow recovery, and many possible complications.

This study evaluated the modified evisceration time, blood loss, days of hospitalization, time interval for placement of prosthesis after surgery, complications, and cosmetic outcomes.

Methods

This was an interventional case series that included 80 patients who underwent minimal evisceration and a hydroxyapatite implant procedure from January 2013 to January 2019. Among these patients, 37 cases

involved atrophy (46.3%), 22 cases had secondary glaucoma (26.8%), 8 cases had staphyloma (10%), and 13 cases had trauma (16.3%). An informed consent form was signed by the patients or their guardians. The study and data collection conformed to all local laws and complied with the principles of the Declaration of Helsinki.

Indications for the surgery included relieving pain in a blind eye, or cosmetic improvement of a disfigured eye. The absolute contrain- dications were intraocular malignancy and endophthalmitis. Careful examinations included ultrasonography and computerized tomography scans when required, which were undertaken to exclude the possibility of intraocular malignancy and endophthalmitis. Patients with unstable blood pressure or blood glucose control, severe orbital fractures without surgical correction, or patients with systemic diseases who could not tolerate surgery were excluded from the study.

Surgical technique

After administration of local or general anesthesia, an eyelid speculum was placed between the eyelids. A 360-degree conjunctival peritomy was performed just posterior to the corneal limbus, and then the cornea was removed and the intraocular contents were delivered. The interior of the sclera shell was scraped with a blade. Hemostasis of the central retinal artery and vortex veins was obtained by digital pressure with cotton moistened gauze. A sclerotomy vertical to the limbus was performed in the superior nasal quadrant to the optic papilla. Then the optic nerve was transected to loosen the sclera, turn the posterior sclera out, and scrape out all visible uveal tissue remnants with a blade. The edges of the sclera incision were clamped with a teeth forceps, and the Tenon’s capsule of the superior nasal quadrant was opened with the hook. The posterior intramuscular cone space, was exposed, and then an appropriate hydroxyapatite implant with the diameter of, 22 mm that was infiltrated with antibiotic/corticosteroid solution, was placed in the posterior sclera muscle cone. The sclera was sutured with interrupted 6 – 0 vicryl suture thread, Tenon’s capsule was closed with interrupted 6 – 0 vicryl suture thread, and the conjunctiva was closed with running 8 – 0 vicryl suture thread. An antibiotic/corticosteroid ophthalmic ointment was placed in the conjunctival sac with an overlying socket conformer. (Fig. 1).

After surgery, systemic antibiotics and corticosteroid as well as topical corticosteroid were prescribed for the first week, and only topical steroid eye drops were used for the subsequent 4 weeks. The patients were examined again at the first week and fourth week after surgery and then were referred to an ocularist for prosthesis fitting. Postoperative follow-up visits took place at 1, 4, 8, and 12 weeks, and then every year after the surgery with the same examiner.

Results

All of the patients underwent minimal evisceration and a hydroxyapatite implant. No complications were recorded, the average surgery time was 30 min, blood loss was 3 ml, days of hospitalization were 3, and the time interval for placement of the prosthesis after surgery was 4weeks.In a mean four years follow-up period (ranging from 1 to 7 years), there was no case of implant extrusion or exposure, enophthalmos, or conjunctival sac stenosis. The cosmetic appearance and implant mobility were satisfactory (Fig. 3).

Discussion

At present, the anophthalmic socket reconstruction methods commonly used in the clinic include the Russian doll technique, four petals technique and on-the-table technique, all of which are modified eye evisceration procedures.[7, 8] C.Kaeilani et al. compared the effectiveness and safety of the three surgical techniques and found that the four petals technique had the best postoperative cosmetic effect, the fewest complications, and the lowest reoperation rate.[7] The surgery technique adopted in this clinical study was also modified eye evisceration, which was different from other classic surgeries in the following aspects: 1) Tenon's capsule in only one quadrant (superior nasal) needed to be separated after the conjunctival peritomy; 2) Only a lateral incision to the optic papilla on the sclera was made, 3) There was no extraocular muscle separation; 4) Implants with larger diameters were available, both of which were 22 mm; and 5) There were fewer surgery steps, shorter surgery times, less blood loss, and shorter hospitalization times. Because of the modifications of the above aspects, the surgical method had many advantages, such as less damage, faster recovery, and weaker inflammatory reaction after the surgery. In addition, no obvious complications occurred during the long follow-up period, and implant mobility and the cosmetic effect were satisfactory.

Implant extrusion or exposure was the most serious complication after evisceration. Although the surgical method has received many improvements, and the incidence of these complications has been significantly reduced, they still exist. Liu reported that the incidence of implant exposure after evisceration varied from 0–20%.[9] If the implant is placed too shallow, the implant is too large, or there is bleeding in the retrobulbar area, the tension of Tenon's capsule will be high, which will lead to rupture of the incision, extrusion, or exposure of the implant. In this study, no patient had implant exposure or extrusion. The possible reasons are as follows: 1) The orbital implant was in the intramuscular cone, and two layers of sclera were present anteriorly, preventing migration, erosion, and extrusion (Fig. 2); 2) The implant was exposed to soft tissue directly, which is beneficial for vascularization; 3) There was a large elastic space in the posterior bulbar muscle cone, and therefore an implant with a diameter of 22 mm or more will not cause high tension of Tenon's capsule; 4) This modified technique produced less damage to the ocular surface, a reduced postoperative inflammatory response, and faster recovery; and 5) Porous HA was used in this study. It is one of the ideal materials for filling the orbital volume after enucleation or evisceration. It is well tolerated by surrounding tissues, and its porous structure can be rapidly infiltrated by host tissue.

Enophthalmos, which is caused by a small implant or absorption of orbital fat, is another serious complication after surgery. It causes difficulties when revision surgeries are needed. C.Keilani et al. compaired average implant diameters in a retrospective review, and they found that the Russian dolls technique group's average was 16 mm, the on-the-table technique group's average was 19.9 mm, and the four petals technique group diameter was 20 mm. The incidence of enophthalmos was higher in the Russian dolls technique group.[7] No enophthalmos occurred in this study. This was likely due to the large elastic space in the posterior bulbar muscle cone, which allowed an implant with a diameter of 22 mm or more to be implanted, which could correct the orbital volume loss better, and ensure the full appearance of the socket.

Conjunctival sac stenosis after evisceration is often seen in cases with multiple operations or trauma history. The conjunctival scar and adhesion are difficult to separate, and it is easily damaged. The complicated cases need minimal damage surgery. No complication of conjunctival sac stenosis was documented in this study. The modified technique allowed the conjunctiva, Tenon's capsule, sclera, and extraocular muscles to remain intact, which protected the ocular surface to the greatest extent. In other surgical methods, especially the on-the-table method, separating the Tenon's capsule in four quadrants, cutting off the extraocular muscles, and removing the sclera shell, will cause great damage to the ocular surface. Therefore, the on-the-table method is not suitable for particularly complicated cases.

Although the patients had a satisfactory cosmetic effect after placement of the ocular prosthesis in this study, the motility of the prosthesis was not ideal, because the prosthesis and the socket were not fixed, and the movement of the socket could not drive the prosthesis to produce a synchronous and equal amount of movement. In the past, some doctors fixed the prosthesis on the socket with nails, which improved the mobility of the prosthesis, but at the same time, there were serious complications; e.g., exposure of the socket, infection, and conjunctival granuloma.[10–13] Therefore, this flaw still needs to be improved.

Conclusions

Minimal evisceration combined with orbital implantation has advantages such as less damage, fast recovery, good effects and fewer complications. It appears to be a perfect modification for anophthalmic socket reconstruction. This technique still needs to be verified by a randomized, double-blind, and multicenter clinical study.

Abbreviations

HA
Hydroxyapatite
ML
Milliliter
MIN
Minute
MM
Millimeter

Declarations

Ethics approval and consent to participate

Approved by Ethics Committee of the First Affiliated Hospital of Guangdong Pharmaceutical University. All patients understood and signed informed consent form before surgery. This was written in the

manuscript in Methods section.

Consent for publication

All participants have been given written consent for their personal details along with images to be published in this study (images in Fig1, Fig3). A copy of the written consent is available for review by the Editor of this journal.

Availability of data and material

All data generated or analyzed during this study are included in this published article.

Competing interests

The authors declare that they have no competing interests.

Funding

This research was funded by National Natural Science Found (Grant No. 81371004).

Author Contributions

Zhe Xu designed research; Haitao Zhang conducted research; Shu hao Shen and Jia jun Yang analyzed data; Haitao Zhang wrote the first draft of manuscript; Zhe Xu had primary responsibility for final content. All authors read and approved the final manuscript.

Acknowledgments

None.

References

1. Chan SWS, Khattak S, Yucel N, Gupta N, Yucel YH. A decade of surgical eye removals in Ontario: a clinical-pathological study. Can J Ophthalmol. 2017;52(5):486–93.
2. Timothy NH, Freilich DE, Linberg JV. Evisceration versus enucleation from the ocularist's perspective. Ophthalmic Plast Reconstr Surg. 2003;19(6):417–20. **discussion 420**.
3. Lemaire A, Dakpe S, Lafitte J, Sorrel-Dejerine E, Testelin S. [Enophtalmos of the anophtalmic socket: incidence of the orbital morphology and therapeutic implications. Clinical study of 86 cases]. Ann Chir Plast Esthet. 2012;57(6):549–57.
4. Conroy BF. A brief sortie into the history of cranio-oculofacial prosthetics. Facial Plast Surg. 1993;9(2):89–115.
5. Martin O, Clodius L. The history of the artificial eye. Ann Plast Surg. 1979;3(2):168–71.

6. Sales-Sanz M, Sanz-Lopez A. Four-petal evisceration: a new technique. Ophthalmic Plast Reconstr Surg. 2007;23(5):389–92.
7. Keilani C, Baus A, Tick S, Sahel JA, Boumendil J. Effectiveness and safety comparison of three eye and orbital reconstruction techniques in facial plastic surgery. Ann Chir Plast Esthet. 2019;64(4):351–61.
8. Huang D, Yu Y, Lu R, Yang H, Cai J. A modified evisceration technique with scleral quadrisection and porous polyethylene implantation. Am J Ophthalmol. 2009;147(5):924–8. **928 e921-923**.
9. Liu D. A comparison of implant extrusion rates and postoperative pain after evisceration with immediate or delayed implants and after enucleation with implants. Trans Am Ophthalmol Soc. 2005;103:568–91.
10. Su GW, Yen MT. Current trends in managing the anophthalmic socket after primary enucleation and evisceration. Ophthalmic Plast Reconstr Surg. 2004;20(4):274–80.
11. Guillinta P, Vasani SN, Granet DB, Kikkawa DO. Prosthetic motility in pegged versus unpegged integrated porous orbital implants. Ophthalmic Plast Reconstr Surg. 2003;19(2):119–22.
12. Custer PL, Trinkaus KM, Fornoff J. Comparative motility of hydroxyapatite and alloplastic enucleation implants. Ophthalmology. 1999;106(3):513–6.
13. Colen TP, Paridaens DA, Lemij HG, Mourits MP. Comparison of artificial eye amplitudes with acrylic and hydroxyapatite spherical enucleation implants. Ophthalmology. 2000;107(10):1889–94., **van Den** Bosch WA.

Figures

Figure 1

A: An eyelid speculum was placed between the eyelids; B: Sclerotomy vertical to the limbus was performed in the superior nasal quadrant to the optic papilla; C: The implant was placed into the muscle cone. D: The sclera was sutured with an interrupted 6-0 vicryl suture thread; E: The sclera shell was folded into double layers, and it covered the implant; F:Tenon’s capsule and conjunctiva were closed with a vicryl suture.

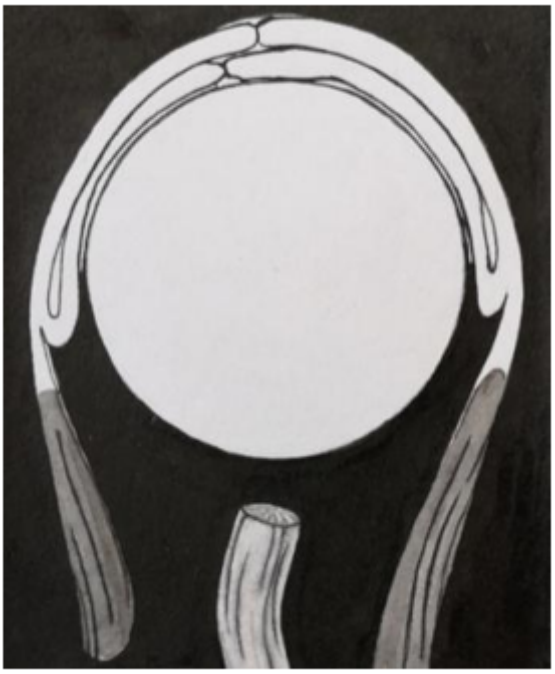

Figure 2

Double layers of sclera covered the implant to prevent exposure, extrusion, migration, and erosion.

Figure 3

A: Pre-evisceration cosmesis. Obvious facial deformity, enophthalmos, and asymmetry(right eye).B:Postevisceration cosmesis. The cosmetic appearance of the patient was satisfactory after placing the ocular prosthesis (right eye).